

Evidence for Locus Heterogeneity in Puerto Ricans with Hermansky-Pudlak Syndrome

Senator Hazelwood,^{1,2} Vorasuk Shotelersuk,¹ Scott C. Wildenberg,⁴ David Chen,¹ Fumino Iwata,⁴ Muriel I. Kaiser-Kupfer,³ James G. White,⁵ Richard A. King,⁴ and William A. Gahl¹

¹Section on Human Biochemical Genetics, Heritable Disorders Branch, National Institute of Child Health and Human Development, ²Howard Hughes Medical Institute, NIH Research Scholars Program, and ³Ophthalmic Genetics and Clinical Services Branch, National Eye Institute, Bethesda; and ⁴Departments of Medicine and Pediatrics and the Institute of Human Genetics and ⁵Department of Laboratory Medicine, University of Minnesota, Minneapolis

Summary

Hermansky-Pudlak syndrome (HPS) consists of oculocutaneous albinism, a platelet storage-pool deficiency, and ceroid lipofuscinosis. In a recent report on the cloning of an *HPS* gene, all 22 Puerto Rican HPS patients were homozygous for a 16-bp duplication in exon 15. This presumably reflected a founder effect for the *HPS* mutation in Puerto Rico. Nevertheless, we ascertained two individuals from central Puerto Rico who lacked the 16-bp duplication, exhibited significant amounts of normal-size *HPS* mRNA by northern blot analysis, and had haplotypes in the *HPS* region that were different from the haplotype of every 16-bp-duplication patient. Moreover, these two individuals displayed no mutations in their cDNA sequences, throughout the entire *HPS* gene. Both patients exhibited pigment dilution, impaired visual acuity, nystagmus, a bleeding diathesis, and absent platelet dense bodies, confirming the diagnosis of HPS. These findings indicate that analysis of Puerto Rican patients for the 16-bp duplication in *HPS* cannot exclude the diagnosis of HPS. In addition, HPS most likely displays locus heterogeneity, consistent with the existence of several mouse strains manifesting both pigment dilution and a platelet storage-pool deficiency.

Introduction

Hermansky-Pudlak syndrome (HPS) consists of the triad of oculocutaneous albinism, a bleeding diathesis, and lysosomal accumulation of ceroid lipofuscin (Herman-

sky and Pudlak 1959). The sine qua non for diagnosis of this autosomal recessive disorder is the absence of platelet dense bodies on wet-mount electron microscopy (Witkop et al. 1987a); this finding explains the lack of a secondary aggregation response of platelets in vitro, as well as easy bruisability in patients themselves. The albinism of HPS manifests with congenital nystagmus, iris transillumination, a visual acuity range of 20/50–20/400, and variable reductions in skin pigmentation (Summers et al. 1988; Witkop et al. 1989). Ceroid lipofuscin consists of an unidentified lipid/protein complex considered to accumulate in cellular lysosomes and to cause pulmonary fibrosis (Garay et al. 1979; Harmon et al. 1994) and granulomatous colitis (Schinella et al. 1980) in some patients. HPS reportedly occurs in 1/1,800 people in northwestern Puerto Rico (Witkop et al. 1990), because of a founder effect, but it has also been described in a Swiss isolate (Lattion et al. 1983) and in almost all ethnic groups (Witkop et al. 1989). In addition, several inbred strains of mice have both pigment dilution and a platelet storage-pool defect (Novak et al. 1984). Two genes responsible for these mouse phenotypes, *ruby eye* and *pale ear* (Novak et al. 1981), map to mouse chromosome 19, in a region syntenic with human chromosome 10q23, the location of the human *HPS* gene. Recently, the *pale ear* gene was shown to be homologous to the human *HPS* gene (Feng et al. 1997; Gardner et al. 1997).

The genetic mapping of *HPS*, performed by linkage analysis in 36 families from northwestern Puerto Rico (Wildenberg et al. 1995), permitted subsequent physical mapping of *HPS* (Oh et al. 1996). Cloning and cDNA sequencing demonstrated that the gene's coding region contains 2,100 bp, predicting a protein with a presumed molecular weight of 79.3 kD. Although 20 exons are now known to exist, and although the genomic structure of *HPS* has been described (Bailin et al. 1997), the function of the *HPS* product remains unknown. In the original report on the *HPS* gene (Oh et al. 1996), mutational analysis revealed a homozygous, 1-bp insertion at codon P324 in six Swiss patients and one Irish patient and a

Received June 23, 1997; accepted for publication September 2, 1997; electronically published October 29, 1997.

Address for correspondence and reprints: Dr. William A. Gahl, Section on Human Biochemical Genetics, 10 Center Drive, MSC 1830, Building 10, Room 9S-241, NICHD, NIH, Bethesda, MD 20892-1830. E-mail: bgahl@helix.nih.gov

© 1997 by The American Society of Human Genetics. All rights reserved. 0002-9297/97/6105-0013\$02.00

Table 1
PCR Primer Sets for Amplifying cDNA Fragments of *HPS*

Fragment	Primer Sequences	Nucleotides ^a
<i>HP-1</i> (310 bp)	5'-GCTTGCCAAGATGAAGTGCCTC-3'	-9 to 12
	5'-TCGGTGTGGTCACCAATTGATG-3'	300 to 279
<i>HP-2</i> (401 bp)	5'-GGAGAATGCCTGTTTCATTGCC-3'	259 to 279
	5'-AATGCCAGCAGCTTGGAGTG-3'	659 to 640
<i>HP-3</i> (437 bp)	5'-CCAAGCTGCTGGCATTCTACTC-3'	644 to 665
	5'-GCTTTCCTTCACGTTGGCATC-3'	1080 to 1060
<i>HP-4</i> (357 bp)	5'-ACACCCTCCAAACACTGGTTCC-3'	998 to 1019
	5'-TAAACTCCAGCCAGGTGCTCTG-3'	1354 to 1333
<i>HP-5</i> (405 bp)	5'-TTGTCAAGAATCGAGGGGCAC-3'	1304 to 1324
	5'-CCAACTCCGACGAGGTCTTTTG-3'	1708 to 1687
<i>HP-6</i> (415 bp)	5'-CGGCTGAACTTTCTGACCACAG-3'	1447 to 1468
	5'-ACCCCATGTCATTCTCGAACC-3'	1861 to 1841
<i>HP-7</i> (338 bp)	5'-CCTACTTCTGTGGTCGAGAATG-3'	1829 to 1852
	5'-GAACAGTGGCAAGCAAGGGTG-3'	2166 to 2146

^a Nucleotide numbering is according to standard nomenclature, with the A of the ATG initiation codon assigned the numeral "1." Note that this is nucleotide number 207 in the numbering system of Oh et al. (1996).

homozygous, 1-bp insertion at codon A441 in a single inbred Japanese patient. All 22 Puerto Rican HPS patients examined were homozygous for the same mutation, a 16-bp duplication in exon 15 of *HPS* (Oh et al. 1996). This finding, combined with the strong population evidence of a founder effect, raised the possibility that all Puerto Rican HPS patients could be diagnosed with a simple molecular test based on PCR amplification of the region encompassing the 16-bp duplication.

However, we have ascertained two individuals of Puerto Rican ancestry who display the clinical characteristics of HPS yet lack the 16-bp duplication. In fact, they exhibit no discernible mutation in *HPS*, suggesting that locus heterogeneity has resulted in two types of HPS, arising in different geographical areas of Puerto Rico.

Subjects and Methods

All patients were enrolled in a protocol approved by the National Institute of Child Health and Human Development institutional review board, to study the clinical, biochemical, and molecular aspects of HPS. Informed consent was obtained either from each patient or from the patient's parents.

Electron Microscopy of Platelet Dense Bodies

Fresh blood was immediately mixed in a 9:1 ratio with 93.0 mmol sodium citrate/liter, 7.0 mmol citric acid/liter, and 140 mmol dextrose/liter (pH 6.5). Drops of platelet-rich plasma, separated from whole cells by centrifugation at 100 g for 20 min at room temperature, were placed on the top sides of formvar-coated, carbon-stabilized 300-mesh copper grids for 10–15 s. The grids were rinsed sequentially with four drops of distilled wa-

ter, with care not to wet the bottom sides. The first three drops were shaken off immediately, and the fourth was quickly removed from the edges with filter paper. Grids were air-dried and were examined in a Phillips Model 301 electron microscope.

PCR Detection of the 16-bp Duplication

DNA was prepared from peripheral blood lymphocytes (Sambrook et al. 1989). A 269-bp fragment spanning exon 15 of *HPS* was amplified by PCR in a 50- μ l volume containing 50 mM KCl, 1.5 mM MgCl₂, 5 mM Tris (pH 8.3), 200 mM dNTPs, 0.01% gelatin, 0.6 mM primers (5'-GATGGTCCACAAAGGACGAG-3'/5'-GCTGAAGGAAGTACGGGCC-3'), 2.5 U *Taq* polymerase, and 500 ng template DNA. After an initial denaturation step at 94°C for 2 min, PCR was conducted for 30 cycles, each consisting of a 1-min denaturation step at 94°C, followed by annealing for 30 s at 60°C, and extension for 1 min at 72°C, and a final elongation step for 10 min at 72°C. PCR products were electrophoresed in 3% agarose and were stained with ethidium bromide.

SSCP Analysis

Fibroblast RNA was reverse transcribed by use of a first-strand cDNA kit (Gibco-BRL), and the 2.1-kb coding region of the *HPS* cDNA was amplified by use of seven sets of primers (table 1). The PCR was performed with 50 mM KCl, 1.5 mM MgCl₂, 5 mM Tris (pH 8.3), 200 mM dNTPs, 0.01% gelatin, 2.5 U *Taq* polymerase, 0.4 mM each primer, and 2 μ l cDNA, in a final volume of 50 μ l. Products were radiolabeled by inclusion of 1 μ Ci α -³²P[dCTP]. After an initial denaturation step at 94°C for 3 min, PCR was conducted for 30 cycles, each with a denaturation step at 94°C for 30 s, annealing at

56°C for 30 s, and extension at 72°C for 2 min, and a final elongation step at 72°C for 10 min. The PCR products were denatured with 10 μ l formamide and heating at 94°C for 10 min and were fractionated, either at room temperature or at 4°C, by electrophoresis for 12 h on a 0.5 \times MDE gel (AT Biochemical). The gel was prepared in 0.6 \times Tris-borate EDTA with or without 5% glycerol and was subjected to autoradiography.

Sequence Analysis

Direct, automated fluorescent sequencing was performed, by Biotech Research Laboratories, on cDNA fragments of *HPS* that had been PCR-amplified by use of the primers listed in table 1. Additional sequencing was performed on full-length cDNA that was PCR-amplified by use of the HP-1 forward primer and the HP-7 reverse primer. After being subcloned into the pCR 2.1 vector (InVitrogen), several clones were selected, and two clones representing different alleles were chosen by identification of specific polymorphic sequences. DNA sequencing was performed by use of an ABI 373 automated DNA sequencer, according to a standard protocol supplied by the manufacturer (Perkin-Elmer). Both strands of DNA were sequenced.

Northern Blots

Total RNA (10 mg), isolated from cultured fibroblasts by use of Trizol reagent (Life Technologies), was separated on a 1.2% agarose/3% formaldehyde gel and was blotted onto a Nytran nylon membrane (Schleicher & Schuell) in the presence of 20 \times SSC. The blot was prehybridized and then hybridized with ExpressHyb solution (Clontech) at 68°C. Full-length human *HPS* cDNA, random primer labeled with α -³²P[dCTP] (duPont/NEN), served as the probe. After hybridization, the blot was washed several times at room temperature with 2 \times SSC/0.05% SDS and once with 0.1 \times SSC/0.1% SDS at 50°C and was exposed to Kodak XAR film with an intensifying screen for 24 h at -70°C.

Haplotype Analysis

Simple tandem-repeat polymorphisms were amplified in 5- μ l PCR reactions (Wildenberg et al. 1995) containing the two primers specific to the marker and a third, fluorescently labeled primer that hybridizes to a 19-bp tail added to the 5' end of one of the marker primers (5'-CACGACGTTGTAAAACGAC-3'). Reactions were prepared in 96-well plates with 2 mM MgCl₂, 50 mM KCl, 10 mM Tris-HCl (pH 9.0), 0.1% Triton-X-100, 200 mM dNTPs, 1 pmol each marker primer, 0.1 pmol M13 primer, 1 U *Taq* polymerase, and 20 ng DNA. PCR products were separated on a 5.5% denaturing acrylamide gel by use of the LI-COR DNA 4000 automated

infrared sequencer (LI-COR). Allele sizes were determined by use of RFLPScan software (Scanalytics).

Results

Case Reports

Patient 1 is a 47-year-old man born in New York City of parents who both came from Naranjito, Puerto Rico. He had nystagmus at birth, and his hair color was lighter than that of three siblings but was the same shade as that of two other siblings. These two siblings have not been extensively investigated and have not been diagnosed with HPS. The patient had worn glasses since 2-3 years of age. Bruising had occurred since the time of ambulation, and nosebleeds had been frequent in elementary school. Rectal bleeding at age 5 years had required a transfusion, and surgeries for tonsillectomy, strabismus repair, and intestinal blockage had caused excessive bleeding. Aggregation studies performed at age 44 years had resulted in the diagnosis of HPS, and the patient had been treated prophylactically with desmopressin acetate for subsequent hernia repairs. During the past 3 years, bloody stools have occurred occasionally but have been attributed to anal fissures. The patient now experiences dyspnea after walking either three blocks or up one flight of stairs.

On physical examination, height was 170 cm, weight was 113.6 kg, and skin pigmentation appeared normal (fig. 1B). Best corrected visual acuity was 20/50 in the right eye and 20/100 in the presumably amblyopic left eye, with significant horizontal nystagmus and minimal transillumination (fig. 1B). Unlike other albino patients, this man exhibited hypopigmentation in the periphery of the retina and choroid, with prominent choroidal vasculature in the posterior pole. The hemoglobin was 15.1 g/dl, with a hematocrit of 45% and a platelet count of 287,000/mm³. Electron microscopy of a wet mount of platelets showed absent dense bodies (fig. 2B). Total serum cholesterol was 221 mg/dl, with LDL-cholesterol of 136 mg/dl and HDL-cholesterol of 35 mg/dl. Triglycerides were 252 mg/dl. On pulmonary function testing, the forced vital capacity was 85% of predicted, forced expiratory in 1 s was 94% of predicted, total lung capacity was 83% of predicted, and diffusing capacity for carbon monoxide was 101% of predicted. A computed-tomography scan of the chest revealed no fibrosis. Serum electrolytes, liver-function tests, mineral levels, and thyroid studies were normal. The serum creatinine was 1.0 mg/dl, and two 24-h urine creatinine-clearance values were 141 and 125 ml/min.

Patient 2 is a 4-year 11-month-old girl from Philadelphia. Her maternal grandmother was from Arecibo, Puerto Rico, her paternal grandmother and grandfather were from Aibonito, Puerto Rico, and her maternal grand-

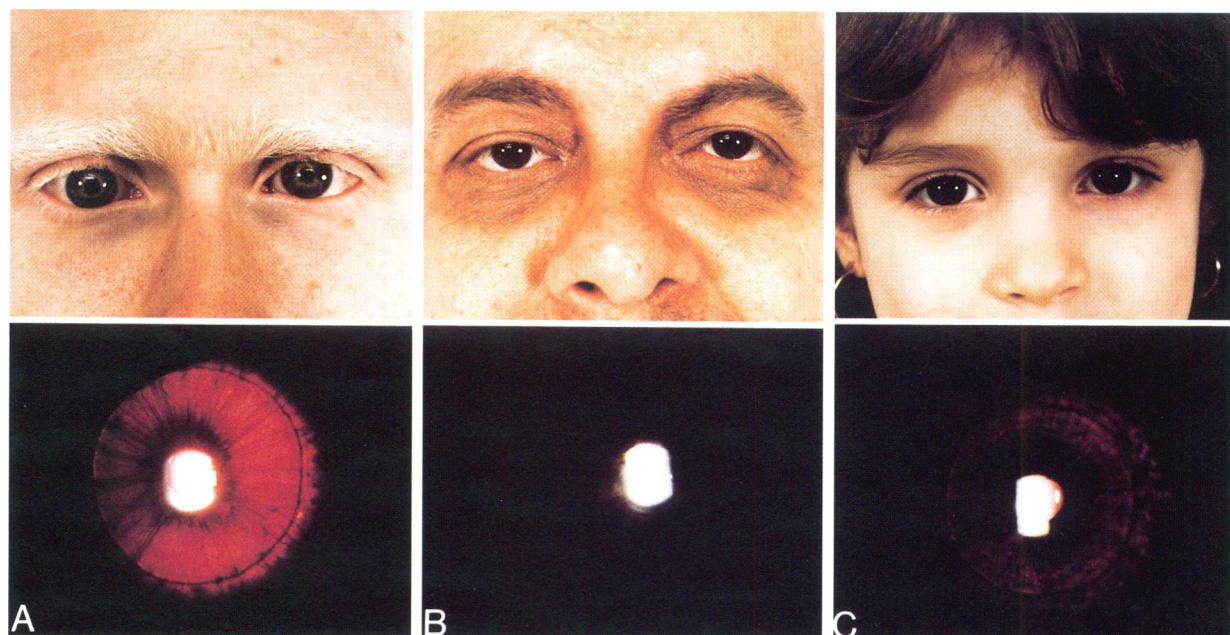


Figure 1 Pigment dilution in Puerto Rican patients with HPS. A patient homozygous for the 16-bp duplication in exon 15 of *HPS* has light eyebrows and eyelashes, with extensive iris transillumination (A), whereas, in contrast, patient 1 has significant hair pigmentation and negligible iris transillumination (B), and patient 2 has relatively dark hair and moderate iris transillumination (C).

father was from Naranjito, Puerto Rico. The only relevant family history was that the father's paternal uncle had light skin and bruising but no visual impairment or nystagmus. At birth, the patient herself had nystagmus and blond hair, which later darkened; she was diagnosed with albinism at 2 mo of age. She began bruising on ambulation at 10–12 mo of age but did not experience nosebleeds or excessive bleeding on cutting her skin. Platelet-aggregation studies at 3 years of age led to the diagnosis of HPS.

On physical examination, height was 107 cm (40th percentile), and weight was 19.3 kg (75th percentile). Her skin was mildly depigmented (fig. 1C). Visual acuity was 20/100 in each eye, but its reliability was questionable, in view of the patient's age. Iris transillumination was moderate (fig. 1C). Fundus examination revealed significant hypopigmentation of the retina and choroid. Laboratory studies revealed a hemoglobin level of 11.7 g/dl, hematocrit of 35%, and platelet count of 319,000/mm³. Electron microscopy of a wet mount of platelets

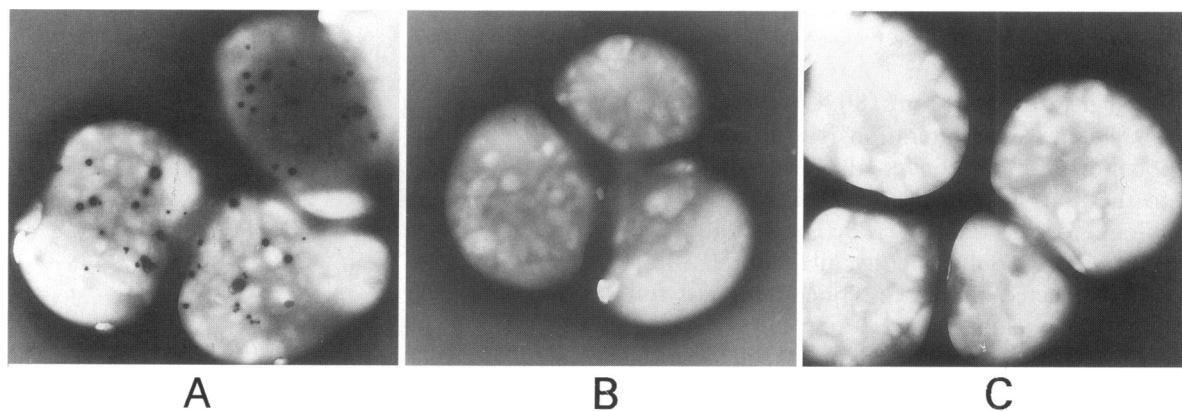


Figure 2 Electron micrograph of wet mount of platelets from a normal individual (A), patient 1 (B), and patient 2 (C) ($\times 9,700$). Patients 1 and 2 lack platelet dense bodies.

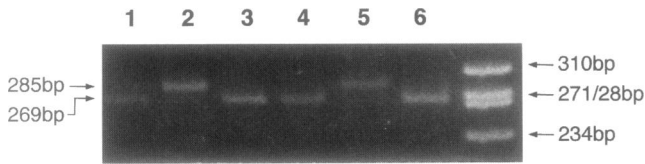


Figure 3 Agarose gel electrophoresis of *HPS* fragment containing 16-bp duplication in exon 15. PCR fragments were amplified from the genomic DNA of two normal individuals (lanes 1 and 6), two classic Puerto Rican *HPS* patients (lanes 2 and 5), and our patients 1 and 2 (lanes 3 and 4). DNA size markers are on the right. The normal-size fragment is 269 bp; the 285-bp fragment reflects a 16-bp duplication. A 3% agarose gel was employed.

showed absent dense bodies (fig. 2C). Pulmonary-function tests were poorly performed. The serum creatinine was 0.6 mg/dl, and electrolytes, liver-function tests, mineral levels, and thyroid studies were all normal.

Molecular Studies

PCR amplification in the region of exon 15 of *HPS* revealed the typical 16-bp duplication, yielding a 285-bp product, in 25/27 Puerto Rican patients. All these patients or their parents were originally from northwestern Puerto Rico, and all were homozygous for the 16-bp duplication. In contrast, patients 1 and 2 displayed a normal-size, 269-bp fragment (fig. 3), with no evidence of the 285-bp fragment. Consequently, a mutation in *HPS* was sought by performance of SSCP analysis of the two patients' cDNA. This was accomplished by PCR amplification of *HPS* cDNA in seven separate fragments (table 1). Only fragment 6 in patient 1 and fragments 5 and 6 in patient 2 showed a difference from normal migration on an MDE gel (data not shown). Sequencing demonstrated that the fragment 5 change occurred because patient 2 was heterozygous for c1472C→G, a known polymorphism causing a P491R alteration (Oh et al. 1996). The fragment 6 changes reflected the finding that patient 1 was homozygous and patient 2 was heterozygous for c1809G→A, resulting in an R603Q change. This alteration is also a nonpathologic polymorphism (Bailin et al. 1997) and corresponds to the normal sequence of the mouse *ep* gene, the homologue of the human *HPS* (Feng et al. 1997; Gardner et al. 1997). Subsequently, all seven *HPS* fragments were subjected to direct sequencing, and full-length *HPS* cDNA clones representing both alleles of each patient were also sequenced. Normal sequence was observed in the area of the 16-bp duplication, for all four alleles of patients 1 and 2. No amino acid-altering changes were observed in any other region of *HPS*.

HPS expression was assessed in patients 1 and 2 by northern blot analysis of RNA extracted from their cultured fibroblasts. The RNA filter, which also contained

samples from normal individuals and from Puerto Rican patients harboring the 16-bp duplication, was probed with the full-length *HPS* cDNA. Although patients homozygous for the 16-bp duplication showed no *HPS* RNA, patients 1 and 2 displayed an approximately normal contingent of normal-size *HPS* RNA (fig. 4).

Haplotype Analysis

Typical Puerto Rican *HPS* patients exhibit a particular haplotype in the area surrounding the *HPS* gene (Wildenberg et al. 1995). In fact, their homozygosity at three specific loci on chromosome 10q2 (D10S58, D10S184, and D10S1433) reflects the founder effect for this autosomal recessive disease. Using markers for five loci surrounding *HPS*, we found that patients 1 and 2 exhibited, at each of the five loci, at least one allele that differed from that of the 16-bp-duplication patients (table 2). This meant that our two patients expressed four unique haplotypes, none of which was shared by the Puerto Rican patients homozygous for the 16-bp duplication.

Discussion

In clinical practice, *HPS* is diagnosed on the basis of the presence of albinism and a platelet storage-pool defect. Ceroid lipofuscin appears only sporadically among non-Puerto Ricans with *HPS* (Witkop et al. 1987b) and accumulates gradually even in Puerto Rican patients with classic *HPS*. Hence, our patients 1 and 2 fulfill standard criteria for *HPS*. They exhibit skin-pigment di-

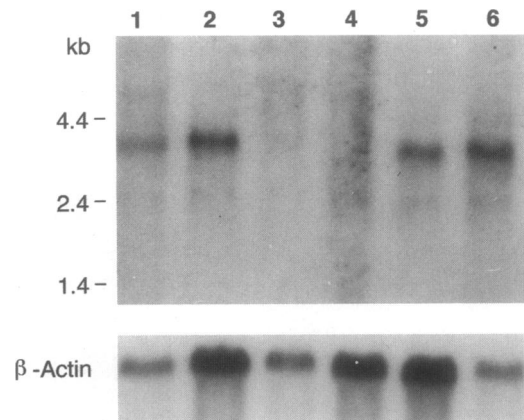


Figure 4 Northern blot of *HPS* mRNA. Total RNA from normal kidney (lane 1), normal fibroblasts (lane 2), fibroblasts carrying the 16-bp duplication in *HPS* (lanes 3 and 4), and fibroblasts of patient 2 (lane 5) and of patient 1 (lane 6) were probed with the full-length *HPS* cDNA. Probing with β -actin indicates unequal loading, but lane 1 serves as a normal control for lane 6, and lane 2 provides a control for lane 5. Patients homozygous for the 16-bp duplication exhibited no *HPS* mRNA, whereas patients 1 and 2 displayed significant amounts of normal-size *HPS* mRNA.

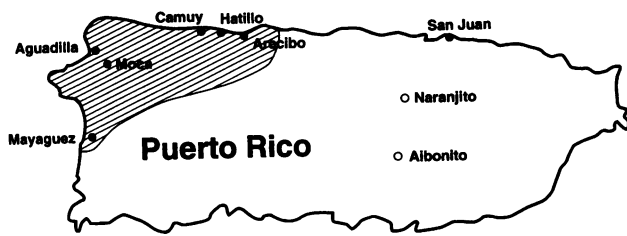


Figure 5 Map of Puerto Rico. Patients with the 16-bp duplication are from northwestern Puerto Rico (*shaded*). Our two patients have ancestors in Naranjito and Aibonito.

lution, relative to other family members, as well as iris transillumination, nystagmus, and impaired visual acuity. In each case, a clinical bleeding diathesis suggested the diagnosis of HPS, which was confirmed by aggregation studies and by the absence of platelet dense bodies on electron microscopy (fig. 2).

Nevertheless, our patients did not display the exact HPS phenotype characteristic of Puerto Rican patients. Visual-acuity deficits were less severe than those of classically affected patients. Our patients manifested minimal or moderate iris transillumination, compared with other Puerto Rican HPS patients, and their skin was only mildly depigmented (fig. 1). Indeed, molecular analysis confirmed that patients 1 and 2 are neither homozygous nor heterozygous for the 16-bp duplication that characterizes typical Puerto Rican HPS. This was demonstrated by PCR amplification (fig. 3) and direct sequencing of the region. Furthermore, cultured fibroblasts of patients 1 and 2 exhibited substantial amounts of normal-size *HPS* mRNA, which was absent from cells of patients homozygous for the 16-bp duplication (fig. 4). Finally, our two patients together displayed four different haplotypes in the region of *HPS*, none of which was the haplotype found in *every* patient bearing the 16-bp duplication (table 2).

If our atypical HPS patients did not manifest the 16-bp duplication, did they have a mutation elsewhere in *HPS*? Extensive direct and clonal sequencing of the entire *HPS* cDNA of both patients revealed only two polymorphisms, P491R (Oh et al. 1996) and R603Q (Bailin et al. 1997). The genomic DNA corresponding to a short, 1.5-kb alternate transcript of *HPS* was also sequenced in patients 1 and 2, and no mutation was found (S. Wildenberg, personal communication).

The absence of a disease-causing mutation in the *HPS* genes of our two patients suggests that HPS can be caused by mutations at another locus. It would not be surprising for other human loci to produce the cardinal features of HPS, since mutations in at least 12 different mouse loci give rise to the combination of pigment dilution and a storage-pool defect (Novak et al. 1981,

1984). There may even be a second founder effect for HPS on the island of Puerto Rico. The towns of origin of the two atypical patients—the towns of Naranjito and Aibonito—are ~12 miles apart in central Puerto Rico, 10 miles from San Juan but 40–70 miles from northwestern Puerto Rico (fig. 5). Patients from Naranjito and Aibonito would not have been included in mapping (Wildenberg et al. 1995) and cloning (Oh et al. 1996) studies involving excursions only to northwestern Puerto Rican cities such as Arecibo, Camuy, Hatillo, Queradilla, Aguadilla, and Moca. In our investigations, this bias of ascertainment was eliminated by acquisition of Puerto Rican patients from the mainland United States whose region of origin was unknown at the time of recruitment. Even though patients 1 and 2 are clearly not homozygous for *any* haplotype in the area of *HPS* (table 2), they may be homozygous for haplotypes surrounding another locus, and this would support a separate founder effect.

Patients 1 and 2 demonstrate that the diagnosis of *HPS* homozygosity or heterozygosity cannot be excluded in Puerto Rican individuals simply by the demonstration of the absence of the 16-bp duplication in exon 15 of *HPS*. However, since all 25 of our patients from northwestern Puerto Rico were homozygous for the 16-bp duplication, screening of patients from this part of the island may be useful. Our patients expand the phenotype of Puerto Rican HPS, to include a milder degree of hair, skin, and iris hypopigmentation and a milder visual deficit; these findings may help to differentiate this variant phenotype from the classic Puerto Rican disorder. More patients must be followed in order to determine the extent of pulmonary and gastrointestinal involvement in the new phenotype.

Finally, locus heterogeneity, if proved, should prompt the genetics community to decide what constitutes HPS. Is it a clinical diagnosis requiring the presence of albinism and a bleeding diathesis (with or without ceroid lipofuscinosis), or is it a molecular diagnosis requiring the presence of a mutation in the one known *HPS* gene? This situation for HPS resembles that for Zellweger disease 10 years ago, when a farrago of peroxisomal dis-

Table 2

Haplotypes and Alleles in the Region of *HPS*, for Puerto Rican Patients with HPS

LOCUS	HAPLOTYPES OF PATIENTS WITH 16-BP DUPLICATION		ALLELES ^a	
			Patient 1	Patient 2
D10S577	214	214	202, 206	206, 202
D10S58	226	226	222, 240	240, 222
D10S184	174	174	176, 184	174, 182
D10S1433	204	204	220, 220	216, 224
D10S198	201	201	201, 187	201, 187

^a Family studies to determine haplotypes were not performed.

orders was under investigation, each entity acquiring, in turn, definition as a specific defect (Lazarow and Moser 1995). For HPS, such resolution should arrive in the next few years, as mutations in the known *HPS* gene and in other causative loci are delineated and as their phenotypes are reported in detail.

Acknowledgments

We thank Dr. Jeff Touchman and the National Human Genome Research Institute, for assistance in the automated sequencing of cDNA fragments; Dr. Geraldine McDowell, of the National Institute of Child Health and Human Development, for her suggestions and insight; and Ernest M. Kuehl, of the National Eye Institute, for his superb ophthalmic photography.

References

- Bailin T, Oh J, Feng GH, Fukai K, Spritz RA (1997) Organization and nucleotide sequence of the human Hermansky-Pudlak syndrome (HPS) gene. *J Invest Dermatol* 108:923-927
- Feng GH, Bailin T, Oh J, Spritz RA (1997) Mouse *pale ear* (*ep*) is homologous to human Hermansky-Pudlak syndrome and contains a rare 'AT-AC' intron. *Hum Mol Genet* 6:793-797
- Garay SM, Gardella JE, Fazzini EP, Goldring RM (1979) Hermansky-Pudlak syndrome: pulmonary manifestations of a ceroid storage disorder. *Am J Med* 66:737-747
- Gardner JM, Wildenberg SC, Keiper NM, Novak EK, Rusiniak ME, Swank RT, Puri N, et al (1997) The mouse pale ear (*ep*) mutation is the homologue of human Hermansky-Pudlak syndrome (HPS). *Proc Natl Acad Sci USA* 94:9238-9243
- Harmon KR, Witkop CJ, White JG, King RA, Peterson M, Moore D, Tashjian J, et al (1994) Pathogenesis of pulmonary fibrosis: platelet-derived growth factor precedes structural alterations in the Hermansky-Pudlak syndrome. *J Lab Clin Med* 123:617-627
- Hermansky F, Pudlak P (1959) Albinism associated with hemorrhagic diathesis and unusual pigmented reticular cells in the bone marrow: report of two cases with histochemical studies. *Blood* 14:162-169
- Lattion F, Schneider PH, Da Prada M, Lorez HP, Richards JG, Picotti GB, Frenck E (1983) Syndrome d'Hermansky-Pudlak dans un village valaisan. *Helv Paediatr Acta* 38:495-512
- Lazarow PB, Moser HW (1995) Disorders of peroxisome biogenesis. In: Scriver CR, Beaudet AL, Sly WS, Valle D (eds) *The metabolic and molecular bases of inherited disease*, 7th ed. Vol 2. McGraw-Hill, New York, pp 2287-2324
- Novak EK, Hui S-W, Swank RT (1981) The mouse pale ear pigment mutant as a possible animal model for human platelet storage pool deficiency. *Blood* 57:38-43
- (1984) Platelet storage pool deficiency in mouse pigment mutations associated with several distinct genetic loci. *Blood* 63:536-544
- Oh J, Bailin T, Fukai K, Feng GH, Ho L, Mao J-i, Frenck E, et al (1996) Positional cloning of a gene for Hermansky-Pudlak syndrome, a disorder of cytoplasmic organelles. *Nat Genet* 14:300-306
- Sambrook J, Fritsch EF, Maniatis T (eds) (1989) *Molecular cloning: a laboratory manual*, 2d ed. Cold Spring Harbor Laboratory Press, Cold Spring Harbor, NY
- Schinella RA, Greco MA, Cobert BL, Denmark LW, Cox RP (1980) Hermansky-Pudlak syndrome with granulomatous colitis. *Ann Intern Med* 92:20-23
- Summers CG, Knobloch WH, Witkop CJ, King RA (1988) Hermansky-Pudlak syndrome: ophthalmic findings. *Ophthalmology* 95:545-554
- Wildenberg SC, Oetting WS, Almadóvar C, Krumwiede M, White JG, King RA (1995) A gene causing Hermansky-Pudlak syndrome in a Puerto Rican population maps to chromosome 10q2. *Am J Hum Genet* 57:755-765
- Witkop CJ, Babcock MN, Rao GHR, Gaudier F, Summers CG, Shanahan F, Harmon KR, et al (1990) Albinism and Hermansky-Pudlak syndrome in Puerto Rico. *Bol Asoc Med P R* 82:333-339
- Witkop CJ, Krumwiede M, Sedano H, White JG (1987a) Reliability of absent platelet dense bodies as a diagnostic criterion for Hermansky-Pudlak syndrome. *Am J Hematol* 26:305-311
- Witkop CJ, Quevedo WC, Fitzpatrick TB, King RA (1989) Albinism. In: Scriver CR, Beaudet AL, Sly WS, Valle D (eds) *The metabolic basis of inherited disease*, 6th ed. Vol. 2. McGraw-Hill, New York, pp 2905-2947
- Witkop CJ, Wolfe LS, Cal SX, White JG, Townsend D, Keenan KM (1987b) Elevated urinary dolichol excretion in the Hermansky-Pudlak syndrome: indicator of lysosomal dysfunction. *Am J Med* 82:463-470