

## Acute, Rapidly Progressive Renal Failure with Simultaneous Use of Amphotericin B and Pentamidine

DIANA ANTONISKIS AND ROBERT A. LARSEN\*

Los Angeles County-University of Southern California Medical Center, Los Angeles, California 90033

Received 2 August 1989/Accepted 8 December 1989

**We report four cases of acute reversible renal failure in patients with acquired immune deficiency syndrome who received both amphotericin B (for systemic mycoses) and pentamidine isethionate (for *Pneumocystis carinii* pneumonia). The concurrent use of amphotericin B with either inhaled pentamidine or trimethoprim-sulfamethoxazole did not cause significant renal impairment.**

Opportunistic infections associated with the acquired immune deficiency syndrome often occur simultaneously or in rapid succession. For this reason, patients are frequently treated with a myriad of antimicrobial, antifungal, or antiparasitic agents with attendant risks of combined toxic side effects. We have identified four patients who developed severe acute renal failure while receiving combination therapy with amphotericin B and parenteral pentamidine isethionate and whose renal failure was fully reversible on discontinuation of both medications.

From 1985 to 1988, 101 patients with acquired immune deficiency syndrome and systemic mycoses were treated with amphotericin B (92 with disseminated cryptococcosis, 7 with disseminated histoplasmosis, and 2 with disseminated coccidioidomycosis). Initial treatment consisted of 0.6 to 0.8 mg of amphotericin B per kg daily for the first 7 to 10 days followed by thrice-weekly dosing for approximately 9 weeks. Nine of these patients also received treatment for *Pneumocystis carinii* pneumonia while under active treatment for their systemic mycoses. A retrospective chart review was performed on those patients known to have developed pneumocystis pneumonia while receiving amphotericin B. *P. carinii* pneumonia was treated with parenteral pentamidine in four patients, intravenous trimethoprim-sulfamethoxazole in three patients, and inhaled pentamidine in two patients. Only those patients who received amphotericin B and parenteral pentamidine developed acute deterioration of renal function.

(This work was presented, in part, at the 28th Interscience Conference on Antimicrobial Agents and Chemotherapy, 3 to 7 October 1988, in Los Angeles, Calif.)

**Patient 1.** A 40-year-old female was discovered to have cryptococcal meningitis in October 1986. She had received 455 mg of amphotericin B with minimal renal insufficiency until late November 1986. At that time, she began to note increasing shortness of breath, and a presumptive diagnosis of *P. carinii* pneumonia was made; the patient was treated with intramuscular injections of pentamidine at 4 mg/kg per day. After the first week of pentamidine treatment, she was discovered to have a serum creatinine of 398  $\mu\text{mol/liter}$  (which had been 212  $\mu\text{mol/liter}$  prior to institution of pentamidine), so both pentamidine and amphotericin B were discontinued (Fig. 1). Therapy for cryptococcal meningitis was switched to intrathecal amphotericin B. Serum creatinine returned to baseline 9 days after discontinuation of amphotericin B and pentamidine.

**Patient 2.** A 44-year-old male was found to have cryptococcal meningitis in October 1987. He had responded well to systemic and intrathecal amphotericin B therapy (total doses, 1,365 and 5.75 mg, respectively). He was admitted in January 1988 with presumptive and ultimately proved *P. carinii* pneumonia, and treatment with trimethoprim-sulfamethoxazole was begun. His amphotericin B was continued in the hospital on a thrice-weekly schedule. Because of persistent nausea and vomiting, the patient's regimen was changed to intravenous pentamidine at 4 mg/kg per day on hospital day 3. The patient's serum creatinine rose from 159  $\mu\text{mol/liter}$  (prior to institution of pentamidine) to 398  $\mu\text{mol/liter}$  (3 days after the change in therapy) (Fig. 1). Therefore, both amphotericin B and pentamidine were discontinued on hospital day 6, and the patient was treated with oral trimethoprim and dapsone (in reduced doses) for a total of 3 weeks. His renal function returned to baseline 23 days after discontinuation of amphotericin B and pentamidine.

**Patient 3.** A 32-year-old male was admitted in July 1986 with *P. carinii* pneumonia which was treated with intravenous pentamidine at 4 mg/kg per day. His serum creatinine climbed from 88 to 177  $\mu\text{mol/liter}$  over the first 6 days of therapy. At this time, cryptococcal meningitis was discovered and amphotericin B treatment was started, with a total of 16 mg given over 3 days. His serum creatinine rose to 354  $\mu\text{mol/liter}$ , and amphotericin B was discontinued (Fig. 1). Pentamidine was continued for two more days, with an increase in the serum creatinine to 486  $\mu\text{mol/liter}$ , at which time pentamidine was also discontinued. Treatment for cryptococcal meningitis was continued with intrathecal injections of amphotericin B. Fifteen days after discontinuation of both systemic amphotericin B and pentamidine, the serum creatinine had returned to baseline, and systemic amphotericin B therapy was resumed without further worsening of renal function.

**Patient 4.** A 24-year-old male presented in August of 1988 with *P. carinii* pneumonia and was started on intravenous pentamidine at 4 mg/kg per day with no appreciable change in serum creatinine after 8 days of therapy. At this time, blood cultures were found to be growing *Histoplasma capsulatum*. Amphotericin B was initiated, but after a total dose of 121 mg of amphotericin B delivered over 4 days, the serum creatinine rose to 256  $\mu\text{mol/liter}$  and amphotericin B was discontinued (Fig. 1). Pentamidine was continued for an additional 2 days to complete a 14-day course of therapy. Serum creatinine returned to baseline 17 days after discontinuation of both medications, at which time amphotericin B

\* Corresponding author.

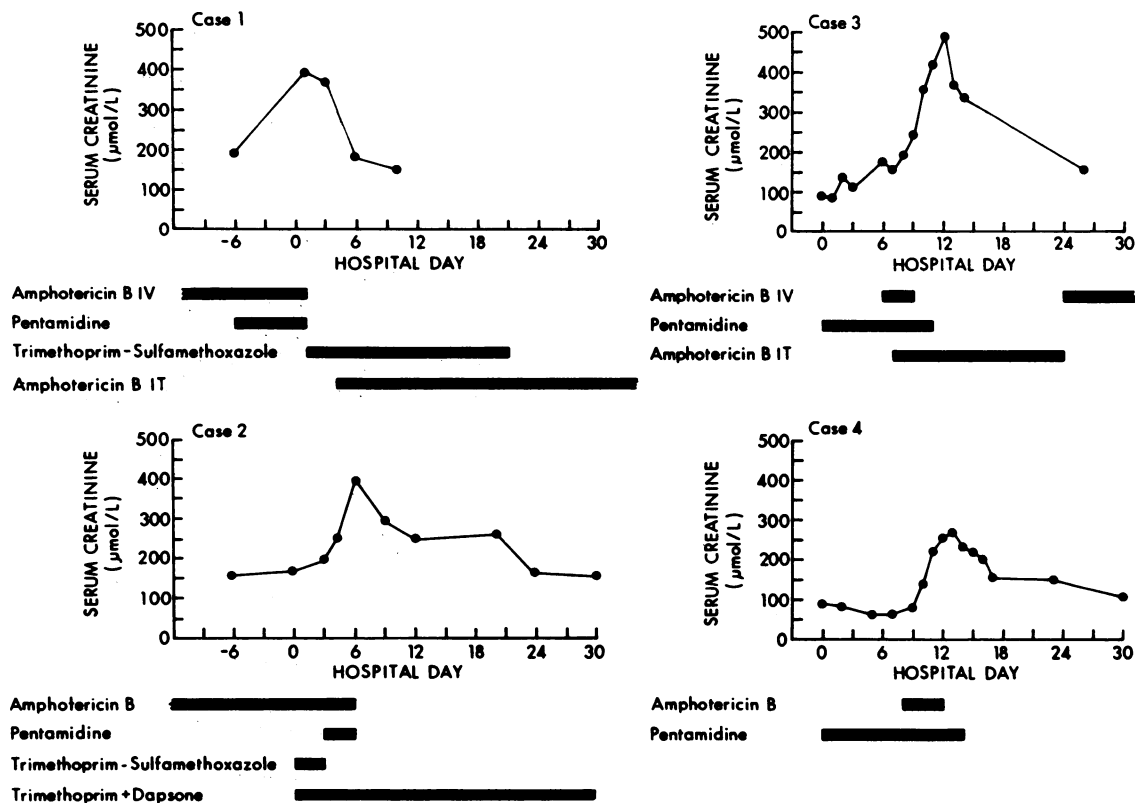


FIG. 1. Serum creatinine measurements in relation to amphotericin B and pentamidine therapy. IV, Intravenous; IT, intrathecal.

therapy was resumed. There has been no further deterioration in renal function.

Amphotericin B is the drug of choice for most systemic mycoses even though it commonly causes renal injury (1, 4, 5). Pentamidine isethionate is often used to treat *P. carinii* pneumonia, with its major toxic side effect being renal insufficiency (2, 6-9). Although one would expect that com-

bined use of two nephrotoxic agents would lead to increased risk of renal insufficiency, this association has not been previously documented. All four patients receiving this drug combination developed rapid renal failure, compared with neither of the two patients treated with inhaled pentamidine and none of the three patients treated with intravenous trimethoprim-sulfamethoxazole (Table 1). Order of administration of agents does not seem to be an influential factor. It is interesting that there were two patients receiving amphotericin B three times weekly who received concomitant pentamidine therapy by the inhalation route for treatment of *P. carinii* pneumonia. Neither of these patients experienced renal toxicity. We feel this may be due to the low levels of pentamidine in serum achieved with this route of therapy (3).

In summary, we have noted four cases in which simultaneous use of amphotericin B and pentamidine was associated with acute and rapidly progressive renal failure confounding the antimicrobial management of these patients. Renal failure was reversible on cessation of both amphotericin B and pentamidine, with sufficient recovery to allow reinstitution of intravenous amphotericin B therapy. Until prospective trials are conducted to determine the true incidence of this severe drug interaction, caution should be used when these medications are given concomitantly.

TABLE 1. Summary results of renal function in patients receiving simultaneous therapy with amphotericin B and anti-*P. carinii* drugs

Treatment <sup>a</sup> and patient no.	Total amphotericin B (mg)	Days of treatment	Creatinine (mmol/liter)		Days to recovery
			Baseline	Peak	
i.v./i.m. pentamidine					
1	1,415	3	159	398	23
2	455	6	212	398	9
3	16	12	177	486	15
4	121	14	97	265	17
i.v./p.o. TMP-SMX					
5	1,680	15	168	203	NA <sup>b</sup>
6	2,080	15	80	97	NA
7	2,060	14	80	88	NA
Inhaled pentamidine					
8	2,021	30	115	115	NA
9	2,000	21	44	124	NA

<sup>a</sup> i.v., Intravenous; i.m., intramuscular; p.o., peroral; TMP-SMX, trimethoprim-sulfamethoxazole.

<sup>b</sup> NA, Not applicable.

LITERATURE CITED

- Butler, W. T., J. E. Bennett, D. W. Alling, P. T. Wertlake, J. P. Utz, and G. J. Hill. 1964. Nephrotoxicity of amphotericin B: early and late effects in 81 patients. *Ann. Intern. Med.* 61:175-187.
- Conte, J. E., R. A. Upton, and E. T. Lin. 1987. Pentamidine pharmacokinetics in patients with AIDS with impaired renal function. *J. Infect. Dis.* 156:885-890.
- Conte, J. E., Jr., H. Hollander, and J. A. Golden. 1987. Inhaled

- or reduced-dose intravenous pentamidine for *Pneumocystis carinii* pneumonia. *Ann. Intern. Med.* **107**:495-498.
4. Porter, G. A., and W. M. Bennett. 1981. Nephrotoxic acute renal failure due to common drugs. *Am. J. Physiol.* **241**:F1-F8.
  5. Sacks, P., and S. K. Fellner. 1987. Recurrent reversible acute renal failure from amphotericin. *Arch. Intern. Med.* **147**:593-595.
  6. Sands, M., M. A. Kron, and R. B. Brown. 1985. Pentamidine: a review. *Rev. Infect. Dis.* **7**:625-634.
  7. Sattler, F. R., R. Cowan, D. M. Nielsen, and J. Ruskin. 1988. Trimethoprim-sulfamethoxazole compared with pentamidine for treatment of *Pneumocystis carinii* pneumonia in the acquired immunodeficiency syndrome. *Ann. Intern. Med.* **109**:280-287.
  8. Western, K. A., D. R. Perera, and M. G. Schultz. 1970. Pentamidine isethionate in the treatment of *Pneumocystis carinii* pneumonia. *Ann. Intern. Med.* **73**:695-702.
  9. Wharton, J. M., D. L. Coleman, C. B. Wofsy, M. Luce, W. Blumenfeld, W. K. Hadley, L. Ingram-Drake, P. A. Volberding, and P. C. Hopewell. 1986. Trimethoprim-sulfamethoxazole or pentamidine for *Pneumocystis carinii* pneumonia in the acquired immunodeficiency syndrome. *Ann. Intern. Med.* **105**:37-44.