

The survivors of gastroschisis

Brian W Davies, Mark D Stringer

Abstract

Aims—To assess the long term morbidity and quality of life in survivors of gastroschisis.

Design—All babies born with gastroschisis between 1972 and 1984 and who survived more than one year were identified. Those who could be traced were questioned about their general health, growth, abdominal symptoms, cosmetic concerns, education, employment, and fertility.

Results—Of the 35 patients, two have died, seven could not be traced, and three declined to be interviewed. Twenty three subjects (70% of survivors) with a median age of 16 years (range 12–23 years) responded. Twenty two (96%) were in good health and overall growth was within normal limits. Eight subjects (35%) have had further surgery related to gastroschisis, including two for adhesive small bowel obstruction and three for scar complications. In 13 (57%), absence of an umbilicus caused distress during childhood.

Conclusion—Most gastroschisis survivors can eventually expect normal growth and good health. Adhesive bowel obstruction is an uncommon, but potentially late, complication. The umbilicus should be conserved during gastroschisis repair.

(*Arch Dis Child* 1997;77:158–160)

Keywords: abdominal wall defects; gastroschisis

Gastroschisis is due to a congenital anterior abdominal wall defect usually to the right of the umbilicus which results in the evisceration of abdominal contents. The incidence of the condition appears to be increasing.¹ During the past four decades, advances in neonatal care, parenteral nutrition, and surgical materials and technique have improved the outlook for gastroschisis to the extent that 90% of affected babies now survive.² The abnormal character of the bowel at birth and the prolonged initial ileus might be expected to predispose to future bowel obstruction, malabsorption, abnormal bowel habit, or chronic abdominal pain. Previous outcome studies have been limited by small numbers of patients,^{3–7} follow up for mean periods of less than 10 years,^{8–9} or by analysis of data concentrating on survival and reoperation.¹⁰ Few studies have attempted to trace adult survivors and many have confused the issue by analysing all congenital anterior abdominal wall defects and therefore including the very different condition of exomphalos.^{5–7 10 11} The aim of this study was to assess the long term outcome

of an early cohort of patients operated on for gastroschisis in a regional neonatal surgical unit.

Subjects and methods

All children with gastroschisis referred to a regional neonatal surgical unit between 1972 and 1984 inclusive, and who survived for more than one year, were included in the study. Case notes were retrieved and reviewed. Attempts were made to trace each subject by contacting their local paediatrician, general practitioner, and local family health authority and they were then sent a written invitation to be interviewed by telephone. All interviews were conducted in a standard, structured fashion by a single person (BWD). Subjects were questioned on their general health and fitness, height and weight, presence of abdominal symptoms, aspects of abdominal wall cosmesis, and education and employment. Birth weights were replotted on modern nine centile charts to allow comparison with current weight and height.^{12 13} The patient's height was compared with their parents' to see if their adult height potential had been achieved: for boys, sum of parents' height (cm), divided by two, plus seven (range \pm 10 cm); for girls sum of parents' height (cm), divided by two, minus seven (range \pm 8.5 cm). Deaths were investigated with the help of the Office for National Statistics.

Results

Thirty five children were treated for gastroschisis between 1972 and 1984, and survived for more than one year. Two patients died subsequently; one was healthy and died after an accident at the age of 2 years, and the cause of death in the other is unknown. Seven children could not be traced; one had been adopted in the first year of life and six had moved out of the area with no record of their forwarding address. Three subjects declined to be interviewed. Consequently, data on 23 (70%) survivors with a median age of 16 years (range 12–23 years) were available for analysis. These 23 patients are comparable with the group as a whole, although their initial hospital stay tended to be less complicated (table 1).

GENERAL HEALTH

All but one of the subjects (96%) described their general health and fitness as good or excellent. Five subjects have relatively minor ailments (one each with eczema, asthma, peptic ulcer disease, chronic diarrhoea, and gynaecological symptoms). Only one individual considered herself in poor health which, after investigation, was found to be due to chronic anaemia secondary to menorrhagia.

Department of
Paediatric Surgery,
United Leeds Teaching
Hospitals NHS Trust
and St James's and
Seacroft University
Hospitals NHS Trust,
Leeds

B W Davies
M D Stringer

Correspondence to:
Mr M D Stringer,
Department of Paediatric
Surgery, Clarendon Wing,
Leeds General Infirmary,
Leeds LS2 9NS.

Accepted 13 May 1997

Table 1 Characteristics of study group compared with those who were unavailable for interview

	Studied (n=23)	Not studied (n=10)
Sex (M/F)	8/15	7/3
Mean birth weight (g)*	2510	2590
Weight < 2nd centile (%)*	11 (52)	3 (33)
Mean (range) gestation (weeks)†	39 (36–41)	39 (35–40)
Primary closure (%)	20 (87)	7 (70)
Intestinal atresia (%)	2 (9)	1 (10)
Further laparotomy during neonatal stay (%)	2 (9)	2 (20)
Discharged home < 6 weeks (%)	15 (65)	6 (60)
Discharged home > 10 weeks (%)	3 (13)	3 (30)

* Birth weight available for 31 patients.

† Gestation available for 29 patients.

Table 2 Further surgical procedures in 23 gastroschisis survivors (20 operations in 16 patients)

Related to gastroschisis	Age (years)		Unrelated to gastroschisis	No
	No			
Laparotomy for adhesion obstruction	3*	9, 13	Tonsillectomy +/- adenoidectomy	4
Laparoscopy for acute abdominal pain	1	12	Insertion of grommets	1
Ventral hernia repair	1	7	Eye surgery	1
Inguinal exploration (impalpable testis)	1	4	Circumcision	1
Anal stretch	1	2	Manipulation of fractured forearm	1
Scar revision	2	18, 21	Orthodontic	1
			Repair of perforated trachea	1
			Termination of pregnancy	1

* One patient had two laparotomies for adhesive intestinal obstruction seven days apart.

GROWTH

All subjects have shown good growth (fig 1). In contrast with birth weight distributions, none are below the third centile for weight and only one is below this standard for height. In comparison with midparental height, 13 (68%) are within the target centile range (that is, have achieved or are set to achieve their height range, as determined by parental heights), four (21%) are taller and two (11%) are shorter. In four cases, data on parental height were not available.

FURTHER SURGERY AND COSMETIC CONCERNS

Sixteen (70%) subjects have undergone further surgery which was related to gastroschisis in eight cases (table 2). Two children have had operations for adhesive intestinal obstruction at 9 and 13 years of age, both of whom had undergone uncomplicated primary gastroschisis repair. One 12 year old girl underwent a laparoscopy for undiagnosed abdominal pain by a local general surgeon. No pathology was identified, minimal adhesions were noted, and she has subsequently remained well.

All patients in this cohort were left without an umbilicus after gastroschisis repair. Thirteen (57%) admitted that this had been distressing during childhood. Both boys and girls had been affected and cited instances of being teased at school when participating in sporting activities. Fortunately, 15 (65%) no longer found this upsetting. The presence of an abdominal scar had caused less concern and only four (17%) individuals were dissatisfied by the appearance; two have had revisional surgery as adults both for wound discomfort and cosmetic reasons, and one adolescent is awaiting scar revision.

ABDOMINAL SYMPTOMS

Six (26%) subjects admitted to mild, self limiting episodes of abdominal pain which did not interfere with their lifestyle. One girl suffers

from more severe abdominal pain and has had treatment for peptic duodenal ulceration and intra-abdominal adhesions. There were no reports of vomiting, and only one of regular indigestion.

Nineteen (83%) subjects have normal bowel function, two have a tendency to mild constipation, and one boy, who had gastroschisis complicated by small bowel atresia, suffers from chronic diarrhoea.

SCHOOLING AND EMPLOYMENT

Twelve children are still at school, but all except one of the remaining older subjects have not progressed to higher education. Five of these are in full time employment, one in part time employment, and three are unemployed. The woman with chronic anaemia is not working due to ill health.

SOCIAL AND REPRODUCTIVE

Twenty subjects still live in their family home, while three are married or cohabiting. Two women have had a total of three pregnancies resulting in one healthy baby, one miscarriage, and one termination of pregnancy. Thirteen were aware that gastroschisis was not considered an inheritable condition, nine did not know, and one thought that offspring were at risk.

Discussion

This study documents the longest recorded outcome of a cohort of survivors of gastroschisis. All but one were in good health with no significant limitation of lifestyle and one woman had managed a successful pregnancy. Despite the frequent presence of intrauterine growth retardation, the survivors of uncomplicated gastroschisis eventually achieve relatively normal growth. While this observation has been disputed,¹⁰ more detailed studies have shown that catch up growth occurs throughout childhood, mostly within the first five years, leading to normal centile ranks in older children.⁶⁻⁹ Children with gastroschisis complicated by intestinal atresia fare less well,⁸ and both of our subjects with an atresia were below the 25th centile for weight.

Late gastroschisis related mortality beyond infancy is rare and often due to unrelated pathology.⁸⁻¹⁰ In uncomplicated gastroschisis, late morbidity is uncommon and any further related surgery is usually as a result of adhesive intestinal obstruction, a ventral hernia, or undescended testes. It has been suggested that the matted bowel in gastroschisis is at less risk of subsequent adhesive intestinal obstruction.¹⁴ This comment, however, was based on a six year follow up of only six children. Two (9%) of our subjects required laparotomy for relief of adhesive bowel obstruction at nine and 13 years after their gastroschisis repair; late adhesive obstruction has not been previously reported. The severity of adhesion formation after gastroschisis repair appears to be very variable, but mechanical bowel obstruction clearly represents a small but significant long term risk. Ventral hernia repair has been necessary in 10% or more of survivors in some

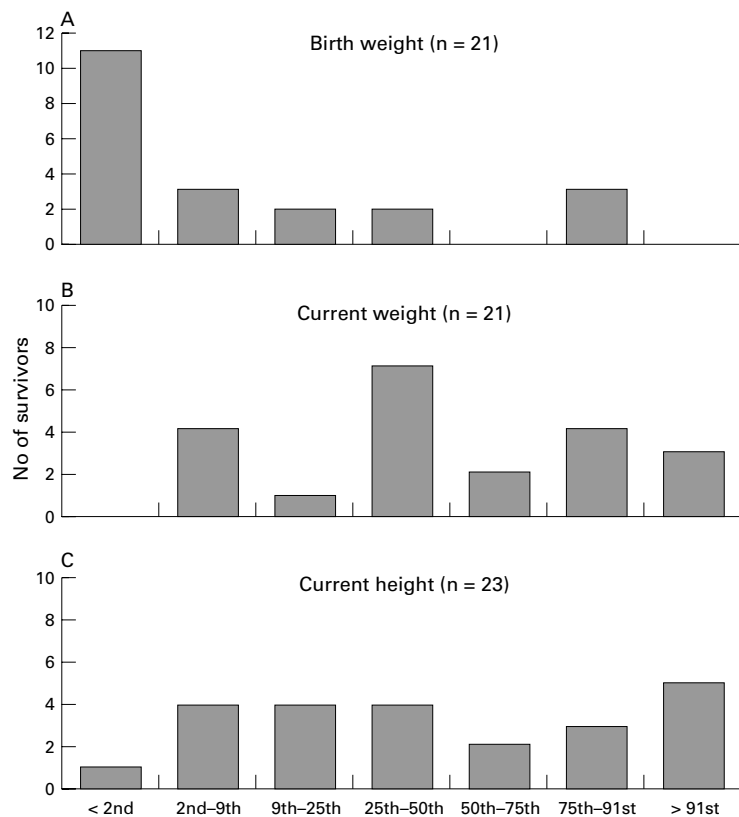


Figure 1 Growth of survivors of gastroschisis.

longer term studies^{7 8 15} but, with the judicious use of staged silo repair and meticulous fascial closure, this should now be a rare complication.

Chronic recurrent abdominal pain was reported by a quarter of our subjects. Shorter term follow up studies have recorded a higher prevalence of this symptom,^{6 9} which may indicate that either spontaneous improvement or adaptation occurs with age. Investigations in such patients have generally found no pathology,^{6 8} but pathological acid gastro-oesophageal reflux was present in four of 13 symptomatic patients in one study.⁹ Swartz *et al* found that chronic abdominal complaints in general were confined to those who had undergone intestinal resection as well as gastroschisis repair.⁸ To our knowledge, acute appendicitis has never been described in a patient with a previously repaired gastroschisis, which is fortunate since the gastroschisis bowel is typically non-rotated and thus the appendix may well be abnormally sited. The neonatal appendix in gastroschisis is typically short and

wide which might protect against acute appendicitis, but it is unknown whether the appendix subsequently remains in this state.

Absence of an umbilicus caused distress to more than half of our subjects and this was most acute in adolescents. Lindham described similar results in Swedish patients,⁶ but fewer North American or Austrian children were affected, which may reflect study methodology or cultural differences.^{9 10} Current surgical methods should aim to conserve the umbilicus whenever possible.¹⁶

Gastroschisis is frequently detected antenatally and many prospective parents now receive prenatal counselling. Early outcome and prognostic factors are well established. This study shows that most babies surviving infancy after repair of gastroschisis can expect to become healthy adults.

We wish to thank Mr JM Beck and Mr DFM Thomas for allowing us to study their patients and we are grateful to our regional paediatric colleagues, general practitioners, and Mr DCG Crabbe for information which enabled us to trace some of these patients.

- 1 Tan KH, Kilby MD, Whittle MJ, Beattie BR, Booth IW, Botting BJ. Congenital anterior abdominal wall defects in England and Wales 1987-93: retrospective analysis of OPCS data. *BMJ* 1996;313:903-6.
- 2 Stringer MD, Brereton RJ, Wright VM. Controversies in the management of gastroschisis: a study of 40 patients. *Arch Dis Child* 1991;66:34-6.
- 3 Mahour GH, Lee FA. Gastroschisis: mortalities, and growth of survivors. *Am Surg* 1974;40:425-7.
- 4 Cywes S, Davies MRQ. Complications and follow-up of gastroschisis. *S Afr Med J* 1979;55:499-501.
- 5 Berseth CL, Malachowski N, Cohn RB, Sunshine P. Longitudinal growth and late morbidity of survivors of gastroschisis and omphalocele. *J Pediatr Gastroenterol Nutr* 1982;1:375-9.
- 6 Lindham S. Long-term results in children with omphalocele and gastroschisis—a follow-up study. *Z Kinderchir* 1984;39:164-7.
- 7 Larsson LT, Kullendorff CM. Late surgical problems in children born with abdominal wall defects. *Annales Chirurgiae et Gynaecologiae* 1990;79:23-5.
- 8 Swartz KR, Harrison MW, Campbell JR, Campbell TJ. Long-term follow-up of patients with gastroschisis. *Am J Surg* 1986;151:546-9.
- 9 Fasching G, Huber A, Uray E, Sorantin E, Mayr J. Late follow-up in patients with gastroschisis. *Pediatr Surg Int* 1996;11:103-6.
- 10 Tunell WP, Puffinbarger NK, Tuggle DW, Taylor DV, Mantor PC. Abdominal wall defects in infants. Survival and implications for adult life. *Ann Surg* 1995;221:525-30.
- 11 Clausner A, Lukowitz A, Rump K, Berger S, Wurfel A. Treatment of congenital abdominal wall defects—a 25-year review of 132 patients. *Pediatr Surg Int* 1996;11:76-81.
- 12 Freeman JV, Cole TJ, Chinn S, Jones PRM, White EM, Preece MA. Cross sectional stature and weight reference curves for the UK, 1990. *Arch Dis Child* 1995;73:17-24.
- 13 Cole TJ. Do growth charts need a facelift? *BMJ* 1994;308:641-2.
- 14 Touloukian RJ, Spackman TJ. Gastrointestinal function and radiographic appearance following gastroschisis repair. *J Pediatr Surg* 1971;6:427-34.
- 15 Klein P, Hummer HP, Wellert S, Faber T. Short-term and long-term problems after duraplastic enlargement of anterior abdominal wall. *Eur J Pediatr Surg* 1991;1:88-91.
- 16 Bowen J, Wilcox D, Bianchi A, Bruce J, Dickson A. The umbilicus in gastroschisis: aesthetic considerations. *Pediatr Surg Int* 1996;11:237-9.