

CURRENT TOPIC

Imaging in scoliosis

Neville Wright

Recent advances in imaging technology have resulted in a better understanding of the complexities of the scoliotic spine. Plain radiography remains the usual method of measuring curvature progression, but use of multiplanar imaging techniques, such as computed tomography and magnetic resonance, have resulted in a greater understanding of the three dimensional nature of scoliosis and enabled underlying abnormalities to be detected with confidence.

Clinical evaluation

Despite the advances in imaging capabilities, the initial detection of scoliosis relies on clinical skills. The prevalence of scoliosis is quoted as approximately 1–3% for curves of greater than 10°.¹ A few are detected through school screening, some will be found incidentally when imaging is performed for other reasons, such as during chest or abdominal radiography, and some will be identified because of a high degree of clinical suspicion in a child with known associated anomalies, such as VATER (vertebral, anorectal, tracheal, oesophageal, renal) complex. It is also important to remember that many neurological and neuromuscular conditions, such as cerebral palsy and spinal muscular atrophy, will produce scoliosis.

Scoliosis is usually described in terms of the side of the convexity, and has been traditionally divided by age at presentation into four main groups: congenital, infantile (< 3 years old), juvenile (3–10 years), and adolescent (> 10 years). This classification forms a general framework for the subsequent imaging assessment of the child. Careful clinical evaluation, especially physical and neurological examination, plays a vital role in deciding how and when to image. Although 80% of scoliosis is idiopathic, there are clinical features that suggest an alternative diagnosis: a child with an abnormal neurological examination, a painful scoliosis, or other clinical signs of dysraphism will require more than plain radiographs (fig 1). Neck pain and headache, especially with exertion, and neurological findings such as weakness, pes cavus, and ataxia are also indications for further imaging.² Back pain should be investigated promptly to exclude inflammatory processes, such as discitis, and the occasional primary bone neoplasm, such as an osteoid osteoma. Leg length discrepancy is a potent cause for postural scoliosis and might in itself require accurate measurement with computed tomography (CT) “scanograms”. A rapidly

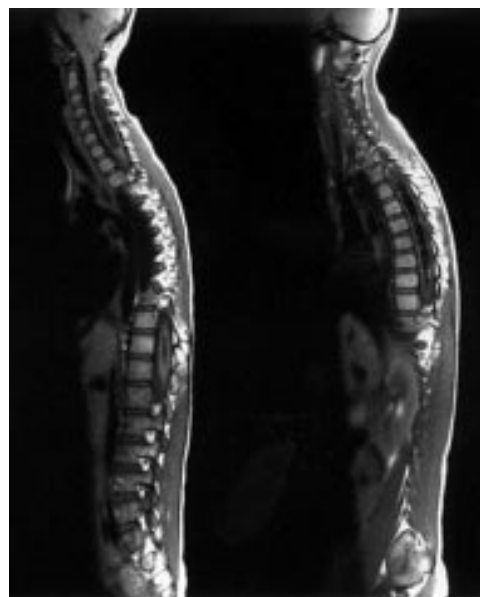


Figure 1 Selected sagittal T1 weighted magnetic resonance images of the whole spine in a girl with a minor scoliosis and asymmetrical abdominal reflexes showing a syrinx of most of the cord and cerebellar tonsillar herniation, consistent with a Chiari 1 malformation.

progressing curve on follow up suggests the presence of an underlying abnormality such as a syringomyelia.

Therefore, the place of radiology in scoliosis management is superficially straightforward; it is to confirm the diagnosis, identify any underlying cause, and monitor the degree of curvature.

Plain radiography

Plain radiography has three roles. First, it will confirm the diagnosis and occasionally suggest aetiology, such as a hemivertebra. Second, the subsequent monitoring of the child depends largely upon the plain film. This is because evaluation of the severity of the scoliosis, and particularly the degree of progression over time, cannot be assessed accurately using clinical methods alone. Third, the plain film provides a method of assessing skeletal maturity.

In practical terms, this means that most children with a scoliosis require regular review combined with radiographic assessment and measurement of the angle of curvature (Cobb angle). The degree of vertebral rotation, part of the three dimensional concept, can also be measured reliably to within $\pm 5^\circ$ using a torsion (Pedriolle) meter.³ Close monitoring of the

Royal Liverpool
Children's Hospital
NHS Trust, Alder Hey,
Eaton Road, Liverpool
L12 2AP, UK
N Wright

Correspondence to:
Dr Wright

scoliosis is required when the greatest growth of the spine occurs, around puberty and early adolescence. Lateral bending films remain an efficient, quick, and dynamic method of assessing the postural nature of any secondary compensatory curves, but are usually limited to the preoperative assessment.

There are obvious concerns that repeated radiographs result in an excessive radiation burden, especially to the developing breast tissue in girls. Nash *et al* estimated that 22 radiographic examinations are performed in the course of scoliosis management.⁴ When properly performed, postero-anterior views of the whole spine using rare earth screens, a method of increasing the sensitivity of plain x rays, can minimise the radiation dose involved.⁵ Using this technique, it has been estimated that the increased relative risk of breast carcinogenesis in young women receiving routine scoliosis radiography is 0.22%. This equates to the induction of two breast cancers each year for each million patients receiving serial diagnostic scoliosis radiography.⁶ Now that digital (electronic) radiography is becoming more readily available there is the potential to reduce the radiation dose further.⁷ Digital radiography reduces the number of repeat films and also permits the use of image manipulation techniques, such as edge enhancement, which aid film interpretation. This produces better definition of the vertebral endplates, essential for measuring the Cobb angle accurately. The interpretation of digital images, however, requires a period of familiarisation both by clinicians and radiologists.

Skeletal maturity is an important factor in determining the likelihood of curvature progression and this is usually measured by the ossification of the iliac apophysis (Risser sign), a feature that can usually be seen adequately on plain radiographs. Increasing degrees of ossification result in decreasing likelihood of curvature progression.¹

Magnetic resonance imaging

Magnetic resonance imaging (MRI) has had a revolutionary impact on imaging the neural axis. Its ability to produce detailed images with excellent tissue contrast in any plane, without the use of ionising radiation, make it an attractive method of assessing the scoliotic spine. Unfortunately, the nature of scoliosis, with different areas of the spine moving in and out of the plane of imaging, means that interpretation might be difficult. In addition, the examination is time consuming and once surgery has been performed the presence of metalwork can make further studies with MRI suboptimal, primarily because of the magnetic susceptibility artefacts that are generated from the internal fixation. Young children require sedation and occasionally general anaesthesia with MRI compatible equipment. Despite this, MRI is advocated as the primary imaging modality in the assessment of scoliosis after plain radiography,⁸ particularly in the infantile and juvenile forms, where the incidence of spinal cord abnormalities is higher.⁹⁻¹⁰ MRI is especially good at identifying hydromyelia, syringomyelia, intramedullary tumours, and dysraphic abnor-

Key messages

- Careful clinical evaluation, including a full physical and neurological examination, is essential
- Subtle signs should not be ignored
- The most common form is seen in girls over 10 years, is idiopathic, thoracic, or thoraco-lumbar and convex to the right, with normal physical and neurological examination
- Plain radiography remains the primary imaging modality for the initial diagnosis and follow up to assess curve progression
- Any child not conforming to the typical form of scoliosis, either by age criteria, history, or clinical examination requires further investigations with magnetic resonance imaging (MRI)
- Ideally, any child in whom surgery is contemplated should have MRI
- The spine should be imaged from the craniocervical junction to the sacrum

Painful scoliosis

- A painful scoliosis always requires thorough investigation
- A bone scan is often helpful in young children who cannot adequately localise the pain
- Targeted cross sectional imaging should be performed if a focal abnormality is identified

Congenital abnormalities

- MRI should be performed to assess dysraphism and other congenital abnormalities
- Congenital bony abnormalities of the spine, such as hemivertebrae and butterfly vertebrae, might benefit from localised computed tomography to define bony detail

malities such as tethered cords, diastematomyelia, or lipomas. In this respect, MRI has replaced CT and computed myelography. The importance of careful clinical examination cannot be underestimated. Subtle findings should be thoroughly investigated with MRI and some authors consider atypical curves as positive neurological findings.¹¹ The role of MRI in adolescent scoliosis is less clear cut. Those with atypical curves (for example, left thoracic) or abnormal neurological findings will benefit from MRI.¹²⁻¹³ However, most of the children seen with scoliosis will have the idiopathic adolescent type. The typical patient (90% girls) will have a normal physical and neurological examination (including abdominal reflexes) and a right thoracic or thoracolumbar or double major curve. Some authors have reported a relatively high incidence (8-15%) of abnormal MRI studies in presumed adolescent idiopathic scoliosis.¹²⁻¹⁴ Others have found few or no abnormalities

(0–4.2%), and have questioned the need for MRI if the child has a normal neurological examination, as long as a high index of suspicion is maintained.^{15,16} The main abnormality looked for is syringomyelia. This is because there is an increased risk of an untreated syringomyelia contributing to iatrogenic paraplegia after surgery, although its incidence is unknown.¹⁷ Once a decision has been reached to correct a scoliosis surgically, some centres now routinely perform MRI preoperatively. Images should be obtained of the whole spine and, in particular, should include the craniocervical junction. Reconstruction of images can be used to “straighten” the spine to make viewing easier, although acquiring data in a suitable fashion for reconstruction might be unduly time consuming. Experienced radiologists can often negotiate the curves within their own three dimensional mind set!

It is a common misconception that scoliosis is simply a lateral deviation of the spine. Rotation of the vertebral bodies involved also plays a crucial role. Not only are the vertebrae rotated with respect to each other (axial intervertebral rotation), but there is also a degree of intrinsic rotation (axial intravertebral rotation or mechanical torsion). This can be measured accurately by CT,¹⁸ although this obviously exposes the child to further radiation. More recently, three dimensional MRI has been used to assess the relative degrees that the intravertebral and intervertebral components contribute to idiopathic scoliosis.¹⁹ It has been suggested that in those patients in whom a large proportion of the scoliosis is the result of intravertebral rotation (up to half of those in the small group studied), the results of standard derotational spinal surgery will be suboptimal. Therefore, it appears that MRI has an expanding role in identifying that subgroup of patients with idiopathic scoliosis in whom derotational surgery will be of little benefit.

Computed tomography

Children with underlying congenital skeletal malformations and segmentation abnormalities, such as butterfly or hemivertebra, or diastematomyelia, require a slightly different imaging approach. MRI will provide excellent detail about the nature of the spinal canal and cord, but detail of the bony anatomy can be evaluated further with localised CT and three dimensional reconstructed images through the area of interest. However, in practice, this is not often required because plain radiography suffices.

There is a role for CT in the postoperative patient who cannot be imaged appropriately in the MRI environment. Localised CT and occasionally CT myelography might help in identifying postoperative complications, such as radiculopathy related to screw malplacement or migration. Considerable artefact is common because of the metalwork present but, nonetheless, images might be interpretable.

Nuclear medicine

Nuclear medicine has a limited role in the routine evaluation of scoliosis. The isotope bone

scan (^{99m}Tc-methylene diphosphonate) can be used in the initial evaluation of a child to localise focal bony abnormalities, such as infection or neoplasia, but is more often used in the postoperative spine to identify complications. Abnormal sites of activity in suspected postoperative infection should be viewed with caution, and require further imaging, possibly with labelled white cell scanning to differentiate normal postoperative bone activity from infection. This is important because infection related to surgery might ultimately necessitate removal of the fixation device.

Conclusion

The appropriate management of scoliosis relies on the vigilance of clinicians: first to identify the presence of a scoliosis, and secondly to ensure an appropriate clinical examination is performed to identify those children who require a more vigorous imaging strategy. Plain radiography remains the initial imaging modality of choice followed by MRI in most cases. MRI in particular has advanced the three dimensional understanding of the scoliotic spine and enabled underlying abnormalities to be identified with more certainty and clarity.

- Lonstein JE. Natural history and school screening for scoliosis. *Orthop Clin North Am* 1988;19:227–37.
- Schwend RM, Hennrikus W, Hall JE, Emans JB. Childhood scoliosis: clinical indications for magnetic resonance imaging. *J Bone Joint Surg Am* 1995;77:46–53.
- Barsanti CM, deBari A, Covino BM. The torsion meter: a critical review. *J Pediatr Orthop* 1990;10:527–31.
- Nash CL, Gregg EC, Brown RH, Pillai K. Risks of exposure to x-rays in patients undergoing long-term treatment for scoliosis. *J Bone Joint Surg Am* 1979;61:371–4.
- Fearon T, Vucich JJ, Butler P, et al. Scoliosis examinations: organ dose and image quality with rare-earth screen-film systems. *Am J Roentgenol* 1988;150:359–62.
- Dutkowsky JP, Shearer D, Schepps B, Orton C, Scola F. Radiation exposure to patients receiving routine scoliosis radiography measured at depth in an anthropomorphic phantom. *J Pediatr Orthop* 1990;10:532–4.
- Kling TF, Cohen MJ, Lindseth RE, De Rosa GP. Digital radiography can reduce scoliosis x-ray exposure. *Spine* 1990;15:880–5.
- Nokes SR, Murtagh FR, Jones III JD, et al. Childhood scoliosis: MR imaging. *Radiology* 1987;164:791–7.
- Tomlinson RJ, Wolfe MW, Nadall JM, Bennett JT, MacEwen GD. Syringomyelia and developmental scoliosis. *J Pediatr Orthop* 1994;14:580–5.
- Lewonowski K, King JD, Nelson MD. Routine use of magnetic resonance imaging in idiopathic scoliosis patients less than eleven years of age. *Spine* 1992;17:S109–14.
- Charry O, Koop S, Winter R, Lonstein J, Denis F, Bailey W. Syringomyelia and scoliosis: a review of twenty-five pediatric patients. *J Pediatr Orthop* 1994;14:309–17.
- Winter RB, Lonstein JE, Denis F, Koop SE. Prevalence of spinal canal or cord abnormalities in idiopathic, congenital, and neuromuscular scoliosis. *Orthopedic Transcripts* 1992; 16:135.
- Barnes PD, Brody JD, Jaramillo D, Akbar JU, Emans JB. Atypical idiopathic scoliosis: MR imaging evaluation. *Radiology* 1993;186:247–53.
- Samuelsson L, Lindell D, Kogler H. Spinal cord and brainstem anomalies in scoliosis. MR screening of 26 cases. *Acta Orthop Scand* 1991;62:403–6.
- O'Brien MF, Lenke LG, Bridwell KH, Blanke K. Preoperative spinal canal investigation in large adolescent idiopathic scoliosis curves (70 to 140°): is it warranted? *J Pediatr Orthop* 1994;14:397.
- Shen W-J, McDowell GS, Burke SW, Levine DB, Chutorian M. Routine preoperative MRI and SEP studies in adolescent idiopathic scoliosis. *J Pediatr Orthop* 1996;16: 350–3.
- Noordeen MHH, Taylor BA, Edgar MA. Syringomyelia: a potential risk factor in scoliosis surgery. *Spine* 1994;19: 1406–9.
- Krismser M, Sterzinger W, Haid C, Frischhut B, Bauer R. Axial rotation measurements of scoliotic vertebrae by means of computed tomography scans. *Spine* 1996;21:576–81.
- Birchall D, Hughes DG, Robinson L, Williamson JB. Analysis of intravertebral axial rotation in idiopathic scoliosis using 3D MRI [abstract]. *Br J Radiol* 1998;S71:19.