

Scrotal temperature is increased in disposable plastic lined nappies

C-J Partsch, M Aukamp, W G Sippell

Abstract

Objectives—Male reproductive health has deteriorated in recent decades. It is proposed that increased testicular temperature in early childhood, due to the use of modern disposable plastic lined nappies (diapers), could be an important factor contributing to this decline.

Study design—Scrotal skin temperature was measured non-invasively in 48 healthy children aged 0–55 months (three age groups) for two 24 hour periods in randomised order (either cotton or disposable plastic lined nappies) using a portable, miniature recorder.

Results—Mean 24 hour scrotal temperature (2880 measurements) was significantly higher in all age groups during the periods of plastic nappy use than with cotton nappies ($p < 0.001$). The rectoscrotal temperature difference was significantly higher with cotton than with plastic nappy use ($p < 0.01$).

Conclusions—Scrotal hypothermia is an important factor for normal spermatogenesis. This study shows that scrotal temperature, which closely reflects testicular temperature, is increased in boys wearing disposable plastic lined nappies. The physiological testicular cooling mechanism is blunted and often completely abolished during plastic nappy use. The present results establish the basis for further research on the impact of increased testicular temperature in infancy on later spermatogenesis.

(Arch Dis Child 2000;83:364–368)

Keywords: testicular temperature; testicular function; spermatogenesis; cryptorchidism; male infertility

It has been suggested that male reproductive health has deteriorated during the last two to three decades.¹ First, the incidence of testicular cancer has increased in several countries.^{2–6} Furthermore, several studies have shown that the quality of human semen has declined.^{7–11} To date, the causes for these trends remain unclear, although several factors have been implicated as reasons for male reproductive problems. Among these are environmental factors—for example, xenoestrogens, chemical hormone disruptors, changes in lifestyle (tight fitting underwear, more sedentary activities), and exposure to heat (sauna, occupational). Until now, the effect of increased testicular temperature has been investigated mainly in adults with respect to type of underwear,¹² occupational heat exposure,^{13–14} sauna bath,¹⁵

and artificial cryptorchidism as a means of male contraception.^{16–17} We propose a new hypothesis: exposure to increased testicular temperature for prolonged duration during early childhood as a result of the use of modern disposable plastic lined nappies could be an important factor in the decline in semen quality and the increasing incidence of testicular cancer in adult age. The obvious first step in investigating this hypothesis would be to characterise the temperature milieu in disposable nappies compared with that in traditional cotton nappies. We therefore prospectively studied 48 healthy, male, nappy wearing children by closely monitoring scrotal skin temperature for 24 hours using modern non-invasive thermoprobes.

Probands and methods

PROBANDS

Three groups of healthy male children were studied. Group I, 14 term and preterm neonates aged 0–4 weeks (five preterms with gestational age 28–36 weeks were studied between postnatal age 14 and 85 days); group II, 22 infants aged 1–12 months; and group III, 12 toddlers aged 13–55 months. After obtaining informed written consent from the parents or guardians, probands were studied prospectively over two 24 hour periods. The study was approved by the ethics committees of the Medical Faculty of the University of Kiel.

METHODS

Scrotal skin temperature was recorded using the miniaturised portable digital data recorder Thermoport (Armin Gräwe Funkelektronik, Münster, Germany). The Thermoport device measures $11 \times 7 \times 3.3$ cm. Two temperature probes (YSI, Model 409BD, Yellow Springs Instrument Co Inc, Yellow Springs, Ohio, USA) with a diameter of 9 mm were connected to the recording device. The frequency of temperature readings was set to once every 30 seconds, resulting in 2880 readings per 24 hours. Data were stored in the Thermoport, then downloaded and transferred to statistics and graphics programs.

The accuracy of the temperature measurements was assessed and officially certified by the German Bureau of Standards. It was shown to be 0.09°C (SD 0.054°C) over a temperature range of 29.89 to 43.01°C ($n = 28$).

The subjects were studied for two 24 hour periods in randomised order: one period using cotton nappies and the other using modern disposable plastic lined nappies (Pampers, Procter & Gamble, Schwalbach, Germany). The temperature probes were attached to the

Division of Paediatric Endocrinology, Department of Paediatrics, Christian-Albrechts-University of Kiel, Schwaneuweg 20, D-24105 Kiel, Germany
C-J Partsch
M Aukamp
W G Sippell

Correspondence to:
Professor Sippell
email: sippell@
paediatrics.uni-kiel.de

Accepted 15 May 2000

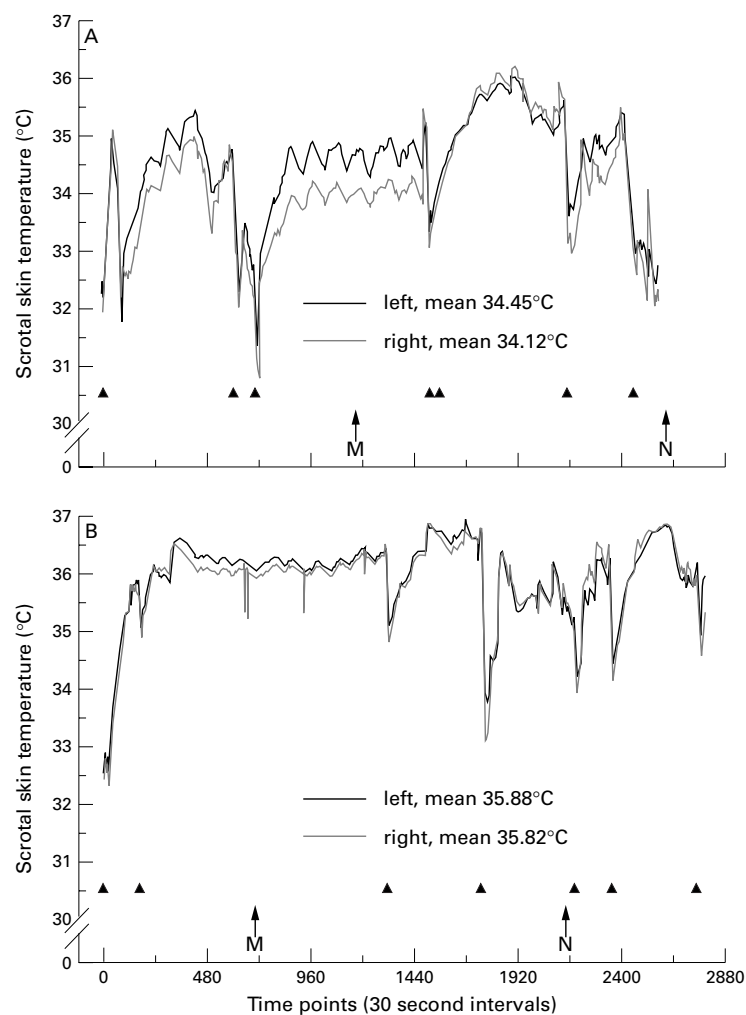


Figure 1 Twenty four hour profiles of scrotal skin temperature (T) of a 4 month old healthy male infant. A: temperature (T) on the right side with use of cotton nappies (maximal T 36.1°C, minimal T 32.9°C, mean T during sleep 35.6°C and during activity 34.2°C, rectoscotal T difference 3.5°C). B: temperature (T) with use of modern disposable plastic lined nappies (maximal T 36.7°C, minimal T 33.9°C, mean T during sleep 36.0°C and during activity 35.6°C, rectoscotal T difference 1.3°C). M and N indicate midnight and noon, respectively. Triangles show episodes of change of nappies.

scrotal skin at the lateral and caudal pole of the testis with thin transparent tape (Tegaderm, 3M Health Care, Borken, Germany). The tape caused no discomfort and did not inhibit free movement. An activity protocol, including all manipulations with the nappies in sleep and awake periods, was filled out by the mothers. The number of nappy changes was calculated for each 24 hour period. Typical 24 hour temperature profiles during either cotton or plastic nappy use are shown in fig 1. Rectal temperature was determined between 0800 and 1200 in each 24 hour period using a calibrated digital thermometer. Temperature measurements were performed within one year excluding the hot summer months (July and August).

The data were used to calculate the mean 24 hour temperature for right and left scrotal sides separately, the mean temperature during activity (waking) and sleep periods, the difference between rectal and mean scrotal temperature, and to define the maximal temperature during each of the profiles. Statistical analysis was performed using Sigmasat 2.0 (SPSS, Erkrath, Germany). Significance between two paired samples was assessed by the Wilcoxon signed rank test and, where appropriate, by the paired t test. Statistical comparisons between the three age groups were done by one way analysis of variance. The Student-Newman-Keuls test was used as posthoc test. The frequency of high ($\geq 37^\circ\text{C}$) v lower ($< 37^\circ\text{C}$) maximal temperatures within the groups was assessed by Fisher's test of exact probability. $p < 0.05$ Was considered significant. Data are given as mean SD.

Results

Mean 24 hour scrotal skin temperature showed significant differences in the periods when cotton nappies were worn compared with those when plastic lined disposable nappies were used (fig 1). Left scrotal skin temperature is shown in table 1. The data of the right side were very similar (NS v left side, data not shown). In all three study groups, scrotal

Table 1 Left side* scrotal skin temperature and rectal temperature in healthy male neonates (group I: age 0 to 4 weeks), infants (group II: age 1 to 12 months), and toddlers (group III: age 13 to 55 months). The results for the right scrotal side were very similar (data not shown, ns for all parameters)

Parameter		Group I (neonates) n = 14	Group II (infants) n = 22	Group III (toddlers) n = 12
Mean scrotal T (°C), left side	cotton (c)	35.7 (0.42) ^{ab}	34.9 (0.61) ^a	34.7 (0.54) ^b
	plastic (p)	36.4 (0.22) ^{‡c}	36.0 (0.36) ^{‡d}	35.7 (0.38) ^{‡c}
	$\Delta p - c$	0.79 (0.45)	1.13 (0.47)	0.95 (0.45)
Mean daytime T (°C), left side	nd		35.1 (0.60)	34.7 (1.08)
	plastic	nd	36.0 (0.54) [‡]	35.8 (0.56)
	$\Delta p - c$	nd	1.10 (0.47)	1.00 (1.36)
Mean sleep T (°C), left side	cotton	nd	35.1 (0.65)	34.7 (1.08)
	plastic	nd	35.8 (0.37) [‡]	35.8 (0.51)
	$\Delta p - c$	nd	1.02 (0.63)	1.00 (0.86)
Rectal T (°C)	cotton	37.0 (0.40)	37.0 (0.37)	37.3 (0.42)
	plastic	37.0 (0.38)	37.0 (0.38)	37.3 (0.42)
Rectal T minus mean scrotal T (°C), left side	cotton	1.47 (0.36) ^{de}	2.13 (0.70) ^d	2.62 (0.82) ^c
	plastic	0.52 (0.37) ^{‡f}	1.01 (0.44) ^{‡f}	1.63 (0.72) ^{‡f}
	$\Delta p - c$	-0.91 (0.29)	-1.11 (0.54)	-1.00 (0.50)
Maximal scrotal T (°C)	cotton	36.8 (0.35)	36.4 (0.41)	36.4 (0.30)
	plastic	37.4 (0.36) [‡]	37.0 (0.36) [‡]	37.2 (0.41) [‡]
Change of nappies per 24 hours (n)	cotton	5.4 (1.2)	5.0 (1.7)	3.6 (2.3)
	plastic	5.6 (1.4)	4.5 (1.2)	3.5 (2.0)

T = temperature, ND = not done, NS = $p < 0.05$.

*The left side was chosen for direct comparability with literature data (table 2), and since this is the side where varicocele occurs.

[†] $p < 0.01$ Cotton v plastic lined nappies.

[‡] $p < 0.001$ Cotton v plastic lined nappies, identical letters mark significant differences between groups (posthoc test: $p < 0.05$).

temperature was consistently and significantly higher during the use of modern disposable nappies compared with cotton nappies. This was seen for both the right and the left side (table 1). The mean difference in scrotal temperature between the two ranged between 0.6 and 1.1°C in the three groups. The highest mean temperatures were seen in the youngest boys wearing plastic nappies. In general, group I showed the highest, and group III the lowest mean scrotal temperatures (table 1). There was no significant difference between right and left mean scrotal temperatures in any age group.

When analysed separately for daytime (wake) and sleep periods, scrotal skin temperature was significantly higher in group II and group III for both periods when disposable nappies were used (table 1; no separate analysis of wake and sleep periods in group I). There was no difference between the two 24 hour periods in the number of nappy changes. Thus, a higher frequency of nappy changes in the periods with cotton nappy use could not be responsible for lower mean 24 hour temperatures during periods of cotton nappy use.

The maximal scrotal skin temperatures recorded over 24 hours were equal or above 37°C in 5, 3, and 0 children using cotton nappies *v* 11, 12, and 7 boys using plastic nappies in groups I, II, and III, respectively ($p < 0.01$ for groups II and III). Mean maximal temperatures within one group were equal or above 37°C in all three groups during the periods of plastic nappy use, but were below 37°C during the cotton nappy periods. This difference was significant ($p < 0.001$ for all groups, table 1).

Rectal temperature was comparable between the two 24 hour periods of the study in all three study groups. When rectal core temperature was simultaneously recorded, the difference between rectal and mean scrotal temperature was consistently and significantly lower ($p < 0.01$ to $p < 0.001$) during plastic nappy use than during cotton nappy use (table 1). Thus, the physiological testicular cooling mechanism was markedly blunted by the insulation properties of modern plastic lined nappies. In four boys, mean 24 hour scrotal skin temperature was similar to rectal temperature during the plastic nappy periods. Taking into consideration the measuring error of 0.2°C for the rectal and 0.1°C for the scrotal temperature measurements, a total of 13 boys did not show any significant rectoscrotal temperature difference during the plastic nappy periods. This was not seen in any subject during the cotton nappy periods. In general, rectoscrotal temperature differences were lowest in the youngest boys and highest in the oldest boys, varying between means of 1.5–2.5°C in the cotton, and 0.5–1.6°C in the plastic nappy periods.

Discussion

The clinical observation of very high scrotal temperatures in feverish baby boys wearing modern disposable plastic lined nappies prompted us to investigate this phenomenon systematically. In the present study, we have shown that scrotal skin temperature is signifi-

cantly increased in healthy young boys wearing plastic lined nappies compared with traditional cotton nappies. Scrotal skin temperature has been shown to reflect testicular temperature reasonably well.^{18–20} In the present study we monitored scrotal skin temperature non-invasively at intervals of 30 seconds over a 24 hour period to obtain a representative and exact quantitative temperature profile. For this purpose we applied two thermoprobes externally to the scrotal skin. The data were recorded by the Thermoport device, developed and first introduced by Jockenhövel *et al.*²¹ This methodology permitted very accurate temperature measurements with minimal discomfort to the children. After the first communication of preliminary data at the Annual Meeting of the German Endocrine Society in March 1999, there has been considerable public interest in this study.²² As modern disposable plastic lined nappies are used by the vast majority of mothers for their infants in Germany, the interest has been widespread. Although there is an increasing number of alternative nappies, these are only used by a small minority of mothers.

The physiological temperature of the adult human testis has been reported as being between 31 and 35°C (table 2). To our knowledge, comparable data in healthy children are not available. One report on cryptorchid boys showed significantly higher testicular temperature on the cryptorchid than on the normally descended testis during operation.²³ Similarly, significantly higher left testicular temperatures have been observed in patients with varicocele than in normal volunteers.²⁴ An extensive review of the available literature (in part: table 2) showed that scrotal temperatures as high as those in infants wearing plastic lined nappies have not been observed before. In fact, the physiological cooling mechanism was blunted in all 48 boys wearing plastic lined, disposable nappies, and was completely abolished in 13 out of 48 (27%).

Even higher scrotal/testicular temperatures can be expected during the not infrequent feverish episodes in male infants and toddlers. In adults, short term testicular temperature elevations by sauna bath (elevation of rectal temperature by 0.93°C), or during acute febrile diseases were shown to suppress spermatogenesis.^{15 16 25 26} Thus, it seems to be possible that a prolonged and continuous elevation of testicular temperature by a mean of 1°C can affect the maturation of the infant testis. An increased testicular temperature and/or an impaired testiculosrotal thermoregulation have deleterious effects on spermatogenesis.^{16 17 20 27} Moreover, mild testicular heating has been demonstrated to be effective as a means of reversible contraception in men.²⁸ A lowering of the rectoscrotal temperature gradient in healthy men by 1°C to 2°C was accompanied by a suppression of spermatogenesis.^{20 27–29} From these and other studies, it can be concluded that an increase of testicular temperature by 1°C and/or a decrease of the rectoscrotal temperature difference by 1 to 2°C is significant for spermatogenesis in men. However, it must be admitted that

Table 2 Scrotal skin temperature and intratesticular temperature of normal men, men with various gonadal pathologies, and boys with cryptorchidism from the literature compared to data from our study (data from left testes, shown as mean (SD)).

Reference	n	Temperature (°C), left side	Patient characteristics	Methods
Zorgniotti, McLeod 1973 ²⁰	35	33.6 (0.6)	nl	Water bath thermometer
	50	34.2 (0.5)	VC	
Kurz, Goldstein 1986 ¹⁹	30	31.4 (1.8)	OB/VC/	Thermistor (intratesticular)
	30	32.2 (1.8)	SCO	surface thermometer (paired data)
Mieusset, et al 1989 ⁴²	64	34.6 (0.5)	nl	Mercury thermometer
Lerchl, et al 1993 ²⁴	6	34.6 (0.7)	nl	Thermoport, 24 hour profile,
	48	35.6 (0.7)	VC	1 minute intervals
Mieusset, et al 1993 ²³	28	33.2 (1.2)	DT	Thermoprobe, intraoperatively
	28	34.4 (0.9)	CT	(paired data, children)
Munkelwitz, Gilbert 1998 ¹²	51	33.8 (0.8)	subfertile	Electronic digital thermometer
	46	33.6 (1.1)		(boxer shorts v brief style underwear)
This study (n = 48)				
neonates	14	35.7 (0.4)	nl/C	Thermoport, 24 hour profile,
		36.4 (0.2)	nl/P	30 second intervals
		34.9 (0.6)	nl/C	(cotton nappies v disposable plastic lined nappies,
		36.0 (0.4)	nl/P	paired data)
infants	22	34.7 (0.5)	nl/C	
toddlers	12	35.7 (0.4)	nl/P	

nl = normal probands, VC = varicocele (left testis), OB = obstruction of vas deferens, SCO = Sertoli-cell-only syndrome, CT = cryptorchid testis, DT = descended testis, C = cotton nappies, P = disposable plastic lined nappies.

the impact of a temperature increase of the observed magnitude on the developing testis of the male infant is still unknown. In addition to the effects of increased testicular temperature on spermatogenesis, the former may be one of the aetiological factors in testicular malignancy.³⁰

As has been recently shown, mechanisms of action of increased testicular temperature on testicular function and spermatogenesis include specific downregulation of messenger ribonucleic acid for the major sperm surface antigen CD52³¹ and/or of testicular androgen biosynthesis due to cytochrome P450c17 thermolability in Leydig cells.³² There is further evidence that heat shock inhibits the translation of messenger ribonucleic acid in testicular cells.³³

While there is ample evidence for the biological significance of increased testicular temperature for male reproductive health, no such data are available in children. However, part of the deleterious effect of cryptorchidism on later spermatogenesis is believed to be due to increased testicular temperature.^{34 35} Furthermore, experimental primary cryptorchidism leads to early Sertoli and Leydig cell dysfunction and germ cell degeneration in immature rats.³⁶ Similar findings were reported for newborn pigs.³⁷ The fact that scrotal temperature is significantly increased in male neonates, infants, and toddlers wearing modern disposable plastic lined nappies, and that the physiological testicular cooling mechanism is significantly blunted during plastic nappy use may have a negative long term effect on testicular maturation and spermatogenesis and, in addition, may facilitate the development of testicular cancer. Furthermore, the much longer exposure time as a result of the prolonged use of disposable nappies, which are more comfortable for the children to wear and more convenient and time saving for the mothers, may aggravate the problem further.

Since disposable plastic lined nappies were introduced in industrialised countries about 25 years ago, the long term effects of increased scrotal temperature in early childhood will have

to be studied in the generation of young men who have recently reached reproductive age. Thus, epidemiological studies of male reproductive health taking early childhood testicular temperature closely into account are needed to prove or disprove our hypothesis. Until the unification of Germany in 1990, there were marked differences in the types of and duration of nappy use in children between East and West Germany. East German children were trained to achieve bladder and bowel control from 10 months of age,³⁸ whereas in West Germany, disposable plastic nappies were (and still are) used much longer, until age 3–4 years. In addition, modern disposable plastic lined nappies were available in East Germany much later than in West Germany. Thus, young men from both parts of Germany could be the appropriate population for a study of the effect of testicular temperature during early childhood on fertility. One could also discuss studies in the non-human primate, which has been shown to be a good preclinical model for human reproductive physiology and toxicology.^{39–41}

The authors thank Dr Inge Quöß, paediatrician in Bordesholm near Kiel, Germany, for valuable suggestions in the initiation of the study. The linguistic help of Joanna Voerste is gratefully acknowledged. The authors are grateful to all parents who participated with their children in the study.

- 1 Toppari J, Larsen JC, Christiansen P, et al. Male reproductive health and environmental xenoestrogens. *Environ Health Perspect* 1996;104:741–803.
- 2 Adami H, Bergström R, Möhner M, et al. Testicular cancer in nine northern European countries. *Int J Cancer* 1994;59:33–8.
- 3 Forman D, Möller H. Testicular cancer. *Cancer Surv* 1994;19–20:323–41.
- 4 Hoff Wanderas E, Tretli S, Fossa SD. Trends in incidence of testicular cancer in Norway 1955–1992. *Eur J Cancer* 1995;31A:2044–8.
- 5 Weir HK, Marrett LD, Moravan V. Trends in the incidence of testicular germ cell cancer in Ontario by histologic subgroup, 1964–1996. *CMAJ* 1999;160:201–5.
- 6 Zheng T, Holford TR, Ma Z, Ward BA, Flannery J, Boyle P. Continuing increase in incidence of germ-cell testis cancer in young adults: experience from Connecticut, USA, 1035–1992. *Int J Cancer* 1996;65:723–9.
- 7 Auger J, Kunstmann JM, Czyglik F, Jouannet P. Decline in semen quality among fertile men in Paris during the past 20 years. *N Engl J Med* 1995;332:281–5.
- 8 Benshushan A, Shoshani O, Paltiel O, Schenker JG, Lewin A. Is there really a decrease in sperm parameters among healthy young men? A survey of sperm donations during 15 years. *J Assist Reprod Genet* 1997;14:347–53.

- 9 Carlsen E, Giwercman A, Keiding N, Skakkebaek NE. Evidence for decreasing quality of semen during past 50 years. *BMJ* 1992;305:609-13.
- 10 Irvine S, Cawood E, Richardson D, MacDonald E, Aitken J. Evidence of deteriorating semen quality in the United Kingdom: birth cohort study in 577 men in Scotland over 11 years. *BMJ* 1996;312:467-71.
- 11 Skakkebaek NE, Keiding N. Changes in semen and the testis. *BMJ* 1994;309:1316-17.
- 12 Munkelwitz R, Gilbert BR. Are boxer shorts really better? A critical analysis of the role of underwear type in male subfertility. *J Urol* 1998;160:1329-33.
- 13 Thonneau P, Ducot B, Bujan L, Mieusset R, Spira A. Heat exposure as a hazard to male fertility. *Lancet* 1996;347:204-5.
- 14 Thonneau P, Bujan L, Multigner L, Mieusset R. Occupational heat exposure and male infertility: a review. *Hum Reprod* 1998;13:2122-5.
- 15 Brown-Woodman PD, Post EJ, Gass GC, White IG. The effect of a single sauna exposure on spermatozoa. *Arch Androl* 1984;12:9-15.
- 16 Kandeel FR, Swerdloff RS. Role of temperature in regulation of spermatogenesis and the use of heating as a method for contraception. *Fertil Steril* 1988;49:1-23.
- 17 Mieusset R, Bujan L. Testicular heating and its possible contributions to male infertility: a review. *Int J Androl* 1995;18:169-84.
- 18 Kitayama T. Study on testicular temperature in men [Japanese]. *Hinjokika Kyo* 1965;11:435-65.
- 19 Kurz KR, Goldstein M. Scrotal temperature reflects intratesticular temperature and is lowered by shaving. *J Urol* 1986;135:290-2.
- 20 Rock J, Robinson D. Effect of induced intrascrotal hyperthermia on testicular function in man. *Am J Obstet Gynecol* 1965;93:793-801.
- 21 Jockenhövel F, Gräwe A, Nieschlag E. A portable digital data recorder for long-term monitoring of scrotal temperatures. *Fertil Steril* 1990;54:694-700.
- 22 Schuh H. Zu heiß gewickelt. *Die Zeit* 1999;March 11:31.
- 23 Mieusset R, Fouda PJ, Vaysse P, Guitard J, Moscovici J, Juskiewski S. Increase in testicular temperature in case of cryptorchidism in boys. *Fertil Steril* 1993;59:1319-21.
- 24 Lerchl A, Keck C, Spiteri-Grech J, Nieschlag E. Diurnal variations in scrotal temperature of normal men and patients with varicocele before and after treatment. *Int J Androl* 1993;16:195-200.
- 25 Mills RG. The pathological changes in the testes in epidemic pneumonia. *J Exp Med* 1919;30:505-10.
- 26 Procope BJ. Effect of repeated increase of body temperature on human sperm cells. *Int J Fertil* 1965;10:333-9.
- 27 Mieusset R, Grandjean H, Mansat A, Pontonnier F. Inhibiting effect of artificial cryptorchidism on spermatogenesis. *Fertil Steril* 1985;43:589-94.
- 28 Mieusset R, Bujan L. The potential of mild testicular heating as a safe, effective and reversible contraceptive method for men. *Int J Androl* 1994;17:186-91.
- 29 Zorgniotti AW, MacLeod J. Studies in temperature, human semen quality, and varicocele. *Fertil Steril* 1973;24:854-63.
- 30 Skakkebaek N, Rajpert-De Meyts E, Jorgensen N, et al. Germ cell cancer and disorders of spermatogenesis: an environmental connection? *APMIS* 1998;106:3-12.
- 31 Pera I, Ivell R, Kirchoff C. Body temperature (37C) specifically down-regulates the messenger ribonucleic acid for the major sperm surface antigen CD52 in epididymal cell culture. *Endocrinology* 1996;137:4451-9.
- 32 Kühn-Velten WN. Rapid down-regulation of testicular androgen biosynthesis at increased environmental temperature is due to cytochrome P450c17 (CYP17) thermolability in Leydig cells, but not in endoplasmic reticulum membranes. *Exp Clin Endocrinol Diabetes* 1996;104:243-9.
- 33 Cataldo L, Mastrangelo MA, Kleene KC. Differential effects of heat shock on translation of normal mRNAs in primary spermatocytes, elongated spermatids, and Sertoli cells in seminiferous tubule culture. *Exp Cell Res* 1997;231:206-13.
- 34 Cooper ERA. The histology of the retained testis in the human subject at different ages and its comparison with the scrotal testis. *J Anat* 1929;64:5-27.
- 35 Afzelius BA. Why man but not the shrew has a scrotum. In: Bierich JR, Giarola A, eds. *Cryptorchidism*. London: Academic Press, 1979:57-61.
- 36 Bergh A. Early morphological changes in the abdominal testes in immature unilaterally cryptorchid rats. *Int J Androl* 1983;6:73-90.
- 37 van Straaten HW. Lack of a primary defect in maldescended testis of the neonatal pig. *Biol Reprod* 1978;19:994-8.
- 38 Liebe S. *Pflege des kranken Kindes*. Berlin, VEB Verlag Volk und Gesundheit, 1982.
- 39 Meusy-Dessolle N, Dang DC. Plasma concentrations of testosterone, dihydrotestosterone, dehydroepiandrosterone, dehydroepiandrosterone and oestradiol-17 beta in the crab-eating monkey (*Macaca fascicularis*). *J Reprod Fertil* 1985;74:347-359.
- 40 Nieschlag E, Wickings EJ. Does the rhesus monkey provide a suitable tool for human testicular functions? In: Serio M, Martini L, eds. *Animal models in human reproduction*. New York: Raven Press, 1980:103-19.
- 41 Weinbauer GF, Behre HM, Nieschlag E. Gonadotropin-releasing hormone analog-induced regulation of testicular function in monkeys and men. In: Bouchard P, Caraty A, Coeling Bennink HJT, et al, eds. *GnRH, GnRH analogs, gonadotropins and gonadal peptides*. London: The Parthenon Publishing Group, 1993:211-227.
- 42 Mieusset R, Bujan L, Plantavid M, Grandjean H. Increased levels of serum follicle-stimulating hormone and luteinizing hormone associated with intrinsic testicular hyperthermia in oligospermic infertile men. *J Clin Endocrinol Metab* 1989;68:419-25.

Discitis versus vertebral osteomyelitis

The clinical distinction between discitis and vertebral osteomyelitis may be difficult or impossible. Data from 50 children treated at the children's hospital in Houston, Texas between 1980 and 1998 have been reviewed (Marisol Fernandez and colleagues. *Pediatrics* 2000;105:1299-304).

Of the 50 children, 36 had discitis and 14 vertebral osteomyelitis. Children with discitis were often younger (mean age 2.8 years, range 0.7-16 years) than those with osteomyelitis (mean 7.5 years, range 2-13 years) and had had symptoms for a shorter time (22 days v 33 days). In both groups the usual symptoms were refusal to walk, limp, or back pain but those with osteomyelitis often appeared more ill and were more often febrile (79% v 28%). These authors dismiss radionuclide bone scans and computed tomography as providing non-specific information and concentrate on plain radiography and magnetic resonance imaging. Plain x rays of the spine were performed on 33 patients with discitis and were regarded as diagnostic in 25 (76%). Ten children with discitis had MRI which showed abnormalities "consistent with the diagnosis" in nine. Of the 14 children with vertebral osteomyelitis plain x rays of spine were obtained in 13 and were normal in six. Eleven had MRI which established the diagnosis in all of them.

These authors conclude that spinal x rays are diagnostic in most children with discitis but MRI is needed when vertebral osteomyelitis is a serious possibility.

ARCHIVIST