

Low grade astrocytomas in the West of Scotland 1987-96: treatment, outcome, and cognitive functioning

S M Yule, T A H Hide, M Cranney, E Simpson, A Barrett

Abstract

Background—Low grade astrocytomas are among the most common central nervous system tumours in children.

Aims—To identify risk factors for the development of persistent intellectual handicap.

Methods—The notes of 30 children with histologically proven low grade astrocytoma who presented during the period 1987-96 were reviewed. Thirteen of these children who were diagnosed with intracranial tumours between 1992 and 1996 underwent cognitive assessment one year after the completion of treatment.

Results—Low grade astrocytomas were found in the cerebellum (59%), thalamus (17%), cerebral hemispheres (10%), and the cervical spinal cord (9%). Where possible all patients were treated with gross total resection of the tumour. Symptomatic children with tumours judged to be inoperable underwent biopsy followed by radiotherapy (13%). Three patients developed progressive disease following surgery and underwent repeat surgery and radiotherapy. Survival at a median follow up of 75 months (range 30-131) is 97%. At one year after the completion of treatment persisting cognitive impairment was common. The strongest predictor of IQ scores was the duration of symptoms of increased intracranial pressure preoperatively.

Conclusions—Although the overall survival rate of children with low grade astrocytoma is excellent, significant long term disability occurs. Early diagnosis is essential to reduce postoperative cognitive morbidity.

(Arch Dis Child 2001;84:61-64)

Keywords: low grade astrocytoma; surgery; radiotherapy; cognitive functioning

Low grade astrocytomas account for the majority of paediatric central nervous system neoplasms. Our knowledge of the clinical behaviour of these tumours has increased considerably following improvements in imaging and recent reports of long term outcome.¹⁻⁶ The optimum treatment of cerebellar tumours and lesions in the cerebral hemispheres is gross total resection (GTR). For tumours in other sites, and in cases where this approach would produce unacceptable sequelae, surgery is usually limited to partial resection or biopsy. The routine use of adjuvant radiotherapy following

GTR has largely been abandoned.⁷ Indications for postoperative irradiation in asymptomatic patients with significant residual tumour remain unclear because of the indolent nature of these neoplasms.

Although the long term outcome in terms of survival for this group of patients is excellent, in addition to physical disability there is an increasing awareness of cognitive sequelae in a proportion of children.⁸⁻⁹ While previous studies have highlighted the importance of radiotherapy in this respect, such analyses cannot explain intellectual loss in a group of children treated with surgery alone.¹⁰⁻¹² In this study we reviewed a decade of experience with low grade astrocytomas in order to identify risk factors for the development of significant cognitive/intellectual impairment following therapy.

Patients and methods

Medical records were reviewed for all children referred to this paediatric oncology unit with low grade astrocytomas between January 1987 and December 1996 inclusive. Patients were included in the study only if they had a biopsy proven diagnosis of low grade astrocytoma and complete follow up information. Tumours of the visual pathway and brain stem were not included in the study as the majority of these were diagnosed on imaging alone and were not biopsied. The extent of planned surgical resection was based on tumour location and preoperative imaging studies. Initial GTR was attempted for supratentorial hemispheric, cerebellar, and spinal cord tumours. Biopsy alone was performed on deep seated midline (hypothalamic and thalamic) tumours. Symptomatic patients whose initial surgery consisted of biopsy only and children who experienced tumour progression at an interval following surgery underwent further surgical resection followed by radiotherapy. The extent of tumour clearance was evaluated by reviewing operating notes and imaging studies. All patients underwent computed tomography of the primary site with contrast enhancement between three and six months following initial surgery and were reviewed regularly as outpatients. Further imaging studies were only performed following symptomatic deterioration. The duration and nature of each child's presenting symptoms was obtained from their initial entry in the case notes or from the general practitioner or referring paediatrician's letter. From 1992 onwards all patients with intracranial tumours underwent psychometric assessment one year after completing therapy.

Department of
Haematology, Royal
Hospital for Sick
Children, Yorkhill,
NHS Trust, Yorkhill,
Glasgow G3 8SJ, UK
S M Yule
M Cranney
E Simpson

Institute of
Neurological Sciences,
Southern General
Hospital NHS Trust,
Glasgow, UK
T A H Hide

Beatson Oncology
Centre, Western
Infirmary, Glasgow
G11 6NT, UK
A Barrett

Correspondence to:
Dr Yule

Accepted 9 May 2000

Table 1 Overall IQ scores one year following treatment in children with intracranial astrocytomas diagnosed between 1992 and 1996

Clinical characteristics	Overall IQ, median (range)	p value
Supratentorial tumour	87 (76–105)	NS
Infratentorial tumour	90 (69–123)	
Perioperative CSF shunt	80 (69–105)	NS
No CSF shunt	79 (75–123)	
Radiotherapy	77 (76–102)	NS
Surgery alone	81 (69–123)	

Table 2 Persisting neurological sequelae in children treated for low grade astrocytoma

Disability	Frequency
Ataxia	5 (17%)
Optic atrophy	4 (13%)
Eye movement disorder	4 (13%)
Hemiplegia	2 (7%)
Facial nerve palsy	2 (7%)
Seizures	2 (7%)
Panhypopituitarism	1 (3%)

Results

Thirty children (14 girls) were identified from hospital records. Median age at presentation was 6 years (range 1–13). Twenty six (87%) of these tumours were pilocytic astrocytomas, another three (10%) were fibrillary astrocytomas, and a single tumour was classified as a mixed oligoastrocytoma. Cerebellar tumours accounted for more than half of the cases studied (57%) with central midline supratentorial tumours, predominantly thalamic, forming the next largest group (17%). The remainder of the study group consisted of tumours originating from either the cerebral hemispheres (13%) or the cervical spinal cord (10%).

The median duration of symptoms prior to diagnosis was four months (range zero (incidental finding) to eight years). An attempt at GTR was carried out at presentation in 87% of children, with complete resection achieved in 38%. Twelve patients (40%) required perioperative cerebrospinal fluid shunting. Biopsy followed by postoperative radiotherapy was performed in the majority of central supratentorial tumours. A median dose of 50 cGy (range 44–50 cGy) was delivered in weekday fractions of 1.5 cGy. Three children developed tumour recurrence/progression, occurring 9–28 months following surgery, and in all cases

a second attempt at GTR was made followed by radiotherapy. Overall a total of eight (27%) children were treated with radiotherapy. There was no correlation between the extent of tumour resection at presentation, histology, or site and recurrence/progression following therapy. No patient developed progressive disease following radiotherapy. One patient died following matched unrelated donor bone marrow transplantation for acute lymphoblastic leukaemia. Thus the overall survival at a median follow up of 75 months (range 30–131 months) is 97%.

Sixteen patients diagnosed between 1992 and 1996 inclusive underwent global psychometric testing using the Weschler Intelligence Score for Children III (UK edition). Standard administration and scoring procedures were used to generate verbal, performance, and full scale intelligence quotients (IQ), mean 100, SD 15.¹³ Testing was impossible in two patients as a result of visual handicap and the score of one other patient was excluded from further analysis because of pre-existing autism. The median overall IQ score was 79 (range 69–123); median verbal and performance IQ scores were 89 (range 69–120) and 78 (range 69–125) respectively. IQ scores were not significantly correlated to tumour site (infratentorial versus supratentorial), the requirement for perioperative CSF shunting, or previous radiotherapy (table 1). The most powerful predictor of IQ scores was the duration of symptoms of increased intracranial pressure prior to surgery (fig 1). All IQ scores were significantly greater in children who presented within four months of the development of headache or vomiting of the development of headache or vomiting (median 99.5 v 72, $p = 0.036$, Mann–Whitney U test). All patients with this delay in diagnosis continue to need learning support at school and receive regular assessment by local education psychologists. Two of this group continue to receive support for persistent postoperative behavioural disturbance. While individual performance and verbal IQ scores were often discordant with patients exhibiting unbalanced weaknesses in specific areas, there was no consistent pattern of dysfunction ($p > 0.05$, Student's paired t test).

Table 2 presents a summary of the physical sequelae following treatment. Individual neurological deficits relate closely to tumour site. All four children with residual optic atrophy complained of symptoms of raised intracranial pressure (headache and vomiting for at least four months prior to diagnosis). One patient treated with radiotherapy for a thalamic astrocytoma whose radiotherapy field

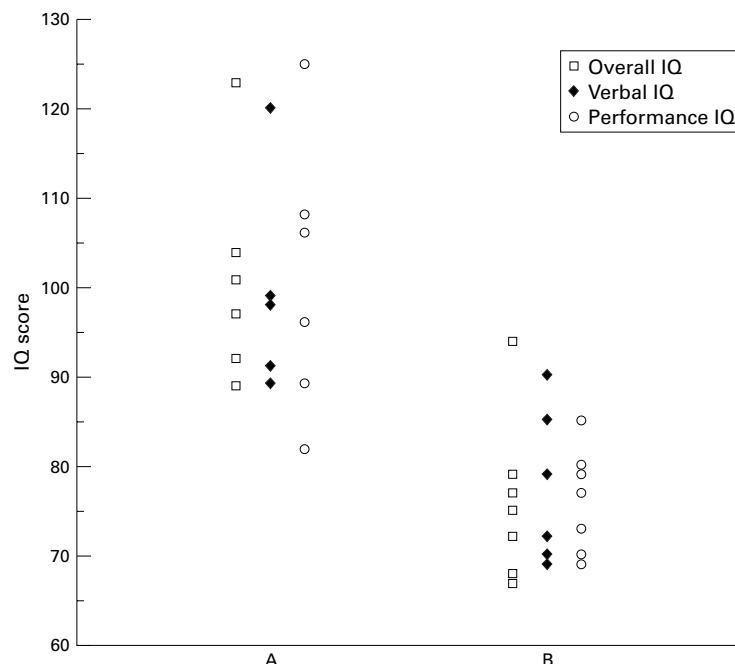


Figure 1 Comparison of IQ scores in patients who experienced less than four months of headache and vomiting prior to neurosurgical referral (A) and those with a more prolonged symptom history (B). Overall IQ scores, $p = 0.036$.

included the pituitary gland has developed panhypopituitarism.

Discussion

This report illustrates the excellent prognosis of low grade astrocytomas in children using current neurosurgical techniques. Previous studies have identified several risk factors for tumour recurrence/progression including age, histology (pilocytic versus non-pilocytic), site, and extent of resection, although several of these remain controversial.^{3 6 14} None of these variables were significantly correlated with recurrence/progression in our investigation. Children with recurrent/progressive tumours re-presented within three years of diagnosis, a time span which is consistent with other reports of a survival plateau in children being reached between three and five years of follow up.^{4 6} Although postoperative radiotherapy is no longer routinely indicated following GTR, its role in the treatment of patients who have a significant tumour mass following surgery is less certain. The benefits of radiotherapy are difficult to establish as many children with untreated residual tumour exhibit no sign of progression during prolonged follow up. Our results concur with those of other investigators who recommend that postoperative radiotherapy should only be given when there is definite evidence of unresectable enlarging tumour or worsening symptoms; in the majority of cases a "wait and see" policy is justified. Our policy of performing repeated imaging only if there is clinical deterioration remains appropriate, provided that symptomatic change is the only indication for further intervention.

Radiotherapy continues to be an effective treatment option for both recurrent low grade astrocytomas and primary tumours whose site of origin make GTR impractical. Increasing concerns over the late effects of radiotherapy, particularly the appearance of second tumours, hypopituitarism, and cognitive dysfunction in very young children have limited its application.^{12 15 16} We found no effect of radiotherapy on IQs obtained using the Weschler Intelligence Score for Children III when the test was applied one year following treatment. While this is reassuring, it is possible that subtle cognitive deficits similar to those seen in children receiving cranial irradiation for the treatment of acute lymphoblastic leukaemia will become more pronounced with longer follow up.¹⁷ Direct comparisons between IQ scores presented here and previously published results are difficult because of methodological and timing differences between studies and our selection of a patient group which varied in terms of tumour site and prior radiotherapy. In contrast to a previous report we did not find evidence of more severe cognitive impairment in patients with supratentorial tumours.¹⁸ Although we had hoped to continue testing at regular intervals beyond one year, this has been abandoned because of limited enthusiasm from the parents of children (and in some cases the children themselves) who are making satisfactory school progress and duplication of work

between ourselves and local educational services. It was not possible to perform IQ testing prior to surgery because of direct referrals to the neurosurgical centre and the deteriorating clinical condition of some patients. With the exception of a single child, who had previously been diagnosed as suffering from autism, there was no suggestion of pre-existing cognitive impairment in this group. Parental reporting suggested a satisfactory school performance in all other patients prior to diagnosis.

Set against the background of high survival rates, the incidence of chronic neurological and cognitive sequelae in children treated for low grade astrocytoma has assumed increasing importance. We found the neurological outcome of this group to be largely predictable on the basis of tumour site. In contrast the extent of cognitive dysfunction varied considerably between patients; indeed it was the seemingly unpredictable severity of this problem which led to this study being performed. Unlike others we found no relationship between neuropsychological functioning and age, tumour site, or the use of radiotherapy.¹⁸⁻²¹ This may reflect differences in study groups and/or assessment techniques. Instead we identified a positive correlation between the duration of symptoms of increased intracranial pressure before surgery and the extent of subsequent cognitive dysfunction, suggesting that long term elevations in intracranial pressure are important in its aetiology. Although such a relationship has been suggested previously, our results are the first to confirm this hypothesis in a clinical setting. The evolution of these cognitive deficits is unknown. There is no reason to expect that they will improve with time. Indeed the limited data that we have obtained indicate that they persist and in some cases deteriorate.²² Serial results are subject to bias in that only patients perceived by their families to be struggling at school attend for repeat testing. At present there is no therapy of proven benefit for affected children and all that can be offered is directed learning support. The outcome of intensive cognitive remediation programmes for severely affected patients is eagerly awaited.²³ It is important to remember that the duration of school absence is also an important predictor of subsequent neuropsychological dysfunction, and patients should be encouraged to make an early return to full time education.²⁰

While low grade astrocytomas in childhood are readily curable the quality of life experienced by survivors is often limited by physical and cognitive sequelae. Regular psychological assessment and discussion of results with local education authorities should be a routine aspect of follow up. Children who have suffered prolonged periods of raised intracranial pressure are particularly at risk of severe neuropsychological sequelae. Recent studies continue to reveal unfortunate delays in the treatment of children with brain tumours.²⁴ While the benefits of early treatment would seem to be self evident, our study shows an objective benefit of prompt referral.

The authors would like to thank members of the Department of Child Psychology, Yorkhill NHS Trust who performed the cognitive assessments included in this study.

- 1 Wallner KE, Gonzales MF, Edwards MSB, Wara WM, Shelton GE. Treatment results of juvenile pilocytic astrocytoma. *J Neurosurg* 1988;69:171–6.
- 2 Woo SY, Donaldson SS, Cox RS. Astrocytoma in children: 14 years experience at Stanford University Medical Center. *J Clin Oncol* 1988;6:1001–7.
- 3 North CA, North RB, Epstein JA, Piantadosi S, Wharam MD. Low grade cerebral astrocytomas. Survival and quality of life after radiation therapy. *Cancer* 1989;66:6–14.
- 4 Janny P, Cure H, Mohr M, et al. Low grade supratentorial astrocytomas. *Cancer* 1994;73:1937–45.
- 5 Pollack IF, Claassen D, al-Shboul Q, et al. Low-grade gliomas of the cerebral hemispheres in children: an analysis of 71 cases. *J Neurosurg* 1995;82:536–47.
- 6 Gajjar A, Sanford RA, Heideman R, et al. Low-grade astrocytoma: a decade of experience at St Jude Childrens Research Hospital. *J Clin Oncol* 1997;15:2792–9.
- 7 Morantz RA. Radiation therapy in the treatment of cerebral astrocytoma. *Neurosurgery* 1987;20:975–82.
- 8 Mulhern R, Hancock J, Fairclough D, et al. Neuropsychological status of children treated for brain tumours: a critical review and integrative analysis. *Med Pediatr Oncol* 1992;20:181–91.
- 9 Dennis M, Hetherington CR, Spiegler BJ. Memory and attention after childhood brain tumours. *Med Pediatr Oncol* 1998;(suppl 1):25–33.
- 10 LeBaron S, Zeltzer PM, Zeltzer LK, et al. Assessment of quality of survival in children with medulloblastoma and cerebellar astrocytoma. *Cancer* 1988;62:1215–22.
- 11 Glauser TA, Packer RJ. Cognitive deficits in long-term survivors of childhood brain tumours. *Childs Nerv Syst* 1991;7:2–12.
- 12 Roman DD, Sperduto PW. Neuropsychological effects of cranial radiation: current knowledge and future directions. *Int J Radiat Oncol Biol Phys* 1995;31:983–98.
- 13 Wechsler D. *Wechsler Intelligence Scale for Children—third edition (WISC-III)*. San Antonio, Texas: Psychological Corp., Harcourt Brace Jovanovich, 1991.
- 14 Berger MS, Deliganis AV, Dobbins J, et al. The effect of extent of resection on recurrence in patients with low grade cerebral hemispheric gliomas. *Cancer* 1994;74:1784–91.
- 15 Brada M, Ford D, Ashley S, et al. Risk of second brain tumour after conservative surgery and radiotherapy for pituitary adenoma. *BMJ* 1992;304:1343–6.
- 16 Sklar CA, Constine LS. Chronic neuroendocrinological sequelae of radiation therapy. *Int J Radiat Oncol Biol Phys* 1995;31:1113–21.
- 17 Moore IM, Kramer JH, Wara W, Halberg F, Ablin AR. Cognitive function in children with leukaemia: effect of radiation dose and time since irradiation. *Cancer* 1991;68:1913–17.
- 18 Ellenberg L, McComb JG, Siegel SE, Stowe S. Factors affecting intellectual outcome in pediatric brain tumour patients. *Neurosurgery* 1987;21:638–44.
- 19 Silber JH, Radcliffe J, Peckham V, et al. Whole-brain irradiation and decline in intelligence; the influence of dose and age on IQ score. *J Clin Oncol* 1992;10:1390–6.
- 20 Butler RW, Hill JM, Steiner PG, Meyers PA, Findlay JL. Neuropsychological effects of cranial irradiation, intrathecal methotrexate and systemic methotrexate in childhood cancer. *J Clin Oncol* 1994;12:2621–9.
- 21 Copeland DR, deMoor C, Moore BD III, Alter JL. Neurocognitive development of children after a cerebellar tumour in infancy: a longitudinal study. *J Clin Oncol* 1999;17:3476–86.
- 22 Hoppe-Hirsch E, Renier D, Lellouch-Tubania A, Sainte-Rose C, Hirsch JF. Medulloblastoma in childhood: progressive intellectual deterioration. *Childs Nerv Syst* 1990;6:60–5.
- 23 Butler RW. Attentional processes and their remediation in childhood cancer. *Med Pediatr Oncol* 1998;(suppl 1):75–8.
- 24 Edgeworth J, Bullock P, Bailey A, Gallagher A, Crouchman M. Why are brain tumours still being missed? *Arch Dis Child* 1996;74:148–51.

Infantile torticollis

Does early treatment of infantile torticollis prevent established deformity needing surgery? Do all babies with a sternomastoid tumour need passive muscle stretching manoeuvres? A large series from Hong Kong (JCY Cheng and colleagues. *Journal of Pediatric Surgery* 2000;35:1091–6) does not answer these questions but provides data about outcome.

The series included 1086 infants with torticollis (excluding acute onset torticollis, spinal anomalies, spasmodic torticollis, and torticollis secondary to neurological, ocular, or other diseases) of whom just under half had a sternomastoid tumour, about a third had a tight sternomastoid muscle but no tumour, and the remaining 20% had neither a tumour nor tightness of the muscle (postural torticollis). Hip dysplasia was found in 4% and craniofacial asymmetry in 90% of the infants.

Treatment was dictated by severity. Those with less than 10° of restriction of passive rotation (compared with the normal side) received an “active home stimulation exercise and positioning programme” (no details given). Those with greater restriction had manual stretching performed by a physiotherapist three times a week. The average duration of treatment was four months. Surgery was restricted to those with significant head tilt and restriction of rotation unresponsive to at least six months of manual stretching.

A quarter of all infants were treated at home and all did well. Of those who had manual stretching over 90% did well and 5% had surgery. None of the postural group needed surgery.

Most infants with muscular torticollis do well with conservative management. A few (4% in this series) eventually need surgery.

ARCHIVIST