

## CASE REPORT

## Acute nicotine poisoning associated with a traditional remedy for eczema

P Davies, S Levy, A Pahari, D Martinez

### Abstract

**We present a case of severe acute nicotine poisoning in an 8 year old boy with moderate eczema after topical application of a traditional remedy from a book published in Bangladesh. Symptoms consistent with nicotine poisoning developed within 30 minutes of application of the remedy. The child subsequently improved with supportive care and was discharged after five days with no neurological sequelae. Diagnosis of nicotine poisoning was not initially made due to difficulty in obtaining an accurate history via an interpreter from the parents who did not speak English. Samples taken 12 hours after application of the remedy showed a serum nicotine of 89 µg/l, serum cotinine of 1430 µg/l, urine nicotine of 1120 µg/l, and a urine cotinine of 6960 µg/l confirming acute nicotine poisoning.**

(Arch Dis Child 2001;85:500-502)

Keywords: nicotine poisoning and toxicity, traditional remedy, dermal absorption

This is the first report of nicotine poisoning secondary to dermal absorption from a traditional remedy. Nicotine is a highly toxic substance in overdose and is rapidly absorbed from the skin. We recommend that parents are educated about the potential toxicity of seemingly innocuous substances used in traditional remedies, and that extra care needs to be taken when taking a history through an interpreter. Health care professionals should be aware of the symptoms and signs of nicotine poisoning

and that rapid absorption of the drug is possible through the skin. Treatment of nicotine poisoning is essentially supportive but atropine can specifically treat muscarinic symptoms such as bradycardia, salivation, and wheezing.

### Case history

KR is a healthy 8 year old boy with moderate eczema. On the day of admission, he had been complaining of a mild headache but was otherwise well. In the evening his mother made up a medicinal paste for eczema, which was applied topically to his affected eczematous areas. He suffered from mild to moderate eczema affecting the flexures of the upper limbs and extensors of the lower limbs but his skin was essentially intact. Around 30 minutes later, he began to feel dizzy and went for a hot bath to wash the paste off. He then complained of laboured breathing, dizziness, unsteadiness, and nausea. Shortly afterwards he vomited and then became unresponsive and an ambulance was called. In the ambulance he initially regained consciousness but, after a further episode of vomiting and a period of agitation, he again became unresponsive.

On assessment in the Accident and Emergency Department, he was noted to be sweaty, vomiting, and agitated with a fluctuating level of consciousness and dilated pupils. Temperature and blood pressure were normal. His pulse rate on admission was 45 beats per minute, which increased following treatment with a single dose of atropine 20 µg/kg intravenously. Cardiac monitor trace subsequently remained normal. Due to his agitation he was electively intubated for a CT scan, which was normal. Full blood count, renal profile, liver function tests, and arterial blood gases were normal. As the diagnosis was unclear, he was initially treated as a case of acute meningo-encephalitis with ceftriaxone, vancomycin, erythromycin, and acyclovir. Information gathered from the child's parents by a professional interpreter indicated the paste was made from betel nuts. He was transferred to intensive care where he had a stable course. He self-extubated on day 2 and had a lumbar puncture which showed no cells. He was transferred to the ward and was slightly ataxic for two days before discharge.

On further discussion with a Bengali speaking doctor (AP), the paste was found to have been made from a ground mixture of tobacco

St Mary's NHS Trust,  
Praed Street, London  
W2 1NY  
P Davies  
A Pahari

Medical Toxicology  
Unit, Guy's and St  
Thomas's Hospital, St  
Thomas Street,  
London SE1 9RT  
S Levy  
D Martinez

Correspondence to:  
Dr Davies, Department of  
Paediatrics, Luton and  
Dunstable Hospital, Lewsey  
Road, Luton LU4 0DZ, UK  
daviespatrick@hotmail.com

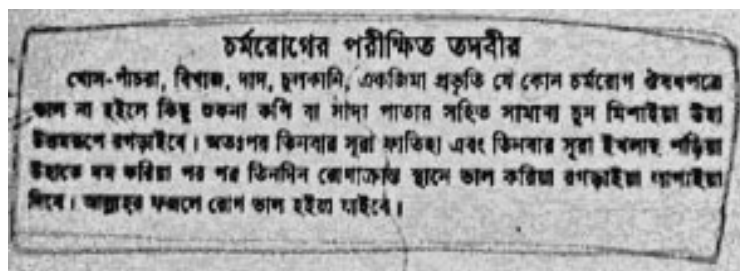


Figure 1 Recipe found in a Bangladeshi book written by Akm Fazlur Rahman Aamwari. Translation: "Tested Remedy for Skin Disease. If skin disease like ringworm, eczema, scabies, etc are not being cured by medicines then mix some dry coffee or tobacco leaves with some lime powder and grind them together vigorously. Thereafter recite Sur Fatiha thrice and Surah Ikhlas thrice over the potion. Apply the potion over the affected skin for three consecutive days. God willing, your disease will be cured."



Figure 2 Photograph of ingredients of the paste.

leaves, lime, and freeze dried coffee mixed with water (figs 1, 2<sup>3</sup>).

Samples taken 12 hours after onset of symptoms, were subsequently positive for nicotine and cotinine (the major metabolite of nicotine) showing a serum nicotine of 89 µg/l, serum cotinine of 1430 µg/l, urine nicotine of 1120 µg/l, and a urine cotinine of 6960 µg/l confirming the diagnosis of acute nicotine poisoning. The finding of nicotine or cotinine in urine is very common due to the widespread use of tobacco in the environment and is not usually noteworthy, but the high concentration noted in our patient lead to quantification of these substances in both urine and serum.

### Discussion

This is the first case report of acute nicotine poisoning secondary to dermal absorption from a traditional remedy. Nicotine poisoning has been most frequently described in children due to consumption of tobacco products (cigarette ends or nicotine replacement chewing gum).<sup>1</sup> Poisoning secondary to dermal absorption of nicotine has been described following accidental application of nicotine patches.<sup>2</sup> Of more relevance to our case is the report of severe nicotine poisoning in a 2 and three-quarter year old child following the use of a tobacco leaf enema for the treatment of pinworm.<sup>3</sup> A syndrome termed "Green Leaf Tobacco Sickness" is caused by dermal absorption of nicotine while harvesting wet tobacco leaf without skin protection.<sup>4</sup> In this case, toxicity is associated with moistening the tobacco leaf with water allowing absorption of the nicotine laden fluid through the skin. Our patient removed the paste with hot water and this, along with the child's eczema, may be the reason for the rapid and severe symptoms observed.

Smoking in adults (average 33 cigarettes per day) has been found to give serum nicotine and cotinine concentrations of between 35–249 µg/l and 94–444 µg/l respectively.<sup>5</sup> Serum nicotine concentrations of above 2000 µg/l are

often associated with serious toxicity. The therapeutic half-life of nicotine is short (between 1 and 4 hours) so the finding in our patient of a serum nicotine concentration of 89 µg/l 12 hours after application of the remedy is consistent with the severity of symptoms observed in the child on presentation.

This case highlights the need for clear history taking and the difficulty in achieving this through an interpreter. The initial confusion about the ingredients of the paste was not clarified until a Bengali speaking doctor was able to take a precise history. Betel nuts are used widely in South East Asia and are usually taken combined with a lime and tobacco preparation as a mixture called "pan". It was the use of the same type of lime preparation in the paste made for our patient that caused the initial confusion about the history.

Both tobacco and betel nut contain cholinergic alkaloids (nicotine and arecoline respectively) which act on central and peripheral nicotinic and muscarinic receptors causing central nervous system, sympathetic autonomic, parasympathetic autonomic, and neuromuscular effects in varying combinations, depending on the dose of the substance ingested.<sup>6</sup> Nicotine initially acts as an agonist at the nicotinic receptor causing effects consistent with sympathetic stimulation, but then blocks the receptor producing late parasympathetic effects and neuromuscular blockade. Severe nicotine poisoning, therefore, has 2 phases, with the first being stimulatory and the second being inhibitory. Nicotine also acts unpredictably as an agonist at muscarinic receptors causing parasympathetic type effects that are reversed by atropine.<sup>6</sup> The mechanism of action of betel nut is very similar to nicotine with early hypertension and tachycardia progressing to hypotension and bradycardia with variable muscarinic effects also observed.<sup>6</sup>

The symptoms experienced by our patient illustrate the biphasic nature of severe nicotine poisoning and the partial response to atropine show that some of the adverse effects were muscarinic in origin. The child continued to have residual symptoms for 72 hours and this is consistent with the duration of symptoms in other cases of severe nicotine poisoning.

This is the first report of nicotine toxicity secondary to dermal absorption of the substance from a traditional remedy. Nicotine poisoning should be considered in cases where traditional remedies have been applied topically. Parents should be educated about the dangers of using seemingly innocuous substances in traditional remedies and health care professionals should be aware of the toxicity of nicotine when taken both orally and absorbed dermally. Accurate history taking is critical in making the diagnosis of poisoning and can be inaccurate if taken via a third party. Treatment for nicotine poisoning is supportive but atropine can be effective in reversing muscarinic effects such as symptomatic bradycardia, hypotension or excessive respiratory secretions.

<sup>1</sup> Haruda F. "Hip-pocket" sign in the diagnosis of nicotine poisoning. *Pediatrics* 1989;84:196.

- 2 Woolf A, Burkhart K, Caraccio T, *et al.* Childhood poisoning involving transdermal nicotine patches. *Pediatrics* 1997;99:E4.
- 3 Oberst BB, McIntyre RA. Acute nicotine poisoning. *Pediatrics* 1953;11:338-40.
- 4 Mcknight RH, Levine EJ, Rodgers GC Jr. Detection of green tobacco sickness by a regional poison center. *Vet Hum Toxicol* 1994;36:505-10.
- 5 Hurt RD, Dale LC, Offord KP, *et al.* Serum nicotine and cotinine levels during nicotine-patch therapy. *Clin Pharmacol Ther* 1993;54:98-106.
- 6 Salomon ME. Nicotine and tobacco preparations. In: Goldfrank, Flomenbaum, Lewin, Weisman, Howland, Hoffman. *Goldfrank's Toxicologic Emergencies, 6th edn.* Ohio: Appleton and Lange, 1998:1146-57.

## Out of the mouths of babes and sucklings



Figure 1 Cover of Archives, June 2001.



Figure 2 By Gavriel Cohn

In June 2001, our cover contained an image of an artwork now hanging in the Royal College of Paediatrics and Child Health's council chamber, showing children rollerskating (fig 1). Dr Anthony Cohn, a Watford (UK) paediatrician, told us that his son had remarked how dangerous it was that no child in the painting was wearing a helmet. Eager to subscribe to the current passion for hearing the patient's voice, we politely asked Dr Cohn if his son would like to write us a short note of his views.

With our usual close attention to detail, we had failed to note that Gavriel Cohn was aged 4. Dr Cohn responded that, consequently, a short note would be somewhat overambitious; his co-drawing skills, he told us, were subjectively meaningful but objectively abstract (fig 2).

However, Dr Cohn kindly passed on his son's opinion that the reasons for helmet use were: in case you break your head and;

- then the doctor will have to come
- you can't see anymore
- you will have to go to hospital for a long time
- you will be died (sic)

We are grateful to Cohn and Cohn for their contribution and are impressed by the second author's belief in the reliability of his general practitioner's probable response to a request for a home visit.

Our referee expressed concern about the perceived prolonged length of stay in Watford General Hospital. The editorial board were alarmed about the stated likely outcomes so wondered whether our ethical position demanded that we advise the hospital's medical director to mount an audit of such patients. However, Cohn and Cohn also pointed out that a US report in 1996 identified 76 000 injuries and 36 deaths from the activity illustrated<sup>1</sup> so we withdrew our suggestion on the grounds that the second author (and probably his senior colleague) were at least as safe in Watford as in California.

1 American Academy of Pediatrics. Policy statement on in-line skating injuries in children and adolescents (RE9739). *Pediatrics* 1998;101:720-2.