

SHORT REPORT

Cerebral venous thrombosis during diabetic ketoacidosis

S Keane, A Gallagher, S Ackroyd, M A McShane, J A Edge

Arch Dis Child 2002;**86**:204–206

Neurological deterioration during an episode of diabetic ketoacidosis is usually assumed to be caused by cerebral oedema. We present a case of cerebral venous sinus thrombosis presenting in a similar manner, also associated with severe iron deficiency anaemia. Computed tomography scanning provided the correct diagnosis and allowed institution of anticoagulation with improvement in neurological outcome. Neuroimaging should always be performed in suspected cerebral oedema associated with diabetic ketoacidosis in order to exclude other pathologies.

Cerebral oedema is the major cause of death and neurological morbidity in children with insulin dependent diabetes. However, other intracranial pathologies may present in a very similar manner and unless neuroimaging is performed, appropriate treatment may be withheld. We present a case where neuroimaging provided the correct diagnosis of cerebral venous sinus thrombosis, allowing anticoagulation to be started, and resulting in an improved clinical outcome.

CASE REPORT

A 5 year old previously fit and well white girl with insulin dependent diabetes was admitted to her local hospital with a 12 hour history of vomiting and lethargy. She had had diabetes since she was 2 years old and was well controlled on twice daily insulin (0.7 units/kg/day).

On admission she was pale, afebrile, moderately dehydrated, and lethargic. No infective focus was found on clinical examination and there were no focal neurological manifestations. Admission laboratory studies revealed an increased true blood glucose of 14.8 mmol/l, with a compensated metabolic acidosis (pH 7.33, pco₂ 3.2 KPa, bicarbonate 12 mmol/l, base excess -11 mmol/l). Urinalysis showed ketones of 16 mmol/l.

A blood count showed a microcytic anaemia, with a haemoglobin of 41 g/l, a mean cell volume of 59.3fL, a white cell count of $10.2 \times 10^9/l$, and platelet count of $348 \times 10^9/l$. A clotting screen was normal and laboratory investigations were consistent with iron deficiency anaemia. The patient had no history of chronic blood loss, pica, dietary deficiencies, or symptoms of coeliac disease.

A diagnosis of mild diabetic ketoacidosis (DKA) with moderate dehydration and microcytic anaemia was made. Over the next 12 hours she was treated with around 30 ml/kg 4.5% albumin intravenously and commenced on a normal maintenance fluid rate (0.45% saline/5% dextrose) and intravenous insulin (0.05 units/kg/h). Her condition initially began to improve. However 12 hours after admission she became increasingly confused and by morning she was unconscious, responding to painful stimuli only and was found to have limb rigidity and fisting. Her pupils were reacting and her fundi were normal on fundoscopy. The blood glucose had risen to 20 mmol/l overnight, plasma bicarbonate remained between 11 and 14 mmol/l, and the pH had risen to 7.35. Ketonuria was

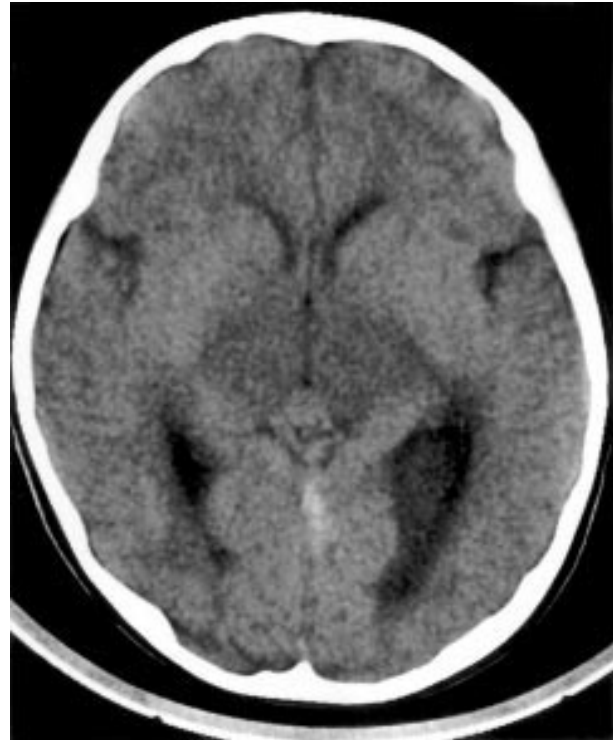


Figure 1 CT scan showing increased echogenicity in straight sinus, confirming presence of thrombosis. Also note control hypodense areas consistent with basal ganglia infarction.

still present. She was immediately treated for suspected cerebral oedema with mannitol (0.5 g/kg) and dexamethasone and then transferred to the intensive care unit where she was intubated and commenced on artificial ventilation. Empirical antibiotics and acyclovir were commenced after blood cultures were taken. She received a transfusion of packed red blood cells. She was transferred to the regional paediatric intensive therapy unit for further management of suspected cerebral oedema.

On arrival, a brain computed tomography (CT) scan was done which showed an appearance consistent with thrombosis in the straight sinus and the vein of Galen with ischaemic changes in the thalamus (fig 1). A lumbar puncture was performed (white cell count 0, red blood cells 160, no organisms seen). An intracranial pressure transducer was inserted to monitor intracranial pressure but this remained stable and no treatment was required. The transducer was removed after 24 hours. Her blood glucose concentration was well controlled on intravenous insulin and maintenance dextrose saline. After

Abbreviations: CT, computed tomography; CVT, cerebral venous thrombosis; DKA, diabetic ketoacidosis

two days of artificial ventilation, she was extubated without difficulty but remained encephalopathic. A further CT brain scan showed extension of the thrombus involving the cortical venous system. A decision to anticoagulate was made and intravenous heparin was commenced 48 hours after admission to the intensive therapy unit, with some improvement in neurological status. Warfarin treatment was started after several days with a plan to continue it for three months.

The child was slow to improve neurologically, remaining irritable with poor comprehension and no verbal communication. She had a right sided hemiplegia and was unable to support herself sitting or standing. She was fed via a nasogastric tube and her normal subcutaneous regime of insulin was restarted once full enteral feeding had been established. She was transferred back to her local hospital 13 days after admission.

She made a remarkably good neurological recovery at her local hospital and after several weeks was walking stably, using her upper limbs and vocalising a little. The warfarin was discontinued after three months. Two years after her illness she has no motor deficit and very mild learning difficulties; she attends a mainstream school with some extra help. Her diabetes remains well controlled and her haemoglobin has remained stable after a course of iron.

The following further laboratory investigations were normal: blood, CSF, urine, and stool cultures; thrombophilia screen; haemoglobin electrophoresis; immunoglobulins; anti-tigliadin antibodies; thyroid function test; and short synacthen test. No cause for her severe iron deficiency anaemia was ever found.

DISCUSSION

This is the first published report of central venous thrombosis (CVT) occurring in association with DKA in a child. Other neurological conditions (particularly cerebral oedema) may occur during treatment for DKA, but this case highlights the importance of making a specific neurological diagnosis because of the management implications. Many children presenting with apparent cerebral oedema during DKA do not have neuroimaging. However, unless CT scanning had been carried out, this girl may have been treated only for cerebral oedema, with a much less favourable outcome.

The diagnosis was not made on purely clinical grounds. In DKA there is no good correlation between the degree of obtundation and blood glucose, serum osmolality, and pH¹; in the absence of focal neurological signs the initial lethargy would have been ascribed to DKA with dehydration. Cerebral oedema is the most likely cause of acute neurological deterioration in DKA, with only 10% of acute neurological episodes a result of other causes.² This case was unusual however as ketoacidosis was only mild, and a severe iron deficiency anaemia was present. Large amounts of fluid given during resuscitation may predispose to cerebral oedema, but cerebral oedema can also occur with cautious fluid replacement.³

CVT is an uncommon condition in children and often not suspected until a neuroradiological evaluation has been made. CVT can arise as an isolated entity or in association with an underlying systemic condition such as dehydration, sepsis, malignancy, or trauma, and in rare cases of homocystinuria and Behçet's disease. Genetic or acquired risk factors for thrombophilia also play an important role in childhood venous sinus thrombosis. The incidence of familial thrombophilia tends to be higher in CVT cases than controls, by up to 30% in some studies.⁴ In the normal population there is a high frequency of familial thrombophilia but a low incidence of thromboembolic complications, suggesting that children with an inherited prothrombotic state must have an additional risk factor before CVT occurs.⁵ Several studies in adults with type 1 diabetes have shown coagulation abnormalities such as decreased protein c concentration,⁶ enhanced anti-

coagulation response to activated protein c,⁷ activated protein c resistance,⁸ and evidence of coagulation activation.⁹ Our case however had no underlying thrombotic tendency.

The association of iron deficiency anaemia and CVT/ischaemic stroke has been described in an individual case report¹⁰ and one series of six children,¹¹ in whom all other aetiologies of thrombosis were excluded. There are three proposed hypotheses as to why iron deficiency anaemia causes thrombosis/ischaemia. Firstly, thrombocytosis occurs secondary to iron deficiency anaemia and may be associated with a hypercoagulable state.¹² Secondly, iron deficiency is thought to contribute to a hypercoagulable state by altering flow patterns in vessels because of reduced red cell deformity and increased viscosity; and thirdly, hypoxia secondary to iron deficiency anaemia can occur in situations of increased metabolic stress, such as dehydration and infection.

In the case described here, there were two factors that contributed to the development of CVT: dehydration secondary to mild DKA and iron deficiency anaemia of unknown aetiology. One previous report describes thromboembolism in association with DKA in an adolescent with type 1 diabetes and Prader-Willi syndrome,¹³ but there have been no previous case reports of CVT as a complication of DKA. The condition was mentioned as a cause of death in one study of children with diabetes, but no further details were given.¹⁴

This case shows the importance of neuroimaging in DKA when cerebral oedema is suspected. Although 10% of cases of apparent cerebral oedema are caused by other pathologies,² the treatment and management of other pathologies is often different to the management of cerebral oedema. In CVT, treatment with heparin is safe and of benefit and often indicated whatever the clinical or neuroimaging pattern.¹⁵ Supportive management, control of raised intracranial pressure, and anticoagulation with heparin probably contributed towards a favourable outcome in our patient once the diagnosis of CVT was made.

It is important to recognise that not all episodes of acute neurological deterioration in DKA are caused by cerebral oedema. CVT is an infrequent condition with diverse clinical presentations. In this case CVT mimicked cerebral oedema in the setting of a child being treated for mild DKA who also had iron deficiency anaemia. The diagnosis of CVT should therefore be suspected in similar clinical settings, and the diagnosis confirmed by neuroimaging, so that appropriate treatment can be instituted.

Authors' affiliations

S Keane, A Gallagher, M A McShane, J A Edge, Department of Paediatrics, John Radcliffe Hospital, Oxford
S Ackroyd, Paediatric Department, Cheltenham General Hospital, Cheltenham, UK

Correspondence to: Dr J A Edge, Department of Paediatrics, John Radcliffe Hospital, Headington, Oxford OX3 9DU, UK; julie.edge@paediatrics.ox.ac.uk

Accepted for publication 13 November 2001

REFERENCES

- 1 Guisado R, Arieff A. Neurologic manifestations of diabetic comas: correlation with biochemical alterations in the brain. *Metabolism* 1975;**24**:665-79.
- 2 Rosenbloom A. Intracerebral crises during treatment of diabetic ketoacidosis. *Diabetes Care* 1990;**13**:22-33.
- 3 Greene S, Jefferson I, Baum J. Cerebral oedema complicating diabetic ketoacidosis. *Dev Med Child Neurol* 1990;**32**:633-8.
- 4 Bonduel M, Sciuccati G, Hepner M, et al. Prethrombotic disorders in children with arterial ischemic stroke and sinovenous thrombosis. *Arch Neurol* 1999;**56**:967-71.
- 5 Vielhaber H, Ehrenforth S, Koch H, et al. Cerebral venous sinus thrombosis in infancy and childhood: role of genetic and acquired risk factors of thrombophilia. *Eur J Pediatr* 1998;**157**:555-60.
- 6 Vukovich T, Scherthaner G. Decreased protein C levels in patients with insulin-dependent diabetes mellitus. *Diabetes* 1986;**35**:617-19.