

PERSONAL PRACTICE

Investigation of daytime wetting: when is spinal cord imaging indicated?

E Wraige, M Borzyskowski

Arch Dis Child 2002;87:151-155

Background: Most children with daytime wetting have detrusor instability. A minority have neuropathic vesicourethral dysfunction. The commonest cause is spina bifida, which may be closed. Clinical features suggestive of closed spina bifida include cutaneous, neuro-orthopaedic or lumbosacral spine x ray abnormalities, impaired bladder sensation, and incomplete bladder emptying. MRI is the ideal method for detecting spinal cord abnormality. It has been suggested that MRI spine is an unnecessary investigation in children with daytime wetting in the absence of cutaneous, neuro-orthopaedic, or lumbosacral spine x ray abnormalities.

Aim: To clarify indications for magnetic resonance imaging (MRI) of the spine in children with voiding dysfunction.

Methods: Retrospective study of children with voiding dysfunction referred from the Guy's Hospital neurology clinic for MRI spine between April 1998 and April 2000. Clinical notes and results of investigations, including urodynamic studies and MRI spine were reviewed.

Results: There were 48 children (median age 9.1 years). Closed spina bifida was detected in five, of whom four had neuropathic vesicourethral dysfunction confirmed by urodynamic studies. Impaired bladder sensation and incomplete bladder emptying were more frequent in these children than in those with normal MRI spine. One child with spinal cord abnormality had no cutaneous, neuro-orthopaedic, or lumbosacral spine x ray abnormalities.

Conclusion: Spinal cord imaging should be considered in children with daytime wetting when this is associated with impaired bladder sensation or poor bladder emptying, even in the absence of neuro-orthopaedic, cutaneous, or lumbosacral spine x ray abnormalities.

See end of article for authors' affiliations

Correspondence to:
Dr E Wraige, Department
of Paediatric Neurology,
Newcomen Centre, Guy's
Hospital, London SE1 9RT,
UK;
e.wraige@ukgateway.net

Accepted 14 March 2002

Daytime wetting is a common paediatric problem and although the majority achieve daytime bladder control by 3 years,¹ at the age of 7 years 6% of girls and 3.8% of boys continue to have some problems with daytime wetting.² Most children with daytime wetting have detrusor instability.³ It is important to identify the minority in whom wetting is caused by neuropathic vesicourethral dysfunction, as these children are at risk of renal damage and ultimately renal failure.⁴ In addition there may be spinal cord abnormality requiring neurosurgical intervention and, although controversial, spinal cord untethering in those in whom the spinal cord is tethered may prevent further deterioration and improve long term bladder and neurological function.⁵⁻⁸

Normal bladder function depends on intact interactions between sacral spinal nerves and the cerebral cortex.⁹ Neuropathic bladder dysfunction may result from a variety of spinal cord abnormalities including spinal cord trauma, transverse myelitis, or spinal cord tumour.¹⁰⁻¹¹ In a small proportion with neuropathic bladder behaviour no underlying spinal cord abnormality can be detected, the so called "occult neuropathic bladder".⁴

However, the commonest cause of neuropathic bladder dysfunction in childhood is open or closed spina bifida.⁴ Closed spina bifida results from a failure of closure of the neural tube during the first 28 days of embryogenesis, the defect being covered by skin. This may be associated with a variety of developmental abnormalities of the spinal cord,⁵ and indicated clinically by cutaneous abnormalities of the lower back overlying the lumbosacral spine, abnormal lower limb neurology, or orthopaedic abnormalities such as talipes and leg shortening.⁸ Other factors associated with spinal cord abnormality include anorectal anomalies,¹² a family history of spina bifida,⁵ and a maternal history of pregestational insulin dependent diabetes mellitus.⁵ In addition, complex abnor-

malities of the lumbosacral spine may be detected on plain spinal x rays. However, failure of fusion of the fifth lumbar (L5) and first sacral (S1) vertebral arches alone should be distinguished from closed spina bifida. The former is a normal variant occurring in an estimated 10% of the population, and is not associated with an increased incidence of underlying spinal cord pathology.⁷

Symptoms in children with closed spina bifida may include voiding dysfunction, such as wetting, impaired bladder sensation, and difficulty voiding, as well as associated bowel disturbance. An important minority with spinal cord abnormality and closed spina bifida may present with isolated bladder dysfunction in the absence of neuro-orthopaedic or cutaneous abnormalities.³

In order to identify the group of children with neuropathic bladder dysfunction, investigations frequently include video urodynamic studies (VUD). Indications for VUD in children have been described previously.¹ Abnormalities on VUD suggestive of neuropathic bladder dysfunction include incomplete bladder emptying, detrusor sphincter dyssynergia, and large capacity bladder with impaired sensation.^{4,13} When involuntary contractions occur during bladder filling, this is referred to as detrusor hyperreflexia in the presence of neurological abnormality, and detrusor instability in the absence of neurological abnormality.¹⁴ Most cases of neuropathic vesicourethral dysfunction are secondary to spinal cord pathology, and magnetic resonance imaging (MRI) of the spine is the optimum imaging technique for detecting this.^{4,8,14} However, it would be inappropriate to investigate all children with voiding dysfunction in this way.

Abbreviations: MRI, magnetic resonance imaging; VUD, video urodynamic study

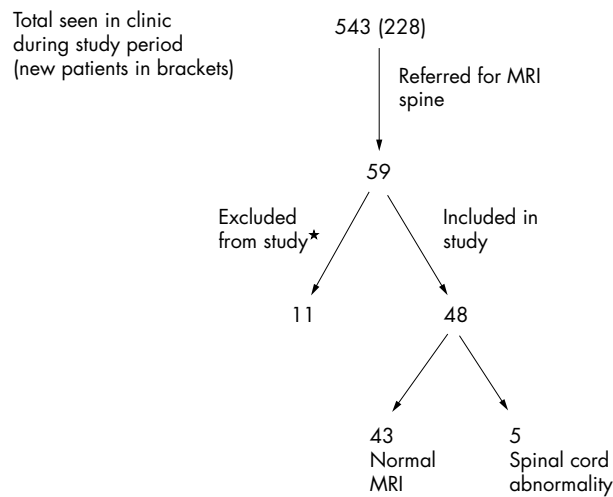


Figure 1 Patients attending neurourology clinic during study period. *Reasons for exclusion: spinal cord pathology clinically apparent and radiologically defined prior to study period ($n = 8$), no voiding dysfunction ($n = 3$).

The indications for spinal cord imaging in children with voiding dysfunction in the absence of cutaneous, neuro-orthopaedic, or plain lumbosacral spine x ray abnormalities remain controversial.^{8 15 16} Before rational guidelines for spinal imaging in children presenting with voiding dysfunction can be developed it is necessary to determine which features in the history, clinical examination, or investigation of bladder function are associated with spinal cord pathology.

The purpose of this study was therefore to investigate the symptoms, signs, and VUD abnormalities among children presenting with voiding dysfunction to the neurourology clinic at Guy's Hospital, who underwent MRI spine, and to determine any correlation with findings. Information obtained during this study has been used to develop guidelines for investigation of children with daytime wetting.

METHODS

This was a retrospective study spanning two years from April 1998 to April 2000. Patients referred from the neurourology clinic at Guy's Hospital for MRI of the spine during this time were identified from records held by the radiology department. The case notes, investigations, and results were

reviewed. This clinic provides a tertiary service for the South Thames region and beyond and the majority of children are referred for further investigation of daytime wetting which has not responded to usual management regimes. Most of the patients attending the clinic are under 18 years of age. Two patients over 18 years of age (18.6 and 19.4 years) have been included in the study; both had remained under follow up for longer than usual because of complex paediatric problems requiring multidisciplinary management.

RESULTS

Forty eight patients (16 males) were included in the study (see fig 1). The median age was 9.1 years (range 0.5–19.4 years). It is not our usual practice to investigate children under the age of 5 years with uncomplicated daytime wetting; however, three children under the age of 5 years were investigated because of the nature of their voiding dysfunction (one with urinary retention, one with anorectal anomaly associated with daytime wetting, and one with worsening daytime wetting and faecal soiling). Two of the scans performed on awake patients were suboptimal because of movement artefact; in both cases the films were adequate to exclude lower spinal cord pathology following review by the lead clinician and neuroradiologist.

Forty three patients had normal MRI spine or coincidental abnormalities unrelated to the bladder dysfunction. Spinal cord abnormalities related to the bladder dysfunction were detected in five children. Table 1 presents the clinical findings and results of investigations in those with spinal cord abnormality.

Table 2 presents the symptoms, clinical findings, and results of investigations in children with normal (or unrelated abnormalities) and abnormal MRI spine. In five patients the only indications for MRI spine were the urinary symptoms (one with secondary daytime wetting, two with daytime wetting who failed to improve as expected following puberty, one with impaired bladder sensation, and one with a sensation of incomplete bladder emptying). MRI spine was normal in each of these five children. Sixteen of those with subsequent normal MRI and all of those found to have spinal cord abnormality had a combination of two or more of the features (in addition to urinary symptoms) indicated in table 2.

Additional investigations included lumbosacral spine x rays in 18 and VUD in 43 patients. Five patients did not have VUD (two refused; in the remaining three the absence of lower spinal cord abnormality on MRI in combination with the clinical

Table 1 Details of children with spinal cord abnormality detected on MRI spine

Patient no.	1	2	3	4	5
Age at MRI (y)	12.2	11.5	4..9	12.9	0.5
History	Imperforate anus, difficulty voiding, UTI	Recurrent UTI, daytime wetting, constipation, incomplete bladder emptying	Falot's tetralogy, anal atresia, impaired bladder sensation, UTI	Daytime wetting, impaired sensation	Urinary retention, UTI
Physical examination	Brisk lower limb reflexes	Normal	Normal neuro-orthopaedic and cutaneous examination	Capillary haemangioma lumbosacral region, absent left ankle reflex	Deep sacral pit and hairy tuft lower lumbar spine
Spine x ray	Short sacrum, lumbar vertebral abnormalities	Failure of fusion S1 vertebral arches*	Not done	Not done	Not done
VUD	Open bladder neck, reduced capacity with low grade contractions. emptying by straining	Detrusor hyperreflexia, incomplete emptying	Hyperreflexia, poorly compliant bladder, incomplete emptying	Refused	Not emptying despite high pressure contractions, DSD
MRI spine	Caudal regression	Intraspinal lipoma, tethered cord	Hydromyelia thoracic and lower cervical cord, caudal regression	Low terminating cord	Caudal regression

*Normal variant.

UTI, urinary tract infection; DSD, detrusor sphincter dyssynergia.

Table 2 Abnormalities in history, on examination or investigation of children presenting with voiding dysfunction

	MRI normal* (n=43)	MRI abnormal (n=5)
Urinary symptoms		
Daytime wetting	41	4
Impaired bladder sensation	4	2
Difficulty voiding	2	1
Urinary retention	0	1
Other†	1	0
UTI	18	4
Other symptoms/features from history		
Constipation/faecal soiling	22	1
Family history spina bifida	4	0
Maternal pregestational diabetes mellitus	2	0
Neurofibromatosis type 1	1	0
Clinical findings		
Lower limb neuro-orthopaedic abnormalities‡	4	2
Cutaneous abnormalities overlying lumbosacral spine	10	2
Anorectal anomaly	0	2
Investigations other than MRI spine		
Abnormal lumbosacral spine x ray§	5	1
Incomplete bladder emptying on ultrasound scan	8	1
Urodynamic studies suggestive of neuropathic vesicourethral dysfunction¶	3	4

*Including those with unrelated abnormality on MRI spine.

†Other = sensation of incomplete emptying.

‡Included the following in isolation or combination: brisk lower limb reflexes (n=4), talipes equinovarus (n=1), absent ankle reflexes (n=1), pes cavus (n=1).

§As detailed in text, excluding failure of fusion L5/ S1 vertebral arches.

¶As detailed in text.

findings was sufficient to enable subsequent management without information from VUD). Seven patients had VUD abnormalities resulting in a diagnosis of neuropathic vesicourethral dysfunction; these included incomplete emptying or emptying by straining in each of these patients. This was associated with the following additional abnormalities: large capacity bladder (n = 4), small capacity bladder (n = 2), detrusor sphincter dyssynergia (n = 1), hyperreflexia (n = 3), and open bladder neck with fixed distal sphincter (n = 1).

Lumbosacral spine x rays were included in the investigation of 16 of the children who did not have lower spinal cord pathology. These were normal in 10 patients; in one patient films were inadequate as the sacrum was not included. The abnormalities detected in the remaining five were: failure of fusion of the neural arches of all the lumbar spinal vertebrae, failure of fusion of the L5 and S1 vertebral arches with associated widening of the interpedicular space, anomalous posterior arch of L5 with absent S1 and S2 spinous processes, extra lumbar vertebra (L6), and multiple end plate fractures from L2 to L4. Two of the children with spinal cord abnormality subsequently detected on MRI had had lumbosacral spine x rays—one was normal and one had complex spinal abnormalities, including short sacrum and partial fusion of the lumbar vertebrae.

DISCUSSION

The purpose of investigating children with bladder dysfunction with MRI of the spine is to identify those with spinal cord abnormality early. Children with closed spina bifida and associated spinal cord abnormality may present with urinary dysfunction; other indicators of spinal cord abnormality may not be apparent from the history or examination findings.^{5 10 16} The indications for spinal MRI in this group remain unclear.^{8 15-17} Pippi Salle *et al* studied a group of 23 children with voiding dysfunction and normal neuro-orthopaedic examination. They found that although there was an increased incidence of spina bifida occulta (which they defined as failure of fusion of L5, S1, or S2 vertebral arches) this did not correlate with an

increased incidence of spinal cord abnormality. They concluded that voiding dysfunction in the absence of cutaneous, neuro-orthopaedic, or complex skeletal abnormalities did not merit investigation by MRI spine.¹⁵

Mak and Radomski reached similar conclusions following their study of young adults with voiding dysfunction and recommended that even in the presence of abnormal urodynamic studies, if neurological and lower spine examination (including plain lumbosacral spine x ray) were normal, there could be little justification for MRI spine.¹⁶ In contrast, De Gennaro *et al* have suggested that MRI of the spine is indicated in children with voiding dysfunction and urodynamic abnormalities,⁸ and Ritchey *et al* recommended imaging of the spine by ultrasound scan or MRI in children with refractory incontinence and spina bifida occulta.¹⁷

Some important findings have arisen from this study:

- (1) Compared with the group with normal MRI spine, those with occult spinal dysraphism were more likely to have multiple abnormalities on examination and urodynamic studies.
- (2) Impaired bladder sensation, urinary retention, and voiding difficulties were more frequent symptoms in those with spinal cord abnormality than in those with a normal MRI. Ten children had these symptoms; four of these were found to have lower spinal cord abnormality. In contrast, only one of the 38 children who lacked these symptoms had lower spinal cord abnormality visible on MRI.
- (3) Constipation and faecal soiling was the commonest abnormality in addition to voiding dysfunction in those with normal MRI spine, but occurred in only one of the patients with spinal dysraphism. Factors prompting MRI spine in this patient were detrusor hyperreflexia and incomplete bladder emptying on urodynamic studies.

Five children with occult spinal cord abnormality were detected; four of these had multiple abnormalities suggestive of an underlying spinal cord abnormality as shown in table 1.

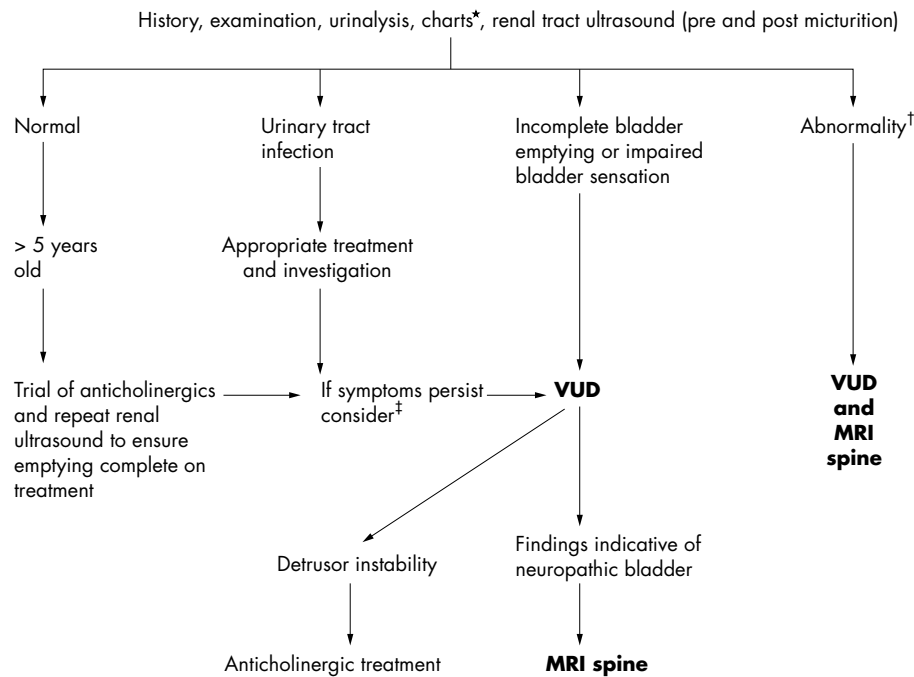


Figure 2 Suggested protocol for investigation of children with daytime wetting. *Frequency voided and volume voided charts. †Abnormalities include: lower limb neurological or orthopaedic abnormalities (e.g. talipes, absent ankle reflexes, sensory loss), midline birth marks lower back (including lipoma, deep sacral pit, hairy tuft), abnormal lumbosacral spine x ray (excluding failure of fusion L5/S1 vertebrae), anorectal abnormalities (e.g. anal atresia). In addition, family history of spina bifida, maternal insulin dependent diabetes, or persistent constipation or faecal soiling indicate need for VUD and consideration of MRI spine. ‡Particularly if other abnormalities coexist (e.g. constipation or faecal soiling).

However, one patient presenting with daytime wetting and constipation had normal neuro-orthopaedic examination, no cutaneous abnormalities, and normal lumbosacral spine x ray. Ultrasound scan showed incomplete bladder emptying. VUD was carried out in view of this finding and confirmed incomplete bladder emptying and detrusor hyperreflexia. MRI spine was performed; it revealed intraspinal lipoma with secondary tethered cord, which required neurosurgical intervention.

This shows that spinal dysraphism may present with bladder dysfunction in the absence of cutaneous, neuro-orthopaedic, or significant skeletal abnormality.

As recommended by Pippi Salle *et al*, all children with voiding dysfunction should undergo a thorough neurological, orthopaedic, and cutaneous examination.¹⁵ However, the results of our study suggest, in contrast to those of Pippi Salle and colleagues¹⁵ and Mak and Radomski,¹⁶ that MRI spine is indicated in children with voiding dysfunction suggestive of neuropathic vesicourethral dysfunction, even in the absence of other markers of occult spinal dysraphism. Our study number is small; however, 4/10 of those with symptoms of difficulty voiding, urinary retention, or impaired bladder sensation had spinal cord abnormality detected on MRI. Thus we recommend that spinal cord MRI should be seriously considered in children presenting with these symptoms.

Guy's Hospital neurology clinic is a tertiary referral centre for children with voiding dysfunction (neuropathic and non-neuropathic). Children referred to this unit have usually undergone simple investigations (for example, renal ultrasound and sometimes plain lumbosacral spine x rays) and therapeutic trials (for example, with anticholinergic medications) prior to referral. This is likely to have biased our results in favour of detection of spinal cord abnormality. However, our results are still helpful in terms of developing useful strategies for investigating children with voiding dysfunction in the primary and secondary care setting. Figure 2 illustrates a suggested protocol.

In contrast to MRI spine, plain x rays are simple to perform without the need for general anaesthetic, even in the youngest

children, and are relatively inexpensive. However, they carry the risk of exposure to x rays, and our own experience is that the failure rate is high with part of the sacrum frequently omitted from films. Pippi Salle *et al* have suggested that plain x ray of the lumbosacral spine is indicated in the investigation of children with complex voiding dysfunction, and that if it reveals complex abnormalities MRI spine may then be necessary.¹⁴ The results of our study suggest that the absence of complex spinal abnormalities on plain x ray does not preclude the need to carry out more detailed spinal imaging. This, coupled with the fact that an abnormal spinal x ray must be followed by MRI spine in order to define the nature of any associated spinal cord abnormality, indicates that when features in the history or on examination suggest that voiding dysfunction may be secondary to spinal cord abnormality, it may be appropriate to proceed directly to MRI spine. However, facilities for MRI are not available at all centres and the majority of children with voiding dysfunction will be referred to a general paediatrician in the first instance. Only a minority with additional abnormalities or failure to respond to usual therapeutic strategies will be referred to a specialist neurology clinic. Plain x rays of the lumbosacral spine may be a helpful adjunct in determining which children should be referred early to a specialist centre for further investigation.

Conclusions

Spinal cord imaging is indicated in children who present with daytime wetting in association with abnormal lower limb neurology, abnormal lumbosacral spine x ray, midline birth marks in the lumbosacral area, or anorectal anomalies, and should be considered in children with daytime wetting and a history of maternal diabetes or a family history of spina bifida. It should also be considered in children with symptoms suggestive of neuropathic vesicourethral dysfunction. This includes those with difficulty voiding, urinary retention, or impaired bladder sensation. When neuropathic bladder dysfunction has been confirmed by VUD, spinal cord imaging is mandatory. The significance of constipation associated with

daytime wetting merits further study. Our findings suggest that constipation and faecal soiling are poor predictors of lower spinal cord abnormality.

.....
Authors' affiliations

E Wraige, M Borzyskowski, Department of Paediatric Neurology, Newcomen Centre, Guy's Hospital, London SE1 9RT, UK

REFERENCES

- 1 **Borzyskowski M**. Daytime enuresis. *Curr Paediatr* 1993;**3**:156–9.
- 2 **Helstrom AL**, Hanson E, Hansson S, *et al*. Micturition habits and incontinence in 7-year-old Swedish school entrants. *Eur J Pediatr* 1990;**149**:434–7.
- 3 **Borzyskowski M**, Mundy AR. Videourodynamic assessment of diurnal urinary incontinence. *Arch Dis Child* 1987;**62**:128–31.
- 4 **Borzyskowski M**. An update on the investigation of the child with a neuropathic bladder. *Dev Med Child Neurol* 1996;**38**:744–8.
- 5 **Sutherland RS**, Mevorach RA, Baskin LS, *et al*. Spinal dysraphism in children: an overview and an approach to prevent complications. *Urology* 1995;**46**:294–304.
- 6 **Khoury AE**, Hendrick EB, McLorie GA, *et al*. Occult spinal dysraphism: clinical and urodynamic outcome after division of the filum terminale. *J Urol* 1990;**144**:426–9.
- 7 **Fone PD**, Vapnek JM, Litwiller SE, *et al*. Urodynamic findings in the tethered spinal cord syndrome: does surgical release improve bladder function? *J Urol* 1997;**157**:604–9.
- 8 **De Gennaro M**, Lais A, Fariello G, *et al*. Early diagnosis and treatment of spinal dysraphism to prevent urinary incontinence. *Eur Urol* 1991;**20**:140–5.
- 9 **Borzyskowski M**, Neville BGR. Neuropathic bladder and spinal dysraphism *Arch Dis Child* 1981;**56**:176–80.
- 10 **Johnston LB**, Borzyskowski M. Bladder dysfunction and neurological disability at presentation in closed spina bifida. *Arch Dis Child* 1998;**79**:33–8.
- 11 **Soler D**, Borzyskowski M. Lower urinary dysfunction in children with central nervous system tumours. *Arch Dis Child* 1998;**79**:344–7.
- 12 **Kakizaki H**, Katsuya N, Asano Y, *et al*. Preexisting neurogenic voiding dysfunction in children with imperforate anus: problems in management. *J Urol* 1994;**151**:1041–4.
- 13 **Borzyskowski M**, Mundy AR. The management of the neuropathic bladder in childhood. *Pediatr Nephrol* 1988;**2**:56–66.
- 14 **Andersen JE**, ed. Urodynamics terminology and normal values in children, females and males. *Scand J Urol Nephrol Suppl* 1988;**114**:1–27.
- 15 **Pippi Salle JL**, Capolicchio G, Houle AM, *et al*. Magnetic resonance imaging in children with voiding dysfunction: is it indicated? *J Urol* 1998;**160**:1080–3.
- 16 **Mak V**, Radomski SB. Value of magnetic resonance imaging of the lumbo-sacral spinal cord in patients with voiding dysfunction. *J Urol* 1996;**156**:1421–3.
- 17 **Ritchey ML**, Sinha A, Dipietro A, *et al*. Significance of spina bifida occulta in children with diurnal enuresis. *J Urol* 1994;**152**:815–18.

WEB TOP TEN FOR 2001

www.archdischild.com

These articles scored the most hits on ADC's website during 2001

1 Complementary and alternative medicine for children: does it work?

January 2001;**84**:6–9. TOTAL HITS: **12,632**

2 MMR vaccine—worries are not justified

D A C Elliman, H E Bedford, E Miller
 October 2001;**85**:271–4. TOTAL HITS: **7225**

3 Recent advances in cystic fibrosis

I J M Doull
 July 2001;**85**:62–6. TOTAL HITS: **5566**

4 Breast feeding and cognitive development at age 1 and 5 years

N K Angelsen, T Vik, G Jacobsen, L S Bakketeig
 September 2001;**85**:183–8. TOTAL HITS: **5218**

5 An evidence and consensus based guideline for acute diarrhoea management

K Armon, T Stephenson, R MacFaul, P Eccleston, U Werneke, H Baumer
 August 2001;**85**:132–42. TOTAL HITS: **4988**

6 New pneumococcal vaccines for children

S Choo, A Finn
 April 2001;**84**:289–94. TOTAL HITS: **3944**

7 Idiopathic thrombocytopenic purpura and MMR vaccine

E Miller, P Waight, C P Farrington, N Andrews, J Stowe, B Taylor
 March 2001;**84**:227–9. TOTAL HITS: **3785**

8 Invasive procedures carried out in conscious children: contrast between North American and European paediatric oncology centres

R D W Hain, C Campbell, S Space, S Kharasch, H Bauchner
 July 2001;**85**:12–15. TOTAL HITS: **3389**

9 Screening and surveillance for autism and pervasive developmental disorders

June 2001;**84**:468–75. TOTAL HITS: **3321**

10 Varicella vaccination—a critical review of the evidence

August 2001;**85**:83–90. TOTAL HITS: **3088**