

CASE REPORT

Radial artery pseudoaneurysm successfully treated by compression bandage

D A Cozzi, F Morini, A Casati, M Pacilli, V Salvini, F Cozzi

Arch Dis Child 2003;**88**:165–166

In children, surgery for radial artery pseudoaneurysm (PA) may be followed by growth retardation of the hand because of inadequate blood flow. We believe this is the first report of a child with PA of the radial artery cured by compression bandage. Conservative management is a safe and valuable initial treatment option for uncomplicated radial PA.

In childhood, pseudoaneurysm (PA) may be caused by a wide variety of paravascular infectious, inflammatory, and traumatic processes that disrupt or destroy the arterial wall.¹ Penetrating trauma and injury from arterial cannulation account for the majority of patients. Although minor lacerations are common in children and adolescents, PA following uncomplicated penetrating injuries has rarely been described.²

Early surgical intervention is recommended when a PA of the radial artery is detected,^{1,4} whereas little consideration is

given to non-operative management. We present a child with traumatic PA of the radial artery cured by compression bandage; to our knowledge, this has not been previously mentioned among the conservative treatment approaches.

CASE REPORT

A 3 year old girl presented with sudden onset of a swelling in her right wrist. Two weeks before the appearance of this lump, she sustained a glass laceration of her right wrist which was sutured in an emergency room. On examination, a 2 cm diameter expansile mass at the radial aspect of the volar surface of the right wrist was found. The lesion was non-tender, round shaped, and contiguous to the wound site (fig 1A). A thrill was palpable and auscultation revealed a bruit. Motor and sensory examinations were unremarkable. Ultrasonography identified an anechoic mass measuring $15 \times 8 \times 15$ mm, and colour Doppler imaging showed a swirling pattern of internal flow consistent with PA of the radial artery (fig 2). A short and narrow neck between the PA and the patent radial artery was documented. Formal and modified Allen's test by means of Doppler flowmetry revealed a lack of continuity of the palmar arch.

A compression bandage was fashioned by applying a small rectangular pad over the swelling, and wrapping the wrist with an elastic bandage (Tensoplast, BSN medical Limited, Brierfield, UK). The bandage was considered firm enough if slight manual extra pressure resulted in hand discomfort.

Clinical and Doppler ultrasound reassessment after 72 hours showed a decrease in size of the PA and a thrombus formation. Repeat compression bandage was checked weekly until complete healing eventually occurred after three weeks (fig 1B). At two years follow up the girl remains symptom free, with normal growth and function of both hands.

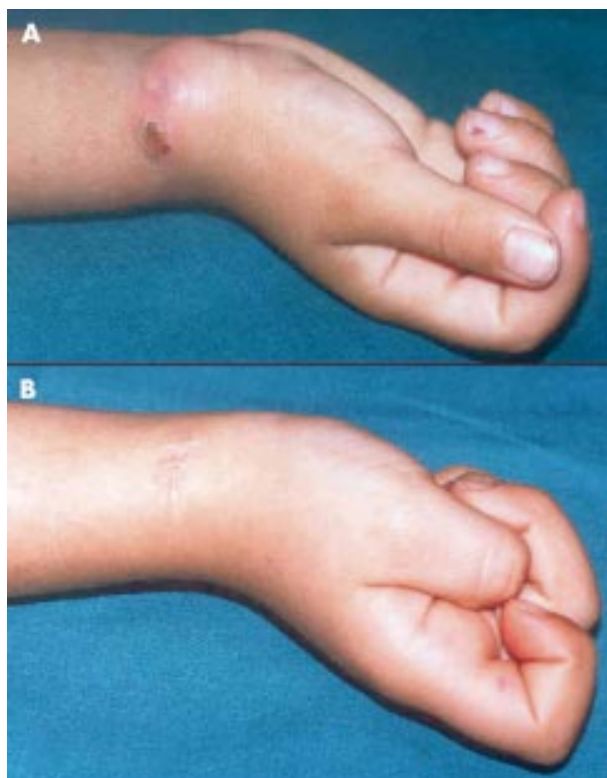

Figure 1 (A) Swelling at the right wrist contiguous to a healing scar from recent wound repair. (B) Complete wound healing and disappearance of the mass at the right wrist.

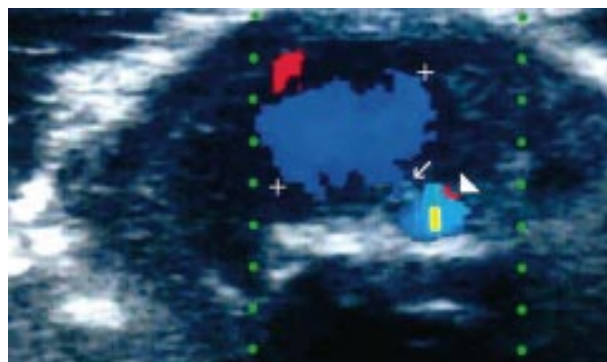


Figure 2 Colour Doppler imaging of the right wrist: cross section at the level of the palpable mass shows turbulent flow within the lesion (+ + +); narrow track (arrow) between the lesion, and the patent radial artery (arrowhead).

DISCUSSION

PA has a saccular appearance and occurs as the result of penetrating injury to the vessel, with resultant haemorrhage and haematoma. The false sac is lined with endothelium, and the outer walls are formed of fibrous scar tissue.³ PA of the distal upper extremity may mimic many other soft tissue masses. Therefore, diagnostic puncture of a wrist swelling may be unwise.³ The real incidence is unknown, probably because these lesions are seldom reported, especially in children.

The most common causes of radial PA in children and adolescents are penetrating trauma and iatrogenic arterial injury. These vascular lesions may occur within hours or months from the time of injury. Prompt surgery has been advocated in adults because of the potential risk of rupture and thromboembolism.³⁻⁴ However, current operative management after excision of radial PA remains controversial, with some authors advising vascular reconstruction, and others opting for arterial ligation.¹⁻⁴

Proponents of vascular reconstruction cite the possibility of elimination of complications, such as cold and work intolerance.³⁻⁴ Moreover, the importance of full restoration of the hand blood supply is stressed in children, to prevent retardation of extremities growth.¹⁻² Nevertheless, we are not aware of radial PA treated by vascular reconstruction during childhood.

Other authors support simple ligation of radial artery and excision of the PA if adequate collateral flow can be shown. This treatment strategy is considered satisfactory even in the paediatric population.¹⁻² Indeed, studies on lacerations of the arteries at the wrist, and radial artery harvesting for coronary artery bypass, have shown that the radial artery can be safely sacrificed in adults.⁵⁻⁶ However, preoperative investigation on palmar collateral circulation may be difficult to perform and to interpret, especially in children.⁷ Allen's test and its modifications are widely performed to evaluate adequacy of collateral hand circulation. The test was originally described in patients with thromboangiitis obliterans.⁸ The examiner compresses both radial or ulnar arteries for about one minute, while the patient closes both hands as tightly as possible to exanguinate the hands. Subsequently, the patient extends his or her fingers while the examiner maintains compression of the artery. The return of colour to the hand indicates absence of lesions in the artery not compressed. Unfortunately, the traditional Allen's test carries significant false positive and false negative results, and additional studies are needed to define the accuracy of some innovative non-invasive tests.⁶ Therefore, the gold standard investigation to assess an efficient collateral flow is still angiography, which is invasive and expensive.⁶

Conservative treatment has recently become a reliable alternative to surgical intervention in adults with PA following iatrogenic injury of the femoral artery. Available non-surgical measures rely on thrombus formation, and include ultrasound guided compression repair,⁹ reapplication of a compression bandage,¹⁰ and clinical observation of the natural course.¹⁰⁻¹¹ Ultrasound guided compression repair is a non-invasive technique characterised by manual compression of the PA with the transducer probe, maintained for 10 minute intervals, after which time the PA is rechecked for occlusion.⁹ If flow is still present, compression is quickly re-established for additional 10 minute intervals, until occlusion is achieved. Circulation is

maintained in the underlying artery, and care is taken to visualise flow and avoid occlusion throughout the procedure. However, the procedure is distressing for the patient and costly in terms of skilled manpower and sophisticated technical equipment.¹⁰ Reapplication of an occlusive bandage and waiting for spontaneous healing during a wait-and-see period may represent another treatment strategy.¹⁰ Furthermore, restriction of physical activity alone may be curative.¹¹ Surgery may be reserved for expanding, actively bleeding, or otherwise complicated lesions. However, operative intervention may be safely withheld in the majority of adult patients with uncomplicated post-catheterisation PA of the femoral artery.¹⁰

In children, reported experience with conservative management of radial PA is limited. Fields and colleagues¹² reported an infant with a small radial PA following arterial puncture, which resolved spontaneously. Our patient was successfully cured by simple compression bandage of the radial PA, and at two years follow up remains symptom free with symmetrical distal upper extremities.

In conclusion, non-operative management of uncomplicated PA of the radial artery is a safe and valuable treatment strategy that may be useful, especially in children and adolescents. Compression bandage provides a simple, non-invasive, and cost effective procedure which may be first line treatment for children with uncomplicated radial PA.

Authors' affiliations

D A Cozzi, F Morini, A Casati, M Pacilli, F Cozzi, Paediatric Surgery Unit, Policlinico Umberto I, University of Rome "La Sapienza", Rome, Italy
V Salvini, Paediatric Radiology Unit, University of Rome "La Sapienza"

Correspondence to: Dr D A Cozzi, S.S. Chirurgia Pediatrica, Policlinico Umberto I, Università degli Studi di Roma "La Sapienza", Viale Regina Elena, 324, 00161 Roma, Italy; da.cozzi@uniroma1.it

Accepted 23 July 2002

REFERENCES

- 1 **Sarkar R**, Coran AG, Cillely RE, et al. Arterial aneurysms in children: clinicopathologic classification. *J Vasc Surg* 1991;**13**:47-57.
- 2 **Zitsman JL**. Pseudoaneurysm after penetrating trauma in children and adolescents. *J Pediatr Surg* 1998;**33**:1574-7.
- 3 **Kerr CD**, Duffey TP. Traumatic false aneurysm of the radial artery. *J Trauma* 1988;**28**:1603-4.
- 4 **Turowski GA**, Amjadi N, Sterling A, et al. Aneurysm of the radial artery following blunt trauma to the wrist. *Ann Plast Surg* 1997;**38**:527-30.
- 5 **Johnson M**, Ford M, Johansen K. Radial or ulnar artery laceration. Repair or ligate? *Arch Surg* 1993;**128**:971-5.
- 6 **Starnes SL**, Wolk SW, Lampman RM, et al. Noninvasive evaluation of hand circulation before radial artery harvest for coronary artery bypass grafting. *J Thorac Cardiovasc Surg* 1999;**117**:261-6.
- 7 **Mercier FJ**, Basdevant C, De Tovar G, et al. Evaluation préopératoire par doppler de la prévalence des anomalies fonctionnelles de l'arcade palmaire chez l'enfant. *Ann Fr Anesth Reanim* 1994;**13**:785-8.
- 8 **Allen EV**. Thromboangiitis obliterans: methods of diagnosis of chronic occlusive arterial lesions distal to the wrist with illustrative cases. *Am J Med Sci* 1929;**178**:237-44.
- 9 **Cox GS**, Young JR, Gray BR, et al. Ultrasound-guided compression repair of postcatheterization pseudoaneurysms: results of treatment in one hundred cases. *J Vasc Surg* 1994;**19**:683-6.
- 10 **Schaub F**, Theiss W, Busch R, et al. Management of 219 consecutive cases of postcatheterization pseudoaneurysm. *J Am Coll Cardiol* 1997;**30**:670-5.
- 11 **Kresowik TF**, Khoury MD, Miller BV, et al. A prospective study of the incidence and natural history of femoral vascular complications after percutaneous transluminal coronary angioplasty. *J Vasc Surg* 1991;**13**:328-36.
- 12 **Fields JM**, Saluja S, Schwartz DS, et al. Hemophilia presenting in an infant as a radial artery pseudoaneurysm following arterial puncture. *Pediatr Radiol* 1997;**27**:763-4.