

ORIGINAL ARTICLE

Cranial MRI scans are indicated in all girls with central precocious puberty

S M Ng, Y Kumar, D Cody, C S Smith, M Didi

Arch Dis Child 2003;88:414–418

See end of article for authors' affiliations

Correspondence to: Dr S M Ng, Endocrinology Department, Royal Liverpool Children's Hospital, Liverpool L12 2AP, UK; ngszemay@yahoo.com

Accepted 14 August 2002

Aims: (1) To assess the value of cranial magnetic resonance imaging (MRI) scans in the investigation of girls with central precocious puberty (CPP); and (2) to determine the clinical predictors of abnormal cranial MRI scans in these patients.

Methods: A retrospective study of 67 girls diagnosed with CPP who underwent cranial MRI scans at diagnosis. Patients with neurological signs or symptoms at presentation were excluded.

Results: The mean age of onset of puberty was 6.2 years (range 2.0–7.9). Intracranial abnormalities were present in 10 (15%) patients (MR⁺), while 57 (85%) had no abnormalities (MR⁻). There was no statistical difference between MR⁺ patients and MR⁻ patients at presentation with respect to age of onset of puberty, pubertal stage, bone age advance, pelvic ultrasound findings, or height or body mass index standard deviation scores (SDS).

Conclusion: Girls with CPP should have a cranial MRI scan as part of their assessment since clinical features, including age, are not helpful in predicting those with underlying pathology. Implementation of such an approach may have a substantial effect on clinical practice and healthcare cost.

Idiopathic central precocious puberty (CPP) in girls is defined as the onset of secondary sexual characteristics before the age of 8 years because of premature activation of the hypothalamic–pituitary–gonadal axis.^{1–3} The majority of cases of CPP in girls are defined as idiopathic since no organic lesion is found, whereas intracranial lesions are common in boys with CPP.^{1–7} Studies have emphasised the importance of detecting intracranial causes of CPP in boys, but few have focused on its importance in girls with CPP.^{8–11} Determination of gonadotrophin levels following luteinising hormone releasing hormone (LHRH) stimulation does not help in identifying those patients with intracranial lesions.¹⁷

In recent years, cranial magnetic resonance imaging (MRI) has become the imaging method of choice in the assessment of central precocious puberty.^{8–12–13} The advent of MRI has made it possible to study the hypothalamic–pituitary area in greater detail compared with the computed tomography (CT) scan.^{6–8–14} MRI now allows the identification of previously unseen intracranial abnormalities in CPP, thus reducing the number of cases previously considered to be “idiopathic”. A few studies have suggested that there may be a higher incidence of intracranial cause of CPP in girls as a result of wider use of the MRI.^{6–8}

At our institution, cranial MRI has been done routinely in the investigation of girls with CPP since 1990. The purpose of this study was to evaluate the validity of this investigation and to assess the clinical features associated with abnormal MRI findings.

METHODS AND PATIENTS

We reviewed the records of 91 girls diagnosed with CPP in Alder Hey Children's Hospital between January 1990 to March 2001. We included in the study 67 girls who underwent cranial MRI scans to exclude intracranial causes. These patients were in good health without neurological signs or symptoms, and were not receiving any therapy for CPP.

Patients with precocity attributable to neurofibromatosis or other obvious intracranial pathology, central nervous system irradiation, trauma, or hydrocephalus were excluded. The diagnosis of CPP was based on clinical evaluation, assessment

of bone age, appearance of pelvic structures on ultrasound, LHRH stimulation test, and plasma oestradiol levels. Pubertal status was staged according to Tanner.¹⁵ Height and body mass index were expressed as standard deviation scores (SDS) with reference to British standards,¹⁶ and bone age was estimated by one of four consultant paediatric radiologists in the Department of Radiology using the RUS (TW2) system.¹⁷

Pelvic ultrasound examinations were performed at diagnosis by the full bladder technique obtained by voluntary urine retention following oral administration of fluids.² This was performed by one of three radiographers in the Department of Radiology trained in paediatric pelvic ultrasound assessments. The criteria for assigning appearances as pubertal as opposed to prepubertal were dependent on the appearance of the uterus, including the presence or absence of an endometrial echo.¹⁸

The LHRH test consisted of a basal sample of luteinising hormone (LH) and follicle stimulating hormone (FSH) followed by an intravenous dose of 100 µg LHRH (Intrapharm Laboratories, UK or Hoechst Marion Roussel). Repeat LH and FSH estimations were made at 30 and 60 minutes after the intravenous dose. The following biochemical parameters were used in assigning the response to stimulation with LHRH as a pubertal response: peak LH/FSH ratio greater than 1 or peak LH greater than 5U/l. However, the decision on whether a child was in true puberty was a clinical one based mainly on progression of features of puberty. Plasma oestradiol assay used from 1985 to 1995 was the double antibody radioimmunoassay (Diagnostic Products Ltd), and from 1995 onwards, the Bayer Immuno 1 automated assay.

Routine imaging was offered at this centre for all girls diagnosed with CPP since 1990. A mobile MRI unit was used between 1990 and 1995. The MRI examination was performed on 0.5 Tesla magnet (GE scanner) and on 0.5 Tesla magnet

Abbreviations: CPP, central precocious puberty; CT, computed tomography; FSH, follicle stimulating hormone; LH, luteinising hormone; LHRH, luteinising hormone releasing hormone; MRI, magnetic resonance imaging; SDS, standard deviation score

Table 1 Presenting features of MR⁺ patients

Patient	Aetiology	Age at onset of precocious puberty (y)	Tanner breast (B) and pubic hair (P) stages	Height (SDS)	Treatment
1	Hypothalamic hamartoma	7.8	B2 P2	0.6	LHRH analogue
2	Hypothalamic hamartoma	2.0	B3 P3	2.9	LHRH analogue
3	Hypothalamic hamartoma	3.1	B3 P2	3.0	LHRH analogue
4	Hypothalamic hamartoma	5.7	B3 P3	2.8	LHRH analogue
5	Hypothalamic hamartoma	2.3	B3 P3	2.7	LHRH analogue, surgery
6	Hypothalamic hamartoma	3.0	B3 P2	4.1	LHRH analogue
7	Hypothalamic astrocytoma	7.0	B3 P2	0.9	LHRH analogue, surgery, chemotherapy
8	Hypothalamic teratoma	4.3	B3 P2	-1.7	LHRH analogue
9	Arachnoid cyst	6.1	B2 P3	0.4	LHRH analogue, surgery
10	Pineal cyst	7.0	B3 P2	1.8	No treatment

SDS, standard deviation score.

(Phillips Gyronscan-NT) from 1995 to 2001. The age threshold for imaging has remained 8 years throughout the study period.

Patients with intracranial abnormalities (MR⁺) and patients without intracranial abnormalities (MR⁻) were evaluated for age at onset of puberty, advancement of bone age expressed as bone age minus chronological age, pubertal staging, height, body mass index, and pelvic ultrasound findings at presentation. Commencement of treatment with LHRH analogue was also documented.

Data were analysed using the statistical packages SPSS and StatsDirect. Fisher's exact test was used to compare differences in proportions for categorical variables. Two sampled *t* test was used to compare means between two groups for continuous variables; 95% confidence intervals were calculated and a probability value less than 0.05 were considered statistically significant.

RESULTS

Sixty seven girls satisfied the inclusion criteria for the study. The mean age of reported onset of precocious puberty was 6.2

years (range 2.0–7.9). No imaging abnormalities were found in 57 (85%) girls (MR⁻ patients). An intracranial abnormality to account for CPP was present in 10 (15%) patients (MR⁺ patients) (see table 1). A diagnosis of hypothalamic hamartoma was made in six patients and a hypothalamic teratoma diagnosed in one patient on the basis of neuroradiological appearances. One patient had a significantly large pineal cyst (greater than 10 mm), one had a large arachnoid cyst, and one had a hypothalamic pilocytic astrocytoma (histological diagnosis). None of these patients had neurological abnormalities at initial presentation.

The two patients who were diagnosed with the arachnoid cyst and the hypothalamic pilocytic astrocytoma required surgical intervention at a later stage. The patient with a large arachnoid cyst (fig 1) needed surgery because the large cyst seemed under tension and was distorting the brain stem. The patient with the hypothalamic pilocytic astrocytoma, grade 1 (fig 2) required surgery because detailed ophthalmic assessment revealed early abnormalities of colour vision, even

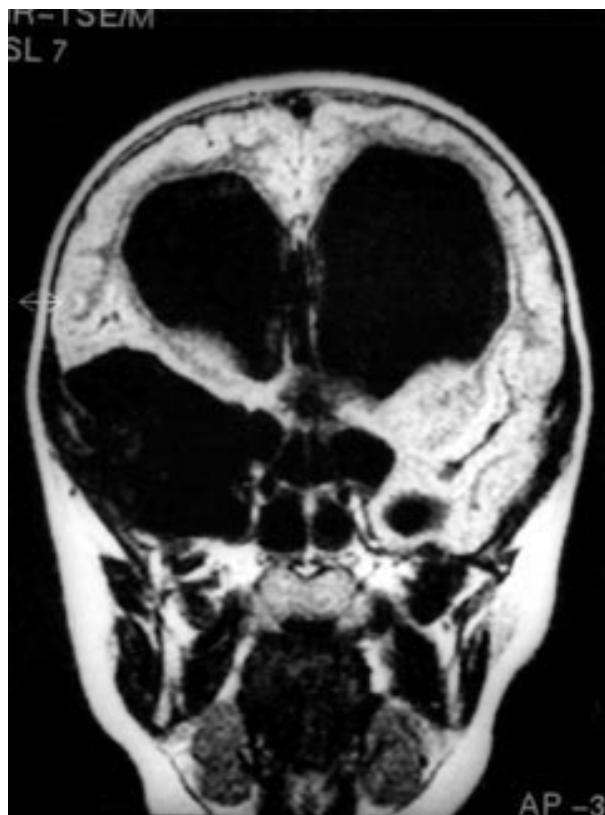


Figure 1 Large arachnoid cyst.

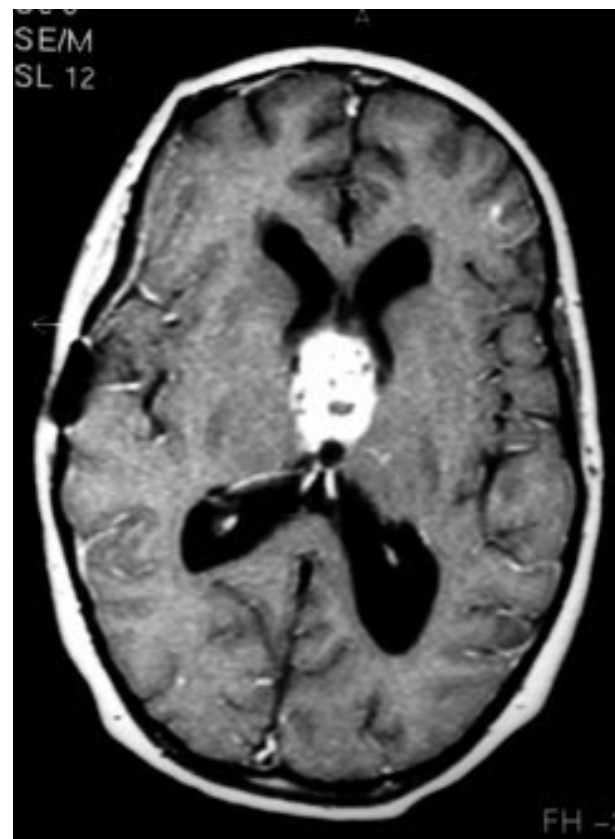

Figure 2 Hypothalamic pilocytic astrocytoma.

Table 2 Presenting features of MR⁺ versus MR⁻ patients

Features	Category	MR ⁺ patients n=10 (%)	MR ⁻ patients n=57 (%)	Difference (95% CI)	p value
Age at beginning of precocious puberty (y)	≤4	4 (40)	8 (14)	26% (0.00 to 0.56)	0.07
	>4	6 (60)	49 (86)		
*Bone age—chronological age (y)	≤2	1 (10)	18 (37)	-27% (-0.45 to 0.06)	0.145
	>2	9 (90)	31 (63)		
Tanner Breast stage	1 and 2	2 (20)	22 (39)	-19% (-0.39 to 0.15)	0.311
	3 and 4	8 (80)	35 (61)		
Pubic hair stage	1 and 2	6 (60)	35 (61)	-1% (-0.33 to 0.26)	1.000
	3 and 4	4 (40)	22 (38)		
Height SDS, mean (SEM)		1.69 (0.54)	1.17 (0.16)	0.52 (-1.77 to 0.73)	0.374
Body mass index SDS, mean (SEM)		0.89 (0.24)	0.67 (0.13)	0.22 (-0.79 to 0.36)	0.431
*Ultrasound pelvis	Prepubertal	8 (80)	46 (81)	-1% (-0.33 to 0.19)	1.000
	Pubertal	2 (20)	11 (19)		
Treatment started		9 (90)	45 (79)	11% (-0.21 to 0.27)	0.673
Treatment not started		1 (10)	12 (21)		

*Data not available for some patients.
SDS, standard deviation score; SEM, standard error mean.

though this was not demonstrable at the bedside. In addition, one patient who was diagnosed to have a large hypothalamic hamartoma required surgery because neurosurgeons were concerned about the impending effects on visual fields as a result of the large mass in close proximity to the optic nerves, even though there was no abnormality on formal ophthalmic assessment.

Table 2 summarises presenting features of MR⁺ and MR⁻ patients. The mean bone age advancement was similar in both groups. All girls had a history of accelerated growth at the time of presentation and mean bone age advancement was 2.4 years compared with chronological age. No significant difference was shown for age of onset of puberty, pubertal staging, height SDS, or body mass index SDS between the two groups. Five girls in the MR⁻ group had experienced menarche at the time of diagnosis.

Findings on pelvic ultrasound were similar in both groups. Seventy nine per cent of MR⁻ patients and 90% of MR⁺ patients received LHRH analogue treatment. The rationale for the decision to start treatment was made on an individual basis, largely based on the psychosocial problems, especially the frequency of mood changes associated with the early onset of puberty.

DISCUSSION

The prevalence of intracranial pathology in this series was 15%. Several other studies based on high resolution computed tomography (CT) and MRI scans have reported on the incidence of neurological lesions in central precocious puberty in girls, ranging from 21% to 49%.^{7, 8, 19} However, this is the first study indicating that clinical features, including the age of onset of puberty, are not a good indicator of underlying pathology in girls with CPP presenting without any neurological signs or symptoms.

Several studies have reported on the incidence of hypothalamic hamartomas in patients with isosexual precocious puberty, varying from 14% to 58%.^{7, 9, 14, 19} Hypothalamic hamartoma is the most common tumour causing CPP in our cohort of patients, accounting for 6 out of 10 (60%) of the abnormal MRI findings. This is in agreement with previous studies.⁶⁻⁸ The apparent association between hypothalamic hamartoma and CPP is still not completely understood.^{6, 20} It may be caused by abnormal migration of neurones producing

LHRH, or it may activate puberty early by acting on LHRH hypothalamic cells.²¹ However, Jung *et al* did not find LHRH producing neurones in material obtained from two hypothalamic hamartomas.²²

One of our patients, aged 3 years, had a large hypothalamic hamartoma which required surgery to remove the lesion because of impending risk to the optic nerves. A large arachnoid cyst of the third ventricle was diagnosed in a 6.8 year old girl who required surgical intervention. A hypothalamic pilocytic astrocytoma was diagnosed in a 7.9 year old girl who required both surgical intervention and chemotherapy. The two latter lesions are considered to be rare associations with CPP in girls.

A clinically significant pineal cyst was found in one patient, and a lesion whose radiological features were consistent with a hypothalamic teratoma was found in another. Seven patients did not receive any treatment directed at the lesion. They were closely followed up with serial MRI imaging. All seven lesions were non-progressive and the patients in this group remained well.

In our study, there was no clear difference between patients with intracranial lesions compared to patients without intracranial lesions with respect to age of onset of puberty, pubertal staging, height or body mass SDS at presentation, bone age advancement, or ultrasound findings. Clinical features were not helpful in predicting abnormal MRI scans in these girls. This was consistent with findings by Lyon *et al* on isosexual CPP in 39 girls with precocious puberty starting before the age of 7 years.⁷ In contrast, a study of 62 children with CPP by Kornreich *et al* found that age younger than 5 years, rapid advancement of pubertal signs, and bone age advancement were related to a higher incidence of patients who had abnormal CT and/or MRI findings.⁸ This was supported by findings of Cacciari and colleagues.¹⁴ A recent large study by Cisternino *et al* found that 16% of girls aged 7–7.9 years with CPP have a neurological lesion; the appearance of sexual characteristics in this age group accounted for 60% of patients with CPP.²³ Another recent study by Chemaitilly *et al* found that girls with organic lesions started their puberty earlier and had higher LH and FSH peaks compared to those with idiopathic CPP.²⁴ We were unable to confirm this observation in our study. Age at onset of puberty was not a predictor in our series. Two of the patients who required treatment directed at the lesions were girls over 6 years of age.

The advent of wider use and higher resolution of cranial MRI has identified previously undiagnosed intracranial pathology as a possible aetiology for CPP. This will lead to a decrease in cases previously defined as "idiopathic".²⁵ The role of cranial MRI in the routine assessment of idiopathic CPP in girls has been considered to be debatable. The decision is often weighed between increased healthcare cost resulting from indiscriminate use of MRI scans and the benefits of early identification of intracranial pathology.

Our study identified 15% of girls with CPP to have an intracranial cause for their condition without any neurological signs or symptoms at presentation. Three of the 10 girls had lesions which required surgery, suggesting that the onset of sexual precocity was the initial clue to their intracranial pathology. This is significant in that a delay in diagnosis impacting on the outcome is likely if cranial MRI scans are not used routinely to investigate these children. We suggest that this risk justifies the continued use of cranial MRI scan as a first line investigation in girls with CPP, especially because of the considerable dose of radiation associated with computed tomography scans. Implementation of such an approach by clinicians could have a substantial effect on clinical practice and healthcare cost.

Authors' affiliations

S M Ng, Y Kumar, D Cody, C S Smith, M Didi, Endocrinology Department, Royal Liverpool Children's Hospital, Liverpool, UK

REFERENCES

- 1 Sigurjonsdottir TJ, Hayles AB. Precocious puberty. A report of 96 cases. *Am J Dis Child* 1968;**115**:309–21.
- 2 Baek-Jensen AM, Brocks V, Holm K, et al. Central precocious puberty in girls: internal genitalia before, during, and after treatment with long-acting gonadotrophin-releasing hormone analogues. *J Pediatr* 1998;**132**:105–8.
- 3 Chaussain JL, Couprie C, Lacaille F, et al. Growth and precocious puberty. *Acta Paediatr Scand* 1988;**347**(suppl):38–43.
- 4 Wheeler MD, Styne DM. Diagnosis and management of precocious puberty. *Pediatr Clin North Am* 1990;**37**:1255–69.
- 5 Fontoura M, Brauner R, Prevot C, et al. Precocious puberty in girls: early diagnosis of a slowly progressing variant. *Arch Dis Child* 1989;**64**:1170–6.
- 6 Robben SGF, Oostdijk W, Drop SLS, et al. M. Idiopathic isosexual central precocious puberty: magnetic resonance findings in 30 patients. *Br J Radiol* 1995;**68**:34–8.
- 7 Lyon AJ, De Bruyn R, Grant DB. Isosexual precocious puberty in girls. *Acta Paediatr Scand* 1985;**74**:950–5.
- 8 Kornreich L, Horev G, Blaser S, et al. Central precocious puberty; evaluation by neuroimaging. *Pediatr Radiol* 1995;**25**:7–11.
- 9 Rieth KG, Comite F, Dweyer AJ. CT of cerebral abnormalities in precocious puberty. *AJR* 1987;**148**:1231–5.
- 10 Judge DM, Kulin HE, Page R, et al. Hypothalamic hamartoma and luteinising hormone release in precocious puberty. *N Engl J Med* 1977;**296**:7–10.
- 11 Mansfield MJ, Beardsworth DE, Loughlin IS. Long term treatment of central precocious puberty with long acting analogue of luteinising hormone releasing hormone; effect on somatic growth and skeletal maturation. *N Engl J Med* 1983;**309**:1286–90.
- 12 Gupta R, Ammini AC. Precocious puberty with pituitary gland hyperplasia; two cases in one family. *Pediatr Radiol* 1996;**26**:418–20.
- 13 Kao SCS, Cook JS, Hansen JR, et al. MR imaging of the pituitary gland in central precocious puberty. *Pediatr Radiol* 1992;**22**:481–4.
- 14 Cacciari E, Zucchini S, Carla G, et al. Endocrine function and morphological findings in patients with disorders of the hypothalamic-pituitary area: a study with magnetic resonance. *Arch Dis Child* 1990;**65**:1199–202.
- 15 Odel WD. Puberty. In: DeGroot LJ, ed. *Endocrinology*. Philadelphia: Saunders, 1989.
- 16 Freeman JV, Cole TJ, Chinn S, et al. Cross-sectional stature and weight reference curves for the UK. *Arch Dis Child* 1995;**73**:17–24.
- 17 Tanner JM, Whitehouse RH. Prediction of adult height for height, bone age and occurrence of menarche at ages 4 to 16 with allowance for midparental height. *Arch Dis Child* 1975;**50**:14–26.
- 18 Griffin IJ, Cole TJ, Duncan KA, et al. Pelvic ultrasound measurements in normal girls. *Acta Paediatr* 1995;**84**:536–43.
- 19 Cacciari E, Frejville E, Cicognani E. How many cases of true precocious puberty in girls are idiopathic. *J Pediatr* 1983;**102**:357–60.
- 20 Hockman HI, Judge DM, Reichlin S. Precocious puberty and hypothalamic hamartoma. *Pediatrics* 1981;**67**:236–44.
- 21 Debeneix C, Bourgeois M, Trivin C, et al. Hypothalamic hamartoma: comparison of clinical presentation and magnetic resonance images. *Horm Res* 2001;**56**:12–18.
- 22 Jung H, Carmel P, Schwartz MS, et al. Some hypothalamic hamartomas contain transforming growth factor, a puberty-inducing growth factor but no luteinizing hormone-releasing hormone neurons. *J Clin Endocrinol Metab* 1999;**84**:4695–701.
- 23 Cisternino M, Arrigo T, Pasquino AM, et al. Etiology and age incidence of precocious puberty in girls: a multicentre study. *J Pediatr Endocrinol Metab* 2000;**13**:695–701.
- 24 Chemaitilly W, Trivin C, Adan L, et al. Central precocious puberty: clinical and laboratory features. *Clin Endocrinol* 2001;**54**:289–94.
- 25 Zucchini S, Di Natale B, Ambrosetto P, et al. Role of magnetic resonance imaging in hypothalamic-pituitary disorders. *Horm Res* 1995;**44**(suppl):8–14.

COMMENTARY

Puberty results from increased activity of the hypothalamic gonadotrophin releasing hormone (GnRH) pulse generator. Outward signs of puberty usually occur around the age of 11 years. although pulsatile LH and FSH secretion can be shown some two years prior to this.¹

Precocious and early puberty are defined as true puberty with onset before 8 years in girls and 9 years in boys, at 8–10 years in girls and 9–11 years in boys respectively. Precocious puberty is relatively common in girls in whom it is usually idiopathic, and uncommon in boys in whom there is a much higher chance of finding pathology.²

Early and precocious puberty are seen in association with disorders of the central nervous system (CNS) such as spina bifida and hydrocephalus, cerebral palsy, and previous periventricular haemorrhage related to prematurity. Other causes include low dose cranial irradiation, exposure to increased androgen levels (for example, in simple virilising 21-hydroxylase deficiency), and tumours either adjacent to or within the hypothalamus. CNS disorders and tumours adjacent to the hypothalamus are believed to impair inhibitory pathways to the GnRH pulse generator, whereas hamartomas within the hypothalamus, which are congenital heterotopic masses of nervous tissue rather than neoplasms, may contain GnRH secreting neurones.³ Hypothalamic hamartomas are non-progressive and do not usually require removal, unless causing problems with mass effect on adjacent structures such as the optic nerves, or intractable gelastic (laughing) seizures. Tumours adjacent to the hypothalamus, such as suprasellar germinomas and optic glioma, may cause growth hormone deficiency as well as precocious puberty, so that the growth response to puberty will be impaired.⁴

Magnetic resonance imaging (MRI) is now recognised as superior to computerised tomography (CT) in neuroimaging. Use of MRI in children with central precocious puberty has been shown to increase the detection rate of abnormalities in the hypothalamo-pituitary region which might have been missed by previous techniques.^{5,6}

It is widely accepted that all boys with precocious and early puberty should undergo cranial imaging given the likelihood of finding an underlying lesion. The rarity of the condition in boys means that there are no resource implications with this dictum.

Deciding on an age cut off for girls with apparently idiopathic precocious and early puberty is more difficult. In *Williams' textbook of endocrinology*, the veteran paediatric endocrinologists Melvin Grumbach and Dennis Styne write "Many girls age 6 to 8 with idiopathic precocious puberty represent the left-hand end of the bell-shaped curve for the onset of normal puberty and are examples of early normal puberty. There may be a history of early maturation in the family".⁷ In the light of this statement and the fact that precocious and early puberty in girls is relatively common, is there a place for scanning particularly young subjects (for example, <6 years) routinely and adopting a more selective approach in girls older than this?⁸

Ng *et al* report their findings in 67 girls diagnosed with central precocious puberty, all of whom underwent MRI scanning between 1990 and 2001. Ten (15%) of the 67 girls showed intracranial abnormalities on MRI scanning, and there was no statistical difference between these patients and the remaining children in terms of clinical features, including age of onset at puberty. Their findings are similar to a large Italian study in which CT or MRI abnormalities were found in 56/304 (18.4%) of girls with central precocious puberty.⁹ How should these studies influence our practice with regard to the selection of girls for intracranial imaging?

Inspection of the data of Ng *et al* indicates that although age at onset of puberty was not statistically significant between the MRI positive and negative girls, the former group were young, with onset of precocious puberty at a median age of 5 years. Of the six girls with hypothalamic hamartoma, all but one was aged 5.7 years or less at presentation. The sixth child was 7.8 years old and did not require surgery. The four girls with other lesions included two aged 4.3 and 6.1 years, a girl aged 7.0 years at presentation with a pilocytic astrocytoma who required surgery although not immediately after presentation, and one with a pineal cyst at 7.0 years requiring no treatment. In summary, of the 67 girls scanned in this study, only one patient aged over 6 years required surgery, and this was "at a later stage", implying that there were clinical features meriting intervention.

Nevertheless, the findings of this and other studies, together with the non-invasive and safe nature of MRI and its superiority over CT scanning in detecting subtle lesions, indicate that MRI imaging in girls as well as boys with precocious puberty should now be recommended as good practice. However, as the authors point out, this policy has resource implications, and in the UK some families may have to wait several months for the procedure. In this situation it is important to reassure parents that the chance of finding a lesion requiring surgery in a girl with precocious puberty and no adverse clinical features is actually very small.

Any cut off age for imaging in precocious and early puberty will be arbitrary (the 7.8 year old girl in Ng *et al*'s study might not have been scanned had she presented after the age of 8 years). Moreover, MRI facilities are not available in all countries. Clinical examination, therefore, remains important. The history should include an enquiry about headache, visual

disturbance, and polydipsia, as well as details as to the age of menarche in the mother and older siblings; examination should include careful pubertal staging, assessment of height status in relation to the parental heights, and scoring of skeletal maturity by a skilled observer. It is also important to look for cutaneous signs, such as the café au lait patches of neurofibromatosis, to examine the visual fields, and to inspect the fundi for signs of optic nerve atrophy and papilloedema. The diagnosis of true puberty should be confirmed with a GnRH test before cranial imaging and treatment are contemplated.

Finally, patients who fall below the mid-parental height, indicating a poor growth response to puberty, should undergo both cranial imaging and full pituitary evaluation, irrespective of age and sex.

M D C Donaldson

Department of Child Health, Royal Hospital for Sick Children, Yorkhill, Glasgow, UK

REFERENCES

- 1 **Wu GCW**, Butler GE, Kelnar CJH, *et al*. Ontogeny of pulsatile gonadotropin releasing hormone secretion from childhood, through puberty, to adulthood in the human male: a study using deconvolution analysis and an ultrasensitive immunofluorometric assay. *J Clin Endocrinol Metab* 1996;**81**:1798–805.
- 2 **Bridges BA**, Christopher JA, Hindmarsh PC, *et al*. Sexual precocity: sex incidence and aetiology. *Arch Dis Child* 1994;**70**:116–18.
- 3 **Mahachoklerwattana P**, Kaplan SL, Grumbach MM. The luteinizing hormone-releasing hormone-secreting hypothalamic hamartoma is a congenital malformation: natural history. *J Clin Endocrinol Metab* 1993;**77**:118–24.
- 4 **Brauner R**, Malandry F, Rappaport R, *et al*. Growth and endocrine disorders in optic glioma. *Eur J Pediatr* 1990;**149**:825–8.
- 5 **Zucchini S**, di Natale B, Ambrosetto P, *et al*. Role of magnetic resonance imaging in hypothalamic-pituitary disorders. *Horm Res* 1995;**44**(suppl 3):8–14.
- 6 **Robben SG**, Oostdijk W, Drop SL, *et al*. Idiopathic isosexual central precocious puberty: magnetic resonance imaging in 30 patients. *Br J Radiol* 1995;**68**:34–8.
- 7 **Grumbach MM**, Styne DM. Puberty: ontogeny, neuroendocrinology, physiology, and disorders. In: Wilson JD, Foster DW, Kronenberg HM, Reed Larson P, eds. *Williams textbook of endocrinology*, 9th edn. Saunders, 1998:1509–626.
- 8 **Raine JE**, Donaldson MDC, Gregory JW, Savage MO. Puberty. In: *Practical endocrinology and diabetes in children*. Blackwell Science, 2001:65–84.
- 9 **Cisternino M**, Arrigo T, Pasquino AM, *et al*. Etiology and age incidence of precocious puberty in girls: a multicentric study. *J Pediatr Endocrinol* 2000;**13**(suppl 1):695–701.