

Determination of sex

Early assessment of ambiguous genitalia

A L Ogilvy-Stuart, C E Brain

A multidisciplinary problem

To discover that there is uncertainty about the sex of one's newborn baby is devastating and often incomprehensible for most parents. It is paramount that clear explanations and investigations are commenced promptly, and that no attempt is made to guess the sex of the baby. Extreme sensitivity is required, and ideally the baby should be managed in a tertiary centre by a multidisciplinary team including a paediatric endocrinologist and a paediatric urologist. Early involvement of a clinical psychologist with experience in this field should be mandatory. Other professionals including geneticists and gynaecologists may also become involved. There must be access to specialist laboratory facilities and experienced radiologists. The incidence of genital ambiguity that results in the child's sex being uncertain is 1 per 4500,¹ although some degree of male undervirilisation, or female virilisation may be present in as many as 2% of live births.²

Parents require reassurance that either a male or female gender will definitely be assigned. However the outcome of some of the investigations may take some weeks, and registration of the child's birth should be deferred until gender has been assigned. This may require communication with the Registrar of Births, and a skilled clinical psychologist will help the parents in deciding what to tell family and friends in the interim. It is also helpful (if appropriate) to reassure the parents that their child is otherwise healthy.

While not all intersex conditions are apparent at birth (for example, complete androgen insensitivity may only become apparent in a child with a testis within an inguinal hernia, or at puberty with primary amenorrhoea and lack of androgen hair), only those presenting with genital ambiguity at birth will be considered in this article.

An understanding of sex determination and differentiation is essential to direct appropriate investigations and to establish a diagnosis.

Genetic sex is determined from the moment of conception and determines

the differentiation of the gonad. The differentiation of the gonad in turn determines the development of both the internal genital tracts and the external genitalia and thus *phenotypic sex*, which occurs later in development (from about 5–6 weeks of gestation). Both male and female genitalia differentiate from the same structures along the urogenital ridge. At about 4 weeks after fertilisation, primordial germ cells migrate from the yolk sac wall to the urogenital ridge that develops from the mesonephros. The urogenital ridge also contains the cells that are the precursors for follicular or Sertoli cells and steroid producing theca and Leydig cells. The "indifferent" gonads form on the genital ridges.

The development of the fetal adrenals and gonads occur in parallel, as before migration, the potential steroidogenic cells of both originate from the mesonephros. There are many genes and transcription factors that are expressed in both tissues (for example, SF1 and DAX1), and hence mutations in these genes may affect both adrenal and gonadal development (fig 1). In addition, WT1 is expressed in the kidney and gonad, hence the association of Wilms' tumour and gonadal dysgenesis in Denys-Drash syndrome, for example.

The undifferentiated gonad is capable of developing into either an ovary or a testis. The theory that the "default" programme generates an ovary is probably not correct, although the exact role of "ovarian determining" genes in humans is unclear at present. In contrast, testicular development is an active process, requiring expression of the primary testis determining gene SRY, and other testis forming genes such as SOX9. Transcription factors such as SF1 and WT1 are also required for development of the undifferentiated gonad, as well as for the activation of the other male pathway genes required for testis development and the consequent development of male internal and external genitalia.³

DAX1 and Wnt 4 are two genes that may act to "antagonise" testis development. Over-expression of DAX1

(through duplication of Xp21) and Wnt4 (through duplication of 1p35), have been associated with impaired gonadal development and undervirilisation in a small number of karyotypic 46 XY males.

Mutations or duplications in the various genes responsible for gonadal differentiation and the subsequent development of the internal and external genital phenotype genes may be responsible for gonadal dysgenesis and in some cases complete sex reversal (table 1).

Wnt4 is also expressed in the Müllerian ducts and in the absence of anti-Müllerian hormone (AMH) (also known as Müllerian inhibiting substance) and testosterone, Müllerian structures develop, while the Wolffian ducts involute.⁴ AMH promotes regression of Müllerian structures and as the only source of AMH in the fetus is the testes, the absence of a uterus in a baby with ambiguous genitalia is evidence that there has been functional testicular tissue (Sertoli cell) present. Testosterone produced from Leydig cells promotes differentiation of the Wolffian ducts and hence the internal male genitalia (vas deferens, epididymis, and seminal vesicles).

Testosterone is converted to dihydrotestosterone [DHT] by the enzyme 5 α -reductase. DHT masculinises the external genitalia from about 6 weeks gestation, and the degree of masculinisation is determined by the amount of fetal androgen present (irrespective of source) and the ability of the tissues to respond to the androgens.

Defects in any part of this pathway (including gene mutations and chromosomal abnormalities (for example, 46XY/46XX, 45X/46XY), inappropriate hormone levels, or end-organ unresponsiveness) may result in genital ambiguity, with undervirilisation of an XY individual, virilisation of an XX individual, or the very rare true hermaphrodite (an individual with both ovarian tissue with primary follicles and testicular tissue with seminiferous tubules which may be in separate gonads or ovotestes).

CLINICAL ASSESSMENT OF AMBIGUOUS GENITALIA

History

The history should include details of the pregnancy, in particular the use of any

Abbreviations: AMH, anti-Müllerian hormone; CAH, congenital adrenal hyperplasia; DHEA, dehydroepiandrosterone; DHEAS, dehydroepiandrosterone sulphate; DHT, dihydrotestosterone; EUA, examination under anaesthesia; hCG, human chorionic gonadotrophin; StAR, steroidogenic acute regulatory protein

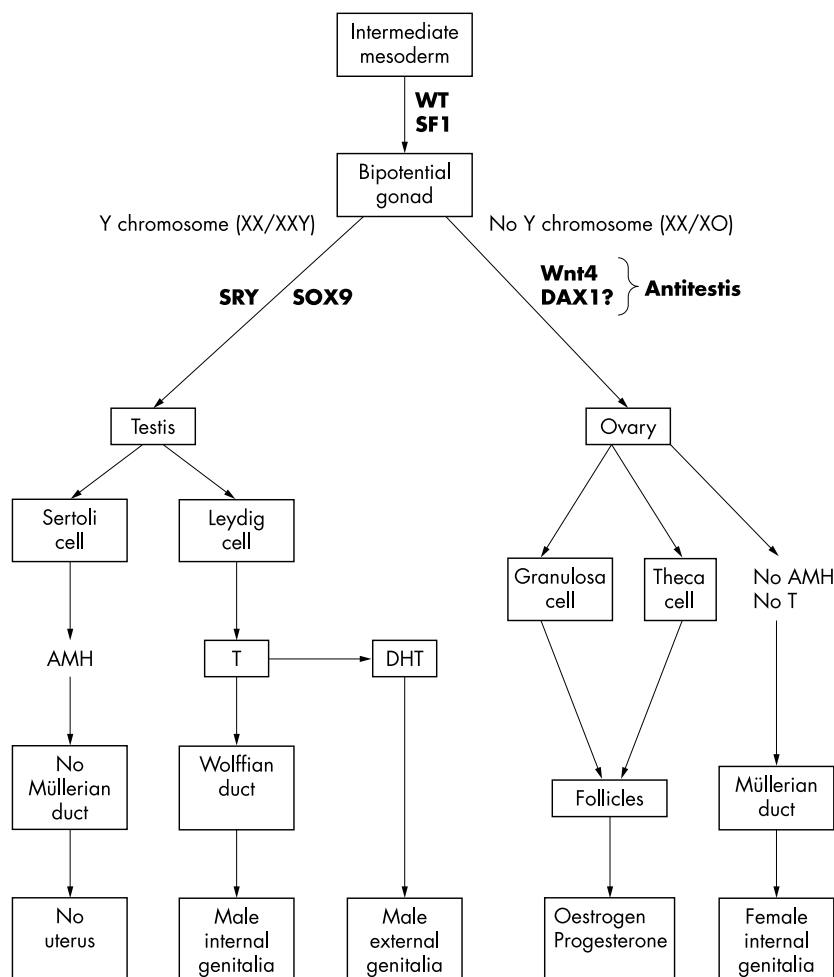


Figure 1 Normal sexual differentiation. SRY, sex determining region on Y chromosome; TDF, testis determining factor; AMH, anti-Müllerian hormone; T, testosterone; DHT, dihydrotestosterone; WT1, Wilms’ tumour suppressor gene; SF1, steroidogenic factor 1; SOX9, SRY-like HMG-box; Wnt4, Wnt=a group of secreted signalling molecules that regulate cell to cell interactions during embryogenesis; DAX1, DSS-AHC critical region on the X chromosome.

drugs (table 2) that may cause virilisation of a female fetus and details of any previous neonatal deaths (which might point to an undiagnosed adrenal crisis). A history of maternal virilisation may suggest a maternal androgen secreting tumour or aromatase deficiency. A detailed family history should be taken, including whether the parents are consanguineous (which would increase the probability of an autosomal recessive condition) or if there is a history of genital ambiguity in other family members (for example, an X-linked recessive condition such as androgen insensitivity).

Examination

The general physical examination should determine whether there are any dysmorphic features and the general health of the baby. A number of syndromes are associated with ambiguous genitalia, for example, Smith-Lemli-Opitz syndrome (characterised by hypocholesterolaemia and elevated 7-dehydrocholesterol levels, and resulting from mutations affecting 7-dehydrocholesterol reductase), Robinow syndrome, Denys-Drash syndrome, and Beckwith-Wiedemann syndrome. Midline defects may point towards a hypothalamic-pituitary cause for micropenis and cryptorchidism. Hypoglycaemia may indicate cortisol deficiency secondary to hypothalamic-pituitary or adrenocortical insufficiency. The state of hydration and blood pressure should be assessed as various forms of congenital adrenal hyperplasia (CAH) can be associated with differing degrees of salt loss, varying degrees of virilisation in girls or undervirilisation in boys,

Table 1 Consequences of mutations/deletions and duplications/translocations of genes involved in gonadal differentiation

Gene mutation or deletion (loss of function)	Chromosome location	Gonadal development	Associated disorder	Sex reversal/genital ambiguity	Müllerian development
WT1	11p13	Dysgenesis (♀ and ♂)	WAGR syndrome Denys-Drash syndrome	Genital ambiguity (♂) Sex reversal or genital ambiguity (♂)	Variable (♂) Variable (♂)
SF1	9q33	Dysgenesis (♂)	Frasier syndrome Adrenal failure	Sex reversal (♂) Sex reversal (♂)	Yes (♂) Yes (♂)
SRY	Yp11.3	♂ → ovary		Sex reversal or genital ambiguity (♂)	♂ (variable)
DAX1	Xp21	♂ Dysgenesis	Adrenal failure and hypogonadotropic hypogonadism/impaired spermatogenesis	No	No
SOX9	17q24.3–25.1	♂ Dysgenesis or ovary/ovotestis	Campomelic dysplasia	Sex reversal or genital ambiguity (♂)	Variable
AMH	19p 13.3–13.2	Normal			Yes (♂)
Gene duplication or translocation (gain of function)					
SRY Y fragment translocation	Yp11.3	♀ → testis		Sex reversal or genital ambiguity (♀)	No
DAX1 duplication	dupXp21	♂ Dysgenesis or ovary/ovotestis		Sex reversal or genital ambiguity (♂)	Variable
Wnt 4 duplication	Dup 1p35	♂ Dysgenesis		Genital ambiguity (♂)	Yes
SOX9 duplication	dup17q24.3–25.1	♀ → Testis		Genital ambiguity (♀)	No

WAGR, Wilms’ tumour, aniridia, genitourinary anomalies, mental retardation; Denys-Drash (exonic mutations) WT, diffuse mesangial sclerosis; Frasier (intronic mutations) no WT, focal segmental glomerulosclerosis. Other abbreviations as for fig 1.

Table 2 Disorders of sex differentiation**Virilisation of XX females**

Increased fetal adrenal androgen production
 Congenital adrenal hyperplasia (3 β -hydroxysteroid dehydrogenase deficiency, 21-hydroxylase deficiency, 11 β -hydroxylase deficiency)
 Androgen secreting tumour
 Placental aromatase deficiency
 Fetal gonadal androgen production
 True hermaphrodite with both testicular and ovarian tissue
 Transplacental passage of maternal androgens
 Drugs administered during pregnancy: e.g. progesterone, danazol
 Maternal androgen secreting tumour, luteoma of pregnancy
 Other causes
 Dysmorphic syndromes
 Prematurity—prominent clitoris
 Bisexual gonads
 Hermaphroditism. Usual genotype 46XX

Undervirilisation of XY males

Testicular dysgenesis/malfunction
 Pure XY gonadal dysgenesis
 Mixed gonadal dysgenesis—45X/46XY. May be associated with gene mutations on SRY, SOX9, or WT1 genes
 Dysgenetic testis
 Testicular regression syndromes
 True agonadism, rudimentary testis syndrome
 Biosynthetic defect—decreased fetal androgen biosynthesis
 Leydig cell hypoplasia (LH deficiency or LH receptor defect)
 Testosterone biosynthesis (non-virilising CAH): (StAR, 3 β -HSD, 17 α -OHD/17–20 lyase, Smith-Lemli-Opitz syndrome)
 5 α -reductase deficiency
 Deficient synthesis or action of AMH—persistent Müllerian duct syndrome. May be due to mutations in AMH or AMH receptor gene or SF1 gene
 End organ unresponsiveness
 Androgen receptor and post-receptor defects (complete and incomplete androgen insensitivity syndrome)
 Others
 Urogenital malformations
 Dysmorphic syndromes
 Exogenous maternal oestrogens

or hypertension (table 3). Although the cardiovascular collapse with salt loss and hyperkalaemia in congenital adrenal hyperplasia does not usually occur until between the 4th to 15th day of life and so will not be apparent at birth in a well neonate, it should be anticipated until CAH has been excluded. Jaundice (both conjugated and unconjugated) may be caused by concomitant thyroid hormone or cortisol deficiency. The urine should be checked for protein as a screen for any associated renal anomaly (for example, Denys-Drash/Frasier syndromes).

Examination of external genitalia and Prader staging

Examination of the external genitalia determines whether gonads are palpable and the degree of virilisation or Prader stage. Prader stages I–V describe increasing virilisation from a phenotypic female with mild cliteromegaly (stage I) to a phenotypic male with glandular hypospadias (stage V) (fig 2).

If both gonads are palpable they are likely to be testes (or ovotestes) which may be normal or dysgenetic. Flat finger palpation from the internal ring milking down into the labial scrotal folds may

detect the presence of a gonad. They may be situated high in the inguinal canal so careful examination is required. A unilateral palpable gonad may be a testis, ovotestis, or rarely an ovary within an inguinal hernia. Congenital adrenal hyperplasia must be excluded in a phenotypically male baby with bilateral undescended testes.

The length of the phallus should be determined. The normal term newborn penis is about 3 cm (stretched length from pubic tubercle to tip of penis) with micropenis less than 2.0–2.5 cm, although this does vary slightly depending on ethnic origin.⁵ Chordee should be noted as this may decrease the apparent length of the phallus and the penis may be “buried” in some cases. The presence of hypospadias and the position of the urethral meatus should be determined. The urine may be coming from more than one orifice. The degree of fusion and rugosity of the labioscrotal folds should be noted and the presence or absence of a separate vaginal opening determined.

Hyperpigmentation, especially of the genital skin and nipples occurs in the presence of excessive ACTH and pro-opiomelanocortin and may be apparent

in babies with CAH. The gestation of the baby can cause confusion—in preterm girls the clitoris and labia minora are relatively prominent and in boys, the testes are usually undescended until about 34 weeks gestation.

INVESTIGATIONS

Initial investigations ascertain whether the child is an undervirilised male or a virilised female and from these a differential diagnosis can be established and subsequent investigations planned (fig 3). The principal aims of the initial investigations are to determine the most appropriate sex of rearing and in a genetic female, to exclude CAH and avert a salt losing crisis. Rarer forms of CAH (steroidogenic acute regulatory protein (StAR) deficiency, 3 β -hydroxysteroid dehydrogenase deficiency) may also present with an adrenal crisis in undervirilised males.

Karyotype

As the differential diagnosis and a number of subsequent investigations will depend on the genetic sex, an urgent karyotype should be sent. Rapid FISH studies using probes specific for the X (DX1) and Y (SRY) chromosomes can provide useful information, although a full karyotype is required for confirmation and exclusion of mosaicism. The latter may be tissue specific and may not be apparent from blood, but only from skin or gonadal biopsies. In cases with a mosaic karyotype, for example, XO/XY or XX/XY, the gonads are often different. This may involve one being a streak gonad and the other a testis or ovotestis, or two ovotestes with different ovarian and testicular components.

Determination of internal anatomy

As with the external genitalia, the degree of virilisation of the internal genital tracts is defined by Prader stages I–V (fig 2). The anatomy of the vagina or a urogenital sinus and uterus may be determined by ultrasound, and if necessary, further delineation by EUA/cystoscopy or urogenital sinogram. Ultrasound is also useful in excluding associated renal anomalies, particularly if Denys-Drash syndrome is suspected or proven. It may also be used to visualise the adrenal glands. Ultrasound may also locate inguinal gonads, although it is not sensitive for intra-abdominal gonads. Ultrasound sensitivity and accuracy depend on probe resolution; an experienced ultrasonographer is required. Identification of the gonads may require magnetic resonance imaging (MRI) or laparoscopy. These latter investigations are also useful for determining the anatomy of the internal

Table 3 Forms of CAH causing genital ambiguity in the newborn

Type of CAH	StAR protein deficiency	3 β -HSD	17 α -OHD	11 β -OHD	21-OHD
Genital ambiguity	♂	♂	♂	♀	♀
Salt wasting	Yes	Yes	Hypertension	Hypertension	Yes
Enzyme	P-450cc	3 β -HSD	P-450c17	P-450c11	P-450c21
Steroids \uparrow	None	DHEA, 17-OH-preg	DOC, corticosterone	DOC, 11-deoxycortisol	17-OHP, A4
Steroids \downarrow	All	Aldosterone, testosterone, cortisol	Cortisol, testosterone	Cortisol	Cortisol, aldosterone
Defective gene	StAR	HSD3B2	CYP17	CYP11B1	CYP21
Chromosome	8p11.2	1p13.1	10q24.3	8q24.3	6p21.3

StAR protein, steroidogenic acute regulatory protein deficiency, otherwise known as lipoid hyperplasia/cholesterol desmolase deficiency; 3 β -HSD, 3 β -hydroxysteroid dehydrogenase deficiency; 17 α -OHD, 17 α -hydroxylase deficiency; 11 β -OHD, 11 β -hydroxylase deficiency; 21-OHD, 21-hydroxylase deficiency; DOC, 11-deoxycortisol; DHEA, dehydroepiandrosterone; 17-OHP, 17-hydroxyprogesterone; 17-OH-preg, 17-hydroxypregnenolone; A4, androstenedione.

genitalia, and gonadal and genital skin biopsies can be performed at the time of laparoscopy.

Testosterone response to human chorionic gonadotrophin (hCG)

To determine whether functioning Leydig cells are present (that is, capable of producing testosterone in response to LH), an hCG stimulation test is undertaken. This is also used to delineate a block in testosterone biosynthesis from androstenedione (17 β -hydroxysteroid dehydrogenase deficiency) or conversion of testosterone to DHT (5 α -reductase deficiency). There are a variety of protocols for the hCG test, but essentially it involves taking baseline samples for testosterone and its precursors dehydroepiandrosterone (DHEA) (or DHEA sulphate (DHEAS)) and androstenedione and its metabolite (DHT). One to three intramuscular injections of high dose hCG (500–1500 IU) are given at 24 hour intervals and repeat androgen samples are taken at 72 hours or 24 hours after the last injection. The neonatal gonad is more active than at any time in childhood until puberty, reaching a peak at about a 6–8 weeks of age. A balance needs to be reached between performing the hCG test when the gonad is normally most active

(testosterone secretion normally rises in the fourth week of life, peaking at 1–3 months^{6–8}) and proceeding with the investigations as promptly as possible. While some would advocate that this test is deferred beyond 2 weeks of age, this may not be necessary. In the newborn period an increase in testosterone, reaching adult male levels, would normally be expected after hCG.

The hCG test can be extended to a three week test if the three day hCG test is inconclusive. The same dose of hCG is administered twice weekly for three weeks and testosterone, DHT, and androstenedione samples taken 24 hours after the last hCG injection. The clinical response in terms of testicular descent and change in the size of the phallus and frequency of erections should be documented. Photographs pre- and post-hCG, may be helpful.

Anti-Müllerian hormone (AMH) and inhibin B levels

While hCG stimulation tests the function of the Leydig cells, both AMH and inhibin B are secreted by the Sertoli cells. Inhibin B is detectable for the first six months, rising again at puberty. AMH levels are high in human male serum postnatally for several years before declining during the peripubertal

period, but AMH is undetectable in female serum until the onset of puberty. AMH may prove to be a more sensitive marker for the presence of testicular tissue than serum testosterone levels, both before and after the neonatal androgen surge, and, consequently, may obviate the need for hCG stimulation in the evaluation of certain intersex disorders.⁹ Similarly, basal inhibin B has been shown to predict the testosterone response to hCG in boys, and therefore may give reliable information about both the presence and function of the testes. Furthermore, inhibin B levels have been shown to demonstrate specific alterations in patients with genital ambiguity which may aid the differential diagnosis of male undervirilisation.¹⁰ However, these assays are not routinely available in the UK.

Assessment of gonadotrophins

Assessment of the gonadotrophins may give useful information. Raised basal gonadotrophins are consistent with primary gonadal failure. The gonadotrophin response to GnRH is difficult to interpret in the prepubertal child unless exaggerated, which is consistent with gonadal failure but adds little to the basal levels alone. Pituitary failure would give a flat response but is not diagnostic, and hypothalamic abnormalities such as Kallmann's syndrome are not excluded by a "normal" response. The optimal time to assess this is within the first six months of life when there is a gonadal surge in both sexes (girls greater than boys), and the axis is hence maximally responsive.

Assessment of adrenal function

Urine steroid profile

Output of adrenal steroids will be low in adrenal insufficiency. In CAH specific ratios of metabolites will be altered, depending on the level of the enzyme block.

Synacthen test

A standard short Synacthen test is useful in the following situations:

- Suspected CAH where a peak 17-hydroxyprogesterone (17-OHP) of 100–200 nmol/l is suggestive of 21-hydroxylase deficiency. (Higher reference ranges for preterm infants.)
- Suspected CAH to assess adrenal cortical reserve (measurement of cortisol levels).

The dose of Synacthen is dependent on local protocol (example 36 μ g/kg or a standard dose of 62.5 μ g intravenously or intramuscularly). Cortisol and 17-OHP levels are normally measured at 0 and 30 minutes only as the 60 minute

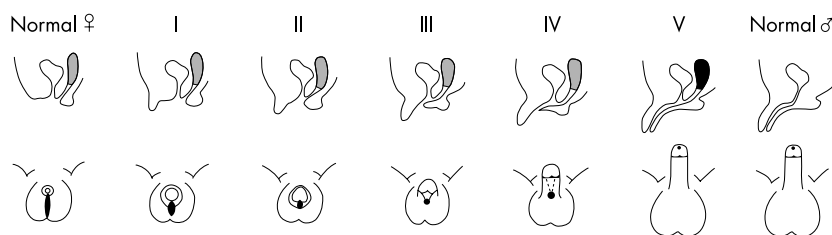


Figure 2 Differential virilisation of the external genitalia using the staging system of Prader, from normal female (left) to normal male (right). Sagittal (upper panel) and perineal (lower panel) views shown.

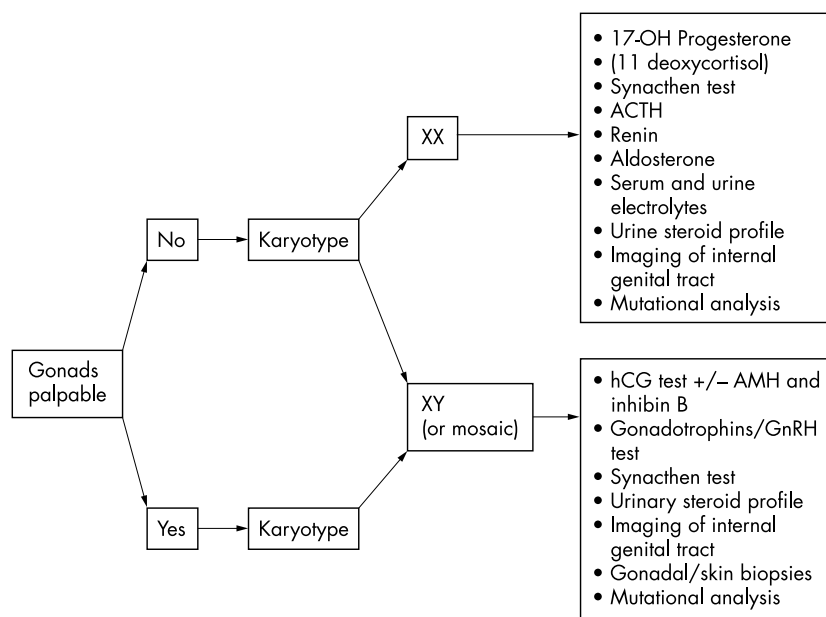


Figure 3 Investigation flow plan for assessment of ambiguous genitalia.

value does not usually contribute further. A normal basal value, or even a normal stimulated response does not exclude the evolution of adrenal insufficiency, and may need to be repeated depending on clinical suspicion. A basal ACTH level may be helpful, but in most laboratories the turnaround time is slower than for cortisol.

Skin and gonadal biopsies

Genital skin biopsies (2–4 mm) performed at the time of examination under anaesthesia (EUA) or genitoplasty are useful to establish cell lines for androgen receptor binding assays and analysis of 5 α -reductase activity. The cell line is also a source of genomic DNA and RNA and/or subsequent molecular and functional studies. Karyotype analysis for the presence of mosaicism may be indicated. Gonadal biopsies are essential when considering diagnostic categories such as dysgenesis and true hermaphroditism. A detailed histopathological report is essential. As special treatment of the samples may be required, prior discussion with the pathologist or genetics laboratory should take place.

INTERPRETATION OF RESULTS

Genital ambiguity with a 46XX karyotype indicates a virilised female

The female fetus with ovaries and normal internal genitalia has been exposed to excessive testosterone, and hence dihydrotestosterone (by conversion of testosterone by 5 α -reductase) which virilises the external genitalia.

The androgens may be derived from the fetal adrenal gland (CAH and placental aromatase deficiency), fetal gonad (the testis or ovotestis in true hermaphroditism), or rarely, exogenously via transplacental passage from the mother (adrenal or ovarian tumours).

Absence of palpable gonads in association with otherwise apparently male genitalia should always alert one to the possibility of a virilised female. By far the commonest cause of this is CAH. Of the enzyme defects that cause virilisation in female fetuses, 21-hydroxylase deficiency is the most frequent (accounting for 90–95%, UK incidence 1/15–20 000). Diagnosis is made on a raised serum 17-hydroxyprogesterone level. This level may be increased in the first 48 hours in normal babies, and may be significantly increased in sick and preterm babies in the absence of CAH. The other enzyme defects that can cause virilisation of female fetuses are 11 β -hydroxylase deficiency (where the 11-deoxycortisol levels will be increased) and less commonly 3 β -hydroxysteroid dehydrogenase deficiency (diagnosed by raised 17-hydroxypregnenolone and dehydroepiandrosterone) (table 3).

If CAH is confirmed, the electrolytes need to be watched closely as salt wasting occurs in 70% of cases of 21-hydroxylase deficiency, usually between days 4 and 15. Mineralocorticoid deficiency induces a rise in serum potassium levels (usually the first sign of salt wasting) and sodium levels fall. Urinary sodium levels will be inappropriately high. Further confirmatory tests for

CAH are DHEA, androstenedione, testosterone, ACTH, and plasma renin activity, all of which may be increased. From day 3 of life, the ratio of urinary steroid metabolites will be altered depending on the site of the block, and is very helpful in the diagnosis of 21-OHD and the rarer forms of CAH. A skilled ultrasound examination will show normal internal genitalia, but an EUA may be required to confirm the presence of normal Müllerian structures, and to show the level of entry of the vagina into the urogenital sinus, in the case of a single perineal opening.

The excessive androgen may be gonadal in origin—usually from an ovotestis or testis in a true hermaphrodite. While the commonest karyotype of the true hermaphrodite is 46XX (70.6%), the next commonest karyotype is a chromosomal mosaicism containing a Y chromosome (usually 46XX/46XY) (20.2%).¹¹ It is important to check fibroblast and/or gonadal genotype in these babies, which may contain a mosaic cell line.

Transplacental transfer of androgen may rarely occur if the mother has an androgen secreting tumour (she may be virilised as a result) or from drugs given during pregnancy. Placental aromatase deficiency, by inhibiting the conversion of androgens to oestrogens, may cause virilisation of a female fetus, and in addition, maternal virilisation occurs from placental transfer of the excessive fetal androgens.¹²

Table 2 lists conditions that cause virilisation of a female fetus.

Genital ambiguity with a 46XY karyotype indicates an undervirilised male

This is a genetically XY male with two testes, but whose genital tract fails to differentiate normally. There are numerous presentations of genital anomaly, from apparently normal female (Prader I) with a palpable gonad through to an apparently normal male with hypospadias (Prader V).

The three main diagnostic categories are: testicular dysgenesis/malfunction, a biosynthetic defect, and end-organ unresponsiveness (table 2).

If the gonads are palpable, they are likely to be testes (or rarely ovotestes). Investigations are directed at determining the anatomy of the internal genitalia, and establishing whether the testicular tissue is capable of producing androgens. Investigations that may help with the former include pelvic ultrasound, examination under anaesthesia with cystoscopy and laparoscopy. Genital skin biopsy specimens can be taken at the time of endoscopies. Occasionally urogenital sinogram or

MRI can be helpful. Laparoscopy/laparotomy and gonadal biopsy may be required.

Testicular dysgenesis/malfunction
A 46 XY karyotype, with low basal and hCG stimulated testosterone and low testosterone precursors suggests either gonadal dysgenesis (which may require laparoscopy and testicular biopsy) or lipoid CAH (caused by an abnormality in the steroidogenic acute regulatory (StAR) protein)

In the latter condition total adrenal failure is confirmed on Synacthen test, electrolytes, and urinary steroids. Because of the other associated gene defects (table 1), there may be other anomalies such as bony dysplasias or renal anomalies, which should be looked for.

The poorly functioning testicular tissue is likely to give a subnormal testosterone response to hCG and basal gonadotrophins will usually be increased, consistent with primary gonadal failure. In addition, the dysgenetic testes may secrete inadequate amounts of anti-Müllerian hormone, and Müllerian structures may be present (although often hypoplastic) in children with gonadal dysgenesis and a 46XY karyotype.

A mosaic karyotype, for example 45X/46XY suggests gonadal dysgenesis. There is a very variable phenotype both in terms of internal and external genitalia, which is not dependent on the percentage of each karyotype as determined by lymphocyte analysis. Over 90% of individuals with prenatally diagnosed 45X/46XY karyotype have a normal male phenotype, suggesting most individuals with this karyotype escape detection and that an ascertainment bias exists towards those with clinically evident abnormalities.^{13 14}

Biosynthetic defect

A 46XY karyotype, low basal and peak testosterone level on hCG testing, often with increased gonadotrophins suggests a diagnosis of an inactivating mutation of the LH receptor (Leydig cell hypoplasia)

This condition is associated with a variable phenotype from a completely phenotypic female to undervirilisation of varying degrees.¹⁵

A 46XY karyotype with normal or increased basal and peak testosterone on hCG test, and an increased T:DHT ratio is seen in 5 α -reductase deficiency

DHT dependent virilisation of external genitalia is deficient, resulting in a small phallus and perineal hypospadias. Wolffian structures are normal but spermatogenesis is usually impaired.¹⁶

This condition is rare in the UK, but recognised in the Dominican Republic, where individuals are often raised as female and convert to male in puberty, when body habitus and psychosexual orientation becomes male. Virilisation improves but is incomplete.

A biochemical diagnosis is made by showing a ratio of T:DHT >30 after puberty or following hCG stimulation before puberty, and the ratio of 5 α :5 β metabolites in a urine steroid profile will be increased after 6 months of age. The urinary 5 α :5 β metabolites can also be used if the gonads have been removed. The diagnosis is confirmed by screening for mutations in the 5 α -reductase type II gene (5RD5A2).

A 46XY karyotype, low basal and hCG stimulated testosterone levels with increased testosterone precursors indicates a testosterone biosynthetic defect

Those forms of CAH that cause undervirilisation of male genitalia include 17 α -hydroxylase/17,20-lyase deficiency and 3 β -hydroxysteroid dehydrogenase deficiency (table 3).

The conversion of androstenedione to testosterone occurs predominantly in the gonad and a post-hCG stimulated ratio of androstenedione to testosterone of >20:1 suggests 17 β -hydroxysteroid dehydrogenase deficiency. A urine steroid profile is generally not helpful in this diagnosis before puberty. Molecular analysis of the HSD III gene (HSD17B3) is sought as confirmation of the diagnosis.

End-organ unresponsiveness

A 46XY karyotype with genital ambiguity, normal or increased basal and peak testosterone on hCG test, and a normal T:DHT ratio points to partial androgen insensitivity

There is a variable phenotype, and sex of rearing depends on the degree of phallic development, and sometimes cultural considerations. The child may benefit from a trial of topical DHT cream or intramuscular testosterone (for example using 12.5–25 mg, monthly for three months) on penile growth to help anticipate response in puberty.

The diagnosis is suggested by showing an abnormality in androgen binding in genital skin fibroblasts, or a mutation in the androgen receptor gene. This requires DNA and a genital skin biopsy, taken at the time of EUA or genital surgery. Despite clear evidence of a phenotype consistent with partial androgen PAIS and normal production and metabolism of androgens, only a minority of patients are found to have an androgen receptor gene mutation. The likelihood of finding a mutation is increased if there is a family history

consistent with X linkage. The majority of XY infants with undervirilisation remain unexplained.

DNA ANALYSIS

Many of the causes of genital ambiguity have a genetic basis, and in these cases genetic counselling will be required. For example, androgen insensitivity syndrome is X-linked recessive, and CAH is autosomal recessive. In addition, identification and characterisation of a number of mutations of the genes involved in sexual differentiation has resulted in DNA tests which can be used in prenatal diagnosis. Identification of carriers will facilitate genetic counselling.

Congenital adrenal hyperplasia

Several laboratories within the UK will undertake DNA analysis for this condition. Once the diagnosis has been made, a DNA sample from the proband should be taken. If a gene mutation is identified, the carrier status of the parents may be determined and the family should be counselled about the possibility of antenatal screening of subsequent pregnancies, and of steroid treatment of the mother in an attempt to reduce virilisation of a subsequent affected female fetus. In the UK, antenatal diagnosis and treatment is offered as part of a national British Society for Paediatric Endocrinology and Diabetes supported study monitoring efficacy, short and long term side effects, and outcome measures.

Androgen insensitivity

DNA analysis is now being undertaken in Cambridge as part of a molecular genetics service in collaboration with Professor Ieuan Hughes. Samples are only analysed following collection of clinical, biochemical, and histological data that are consistent with an androgen insensitive pathophysiology.

Suspected 5 α -reductase deficiency and 17 β -hydroxysteroid dehydrogenase deficiency

DNA samples in patients with suspected 5 α -reductase deficiency and 17 β -hydroxysteroid dehydrogenase deficiency can also be processed through the Cambridge laboratory.

Unusual cases of sexual ambiguity

Mutations of developmental genes such as DAX1, SOX9, and WT1 may account for rarer cases of sexual ambiguity. Samples should be taken and DNA extracted and either stored or forwarded to the relevant laboratories, depending on clinical suspicion.

ASSIGNMENT OF SEX OF REARING

A decision about the sex of rearing should be made as soon as is practicable, usually based on the internal and external genital phenotype and the results of the various investigations. Cultural aspects may also be important in cases of severe ambiguity. Assignment of sex of rearing can be extremely difficult, particularly as there is a paucity of data on long term outcome in this area.

In the case of a virilised female (usually CAH), there is usually the potential for fertility and these babies are usually raised as girls. This is much easier if the diagnosis of CAH is made early.

Decisions about nature and timing of any surgery are made with the family acknowledging the considerable psychological impact of having a child with genital ambiguity. There is considerable debate as to the optimal timing of any genital surgery.¹⁷ In the presence of marked clitoromegaly, clitoral reduction is usually undertaken in infancy. Lesser degrees of clitoral enlargement may be left until puberty when the child can be involved with the decision making. The timing of any vaginoplasty is dependent on the anatomy of the internal and external genitalia and influenced by local practice. However, there has been a move away from early vaginoplasty in all infants. It may be appropriate to delay surgery until puberty when a single stage reconstruction can be undertaken. Recent outcome data on clitoral sensation¹⁸ and success of early vaginoplasty^{19 20} in adult women who underwent genital surgery in infancy and childhood has induced a more cautious surgical approach.^{21 22}

The appropriate sex of rearing of a very undervirilised male requires as much information as possible, from the investigations discussed, as well as thorough, multidisciplinary discussions involving the parents, urologist, endocrinologist, geneticist, and a clinical psychologist. It may be appropriate to defer gender assignment until the results of relevant investigations are reviewed and the effects of exogenous androgens have been assessed. The birth registration should be delayed for as long as it takes for the final decision to be made.

CONCLUSIONS

Genital ambiguity resulting in uncertainty of sex at birth is uncommon. The most frequent cause in a genetic female is CAH, which may be life threatening if there is a risk of a salt losing crisis. Reaching a diagnosis, particularly in undervirilised males, is currently not always possible, but many may have a partial androgen insensitivity syndrome yet to be defined in molecular terms or milder variants of testicular dysgenesis. Prompt counselling and investigations (with the backup of recognised biochemical and genetic laboratories) is essential. The decision of sex of rearing and the timing of surgery need careful consideration within a multidisciplinary environment with full informed consent of the family.

ACKNOWLEDGEMENTS

We thank Professor Ieuan Hughes and Dr John Achermann for their helpful comments. Email address for Professor Hughes for mutation analysis and discussion on the androgen receptor, 5 α -reductase deficiency, and 17 β -hydroxysteroid dehydrogenase: iah1000@cam.ac.uk. Email address for Dr Achermann for mutation analysis and discussion on early gonadal genes or cases associated with adrenal failure: j.achermann@ich.ac.uk.

Web address for the British Society for Paediatric Endocrinology and Diabetes: www.bsped.org.uk.

Arch Dis Child 2004;**89**:401–407.

doi: 10.1136/adc.2003.011312

Authors' affiliations

A L Ogilvy-Stuart, Neonatal Unit, Rosie Hospital, Addenbrooke's NHS Trust, Cambridge CB2 2SW, UK

C E Brain, Dept of Paediatric Endocrinology, Great Ormond Street Hospital, Great Ormond Street, London WC1N 3JH, UK

Correspondence to: Dr A L Ogilvy-Stuart, Neonatal Unit, Rosie Hospital, Addenbrooke's NHS Trust, Cambridge CB2 2SW, UK; amanda.ogilvy-stuart@addenbrookes.nhs.uk

REFERENCES

- 1 Hamerton JL, Canning N, Ray M, et al. A cytogenetic survey of 14,069 newborn infants. I. Incidence of chromosome abnormalities. *Clin Genet* 1975;**4**:223–43.
- 2 Blackless M, Charuvastra A, Derryck A, et al. How sexually dimorphic are we? *Am J Hum Biol* 2000;**12**:151–66.

- 3 Ahmed SF, Hughes IA. The genetics of male undermasculinization. *Clin Endocrinol* 2002;**56**:1–18.
- 4 Vainio S, Heikkila M, Kispert A, et al. Female development in mammals is regulated by Wnt-4 signalling. *Nature* 1999;**379**:707–10.
- 5 Cheng PK, Chanoine JP. Should the definition of micropenis vary according to ethnicity? *Horm Res* 2001;**55**:278–81.
- 6 Winter JS, Hughes IA, Reyes FI, et al. Pituitary-gonadal relations in infancy: 2. Patterns of serum gonadal steroid concentrations in man from birth to two years of age. *J Clin Endocrinol Metab* 1976;**42**:679–86.
- 7 Ng KL, Ahmed SF, Hughes IA. Pituitary-gonadal axis in male undermasculinisation. *Arch Dis Child* 2000;**82**:54–8.
- 8 Davenport M, Brain C, Vandenberg C, et al. The use of the hCG stimulation test in the endocrine evaluation of cryptorchidism. *Br J Urol* 1995;**76**:790–4.
- 9 Rey RA, Belleville C, Nihoul-Fekete C, et al. Evaluation of gonadal function in 107 intersex patients by means of serum antimullerian hormone measurement. *J Clin Endocrinol Metab* 1999;**84**:627–31.
- 10 Kubini K, Zachmann M, Albers N, et al. Basal inhibin B and the testosterone response to human chorionic gonadotropin correlate in prepubertal boys. *J Clin Endocrinol Metab* 2000;**85**:134–8.
- 11 Krab G, Braun A, Kuhnle. True hermaphroditism: geographical distribution, clinical findings, chromosomes and gonadal histology. *Eur J Pediatr* 1994;**153**:2–10.
- 12 Shazu M, Akasofu K, Harada T, et al. A new cause of female pseudohermaphroditism: placental aromatase deficiency. *J Clin Endocrinol Metab* 1991;**72**:560–6.
- 13 Chang HJ, Clark RD, Bachman H. Chromosome mosaicism in 6,000 amniocenteses. *Am J Med Genet* 1989;**32**:506–13.
- 14 Wilson MG, Lin MS, Fujimoto A, et al. The phenotype of 45,X/46,XY mosaicism: an analysis of 92 prenatally diagnosed cases. *Am J Hum Genet* 1990;**46**:156–67.
- 15 Laue L, Wu S-M, Kudo M, et al. A nonsense mutation of the human luteinizing hormone receptor gene in Leydig cell hypoplasia. *Hum Mol Genet* 1995;**4**:1429–33.
- 16 Hochberg Z, Chayen R, Reiss N, et al. Clinical, biochemical, and genetic findings in a large pedigree of male and female patients with 5 alpha-reductase 2 deficiency. *J Clin Endocrinol Metab* 1996;**81**:2821–7.
- 17 Creighton S. Surgery for intersex. *J R Soc Med* 2001;**94**:218–20.
- 18 Minto CL, Liao LM, Woodhouse CRJ, et al. The effect of clitoral surgery on sexual outcomes in individuals who have intersex conditions with ambiguous genitalia: a cross sectional study. *Lancet* 2003;**361**:1252–7.
- 19 Alizai NK, Thomas DF, Lilford RJ, et al. Feminizing genitoplasty for congenital adrenal hyperplasia: what happens at puberty? *J Urol* 1999;**161**:1588–91.
- 20 Creighton S, Minto C, Steele SJ. Feminizing childhood surgery in ambiguous genitalia: objective cosmetic and anatomical outcomes in adolescence. *Lancet* 2001;**358**:124–5.
- 21 Creighton S, Minto C. Managing intersex. *BMJ* 2001;**323**:1264–5.
- 22 Creighton S, et al. Regarding the consensus statement on 21-hydroxylase deficiency from the Lawson Wilkins Paediatric Endocrine Society and the European Society for Paediatric Endocrinology [letter]. *Hormone Res* 2003;**59**:262; and *J Clin Endocrinol Metab* 2003;**88**:3455.