

ORIGINAL ARTICLE

Anoxic-epileptic seizures: observational study of epileptic seizures induced by syncopes

I A Horrocks, A Nechay, J B P Stephenson, S M Zuberi



Arch Dis Child 2005;90:1283–1287. doi: 10.1136/adc.2005.075408

See end of article for authors' affiliations

Correspondence to: Prof. J B P Stephenson, Fraser of Allander Neurosciences Unit, Royal Hospital for Sick Children, Yorkhill, Glasgow G3 8SJ, UK; john@jbstephenson.com

Accepted 25 August 2005
Published Online First
15 September 2005

Aims: To describe a large series of children with anoxic-epileptic seizures (AES)—that is, epileptic seizures induced by syncopes.

Methods: Retrospective case-note review in a tertiary paediatric neurology unit. For all 27 children seen with a definite diagnosis of AES between 1972 and 2002, a review of clinical histories, videotapes, and EEG/ECG studies was undertaken. Main outcome measures were: age of onset, frequency and type of syncopes; age of onset and frequency of AES; type and duration of induced epileptic seizures; effect of treatment of syncopal and epileptic components.

Results: Median age of onset of syncopes was 8 months (range 0.2–120), frequency 2 in total to 40/day, median total ~200. Syncopes were predominantly reflex asystolic (RAS), prolonged expiratory apnoea (cyanotic breath-holding spells), or of mixed or uncertain origin; there was one each of ear piercing and hair grooming vasovagal syncope and one of compulsive Valsalva. Median age of onset of AES was 17 months (range 7–120), frequency from total 1 to 3/day, median total 3. The epileptic component was almost always bilateral clonic; three had additional epilepsy, one each with complex partial seizures, myoclonic absences, and febrile seizures plus. Median duration of epileptic component was 5 minutes (range 0.5–40, mean 11). Cardiac pacing prevented RAS in two patients: most other anti-syncope therapies were ineffective. Diazepam terminated the epileptic component in 6/8. Valproate or carbamazepine abolished AES in 5/7 without influencing syncope frequency.

Conclusions: Although uncommon compared with simple syncopes, syncope triggered epileptic seizures (AES) are an important treatable basis of status epilepticus.

Convulsive syncope is common in children, and particularly so in infants and toddlers.¹ In most cases these are simply non-epileptic anoxic seizures^{1–2}—well known to all paediatricians—in which abrupt loss of cerebral energy supply leads to brief extensor stiffening and a few seconds of irregular spasms or jerks. Less well known is the situation in which a syncope—that is, an anoxic seizure—provokes a true epileptic seizure. This combination is called an anoxic-epileptic seizure (AES) and was first described as such by one of us in 1983.³ Since then there have been only 11 patients with AES from outwith our unit described in any detail.^{4–11} The paucity of reports may have given the impression that AES are rare, and even the existence of AES has been questioned.¹² We therefore thought it worthwhile to describe the features of a large series of children with AES seen in a single tertiary paediatric neurosciences unit.

METHODS

Setting

The Fraser of Allander Neurosciences Unit is a tertiary referral unit for paediatric neurology which serves the West of Scotland (population 3 million) but may take referrals from elsewhere. Since its opening in 1972 a diagnostic index has been maintained of all patients seen.

Information retrieval

The diagnostic index was searched for the coded diagnosis of AES from 1972 until the end of 2002. All case records were reviewed in detail by the authors. All available home or hospital video recordings were reviewed as well as EEG and ECG traces. The coded diagnosis of AES was only accepted if both the history of syncope and of the triggered epileptic

seizure was convincing to all authors. Box 1 shows the levels of evidence we used for establishing the epileptic component.

Case histories, EEG/ECG records, and/or video recordings of 14 of the children were already in the literature,^{1–2 11 13–15} and these publications were reviewed.

RESULTS

Patient demographics

A total of 27 children had a convincing history of AES, with the first patient being recognised in 1978 and the next two in 1982. Of this total of 27, 21 were referred from the West of Scotland, 1 from Northeast Scotland, 3 from England, 1 from Wales, and 1 from the USA. All patients were seen at one time by the corresponding author (JBPS). There were 11 boys and 16 girls.

Age of onset and frequency of syncopes

The age of onset of syncopes ranged from 5 days (0.2 months) to 10 years (120 months) with a median of 8 months.

The frequency of syncopes varied from 2 in total to 40/day. The median was of the order of 200 syncopes, but since 11 of the children had a history of daily syncopes, the figures for total number of syncopes were in the main approximations.

Type of syncopes

We grouped the syncopes into five types on the basis of clinical description, aided when possible by the appearances of recorded events.

Abbreviations: AES, anoxic-epileptic seizures; PEA, prolonged expiratory apnoea; RAS, reflex anoxic seizures/reflex asystolic syncope

Box 1: Levels of evidence for epileptic component in AES

- (1) Syncope induced epileptic seizure recorded on EEG
- (2) Epileptic component of AES video recorded
 - (a) video included transition from syncope to epileptic seizure
 - (b) video was of epileptic seizure immediately after transition from provoking syncope
 - (c) video was of prolonged epileptic jerking which, although not on that occasion syncope induced, had also by history been so induced
- (3) Prolonged post-syncopal jerking or other epileptic activity witnessed by attending medical staff
- (4) Clinical history of post-syncopal rhythmic jerking or other convincing epileptic activity
 - (a) duration 10 minutes or more
 - (b) duration less than 10 minutes

Reflex anoxic seizures/reflex asystolic syncope (RAS)

There were 9 children whose syncopes were judged to be of this nature, with a typical history of short latency onset syncopes most often precipitated by unexpected hurt.¹⁶ Of these, 7 had ECG recordings during ocular compression (5 children), on head-up tilt (1 child), or on cardiac monitoring at home (1 child). Median cardiac asystole was 28 seconds (range 17–31).

Prolonged expiratory apnoea/cyanotic breath-holding spells

In 6 children the clinical description was of “blue breath-holding”¹³ or cyanotic breath-holding spells,¹⁷ otherwise called prolonged expiratory apnoea,¹⁸ with expiratory grunting apnoea and deep cyanosis in response to frustration. When syncopes occurred during monitoring (3 children), prolonged cardiac asystole was not seen.

Infantile syncopes of uncertain or mixed origin

In 9 children either we could not decide which of the above two mechanisms was operative or else there was evidence of a mixed mechanism. In the most dramatic example^{2 14} there was simultaneous prolonged expiratory grunting and prolonged asystole (23–24 seconds).

Vasovagal syncope

Two children had more typical vasovagal syncope, 1 while having her pierced ears cleaned, and 1 (aged 10 years) during hair grooming.¹⁹

Compulsive Valsalva manoeuvres

One boy¹¹ with autistic spectrum disorder had very frequent daily compulsive Valsalva manoeuvres.

Anoxic-epileptic seizures: age of onset and frequency

The median age of onset of AES was 17 months (range 7–120). The frequency varied from a total of just one to 3/day, the median being 3 AES in total.

Type of epileptic component of AES

In almost all children the epileptic component could be described as bilateral clonic. Sometimes there was horizontal eye deviation or rhythmically interrupted vocalisation.¹¹ In

one child, what appeared to be absence status followed the clonic epileptic component. In 3 children there were in addition unprovoked epileptic seizures, that is epilepsy, the syncope triggered epileptic seizures being reportedly identical to the spontaneous episodes. There was one example each of myoclonic absences, generalised epilepsy with febrile seizures—clonic epileptic seizures with and without fever—and temporal lobe complex partial seizures.

Duration of epileptic component of AES

The duration of the syncope triggered epileptic seizures varied from 28 seconds (Stephenson,¹ case 11.2) to 40 minutes (mean 11 minutes, median 5 minutes). In about half (12 children) the epileptic component lasted for 10 minutes or more, and in 4 children for 30 minutes or more. The epileptic component was witnessed by medical staff in 16 children, and in these the duration of the epileptic component was 10 minutes or more in 8 and 30 minutes or more in 4.

Treatment of the syncopal component of AES

Most medications, including iron supplements and piracetam were unhelpful. In one child with RAS, atropine was associated with improvement, and in another was ineffective. In the autistic boy with compulsive Valsalva manoeuvres, naltrexone had at least temporary benefit. Permanent cardiac pacing^{14 15} prevented RAS, and therefore AES in 2 severely affected children. In one child with very frequent AES from “breath-holding” (prolonged expiratory apnoea), psychological methods⁹ led to no benefit.

Acute treatment of the epileptic component of AES

Rectal or intravenous diazepam was given by emergency doctors in 7 children and was effective in 6, albeit one child required two injections. In the diazepam non-responder, intravenous phenobarbitone and rectal paraldehyde were required in the intensive care unit, and this child later had cardiac pacing.¹⁵ In addition, the child with compulsive Valsalvas was given diazepam at home without evident benefit.

Prophylactic treatment of the epileptic component of AES

Sodium valproate or carbamazepine was effective in 5 of 7 children to whom it was given. By effective we mean that the epileptic component of the AES was abolished, but the syncopes continued unchanged.

Frequency of AES compared with frequency of syncope

Except in a few instances, there were in any child vastly more syncopes, that is pure anoxic seizures, than there were AES. In 3 children in whom a more precise ratio could be calculated, about 7–8% of syncopes developed into AES.

These results are summarised in table 1.

DISCUSSION

This is the first large published series of definite epileptic seizures induced by syncopes. It establishes that such AES are not rare and should be considered when prolonged rhythmic jerking follows a noxious stimulus. While any type of neurally mediated syncope from impaired cerebral perfusion or hypoxia may be the stimulus for the epileptic component of AES, the epileptic component is more stereotyped and less diverse. In the vast majority of AES the epileptic component could best be described as clonic, with no examples known of a tonic-clonic epileptic seizure being induced. Some authors⁵ have stated that tonic-clonic epileptic seizures may be induced by syncopes, but in our opinion the tonic phase was the tonic component of the syncope or anoxic seizure

Table 1 Clinical data on 27 children with a history of AES

Case no./sex/from	Ref./case	Syncope onset (mth)	Syncope type/frequency	AES onset (mth)	Epileptic component/duration (min)	Evidence of epileptic component	AES total	Therapy (bold type = effective)	Other epileptic seizures	Other details/FH
1 M	¹ 11.1	6-7	RAS 3/day	15	Clonic 10	1	3	-	-	OC 22s
2 M	¹ 11.2	9	RAS Several	11	Clonic $\frac{1}{2}$ (28s.)	1	2	-	-	OC 30 s
3 F		15	RAS 1/month	48	Focal 3	1	1+	Carbamazepine	Same	OC 17 s
4 M	¹¹ 5	0.5	BHS 3/week	7	Myoclonic absence 1	2c	Many	Clonazepam	Same	
5 M U	¹¹ 3	30	CVM Daily	30+	Clonic (vibratory) $\frac{3}{4}$	2a	Many	Wrestler's belt Naltrexone Diazepam	-	
6 M	¹¹ 4	5	PEA Daily	10	Clonic 1	2b	Many	Iron Piracetam Psychology Valproate	-	Brother PEA & FS up to 20 m
7 F		30	VVS Total 2	84	Clonic 5	4b	1	-	-	Ear piercing
8 F		6	RAS 3/day	18	Clonic 25	4a	10	-	-	CM 31 s
9 F	¹ 8.1	4	PEA 3/day	14	Clonic 5	3 Seen in ward	20	-	-	OC 5 s
10 F	¹ 15.45	6	BHS 2/week	11	Clonic 20	4a	>3	-	-	OC 12 s One AES febrile
11 F	² 2	8	PEA Daily	15	Clonic 3	4b	4	-	-	OC 7 s PEA 8 s
12 F		42	RAS 3/month	108	Clonic 15	4a	1	Pacing	-	Tilt 30 s
13 M W		12	BHS 1/month	17	Clonic 30	3	3	Diazepam Valproate	-	OC 1.5 s Sister FS with status
14 F E	¹ 4.8	12	RAS Total 12	<20	Clonic 15	3	1	Diazepam	-	OC 28 s
15 F		8	BHS 6/year	13	Clonic 1	4b "That's it!"	3	-	-	OC 2 s
16 F S	¹⁵ 7	0.2	RAS 4/day	19	Clonic 40	3	1	Diazepam Paraldehyde Valproate Pacing	-	CM 20 s
17 M	¹ 11.3	9	PEA Daily	18	Clonic 2	4b	3	-	-	OC 0 s
18 F	¹ 11.4	<16	BHS Total 3	16	Clonic 20	3	2	Diazepam	-	OC 15 s
19 M		9	PEA Daily	17	Clonic 2	4b "1/s. jerks"	4	-	-	
20 F		120	VVS Total 3	120	Clonic 10	3	3	Diazepam	-	Hair groom M: epilepsy
21 F	¹ 11.5	12	RAS 5/year	18	Clonic 30	3	1	Diazepam Repeat needed	-	
22 F		4	BHS Total 13	<30	Clonic 1	2c	6	Valproate	Same, also FS = FS+	M's sister FS
23 M E		8	RAS Up to 5/day	15	Clonic 5	4b	6	Carbamazepine	-	
24 F		8	BHS 3/week	11	Clonic + absence status 30	3	1	Diazepam	-	
25 M E		14	BHS 3/week	20	Clonic 5	4b	1	-	-	
26 M		0.6	PEA Uncertain	12	Clonic 15	4a	10	Phenobarb.	-	OC 0 s
27 F E	¹⁴	8	BHS Up to 40/day	12	Clonic 2	1	Up to 3/day	Valproate Carbamazepine Atropine, Pacing	-	OC 24 s PEA 23 s Twin RAS

All cases were referred from the west of Scotland, except those initialled in the first column as: S, from elsewhere in Scotland; E, from England; W, from Wales, U, from USA. In the second column Ref./case gives the reference and the published case number (if any).

Syncope abbreviations: RAS, reflex anoxic seizures/reflex asystolic syncope; PEA, prolonged expiratory apnoea (cyanotic breath-holding); BHS, breath-holding spells of uncertain mechanism or combined asystole and expiratory grunting; VVS, vasovagal syncope of adult type; CVM, compulsive Valsalva manoeuvre.

Under Evidence of epileptic component, the scoring of level of evidence is as in box 1, with "seen in ward", observed during ward-round; "that's it!", recognition of event by parents from video demonstrations;²⁰ and "1/s jerks", parents described and mimed 1/second jerking.

In Other epileptic seizures: FS, febrile seizures; FS+, febrile seizures plus.

In the last column: FH, family history; M, mother; m, month; the figures before s., seconds refer to duration of asystole; OC, ocular compression; CM, cardiac monitoring; tilt, head-up tilt testing.

Other abbreviations are as previously, except that when PEA is followed by a number of seconds, that is the duration of asystole accompanying the PEA event.

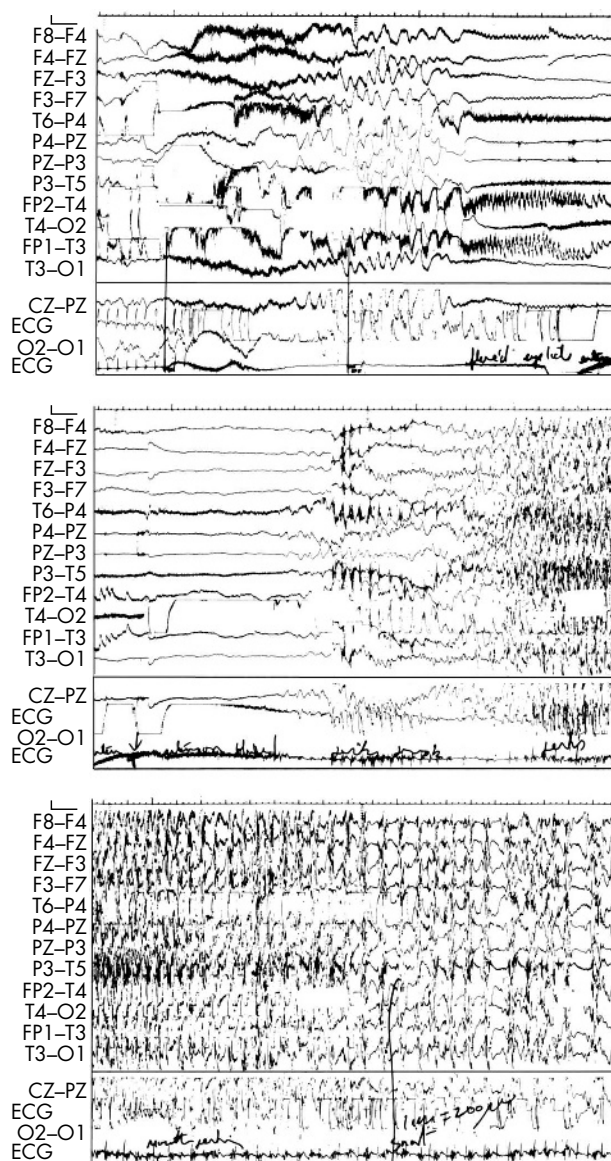


Figure 1 EEG/ECG recording showing AES induced by ocular compression (OC). Each panel lasts about 20 s. In the upper panel OC induces instant asystole and the EEG becomes isoelectric within 12 s (the fast deflections in the 9th and 11th channels correspond to down-beat nystagmus). In the centre panel the tonic phase of the anoxic seizure is shown on the ECG line as black “fuzz” due to tonic EMG activity. Midway across the centre panel while the EEG is still isoelectric, rhythmic 2–3/s jerk artefacts are seen on EEG and ECG channels. By the time of the lower panel, rhythmic EEG spike wave is visible, slowing towards the conclusion. Jerking lasted 28 s but the child was unresponsive for a further 8 minutes (reproduced with permission from Stephenson,¹ Mac Keith Press, fig. 11.4).

and what followed was simply a clonic epileptic seizure.¹ In support of this assertion is the EEG/ECG appearance of published examples of AES, in particular that of our case 2, as shown in fig 1.

Why some patients have epileptic seizures after syncopes while most do not is a most interesting question. It has been known for over 40 years that hypoxia, experimentally induced by nitrogen inhalation, could provoke generalised²¹ or focal²² EEG discharges in adults with respectively generalised or focal epilepsy. Most of the children in our series did not have additional epilepsy—in the sense of recurrent

What is already known on this topic

- Convulsive syncope usually means non-epileptic anoxic seizures
- Published examples of convulsive syncope in which true epileptic seizures were induced by syncopes have been few in number, giving the impression that anoxic-epileptic seizures (AES) are rare

What this study adds

- In this, the first large systematic study of AES from a single referral centre, the numbers seen suggest that AES—triggered by a variety of syncopes—are not rare
- Clonic status epilepticus—however defined—was common in AES, but was treatable or preventable, whereas the syncopal component could only occasionally be treated

“spontaneous” epileptic seizures—but four of them (cases 6, 13, 20, and 22) had a family history of probable epileptic seizures, including prolonged epileptic febrile seizures in two cases. In one large family (case 6) there was a history of both infantile epileptic convulsions and PEA, suggesting that an epileptic seizure gene and a neurally mediated syncope gene might have come together to give a propensity to AES.

It may also be asked whether the syncopes in our cases differed in any identifiable way from the background population of children with neurally mediated syncopes. There is little good information on the relative frequency of the different types of infantile syncope, but in a prospective study Lombroso and Lerman²³ found that of their total of 140, 62% had cyanotic breath-holding or what we would now call prolonged expiratory apnoea, 19% had pallid spells (reflex anoxic seizures or reflex asystolic syncope), and 19% were indeterminate. Our series was different, in that asystolic events were more frequent, but not sufficiently so to provide an explanation. We suggest that future combined clinical and genetic studies should address origins of both the syncopal and epileptic components of AES.

In the literature and in our cases, status epilepticus—whether defined as an epileptic seizure lasting 30 minutes or 10 minutes²⁴—is a frequent complication of AES. Whether this is because AES with only a brief epileptic component are difficult to recognise is not clear.

We think that AES are important for paediatricians, paediatric cardiologists, and paediatric neurologists to recognise because the common tendency to progress to status epilepticus may be prevented, either by acute administration of a benzodiazepine (in our series rectal or intravenous diazepam) or by daily prophylaxis with standard antiepileptic medication (in our series valproate or carbamazepine). The uncomplicated syncopes (anoxic seizures) which are usually much more frequent than AES in any given patient can seldom be prevented, with one important exception: if the syncopal component is RAS, with documented prolonged reflex asystole, specific cardiac therapy (even pacing¹⁵) may prevent the need for antiepileptic medication.

In conclusion, syncopes may trigger true epileptic seizures, and children’s doctors should be aware of this. The paucity of published reports suggests that most AES are either unrecognised or misdiagnosed.

ACKNOWLEDGEMENTS

Thanks are extended to Dr William Whitehouse for referring one of the children and for sharing additional information.

Authors' affiliations

I A Horrocks, J B P Stephenson, S M Zuberi, Fraser of Allander Neurosciences Unit, Royal Hospital for Sick Children, Glasgow, UK
A Nechay, Fraser of Allander Neurosciences Unit, Royal Hospital for Sick Children, Glasgow, UK, and Neurology Department, Paediatric Hospital N° 1, Kiev, Ukraine

Competing interests: none

REFERENCES

- Stephenson JBP. *Fits and faints*. London: MacKeith Press, 1990: 19–23, 112–24.
- Stephenson JBP. Anoxic seizures: self-terminating syncope. *Epileptic Disord* 2001;**3**:3–6.
- Stephenson JBP. Febrile convulsions and reflex anoxic seizures. In: Rose FC, ed. *Research progress in epilepsy*. London: Pitman, 1983:244–52.
- Aicardi J, Gastaut H, Misès J. Syncopal attacks compulsively self-induced by Valsalva's maneuver associated with typical absence seizures. A case report. *Arch Neurol* 1988;**45**:923–5.
- Battaglia A, Guerrini R, Gastaut H. Epileptic seizures induced by syncopal attacks. *J Epilepsy* 1989;**2**:137–45.
- Emery ES. Status epilepticus secondary to breath-holding and pallid syncopal spells. *Neurology* 1990;**40**:859.
- Nirale S, Bharucha NE. Breath-holding and status epilepticus. *Neurology* 1991;**41**:159.
- Bergey GK, Krumholz A, Fleming CP. Complex partial seizure provocation by vasovagal syncope: video-EEG and intracranial electrode documentation. *Epilepsia* 1997;**38**:118–21.
- Kuhle S, Tiefenthaler M, Seidl R, et al. Prolonged generalized epileptic seizures triggered by breath-holding spells. *Pediatr Neurol* 2000;**23**:271–3.
- Kelly AM, Porter CJ, McGoon MD, et al. Breath-holding spells associated with significant bradycardia: successful treatment with permanent pacemaker implantation. *Pediatrics* 2001;**108**:698–702.
- Stephenson J, Breningstall G, Steer C, et al. Anoxic-epileptic seizures: home video recordings of epileptic seizures induced by syncope. *Epileptic Disord* 2004;**6**:15–19.
- Appleton R. Reflex anoxic seizures. *BMJ* 1993;**24**:214–15.
- Stephenson JBP. Blue breath holding is benign. *Arch Dis Child* 1991;**66**:255–7.
- Sreeram N, Whitehouse W. Permanent cardiac pacing for reflex anoxic seizure. *Arch Dis Child* 1996;**75**:462.
- Stephenson JBP, McLeod KA. Reflex anoxic seizures. In: David TJ, ed. *Recent advances in paediatrics 18*. Edinburgh: Churchill Livingstone, 2000:12.
- Stephenson JBP. Reflex anoxic seizures (white breath-holding) nonepileptic vagal attacks. *Arch Dis Child* 1978;**53**:193–200.
- Breningstall GN. Breath-holding spells. *Pediatr Neurol* 1996;**14**:91–7.
- Southall DP, Talbert DG, Johnson P, et al. Prolonged expiratory apnoea: a disorder resulting in episodes of severe arterial hypoxaemia in infants and young children. *Lancet* 1985;**2**:571–7.
- Igarashi M, Boehm RM Jr, May WN, et al. Syncope associated with hair-grooming. *Brain Dev* 1988;**10**:249–51.
- Stephenson JBP. Nonepileptic seizures, anoxic-epileptic seizures, and epileptic-anoxic seizures. In: Wallace SJ, ed. *Epilepsy in children*. London: Chapman & Hall, 1996:23.
- Gastaut H, Bostem F, Fernandez-Guardiola A, et al. Hypoxic activation of the EEG by nitrogen inhalation. 1. Preliminary observations in generalised epilepsy. In: Gastaut H, Meyer JS, eds. *Cerebral anoxia and the electroencephalogram*. Springfield, IL: Charles C Thomas, 1961:343–54.
- Gastaut H, Bostem F, Fernandez-Guardiola A, et al. Hypoxic activation of the EEG by nitrogen inhalation. 2. Preliminary results in partial epilepsy. In: Gastaut H, Meyer JS, eds. *Cerebral anoxia and the electroencephalogram*. Springfield, IL: Charles C Thomas, 1961:355–64.
- Lombroso CT, Lerman P. Breathholding spells (cyanotic and pallid infantile syncope). *Pediatrics* 1967;**39**:563–81.
- Livingston JH. Status epilepticus. In: Wallace SJ, Farrell K, eds. *Epilepsy in children*, 2nd edn. London: Arnold, 2004:290–303.

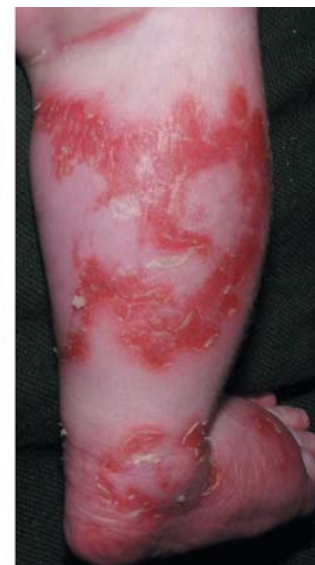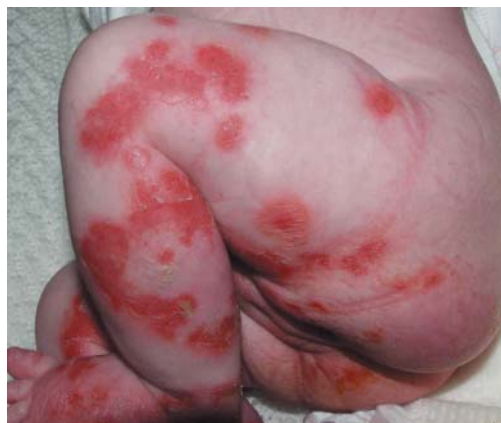IMAGES IN PAEDIATRICS

doi: 10.1136/adc.2005.084160

An unwell child with a florid rash

A 3 month old girl presented with a striking erythematous rash on her lower limbs. She had become increasingly oedematous and had started to vomit frequently. Despite being breast fed, her stools were frequent, offensive, and pale. Investigations revealed anaemia, hypoproteinaemia, and deranged liver function. Serum zinc levels were normal.

This is necrolytic migratory erythema. In children, it may occur in association with liver disease, inflammatory bowel disease, pancreatitis, and malabsorption syndromes. A deficiency of amino acids, essential fatty acids, and/or zinc is thought to be the cause. Our child was subsequently found to have cystic fibrosis. Creon (pancreatic enzymes) and Ketovite (multivitamins and folic acid) supplementation resulted in a dramatic resolution of the rash and a sustained improvement in the child's condition.



Parental consent was obtained for publication of these figures

W Hussain, N Craven

Department of Dermatology, Burnley General Hospital, Burnley, UK

I Swann

Department of Paediatrics, Burnley General Hospital, Burnley, UK

Correspondence to: Dr W Hussain, Department of Dermatology, Burnley General Hospital, Casterton Avenue, Burnley BB10 2PQ, UK; dr_w_hussain@hotmail.com

Competing interests: none