

SHORT REPORT

Old world cutaneous leishmaniasis infection in children: a case series

J Jones, J Bowling, J Watson, F Vega-Lopez, J White, E Higgins

Arch Dis Child 2005;90:530–531. doi: 10.1136/adc.2004.057968

Leishmaniasis currently threatens 350 million people in 88 countries around the world. Ninety per cent of cutaneous leishmaniasis (CL) cases occur in Afghanistan, Brazil, Iran, Peru, Saudi Arabia, and Syria. An epidemic of cutaneous leishmaniasis is ongoing in Kabul, Afghanistan with an estimated 200 000 cases. Lesions can be very disfiguring, particularly on the face, which may have long term psychological and social consequences. Over the past 10 years endemic regions have been spreading further afield and there has been a large increase in the number of recorded cases.

Over the past five years, at the Hospital of Tropical Diseases in London, we have been involved in the diagnosis and treatment of six children with CL due to *L tropica* and three children with cutaneous leishmaniasis due to *L major*. In our patients species identification was made by polymerase chain reaction (PCR).

L tropica CL usually manifests as dry, small, self-healing lesions, mainly located on the face, which heal with permanent scarring, while lesions due to *L major* tend to present as single or multiple “wet” ulcers.

In leishmaniasis *recidivans*, also called lupoid leishmaniasis, brown-red or brown-yellow papules appear in or adjacent to an old lesion of CL. Two children in our series with *L tropica* infection presented with features of lupoid leishmaniasis (fig 3).

Three children with *L tropica* were treated in hospital with systemic sodium stibogluconate 20 mg/kg daily for 3–4 weeks. The remaining three children with CL due to *L tropica* received intralesional sodium stibogluconate. In

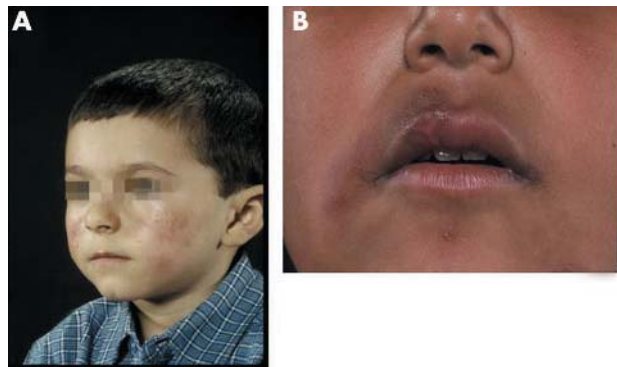


Figure 2 (A) A 3 year old boy from Turkey following treatment with systemic sodium stibogluconate. (B) An 8 year old girl from Pakistan, following treatment with systemic sodium stibogluconate.

addition, one of the children with lupoid leishmaniasis required surgical excision of two nodules.

The three children with *L major* disease were treated with oral itraconazole at a dose of 10 mg/kg daily for 6 weeks. In all children, treatment resulted in resolution of their lesions.

The diagnosis of CL infection has to be suspected in children presenting with chronic, nodular, or ulcerated facial lesions. Diagnosis should be confirmed with, Giemsa stained smears looking for amastigotes, histology looking for granulomas +/- amastigotes, culture in NNN medium to grow promastigotes, and PCR with Old World primers.

Sensitivity of direct microscopy is low and parasitological culture not always successful, whereas PCR is a highly sensitive and specific test which allows species identification.

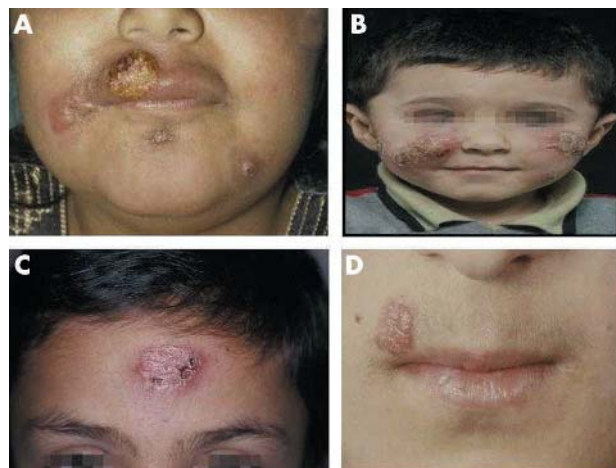


Figure 1 (A) An ulcerated, nodular plaque with diffuse dermal infiltration involving the upper lip in an 8 year old girl from Pakistan (*L tropica*). (B) Ulcerated nodular plaques on the cheeks of a 3 year old boy from Turkey (*L tropica*). (C) An ulcerated plaque on the forehead of a 5 year old boy from Afghanistan (*L tropica*). (D) An ulcerated plaque above the lip of a 10 year old boy from Afghanistan (*L tropica*).

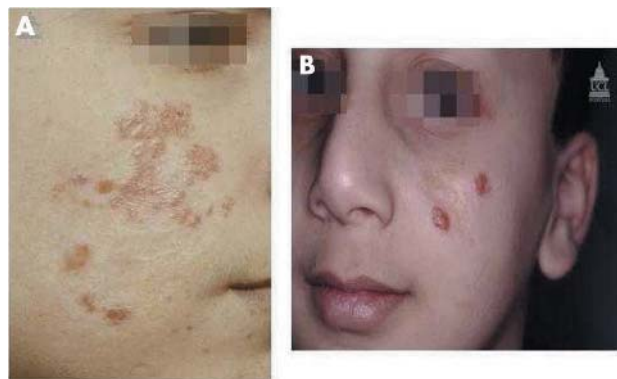

Figure 3 (A) Lupoid leishmaniasis with scarring due to previous *L tropica* infection and the presence of red/brown papules at the periphery of the scar. (B) Lupoid leishmaniasis with scarring due to previous *L tropica* infection, and two red/brown nodules at the superior and inferior poles, of the scar on the left cheek of a 9 year old boy from Afghanistan.

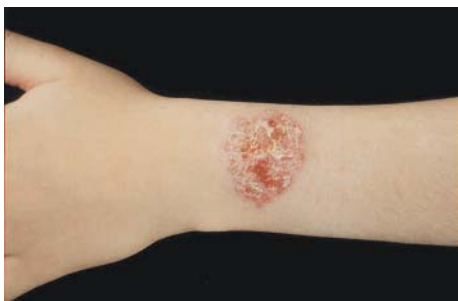

Figure 4 Crusted plaque on the forearm of a young boy from Algeria (*L. major*).

Pentavalent antimonials are an effective treatment in the majority of cases by *L. tropica* and seem to have few side

effects in children. Spontaneous resolution is common in cases with *L. major* cutaneous leishmaniasis. With an increasing immigrant population from endemic regions to the UK, a higher frequency of these previously rarely seen cases is expected.

Authors' affiliations

J Jones, J Bowling, J Watson, F Vega-Lopez, Department of Dermatology, The Middlesex Hospital and Hospital for Tropical Diseases, University College London Hospitals, NHS Trust, London, UK
J White, E Higgins, Department of Dermatology, King's College Hospital, London, UK

Parental consent was obtained for publication of figures

Correspondence to: Dr J M Jones, Department of Dermatology, University College London, 100 Eton Place, Eton College Road, London NW3 2DT, UK; docjenj@aol.com

IMAGES IN PAEDIATRICS

doi: 10.1136/adc.2004.063370

Successful tacrolimus (FK506) therapy in a child with pyoderma gangrenosum

A 12.5 year old boy with colitis ulcerosa, in remission for a year after colectomy, presented with an ulcer on the right lower leg. Pyoderma gangrenosum as extra-intestinal manifestation of the colitis was diagnosed. Topical tacrolimus (protopic = FK506 0.1%) twice a day was started, resulting in an initial improvement of the ulcer. As the ulcer relapsed and started to spread to untreated skin after one month, oral tacrolimus 0.1 mg/kg/day was started in addition to topical treatment. This resulted in gradual healing of the ulcer. After four months, the tacrolimus could be stopped.

Pyoderma gangrenosum is an inflammatory skin disease, characterised by destructive, deep, painful lesions at the anterior side of the legs, with irregular purple edges. In 50–75%, pyoderma gangrenosum is associated with inflammatory bowel disease, rheumatoid arthritis, chronic autoimmune hepatitis, or haematological solid tumours. The diagnosis is based on clinical presentation. There are no serological or histological markers and there is no relation between clinical activity of the

inflammatory bowel disease and pyoderma gangrenosum. Treatment depends on severity, extent, and chronicity of the skin lesions, and on previous treatment. Local treatment with corticosteroids or tacrolimus is adequate for non-chronic small lesions. In case of severe lesions, systemic treatment with tacrolimus, corticosteroids, cyclosporine A, methotrexate, or infliximab is required. In general, an initial response is seen within days to weeks, but complete remission may require months to years of treatment. This is one of the

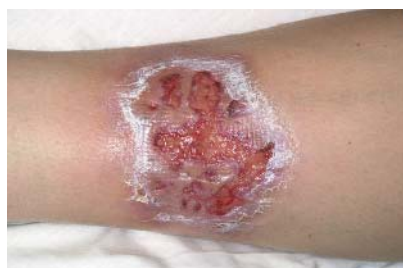

Figure 1 First presentation: ulceration at the lower leg due to pyoderma gangrenosum.

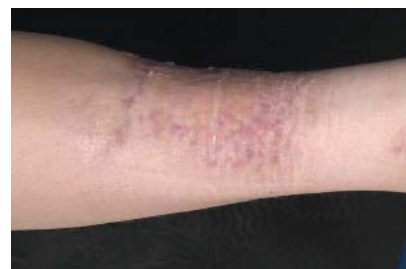

Figure 2 Complete clearing of lesions following local and systemic treatment with tacrolimus.

first reports of successful treatment of a child with pyoderma gangrenosum using tacrolimus.

J M Deckers-Kocken, S G M A Pasmans
 Wilhelmina Children's Hospital, University Medical Center Utrecht, Huispost KE01.147.0, PO Box 85090, 3508 AB Utrecht, Netherlands; j.m.deckers@umcutrecht.nl

Competing interests: the authors have no financial binding with any pharmaceutical company

Parental consent was obtained for publication of figures