

Level of conus medullaris in term and preterm neonates

F Şahin, M Selçuki, N Ecin, A Zenciroğlu, A Ünlü, F Yılmaz, N Maviş, S Saribaş

Abstract

Aims—To compare the levels of conus medullaris in preterm and term neonates; to show the time of ascent to normal; and to evaluate the babies with low conus medullaris levels for tethered cord syndrome.

Methods—Levels were assessed using ultrasonography in 41 preterm and 64 term neonates.

Results—In the preterm group the conus medullaris level in one infant (2.4%) was below L4. In three infants (7.2%) it was between L2 and L3 and in 37 infants (90.4%) it was above L2. In the term group it was below L4 in one baby (1.6%), between L2 and L3 in four (6.3%), and above L2 in 57 babies (92.1%). The difference in the conus medullaris levels between term and preterm neonates and genders was not significant. Two patients, one with a conus medullaris level at L4–L5, and the other at L2–L3, had Down's syndrome.

Conclusion—The ascent of conus medullaris seems to occur early in life. It is important to follow up patients with conus medullaris levels at or below the 4th lumbar vertebra for the development of tethered cord syndrome.

(*Arch Dis Child* 1997;77:F67–F69)

Keywords: conus medullaris; spinal cord; tethered cord; ultrasonography

Neonatal Intensive Care Unit,
Sami Ulus Children's Hospital,
Ankara,
Turkey
F Şahin
A Zenciroğlu
S Saribaş

Department of Neurosurgery, Division of Paediatric Neurosurgery,
University of Ankara School of Medicine
M Selçuki
A Ünlü

Radiology Unit,
Sami Ulus Children's Hospital
N Ecin
F Yılmaz
N Maviş

Correspondence to:
Dr Figen Şahin,
Oyak Sitesi 7, Blok No 7,
Çankaya 08550 Ankara,
Turkey.

Accepted 12 February 1997

menstrual date or by antenatal ultrasonography. In the preterm babies, corrected gestational ages were used for the evaluation of conus medullaris if ultrasound examination could not be done immediately because of the clinical instability of the babies.

Ultrasound examination was performed using an SSA 250 A machine (Toshiba, Tokyo) with a 7.5 MHz linear transducer. Infants were examined in the prone, gently flexed position. Both longitudinal and transverse sections were performed and 5th lumbar vertebra (L5) was identified by finding the lumbosacral junction and angulation at this point. The conus was marked at the end of tapering distal spinal cord which is hypoechoic and its level determined by the adjacent intervertebral disk space.

The χ^2 test was used for statistical analysis.

Results

Spinal ultrasonography was performed on a total of 106 patients (48 girls and 58 boys). In a patient with cleft lip and cleft palate and congenital hydrocephalus, conus medullaris was found below the 4th lumbar vertebra (L4), but this patient was not included in this study because of his neural defect. Of the other 105 patients, the gestational ages of 41 babies were smaller than or equal to 37 weeks, and in 64 patients gestational age was above 37 weeks.

The conus medullaris levels of these patients are shown in table 1. Conus medullaris ended at the level between the first and second lumbar vertebrae (L1–L2) in 88% and 78% of preterm and term babies, respectively. In the preterm group three patients (7.2%) had conus medullaris between the second and third lumbar vertebrae (L2–L3) and in one patient (2.4%) it was at the L4–L5 level. The gestational ages of these patients were 37, 36, 34 and 37 weeks, respectively. In one patient the level of conus medullaris, at L2–L3 at the age of 34 weeks, had ascended to L1–L2 by the age of 42 weeks. Conus medullaris was also found at the L1–L2 level in premature babies with the smallest for gestational age patients (fig 1). The difference between gestational ages and conus medullaris levels was not significant ($P>0.05$).

In the term babies, conus medullaris ended at L4–L5 in one patient (1.6%) and at L2–L3 in four (6.3%). In the other patients (92.1%) conus medullaris was above L2 level. The patient with conus medullaris at L4–L5 had severe hyponatremia and acute renal failure and died before the control ultrasonography could be carried out (fig 2).

Among the preterms two neonates, one with conus medullaris level at L4–L5 and the other with L2–L3, had Down's syndrome. The first

The medulla spinalis, which has the same length as the vertebral canal in the early fetal life, moves cranially. The precise timing of this ascent is unknown.¹ It is important to know the level of conus medullaris in both preterm and term babies to perform lumbar puncture and surgical procedures. The infants in whom lower levels of conus medullaris or thick filum terminale are determined, must be followed up for tethered cord syndrome, so that early surgical intervention can be undertaken.

Ultrasonography is safe and non-invasive and can be used to determine the level of conus medullaris, especially in infants younger than 3 months.²

Methods

In this study 41 preterm babies between 31 and 37 weeks of gestational age and 64 term babies were examined by ultrasonography to determine the levels of conus medullaris. Gestational ages were determined from the last

Table 1 Termination value of conus medullaris in premature and term neonates

Level of conus medullaris	Premature n (%)	Term n (%)	Total
T12-L1	0 (0)	5 (7.8)	5 (4.8)
L1	1 (2.4)	2 (3.1)	3 (2.8)
L1-L2	36 (88.0)	50 (78.1)	86 (81.9)
L2	0 (0)	2 (3.1)	2 (1.9)
L2-L3	3 (7.2)	4 (6.3)	7 (6.7)
Below L4	1 (2.4)	1 (1.6)	2 (1.9)
Total	41 (100)	64 (100)	105 (100)

P > 0.05.

Table 2 Conus medullaris values in female and male infants

Level of conus medullaris	Female n (%)	Male n (%)	Total
T12-L1	2 (4.2)	3 (5.3)	5 (4.8)
L1	0 (0)	3 (5.3)	3 (2.9)
L1-L2	42 (87.5)	44 (77.2)	86 (81.9)
L2	0 (0)	2 (3.5)	2 (1.9)
L2-L3	3 (6.2)	4 (7.0)	7 (6.6)
Below L4	1 (2.1)	1 (1.7)	2 (1.9)
Total	48 (100)	57 (100)	105 (100)

P > 0.05.

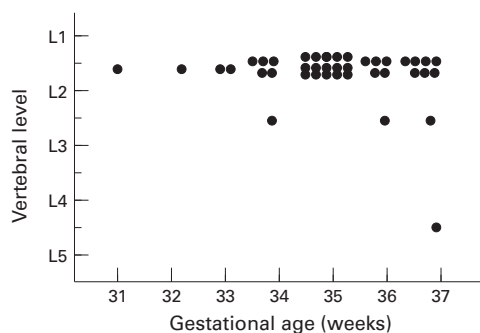


Figure 1 Vertebral level of conus medullaris in preterm babies.

of these died at home before a control ultrasound examination could be performed four weeks later. The other patient did not attend for ultrasonography. It was not known, therefore, whether the cord would have ascended.

The level of conus medullaris was not significantly different between female and male patients (table 2) (P>0.05).

Discussion

The spinal cord in adults may terminate between the last thoracic and the third lumbar vertebra, but in most of them it ends at the first or second lumbar vertebra.³ In embryonic life the elongation of the vertebral column is more rapid than that of spinal cord, resulting in ascent of the spinal cord inside the vertebral

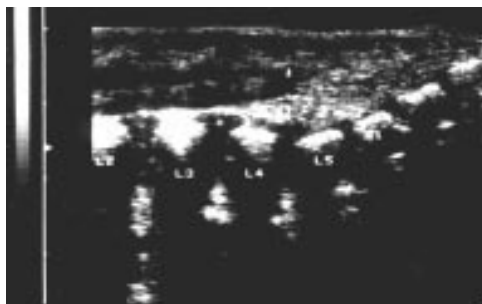


Figure 2 Ultrasonographic appearance of conus medullaris.

canal.⁴ But the precise timing of this ascent is still a matter of debate. In a study of 184 children ranging in age from newborn to 20 years, the range of conus levels was reported as T12 to L3. The range for the 0–2 year old group was T12 to L2–L3 with an average of L1–L2.⁵ They concluded that a conus level at L2–L3 or above should be considered normal at any age. In another study of preterm and term neonates, the mean position of the conus was found midway between the L1–L2 disc and midpoint of the L2 body.⁶ A small but significant rise in position was identified from 33 to 42 postconceptional weeks. In our study the mean level of conus medullaris was L1–L2 both in premature and term babies. There were no significant differences between these two groups. Studies have shown that the most rapid ascent of the conus medullaris occurs in the first half of gestation, especially between 9–16 weeks.^{3,6} The gestational age of the youngest newborn baby in our study was 31 weeks, suggesting that the ascent of the conus medullaris occurs before that age. But as the number of small premature babies in our study is limited, studies with larger numbers of patients are required.

In previous studies racial and sex differences in the level of the termination of the spinal cord have been reported.⁷ But we found no difference in the endpoints of spinal cords between boys and girls. In a study by Vettivel in 1991 a sex difference was not observed either.⁷

Several radiological techniques, such as computed tomography and magnetic resonance imaging, can be used to determine the level of the spinal cord or congenital abnormalities.⁸ But these techniques are difficult to perform, especially in young children as general anaesthesia may be required to keep them immobile. For neonates and young infants in whom the ossification of vertebral bodies is incomplete, ultrasonography of the spine is a safe, easy, and non-invasive method and is therefore preferable.^{9,10}

As the normal level of the conus medullaris does not extend below the third lumbar vertebra, the patients with lower levels should be examined for tethered cord syndrome. The tethered cord syndrome is a clinical entity manifest by progressive motor and sensory changes in the legs, incontinence, back or leg pain and scoliosis. Symptoms are caused by pressure on the spinal cord and nerve roots.¹¹ Impaired blood flow, function, and metabolism have been observed in the traumatised or compressed cord. Surgical untethering should be done not only to prevent the progress of the neurological signs and symptoms, but also to alleviate them.¹² In our study, only in two patients was the conus medullaris below the level of L3. One of these was a term baby with severe hyponatremia and acute renal failure. Spinal ultrasonography was performed only once before he died. The other patient, a 37 week gestational age baby with Down's syndrome, died at home before a control ultrasound scan could be performed. These two patients were therefore not evaluated for tethered cord syndrome.

In our study another patient with Down's syndrome had the conus medullaris level at L2-L3. Although this is in the normal range, it was lower than average. In Down's syndrome associated anomalies related to various organ systems are common and incomplete fusion of vertebral arcs is seen in 37% of these patients.¹³ Although we could not find any report of a correlation between Down's syndrome and low lying conus medullaris, our findings in these two patients have led us to consider the possible association of these two pathological entities.

We conclude that conus medullaris level is not different in preterm and term neonates, and it is above the level of L2 in more than 90% of babies. There does not seem to be any difference in the level of conus medullaris between female and male infants. It is important to follow up babies whose conus medullaris is below L2 to eliminate the tethered cord syndrome.

We thank Dr Tahsin Teziç, director of the Sami Ulus Children's Hospital, for his support and cooperation during the study.

- 1 Wolf S. The conus medullaris: time of ascendance to normal level. *Pediatr Radiol* 1992;22:590-2.
- 2 DiPietro M. The conus medullaris: Normal US findings throughout childhood. *Pediatr Radiol* 1993;188:149-53.
- 3 Barson AJ. The vertebral level of termination of the spinal cord during normal and abnormal development. *J Anat* 1970;106:489-97.
- 4 Ghazi SR. Allometric growth of the spinal cord in relation to the vertebral column during prenatal and postnatal life in the sheep. *J Anat* 1994;185:427-31.
- 5 Award JC. MR Imaging Determination of the location of the normal conus medullaris throughout childhood. *Am J Radiol* 1989;152:1029-32.
- 6 Rowland Hill CA. Ultrasound determination of the normal location of the conus medullaris in neonates. *Am J Neonat Radiol* 1995;16:469-72.
- 7 Vettivel S. Vertebral level of termination of the spinal cord in human fetuses. *J Anat* 1991;179:149-61.
- 8 O'Connor JF. Radiologic manifestations of congenital anomalies of the spine. *Radiol Clin North Am* 1991;29:407-29.
- 9 Gusnard DA. Ultrasonic anatomy of the normal neonatal and infant spine: correlation with cryomicrotome sections and CT. *Neuroradiology* 1986;28:493-511.
- 10 Award JC. Sonography of the caudal spine and back: congenital anomalies in children. *Am J Radiol* 1984;142:1229-42.
- 11 Lyons-Jones K. *Smith's recognizable pattern of human malformation*. 4th edn. Philadelphia: W.B Saunders Co, 1988:10-3.
- 12 Yamada S. Pathophysiology of tethered cord syndrome. *J Neurosurg* 1981;54:494-503.
- 13 Jacobson RI. Congenital structural defects. In: Swaiman KF, ed. *Pediatric Neurology: Principles and practice*. St. Louis: CV Mosby Co, 1989:320-1.