

CASE REPORT

Paracetamol overdose in a preterm neonate

G K Isbister, I K Bucens, I M Whyte

Abstract

The first oral overdose of paracetamol in a neonate is reported. A 55 day old neonate, born 29 weeks premature, was accidentally given 136 mg/kg paracetamol. Treatment was with activated charcoal, supportive care, and N-acetylcysteine. There was no biochemical evidence of hepatotoxicity, and no long term sequelae. After modelling of the data, the following pharmacokinetic variables were calculated: absorption half life (t_{abs}), 0.51 hours; volume of distribution (V/F_{oral}), 0.80 litres/kg; clearance (CL/F_{oral}), 0.22 litres/h; they were consistent with population pharmacokinetic studies. The increased plasma half life ($T\beta$) of 5.69 hours thus reflected normal slower metabolism in infants, rather than toxicity. The toxicity of paracetamol in neonates is unclear, but appears to be low because of slow oxidative metabolism and rapid glutathione synthesis. In an overdose, estimates of toxicity can be made from dose and $T\beta$ in neonates, or from maternal toxicity in transplacental poisoning. Treatment includes N-acetylcysteine and supportive care, with activated charcoal for oral poisoning.

(Arch Dis Child Fetal Neonatal Ed 2001;85:F70-F72)

Keywords: paracetamol; overdose; preterm; toxicity

Paracetamol is a readily available antipyretic and analgesic agent with few side effects. It is the preferred simple analgesic for children and is increasingly being used in neonates.¹ Although paracetamol overdose is common, neonatal paracetamol overdose is rare. It has been reported as the result of transplacental transfer after maternal overdose²⁻⁶ but never from oral ingestion. Management of neonatal paracetamol poisoning is currently based on limited pharmacokinetic studies in neonates and adult treatment protocols. The toxicity of paracetamol in neonates is unclear.

We report the first case of acute oral paracetamol poisoning in a neonate. The toxicokinetics (pharmacokinetics of an overdose) of paracetamol poisoning in the neonate and an approach to treatment are discussed.

Methods

Plasma paracetamol concentration was estimated using a colorimetric test (Vitros ACET

slides; ORTHO Clinical Diagnostics, Victoria, Australia). The lower limit of the reportable range was 10 mg/l. Kinetic variables were derived from plasma concentration versus time data using a first order input (no lag time), first order elimination, one compartment disposition model. The model variables were absorption half life (t_{abs} , hours), the apparent volume of distribution (V/F_{oral} , litres), and total body clearance (CL/F_{oral} , litres/h). Plasma half life ($T\beta$) was calculated from these variables. Data were analysed using MKMODEL (Biosoft, Cambridge, UK).⁷ In two previous case reports, $T\beta$ was calculated from the plasma concentrations and times supplied.^{6,8}

Case report

A 2.2 kg, 55 day old male infant (corrected gestational age 37 weeks) was prescribed 30 mg (13.6 mg/kg) paracetamol before his first triple antigen immunisation. In error, a dose of 300 mg was given by nasogastric tube. The error was realised after four hours when the next dose was due. He was otherwise well at the time of the overdose.

The infant had been delivered at 29 weeks gestation weighing 740 g. He was symmetrically small for gestational age but had few problems of prematurity. He had mild hyaline membrane disease, transient asymptomatic neutropenia, phototherapy for jaundice (maximum bilirubin 119 mmol/l) for two days, and apnoea. At the time of the overdose, he was being fed with calorie supplemented breast milk and receiving multivitamins and iron.

As soon as the overdose had been noticed, the stomach contents were aspirated; no paracetamol was returned. The paracetamol level was 121 mg/l four hours after ingestion, below the "150 treatment line" on the adult nomogram. Nasogastric charcoal was administered, and intravenous fluids (10% dextrose) were begun.

The level at eight hours was 84 mg/l, not decreasing with a $T\beta$ parallel to the treatment line (see fig 1).^{9,10} The baby was given intravenous N-acetylcysteine: 150 mg/kg over 15 minutes; 50 mg/kg over four hours; 100 mg/kg over 16 hours. Charcoal was stopped after 24 hours. N-Acetylcysteine was continued for 20 hours and was tolerated without any adverse effects.

Figure 1 shows a plot of paracetamol concentration against time. There was no increase in transaminases or bilirubin. Initially,

Royal Darwin
Hospital, Northern
Territory, Australia
G K Isbister

Royal Darwin Hospital
and Northern
Territory Clinical
School, Flinders
University
I K Bucens

Department of Clinical
Toxicology and
Pharmacology,
Newcastle Mater
Misericordiae
Hospital, Newcastle,
NSW, Australia
I M Whyte

Correspondence to:
Dr Isbister, Department of
Clinical Toxicology and
Pharmacology, Newcastle
Mater Misericordiae
Hospital, Locked Bag 7,
Hunter Region Mail Centre,
NSW 2310, Australia
gsbite@bigpond.com

Accepted 21 February 2001

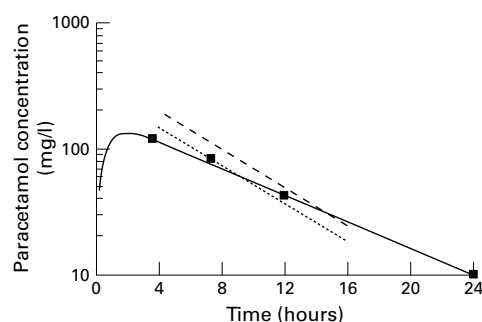


Figure 1 Plot of logarithmic plasma paracetamol concentration against time. The solid line represents the curve modelled to the data points from this case. Black squares represent real data points. The dashed line is the original treatment line based on adult patient data,¹⁰ and the dotted line is the Rumack-Matthews nomogram, 25% below the other treatment line.⁷

the international normalised ratio was slightly elevated at 1.3, but decreased to 1.0 after 48 hours. The patient was discharged from hospital six days later. He was seen in outpatients and had no further problems.

Results and discussion

Acute paracetamol overdose is relatively innocuous in young children^{8,9}; however, the sensitivity of neonates, both term and preterm, to paracetamol overdose is not clear. There are few toxicokinetic data,^{2,3} so pharmacokinetic studies need to be extrapolated to estimate kinetic variables during an overdose. Good pharmacokinetic data now exist for paracetamol in neonates and children, and show that, at birth, clearance is 62% and volume of distribution is 174% of those of older children.¹¹ This means that T_{β} is normally prolonged in neonates and slowly decreases to the adult range with increasing age. Only one study has determined T_{β} in preterm infants,¹² and it shows that 28–32 week neonates have a longer T_{β} (mean (SD) 11 (5.7) hours) than 32–36 week neonates (4.8 (1.2) hours). The nature of this overdose, a prescribing error, means that the precise timing and quantity of the drug were known. Pharmacokinetic variables were calculated: t_{obs} was 0.51 hours, V/F_{oral} was 0.80 litres/kg, and CL/F_{oral} was 0.22 litres/hour after the data had been modelled (fig 1). These are consistent with recent population pharmacokinetic studies of therapeutic paracetamol dosing.¹¹ The calculated increased T_{β} of 5.69 hours thus reflects the normal slower oxidative metabolism rather than toxicity.

Table 1 Summary of four cases of transplacental neonatal paracetamol poisoning that all occurred within 24 hours of maternal overdose, and this case of oral neonatal paracetamol poisoning

	Lederman ²	Roberts ³	Atu ⁶	Kumar ⁸	This case
Gestation (weeks)	29	36	Term	38	—
Delivery time after overdose (hours)	16	6	3	17	—
Maternal dose (g)	32.5	20	20	26	—
Maternal hepatotoxicity	Yes	No	No	No	—
Neonatal T_{β}	AST 4300 U/l	10	7.5*	5.5*	5.7
Peak AST (U/l)	86	NR	86	Normal	18 (ALT)
Prothrombin time	28	NR	44	NR	13.9
Treatment	ExTx	ExTx (maternal methionine)	NAC	Supportive (maternal NAC)	NAC, charcoal
Outcome	NAD	NAD	NAD	NAD	NAD

*Estimated from paracetamol levels supplied in the original case reports.

T_{β} , Plasma half life; AST, aspartate transaminase; ALT, alanine transaminase; NR, not reported; NAC, N-acetylcysteine; ExTx, exchange transfusion; NAD, no abnormality discovered.

Reported cases of neonatal paracetamol poisoning have all resulted from transplacentally acquired paracetamol.^{2–6} In transplacental overdose, the fetus has the added insult of maternal toxicity. If the baby is delivered within 24 hours of maternal overdose, it is less likely to be affected by maternal toxicity, and the case resembles that of an oral overdose. All reported neonatal/fetal deaths occurred when the baby was delivered more than 24 hours after the overdose; death was in utero or a spontaneous abortion occurred.^{4,5} The only series of paracetamol overdoses in pregnancy reported a 17.7% incidence of fetal death, which was not significantly different from national statistics of spontaneous abortions.⁴ Four cases of infants delivered within 24 hours of a maternal overdose have been reported,^{2,3,6,8} and they are summarised in table 1. In the first, the potential for toxicity was greatest with maternal hepatotoxicity and a prolonged T_{β} . In two cases, the authors suggested that the moderately elevated prothrombin time immediately after birth indicated hepatotoxicity.^{2,6} However, about half of patients suffering from a paracetamol overdose without hepatotoxicity have an abnormal international normalised ratio. This increase appears to be due to inhibition of activation of vitamin K dependent coagulation factors (mainly factor VII), and is independent of hepatotoxicity.¹³ The isolated increase in prothrombin time in these cases does not represent hepatotoxicity and is either due to prematurity or is the direct effect of paracetamol on coagulation factors. The good outcome in neonates born within 24 hours of maternal overdose, despite significant maternal toxicity in one case,² suggests that acute paracetamol poisoning is relatively harmless in neonates. A combination of the slower production of toxic metabolite in fetal livers and an increased rate of glutathione synthesis may explain this reduced toxicity.^{1,3}

Predicting potential toxicity in neonates is difficult. In oral paracetamol poisoning, the dose can be estimated. The safe oral dose in neonates is not known, but is unlikely to be less than 150 mg/kg and may be as high as 200 mg/kg.⁹ In transplacental overdoses, an estimate of toxicity is better made from maternal dose and severity of maternal hepatotoxicity. An increased T_{β} of paracetamol in adult overdoses is a good predictor of hepatotoxicity and outcome,¹⁰ but this has not been validated in

Table 2 Suggested indications for N-acetylcysteine treatment in neonatal paracetamol poisoning

Transplacentally acquired poisoning	Oral poisoning
Potentially toxic maternal overdose (adult criteria)	Ingested dose >150 mg/kg
Maternal hepatotoxicity	Four hour paracetamol level above 150 treatment line on adult nomogram
Significant increase in T _β compared with estimated normal T _β for age	Significant increase in T _β compared with estimated normal T _β for age

children or neonates.¹⁻³ In five cases of neonatal paracetamol poisoning for which T_β was calculated (including ours),^{2,3,6,8} it was longer than four hours. This is probably a reflection of a decreased V/F_{oral} and increased CL/F_{oral} at birth.¹¹ In neonatal paracetamol poisoning, the plasma T_β should be determined and compared with the expected normal values in neonates of similar age.¹¹ The use of adult nomograms in neonatal poisoning has problems,¹⁰ and, being based on a T_β of four hours, should only be used as a guide before T_β determination.

Treatment of neonatal paracetamol overdose to date has been based on adult studies.¹⁰ Early treatment of the mother is essential with the more common transplacental overdose. In a series of 60 paracetamol overdoses in pregnancy, only gestational age and time to N-acetylcysteine treatment were shown to be significant predictors of fetal death.⁴ The benefit of maternal N-acetylcysteine treatment to the fetus is twofold: prevention of maternal toxicity prevents adverse effects on the fetus; N-acetylcysteine crosses the placenta⁵ and detoxifies the toxic metabolite N-acetyl-p-benzoquinone imine formed by the fetal liver. Activated charcoal has been used in neonates and appears to be safe for treatment of oral overdose.¹⁴

Oral absorption of paracetamol in term neonates is slow¹¹ and may continue for up to three hours. Activated charcoal is potentially

beneficial within this time period. Treatment with N-acetylcysteine is based on adult studies,³ but is safe in pregnancy^{4,5} and neonates.⁶ We suggest a low threshold for N-acetylcysteine administration; table 2 gives suggested indications in neonatal poisoning. These are probably excessive given the apparent safety of paracetamol in neonates, but appropriate until further data are available.

Thanks go to Dr Peter Loughnan for helpful comments on the manuscript.

- 1 Anderson BJ. What we don't know about paracetamol in children. *Paediatr Anaesth* 1998;8:451-60.
- 2 Lederman S, Fysh WJ, Tredger M, et al. Neonatal paracetamol poisoning: treatment by exchange transfusion. *Arch Dis Child* 1983;58:631-3.
- 3 Roberts I, Robinson MJ, Mughal MZ, et al. Paracetamol metabolites in the neonate following maternal overdose. *Br J Clin Pharmacol* 1984;18:201-6.
- 4 Riggs BS, Bronstein AC, Kulig K, et al. Acute acetaminophen overdose during pregnancy. *Obstet Gynecol* 1989;74:247-53.
- 5 Horowitz RS, Dart RC, Jarvie DR, et al. Placental transfer of N-acetylcysteine following human maternal acetaminophen toxicity. *J Toxicol Clin Toxicol* 1997;35:447-51.
- 6 Aw MM, Dhawan A, Baker AJ, et al. Neonatal paracetamol poisoning. *Arch Dis Child Fetal Neonatal Ed* 1999;81:F78.
- 7 MKMODEL Version 5 (computer program). Holford NH.5. 49 Bateman St, Cambridge, UK: Biosoft, 1994.
- 8 Kumar A, Goel KM, Rae MD. Paracetamol overdose in children. *Scott Med J* 1990;35:106-7.
- 9 Anderson BJ, Holford NH, Armishaw JC, et al. Predicting concentrations in children presenting with acetaminophen overdose. *J Pediatr* 1999;135:290-5.
- 10 Prescott LF, Roscoe P, Wright N, et al. Plasma-paracetamol half-life and hepatic necrosis in patients with paracetamol overdosage. *Lancet* 1971;1:519-22.
- 11 Anderson BJ, Woollard GA, Holford NH. A model for size and age changes in the pharmacokinetics of paracetamol in neonates, infants and children. *Br J Clin Pharmacol* 2000;50:125-34.
- 12 van Lingen RA, Deinum JT, Quak JM, et al. Pharmacokinetics and metabolism of rectally administered paracetamol in preterm neonates. *Arch Dis Child Fetal Neonatal Ed* 1999;80:F59-63.
- 13 Whyte IM, Buckley NA, Reith DM, et al. Acetaminophen causes increased International Normalized Ratio by reducing functional factor VII. *Ther Drug Monit* 2000;22:742-8.
- 14 Burkhart KK, Metcalf S, Shurnas E, et al. Exchange transfusion and multidose activated charcoal following vancomycin overdose. *J Toxicol Clin Toxicol* 1992;30:285-94.