

PostScript

LETTER

If you have a burning desire to respond to a paper published in *ADC* or *F&N*, why not make use of our "rapid response" option?

Log on to our website (www.archdischild.com), find the paper that interests you, click on "full text" and send your response by email by clicking on "submit a response".

Providing it isn't libellous or obscene, it will be posted within seven days. You can retrieve it by clicking on "read eLetters" on our homepage.

The editors will decide, as before, whether to also publish it in a future paper issue.

Examination of the neonatal palate

Isolated midline cleft of the soft palate occurs in approximately half of all cases of cleft palate, giving an incidence of 5 per 10 000 newborn caucasian babies per year. High risk groups include family history, maternal exposure to certain teratogens, and as part of certain syndromes. During the routine neonatal examination, Rennie advises that the palate is seen directly, "palpation is not enough".¹ However, palpation is often used as an adjunct, with the expectation that the gag reflex will allow the palate to be seen. In the past year, two neonates in this region have been diagnosed as having a cleft soft palate because of feeding difficulties after a "normal" routine examination (1/750 babies).

We therefore audited whether the soft palate can be adequately visualised during routine examination. A total of 125 babies received a routine neonatal check by junior medical staff. Examination of the palate was visual if the baby spontaneously yawned or cried, by palpation with the little finger otherwise, and an attempt was made to view the palate if the baby gagged.

Figure 1 shows the results. Examiners visualised the soft palate in 18/125 babies (14%). Although more experienced examiners might have visualised more soft palates, these figures show that a minority of babies have a complete examination of the soft palate during the normal clinical examination. Visualisation of the soft palate was found to be possible with a laryngoscope in all babies, but we feel its routine use would be unduly invasive. We would therefore recommend that babies continue to be examined by visualisation of the palate, but that examiners are aware of the limitations of this procedure and

that examination with a laryngoscope is carried out:

- for any baby with a family history of cleft palate;
- any baby exposed in utero to teratogenic drugs;
- any baby with a syndrome associated with cleft palate;
- any baby with feeding difficulties, particularly if milk comes down the nose.

H Armstrong
R M Simpson

Child Health Directorate, Dumfries & Galloway
Royal Infirmary, Bankend Road, Dumfries
DG1 4AP, Scotland, UK;
r.simpson@dgri.scot.nhs.uk

Reference

- 1 Rennie JM, Gandy GM. Examination of the newborn. In: Robertson NRC, Rennie JM, eds. *Textbook of neonatology*. Edinburgh: Churchill Livingstone, 1999:274.

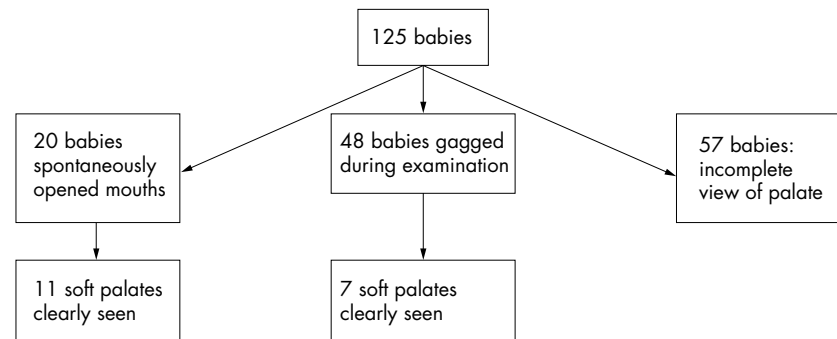


Figure 1 Examination of neonatal palate in 125 babies.