

CASE REPORT

Dehydrated hereditary stomatocytosis with transient perinatal ascites

A P Basu, P Carey, T Cynober, M Chetty, J Delaunay, G W Stewart, S Richmond

Arch Dis Child Fetal Neonatal Ed 2003;**88**:F438–F439

The case is reported of a mother and baby with dehydrated hereditary stomatocytosis and perinatal ascites, an autosomal dominant condition not previously reported in Britain. Recognition is important for the management of pregnancy and for avoidance of splenectomy which, if performed, can predispose the patient to fatal thromboembolic events.

A 29 year old primigravida was noted to have fetal non-immune hydrops from 19 weeks. Fetal pleural effusions, ascites, and skin oedema were observed, although the kidneys and heart appeared normal (fig 1). Fetal haemoglobin was 104 g/l and the karyotype 46XY. No infective cause was identified. Pleural effusions resolved but ascites persisted. Polyhydramnios developed and an amnioreduction was performed at 28 weeks. Fetal ascites was also drained (390 ml at 28 weeks and 360 ml at 31 weeks) to improve lung growth. Normal vaginal delivery at 32 weeks followed spontaneous onset of preterm labour.

At birth he was electively intubated and ventilated for 12 hours. The abdomen was soft and distended with poorly formed abdominal musculature (fig 2). Genitalia were normal, and ultrasound showed ascites with no other abnormality.

Over five weeks, 1155 ml straw coloured ascitic fluid containing variable lymphocyte numbers was removed (protein 20.8 g/l, glucose and electrolyte concentrations as plasma), after which there was no reaccumulation. Haemoglobin was 159 g/l at birth, mean corpuscular volume 95–97 fl, with anisocytosis, occasional fragments, and target cells. White cells and platelets were normal. He received three blood transfusions in the first two months of life; lowest haemoglobin concentration was 75 g/l.

The maternal grandmother mentioned that the baby's mother had had ascites at birth. The mother's microfilmed neonatal notes showed that she was born with unexplained

ascites which resolved after drainage in the first 24 hours. She still has very poor abdominal muscle development and cannot sit up from the supine position. She had a normal karyotype and had no evidence of cytomegalovirus or toxoplasmosis. At 13 years of age, she presented with anaemia, jaundice, splenomegaly, gallstones, and persistent macrocytosis. A blood film showed reticulocytosis (14%), anisopoikilocytosis, schistocytes, and target cells (fig 3). Her haemolytic anaemia was extensively investigated, a striking finding being decreased osmotic fragility. Ham's test was normal, as were screening tests for glucose-6-phosphate dehydrogenase deficiency and pyruvate kinase deficiency. There was no evidence of thalassaemia. Bone marrow investigations showed active erythropoiesis with minor dyserythropoietic changes. Recurrent abdominal pain led to cholecystectomy at 15 years. Studies showed no evidence of preferential splenic sequestration or destruction, so splenectomy was not performed. After extensive investigations, including electron microscopy, her well compensated mild haemolytic anaemia (typical haemoglobin concentration 100 g/l) had been labelled a "congenital dyserythropoietic anaemia" without any real conviction.

It seemed clear that mother and son had the same dominantly inherited and relatively benign problem of intrauterine ascites, possibly associated with the mother's

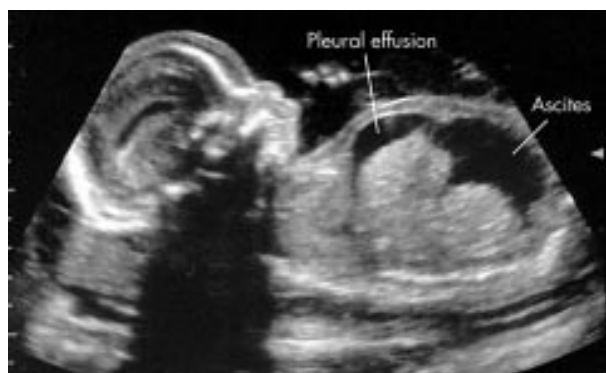

Figure 1 Scan at 23 weeks gestation.

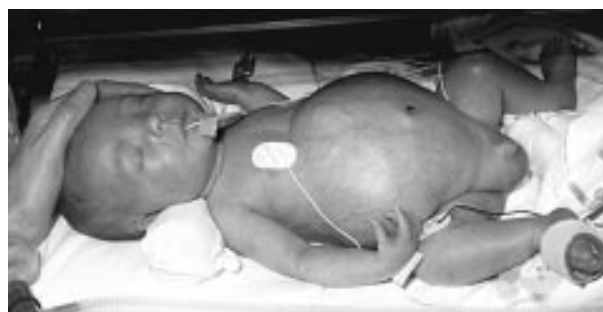

Figure 2 Photograph of baby soon after birth.




Figure 3 Blood film of the mother.

Table 1 Red cell indices, osmotic gradient ektacytometry variables, intracellular [Na⁺] and [K⁺] and isotopic K⁺ influx

	Haematological indices					Osmotic gradient ektacytometry			Intracellular electrolytes (mmol/l cells)		K ⁺ (86Rb) influx at 5 mM external [K ⁺] (mmol/(l cells.h))		
	Hb (g/l)	MCV (fl)	MCHC (g/l)	Retics (%)	Stmtcyts	O _{min} (mosmol/kg)	DI _{max} (arbitrary units)	O' (mosmol/kg)	Na ⁺	K ⁺	Pump	Cotr	Leak
Child	112	87.4	372	5.5	+	125	0.46	312	18.4	88.7			
Mother	99	103.6	363	2.7	+	147	0.47	333	11.48	102.2	3.539	0.252	0.140
Father	158	88.9	355	1.7	-	161	0.41	346	8.93	99.1			
Normal	120–180	85–96	300–350	<2		143–163	0.41–0.53	335–375	5–11	85–105	1–2	0–1	0.05–0.10

Hb, Haemoglobin; MCV, mean corpuscular volume; MCHC, mean corpuscular haemoglobin concentration; Retics, reticulocytes; Stmtcyts, stomatocytes; O_{min}, osmotic fragility; DI, deformability index; O', measure of cellular hydration; Cotr, Na⁺/K⁺ cotransport.

mild haemolytic anaemia. A search of OMIM (Online Mendelian Inheritance in Man; <http://www.ncbi.nlm.nih.gov/omim>) using “ascites, intrauterine” yielded two options, one of which was “dehydrated hereditary stomatocytosis”. (Interestingly “perinatal, ascites” yields five options including dehydrated hereditary stomatocytosis, but “fetal, ascites” yields 17 options and does not include dehydrated hereditary stomatocytosis.) Examination of the photograph in Entezami *et al* strongly suggested that this was the correct diagnosis.

Red cell investigations showed high mean corpuscular haemoglobin concentration readings in mother and baby (table 1). In osmotic gradient ektacytometry, O_{min} corresponds to the osmotic fragility and is below the lower limit of normal in the baby and at the lower limit in the mother. Deformability index is not abnormal, but the parameter O', a measure of cellular hydration, is reduced in both the mother and baby. Both have abnormally high intracellular Na⁺ levels. Isotopic flux measurements for K⁺ show increased ouabain+bumetanide resistant (“leak”) K⁺ influx and increased ouabain sensitive “Na⁺/K⁺ pump” rates typical of a mild leaky red blood cell condition.

DISCUSSION

The “hereditary stomatocytoses” form a group of rare haemolytic conditions in which abnormal sodium and potassium handling by the erythrocyte membrane is a prominent feature.²

Dehydrated hereditary stomatocytosis is the most common single variant (OMIM 603528). Despite the name, stomatocytes may be very scarce or even absent and the term “hereditary xerocytosis” is often used for this variant. In most pedigrees, it is purely a red cell disease. In some families, as here, it forms part of a pleiotropic syndrome which extends beyond haematology.^{1,3,4} This syndrome can combine dehydrated hereditary stomatocytosis, perinatal oedema, and pseudohyperkalaemia (artificially high plasma K⁺ levels due to in vitro loss of K⁺ from red cells at room temperature) in any combination, even within a given family. There may also be wide interfamily differences. In some families, the ascites remains an ultrasound finding which disappears before birth.⁵ In others, fetal oedema can be severe (potentially lethal if effective treatment is not given).⁶ Antenatal drainage of the ascites may be necessary to improve lung growth. Chylous ascites can be seen after oral feeding. Osmotic gradient ektacytometry shows in one test the decrease in osmotic fragility (leftward shift of O_{min}) and cell dehydration (leftward shift of O').^{3,4}

These conditions map to a locus on chromosome 16,⁴ but the mutant gene responsible, the exact red cell membrane defect, how the ascites is produced, why it is transient, and

how this relates to the red cell defect are all unknown. Mild fetal anaemia cannot account for the ascites, and any suggested mechanism must account for its resolution in the first months of life.

The importance of this rare condition lies in its relatively benign prognosis compared with the more common and more devastating causes of non-immune fetal hydrops (parvovirus infection, cardiac malformation or dysfunction, and aneuploidy). Correct diagnosis of the anaemia is also important because there is a serious risk of ultimately fatal thromboembolic events if splenectomy is performed in patients with hereditary stomatocytosis.⁷

ACKNOWLEDGEMENTS

We are most grateful to the family described for permission to report this case. We also thank the Sir Jules Thorn Trust for financial support of the laboratory of GWS.

Authors' affiliations

A P Basu, P Carey, S Richmond, Sunderland Royal Hospital, Sunderland SR4 7TP, UK

T Cynober, J Delaunay, Service d'Hématologie, d'Immunologie et de Cytogénétique, Hôpital de Bicêtre, 94275 Le Kremlin-Bicêtre, France

M Chetty, G W Stewart, Department of Medicine, University College London, London WC1E 6JJ, UK

Correspondence to: Dr Richmond, Neonatal Unit, Sunderland Royal Hospital, Sunderland SR4 7TP, UK; Sam.Richmond@ncl.ac.uk

Accepted 8 October 2002

REFERENCES

- Entezami M, Becker R, Menssen HD, *et al*. Xerocytosis with concomitant intrauterine ascites: first description and therapeutic approach. *Blood* 1996;**87**:5392–3.
- Stewart GW, Turner E. The hereditary stomatocytoses and allied disorders: congenital disorders of erythrocyte membrane permeability to Na and K. *Bailliere's Best Practice in Research and Clinical Haematology* 1999;**12**:707–28.
- Grootenboer S, Schischmanoff PO, Cynober T, *et al*. A genetic syndrome associating dehydrated hereditary stomatocytosis, pseudohyperkalaemia and perinatal oedema. *Br J Haematol* 1998;**103**:383–6.
- Grootenboer S, Schischmanoff PO, Laurendeau I, *et al*. Pleiotropic syndrome of dehydrated hereditary stomatocytosis, pseudohyperkalaemia and perinatal edema maps to 16q23-q24. *Blood* 2000;**96**:2599–605.
- Grootenboer S, Barro C, Cynober C, *et al*. Dehydrated hereditary stomatocytosis: a cause of prenatal edema. *Prenat Diagn* 2001;**21**:1114–18.
- Grootenboer-Mignot S, Crétién A, Laurendeau I, *et al*. Nearly lethal hydrops as a manifestation of dehydrated hereditary stomatocytosis in two consecutive pregnancies. *Prenat Diagn* 2003; in press.
- Stewart GW, Amess JAL, Eber S, *et al*. Thrombo-embolic disease after splenectomy for hereditary stomatocytosis. *Br J Haematol* 1996;**93**:303–10.