

## LETTERS TO THE EDITOR

### Unsuspected infectious crystalline keratopathy masquerading as corneal graft rejection

EDITOR.—Infectious crystalline keratopathy (ICK) is a condition in which there is a chronic and insidious non-inflammatory bacterial infiltration of the cornea. It is thought to have the distinct appearance of snowflake-like branching crystals on slit-lamp examination. We present a case of ICK occurring in a corneal graft which presented with the signs of graft rejection. ICK was not suspected clinically, but was diagnosed by histological examination of the failed graft.

#### CASE REPORT

A fit 90-year-old woman underwent uneventful left extracapsular cataract extraction, posterior chamber lens (PMMA) implantation, and penetrating keratoplasty using an organ cultured cornea, for bullous keratopathy secondary to Fuchs' endothelial dystrophy.

Postoperatively, prednisolone eyedrops 1%, 2 hourly and chloramphenicol eyedrops were administered. A large epithelial defect had disappeared by day 5, when she was discharged home. At 1 month there was diffuse superficial punctate erosions on the graft epithelium and an excessive number of unexplained stromal folds persisted. Treatment was changed to preservative free prednisolone 0.5% eyedrops and chloramphenicol eyedrops. In the eighth week the graft stroma remained thickened and extensive fine and one large endothelial keratic precipitates (KPs) appeared over a few days (Fig 1). The corneal epithelium was intact, no stromal infiltrate was present, and the anterior chamber was quiet. Intraocular pressure was normal. A diagnosis of acute graft rejection was made and the patient was treated with hourly prednisolone 1% eyedrops. The KPs disappeared slowly but stromal oedema persisted. During hospitalisation a transient epithelial defect appeared in the graft. Because of persistent corneal oedema and poor vision, the patient underwent repeat left penetrating keratoplasty 5 months after her original operation.

Histological examination of the recipient's corneal disc confirmed Fuchs' endothelial dystrophy, with no evidence of inflammation or infection. The failed corneal graft showed epithelial oedema and central thinning, and

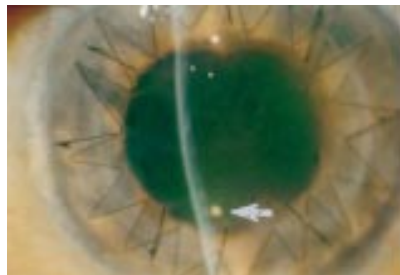


Figure 1 Slit-lamp photograph of left corneal graft at 8 weeks. Note the white eye, thickened cornea, fine endothelial keratic precipitates (KPs), and one large KP (arrow). No stromal infiltrate is present.

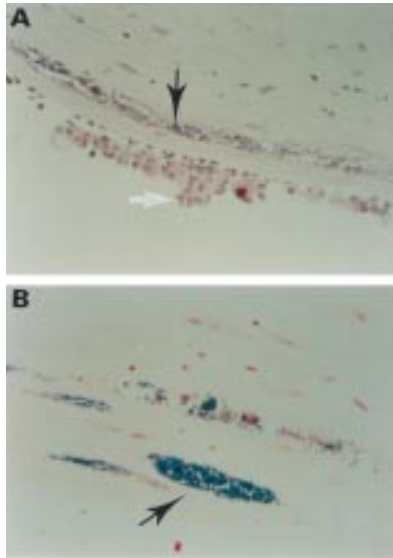


Figure 2 Photomicrograph of failed corneal graft showing infectious crystalline keratopathy. (A) (Haematoxylin and eosin,  $\times 150$ ) shows clumps of macrophages (white arrow) adherent to the (intact) corneal endothelium, and deep intralamellar pockets of bacteria (black arrow). (B) (Gram's stain,  $\times 200$ ) demonstrates clumps of Gram positive bacteria (arrow) and the absence of surrounding inflammation.

discontinuities were evident in Bowman's layer. A few neutrophil polymorphs permeated the deeper corneal fibres but at the periphery there were abundant Gram positive cocci (Fig 2). There was moderate endothelial cell loss. Adherent to the posterior corneal surface were numerous collections of histiocytes including pigment containing macrophages (Fig 2). Based on these appearances the diagnosis of bacterial infection causing crystalline keratopathy was made.

#### COMMENT

Infectious crystalline keratopathy was first recognised in the mid 1980s.<sup>1-3</sup> It is a non-inflammatory bacterial colonisation which has been described in corneal transplants<sup>1-3</sup> and in corneas previously affected by herpes simplex or *Acanthamoeba*.<sup>4</sup> ICK is associated with the prolonged use of topical steroids<sup>2,3</sup> and it has the characteristic appearance of multifocal, white, branching, crystalline, needle-like, progressive stromal opacities associated with little inflammation.<sup>1</sup> Light microscopy shows intrastromal pockets of bacteria, usually Gram positive cocci, with minimal inflammatory infiltrate. *Streptococcus viridans* ( $\alpha$  haemolytic) is the commonest organism to be isolated<sup>5</sup> but culture is often unsuccessful and specific culture conditions may be required.<sup>6</sup> The conjunctival flora has been implicated as the source of bacteria. Possible routes of bacterial entry include persistent epithelial defects,<sup>2,3</sup> migration along suture tracks,<sup>1,7</sup> and compromised epithelium due to herpetic keratitis.<sup>2</sup>

In our patient, although an intermittent epithelial defect occurred, the stromal oedema, absence of stromal infiltrate, and presence of

extensive KPs on the donor endothelium suggested graft rejection rather than microbial keratitis. However, histopathology revealed the KPs to be macrophages (not lymphocytes) and intralamellar Gram positive bacteria were noted, typical of ICK. We presume the persistent stromal oedema was secondary to endothelial dysfunction and intralamellar bacterial infiltration, despite a reasonable complement of endothelial cells. We are not aware of other descriptions of ICK masquerading as graft rejection.

Early recognition and suspicion of ICK is important. Management consists of reduction and withdrawal of topical steroids and prolonged intensive treatment with topical antibiotics.<sup>5</sup> The response to antimicrobial treatment may be poor, possibly because of poor intralamellar penetration or drug resistance. Despite the treatments described, the consequence may be graft failure requiring repeat penetrating keratoplasty.<sup>1,3,5</sup>

This case of ICK masquerading as graft rejection highlights the diversity of presentation of ICK. It should be at least considered in cases of suspected graft rejection, particularly if there are atypical features.

DANNY A MORRISON

GERRY T FAHY

Department of Ophthalmology, Leicester Royal Infirmary NHS Trust, Leicester LE1 5WW

LAURENCE J R BROWN

Department of Histopathology, Leicester Royal Infirmary NHS Trust, Leicester LE1 5WW

Correspondence to: Mr D A Morrison, Department of Clinical Genetics, Molecular Medicine Centre, Western General Hospital, Crewe Road, Edinburgh EH4 2XU.

Accepted for publication 18 March 1997

- 1 Gorovoy MS, Stern GA, Hood CI, Allen C. Intrastromal noninflammatory bacterial colonization of a corneal graft. *Arch Ophthalmol* 1983;101:1749-52.
- 2 Meisler DM, Langston RHS, Naab TJ, Aaby AA, McMahon JT, Tubbs RR. Infectious crystalline keratopathy. *Am J Ophthalmol* 1984;97:337-43.
- 3 Dunn S, Magnen E, Rao NA. Noninflammatory bacterial infiltration of a corneal graft. *Cornea* 1985;4:189-93.
- 4 Davis RM, Schroeder RP, Rowsey JJ, Jensen HG, Tripathi RC. Acanthamoeba keratitis and infectious crystalline keratopathy. *Arch Ophthalmol* 1987;105:1524-7.
- 5 Watson AP, Tullo AB, Kerr-Muir M, Ridgway AE, Lucas DR. Arborescent bacterial keratopathy (infectious crystalline keratopathy). *Eye* 1988;2:517-22.
- 6 Ormerod LD, Ruoff KL, Meisler DM, Wasson PJ, Kintner JC, Dunn SP. Infectious crystalline keratopathy. Role of nutritionally variant streptococci and other bacterial factors. *Ophthalmology* 1991;98:159-69.
- 7 James CB, McDonnell PJ, Falcon MG. Infectious crystalline keratopathy. *Br J Ophthalmol* 1988;72:628-30.

### Angle closure glaucoma as a presenting sign of Vogt-Koyanagi-Harada syndrome

EDITOR.—Vogt-Koyanagi-Harada (VKH) syndrome is an uncommon disorder characterised by panuveitis in association with neurological and cutaneous abnormalities including headache, tinnitus, vitiligo, poliosis, and alopecia. VKH syndrome almost always affects more heavily pigmented individuals, and is seen in women more than twice as often

as men, typically in the third and fourth decades of life. The aetiology of VKH syndrome is unknown, although an autoimmune reaction to shared uveal, dermal, and meningeal melanocytes seems most probable.<sup>1</sup>

We describe here three patients with VKH syndrome who presented with angle closure glaucoma.

#### CASE REPORTS

##### Case 1

A 37-year-old Asian Indian woman presented with a 4 day history of bilateral eye pain, redness, decreased vision, and headache. Vision was right eye 6/36 and 6/6 left eye. Intraocular pressure was 22 mm Hg in the right and 27 mm Hg in the left eye. Anterior chamber examination showed marked shallowing bilaterally. Gonioscopy revealed closed angles. The optic discs were slightly oedematous with a cup to disc ratio of 0.2 bilaterally. The patient was placed on pilocarpine 2% and bilateral peripheral laser iridotomies were performed but with no change in anterior chamber depth. Three weeks after laser iridotomy the patient represented with decreased vision, moderate anterior chamber inflammation, and iris nodules. Fundus examination showed mild vitritis and massive exudative retinal detachments in each eye. The patient was diagnosed with VKH syndrome and improved quickly on local and systemic corticosteroids.

##### Case 2

A 42-year-old Asian Indian man presented with decreased vision, eye redness, and severe headache of 4 days' duration. Vision was 6/36 in the right and 6/60 in the left eyes. Intraocular pressure was 26 mm Hg bilaterally. Anterior chamber examination showed marked shallowing with no angle structures visible on gonioscopy in either eye. Fundus examination showed a cup to disc ratio of 0.3 bilaterally. The patient was placed on pilocarpine 2% and peripheral laser iridotomies were performed but with no change in anterior chamber depth. The patient returned 2 weeks later with severe headache, mildly elevated intraocular pressure, and moderate anterior chamber and vitreous inflammation with total exudative retinal detachments in each eye. The patient was diagnosed with VKH syndrome, and improved quickly on local and systemic corticosteroids.

##### Case 3

A 16-year-old Asian Indian woman presented with decreased vision in each eye, severe headache, and tinnitus of 2 weeks' duration. Vision was 2/60 in the right eye and counting fingers in the left. Intraocular pressure was 21 mm Hg in the right eye and 24 mm Hg in the left. Anterior chamber examination showed mild inflammation and marked shallowing. Scleral spur was barely visible by gonioscopy in each eye. Fundus examination revealed mild vitritis, moderate optic disc swelling with a cup to disc ratio of 0.2, and near total exudative retinal detachments bilaterally. The patient was diagnosed with VKH syndrome, and treated with local and systemic corticosteroids. The intraocular inflammation subsided and intraocular pressures normalised quickly, but the exudative retinal detachments resolved slowly leaving widespread retinal pigment epithelial atrophy and a vision of 2/60 bilaterally.

#### COMMENT

We described three patients with VKH syndrome who presented with angle closure glaucoma. Intraocular pressures were only mildly elevated despite gonioscopic angle closure in each patient. Moreover, laser iridotomies, although performed promptly in two patients, failed to produce anterior chamber deepening. While angle closure glaucoma is reported to be a rare presentation for VKH syndrome,<sup>2-10</sup> our three patients constituted about 3% of the total cohort of 98 patients with this disorder seen in the uveitis clinic at Aravind Eye Hospital in Madurai, India, between January 1993 and January 1996. Ophthalmologists should consider VKH syndrome in patients who present with angle closure glaucoma, particularly in populations known to be at risk, and in the setting of significant anterior or posterior chamber inflammation.

This work was supported by a grant from the De Loris Lange Foundation for International Eye Research.

S R RATHINAM  
P NAMPERUMALSAMY  
Aravind Eye Hospital and Postgraduate  
Institute of Ophthalmology,  
Madurai - 625 020, India

ROBERT A NOZIK  
EMMETT T CUNNINGHAM JR  
The Francis I Proctor Foundation and  
the Department of Ophthalmology,  
UCSF, Medical Center, San Francisco,  
CA 94143-0944, USA

Correspondence to: Dr Emmett T Cunningham, Jr.  
Accepted for publication 12 February 1997

- 1 Moorthy RS, Inomata H, Rao NA. Vogt-Koyanagi-Harada syndrome. *Surv Ophthalmol* 1995;39:265-92.
- 2 Fujishima M. A case with acute diffuse choroiditis (Harada). *Acta Soc Ophthalmol Jpn* 1930; 34(suppl):486-91.
- 3 Hatta M, Kumagai A, Takeda H. Increased ocular tension as an initial sign of disease of Harada. *Jpn J Clin Ophthalmol* 1968;22:721-5.
- 4 Kimura R, Suzuki A, Maekawa N. Four cases of secondary angle-closure glaucoma caused by Harada's disease. *Jpn J Clin Ophthalmol* 1972; 26:827-30.
- 5 Toimori S, Uyama M. Shallow anterior chamber and transient myopia as initial signs of Harada's disease. *Jpn J Clin Ophthalmol* 1977;31:1271-3.
- 6 Shirato S, Hayashi K, Masuda K. Acute angle-closure glaucoma as an initial sign of Harada's disease. Report of two cases. *Jpn J Ophthalmol* 1980;24:260-6.
- 7 Kimura R, Sakai M, Otabe H. Transient shallow anterior chamber as initial symptom in Harada's syndrome. *Arch Ophthalmol* 1981;99:1604-6.
- 8 Kimura R, Kasai M, Shoji K, Kanno C. Swollen ciliary processes as an initial symptom in Vogt-Koyanagi-Harada syndrome. *Am J Ophthalmol* 1983;95:402-3.
- 9 Kawano Y-I, Tawara A, Nishioka Y, Suyama Y, Sakamoto H, Inomata H. Ultrasound biomicroscopic analysis of transient shallow anterior chamber in Vogt-Koyanagi-Harada syndrome. *Am J Ophthalmol* 1995;121:720-3.
- 10 Gohdo T, Tsukahara S. Ultrasound biomicroscopy of shallow anterior chamber in Vogt-Koyanagi-Harada syndrome. *Am J Ophthalmol* 1996;122:112-4.

#### Schwartz-Matsuo syndrome: atypical presentation as acute open angle glaucoma

EDITOR.—Schwartz-Matsuo syndrome describes a condition characterised by rhegmatogenous retinal detachment, with 'cells' in the anterior chamber and elevated intraocular pressure, often in the evening.<sup>1</sup> The detachment is typically caused by a dialysis at the ora serrata or a break in the non-pigmented epithelium of the pars plana or pars plicata of the ciliary body.<sup>2,3</sup> The elevated intraocular

pressure is usually discovered incidentally at the time of diagnosis of the retinal detachment, and resolves without specific treatment when the retina is reattached. We present a case in which the reverse was found. The patient presented with acute open angle glaucoma and the retinal detachment was found incidentally.

#### CASE REPORT

A 24-year-old man presented with a 1 day history of pain in the right eye and blurred vision, following 6 months of intermittent episodes of blurring of vision in that eye. He reported being kicked in this eye by his 2-year-old son 6 months previously. Corrected visual acuity was 6/12 right eye and 6/5 left eye. The right eye showed mild conjunctival injection, with moderate epithelial oedema of the cornea, cells in the anterior chamber, and intraocular pressures of 56 mm Hg right eye and 18 mm Hg left eye (applanation). Neither the drainage angle nor the peripheral retina of the right eye could be seen at this time because of the corneal oedema, but the posterior pole showed no abnormality. The left eye was normal with open angle on gonioscopy.

An initial diagnosis of Posner-Schlossman syndrome was made<sup>4</sup> and treatment started with acetazolamide 500 mg intravenously, followed by oral acetazolamide and betamethasone eyedrops. The following morning the pain had settled and intraocular pressure was 20 mm Hg in the right eye. The cornea was clear and gonioscopy revealed an open angle. Anterior chamber cells were less frequent.

Following this initial response the anterior chamber cellular activity continued to fluctuate despite the use of topical corticosteroids. In addition, the intraocular pressure varied between 10 and 46 mm Hg the higher reading always occurring in the evening, despite the use of topical  $\beta$  blockers and oral acetazolamide to a maximum dose of 250 mg four times a day. Two weeks after initial presentation 'tobacco dust' pigmentation was identified in the anterior vitreous, together with a shallow inferonasal detachment of the retina extending from the 2 o'clock to the 8 o'clock meridian, sparing the macula. The longstanding nature of the detachment was suggested by the presence of wrinkling of the retinal surface and a 'high water mark' line in the mid periphery. No retinal break was identified but the detachment was treated by cryotherapy and circumferential external plumbage of the nasal hemisphere in the area of the expected break.

Following surgery the intraocular pressure returned to normal within 48 hours, with gradual clearing of cells from the anterior chamber. All topical and systemic medications were discontinued within 2 weeks with no further increase in intraocular pressure or recurrence of aqueous cells. The retina remained flat and the corrected visual acuity was 6/9 3 months later.

#### COMMENT

Schwartz first described the association of raised intraocular pressure and aqueous cells with rhegmatogenous retinal detachment in 1973.<sup>1</sup> The ages of these 11 patients ranged from 6 to 53 years, and 10 were male. Five of the 11 patients had a history of blunt trauma to the eye or face, and in nine patients the duration of the retinal detachment was 3 months or more. In all 11 patients the intraocular pressure returned to normal after the retina was reattached.

In 1986 Matsuo *et al* investigated seven similar patients whose ages ranged from 11 to 31 years. In these cases the 'uveitis' was resistant to topical corticosteroids, but resolved completely after successful retinal detachment surgery. They performed paracentesis on these patients, and, using transmission electron microscopy, established that the 'cells' in the aqueous were photoreceptor outer segments rather than inflammatory cells. The lamellar structure of these fragments led to the conclusion that they might have been derived from rods. They speculated that the peripheral retinal break (caused by blunt trauma in 50% of Schwartz's cases), allows free communication between the subretinal space and aqueous humour. Outer segments then flow into the aqueous and obstruct the trabecular meshwork. This increases the coefficient of outflow resulting in reduced aqueous drainage and increased intraocular pressure.<sup>2</sup> Understandably, this has been difficult to demonstrate histologically because of the difficulty in obtaining tissue for examination.

Our case has enough features to allow the diagnosis of Schwartz-Matsuo syndrome: young male with a history of blunt trauma to the eye, presenting with symptoms of acutely raised intraocular pressure, 'cells' in the anterior chamber, and a retinal detachment found subsequently. This appears to be the first reported case where raised intraocular pressure rather than retinal detachment led to presentation.

We believe, therefore, that the Schwartz-Matsuo syndrome should be considered in the differential diagnosis of acute open angle glaucoma, especially if occurring in a young male with a history of blunt trauma.

D CALLENDER

JL JAY

Tenment Institute of Ophthalmology,  
University of Glasgow,  
38 Church Street, Glasgow G11 6NT

T BARRIE

Glasgow Eye Infirmary, 3 Sandyford Place, Glasgow

Correspondence to: Dr J L Jay.

Accepted for publication 18 March 1997

1 Schwartz A. Chronic open angle glaucoma secondary to rhegmatogenous retinal detachment. *Am J Ophthalmol* 1973;75:205-11.

2 Matsuo N, Takabatake M, Ueno H, Nakayama T, Matsuo T. Photoreceptor outer segments in the aqueous humor in rhegmatogenous retinal detachment. *Am J Ophthalmol* 1986;101:673-9.

3 Matsuo T. Photoreceptor outer segments in aqueous humor: key to understanding a new syndrome. *Surv Ophthalmol* 1994;39:211-33.

4 Posner A, Schlossman A. Syndrome of unilateral recurrent attacks of glaucoma with cyclitic symptoms. *Arch Ophthalmol* 1948;39:517.

### Capsular bag distension syndrome

EDITOR.—The advantages of continuous curvilinear capsulorhexis (CCC) for phacoemulsification cataract surgery are well known.<sup>1</sup> We report a case of capsular bag distension syndrome, a complication of capsulorhexis.

#### CASE REPORT

An 80-year-old female patient underwent uncomplicated phacoemulsification via a temporal corneal incision. A 23.0 dioptre foldable posterior chamber intraocular lens (Allergan SI30 NB, 6.00 mm biconvex silicone optic, 13.00 mm polypropylene modified C haptics with 10° posterior angulation) was inserted into the capsular bag following the injection of ProVisc (sodium hyaluronate 1%).

Slit-lamp examination on the first postoperative day showed the IOL to be displaced

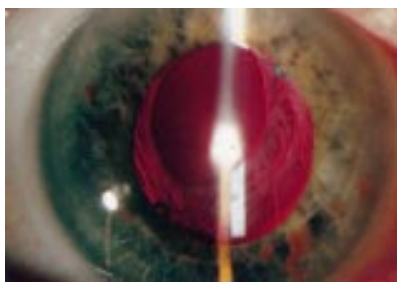


Figure 1 Photograph taken at 3 months postoperatively.

anteriorly within the capsular bag with the posterior capsule lying well behind the optic. As the patient was pain free and the cornea was clear, the intraocular pressure was not measured. The anterior chamber showed minimal activity.

At review 2 weeks later, the visual acuity was 6/9 with a refraction of -3.00 DS/-0.50 DC at 120°, biometry having predicted a postoperative spherical equivalent refraction of -0.35 DS. The intraocular pressure was 10 mm Hg.

Five weeks postoperatively, the visual acuity was 6/9 with a -1.50 DS trial lens, and at 11 weeks, the same visual acuity was attained with a -0.75 DS lens. The IOL was observed to have progressively settled more posteriorly at each examination.

Slit-lamp examination after dilating the pupil showed a vertically oval anterior capsulorhexis opening measuring 3.5 mm by 4.5 mm in size, slightly eccentric supertemporally (Fig 1).

#### COMMENT

Two case series reports have discussed in detail the physical findings, pathogenesis, prevention, and management of the syndrome.<sup>2,3</sup>

Retained viscoelastic, transudation through the lens capsule, and exudation from lens epithelial cells are possible sources of the fluid causing capsular bag distension. The fact that the syndrome was recognised on the first postoperative day in this case almost certainly implicates entrapment of viscoelastic solution behind the IOL. The small capsulorhexis opening relative to the 6 mm optic, we feel, contributed to the entrapment.

The syndrome has been reported following implantation of both PMMA IOLs and silicone IOLs, with either angulated or non-angulated haptics.<sup>3</sup> YAG laser peripheral anterior capsulotomy has been successfully performed in cases of slowly resolving myopia<sup>3</sup> and in one case of apparent closure of the peripheral anterior chamber angle with elevated intraocular pressure.<sup>3</sup>

As the myopic shift lessened gradually with a satisfactory refractive outcome in our case, conservative management was felt to be appropriate.

We suggest care in making the capsulorhexis opening adequate and in ensuring that the viscoelastic is removed from behind the implant at the end of surgery.

K L TU

A GASKELL

Department of Ophthalmology,  
Ayr Hospital, Ayr KA6 6DX

Correspondence to: Dr K L Tu.

Accepted for publication 10 March 1997

1 Ashinoff S. Mechanics of capsulorhexis. *J Cataract Refract Surg* 1992;18:623-8.

2 Davison JA. Capsular bag distension after endolenticular phacoemulsification and posterior

chamber intraocular lens implantation. *J Cataract Refract Surg* 1990;16:99-108.

3 Holtz SJ. Postoperative capsular bag distension. *J Cataract Refract Surg* 1992;18:310-7.

### Cavernous haemangioma of the iris in a leprosy patient

EDITOR.—Haemangiomas of the uveal tract are most frequently located in the choroid. Diffuse choroidal haemangiomas are seen generally in patients with Sturge-Weber syndrome (encephalofacial haemangiomatosis).<sup>1</sup> Haemangiomas of the ciliary body are extremely rare.<sup>2</sup> Haemangiomas of the iris are also rare, with an incidence of 2% in a series of 145 primary tumours of the iris.<sup>3</sup>

Leprosy is a chronic granulomatous disease caused by *Mycobacterium leprae*. A number of tumours have been reported in leprosy patients, some associated with the complications produced by the disease and some incidental.<sup>4,5</sup> We report here an iris haemangioma that occurred in a leprosy patient.

#### CASE REPORT

A 45-year-old man presented in the eye clinic of the Schieffelin Leprosy Research and Training Centre in July 1993 with complaints of watering and pain in the left eye for 1 month. There was no history of any injury to the eye. The patient was diagnosed to have borderline tuberculoid (BT) leprosy 27 years ago. He was treated with dapsone monotherapy for 7 years and also with a 6 month course of the multidrug therapy as recommended by the WHO.<sup>6</sup> He was released from antileprosy treatment 3 years ago.

On examination, the right eye had lagophthalmos and an immature, age-related cataract. The left eye also had lagophthalmos, the conjunctiva being chemotic. There was dense white slough and thinning of the central cornea with iris pigment tamponading a potential perforation. The corrected visual acuity was 6/12 in the right eye and hand movements (HM) in the left eye. The routine skin smears for acid fast bacilli were negative. Smears taken from the corneal slough did not reveal any bacterial or fungal organisms on microscopic examination. The patient was treated with hourly antifungal and antibiotic topical drops but the condition in the left eye continued to worsen and ultimately ended in complete prolapse of the iris. Since there was no perception of light in the left eye and most of the contents were extruded outside, the eye was eviscerated at the patient's request. Swabs immersed in the eviscerated contents were sent for aerobic and anaerobic culture and sensitivity but turned out to be negative for organisms. The eviscerated contents were also sent for histopathological examination.

The histopathological examination showed dense inflammatory exudates composed of neutrophils, lymphocytes, and a few eosinophils in the epithelium as well as in the substantia propria of the corneal tissue. Fragments of iris tissue showed a benign tumour composed of many thin walled cavernous blood vessels and spaces lined by endothelial cells separated by scanty connective tissue stroma<sup>8</sup> (Figs 1 and 2). These proliferating vessels were also found among the smooth muscle fibres of the iris (Fig 3). The surrounding stroma showed a few scattered cells containing melanin pigment. In sections the iris was seen to be adherent to the conjunctiva which showed fibrosis. The nerves of the iris were not inflamed. Sections of lens, choroid, and retinal fragments did not show

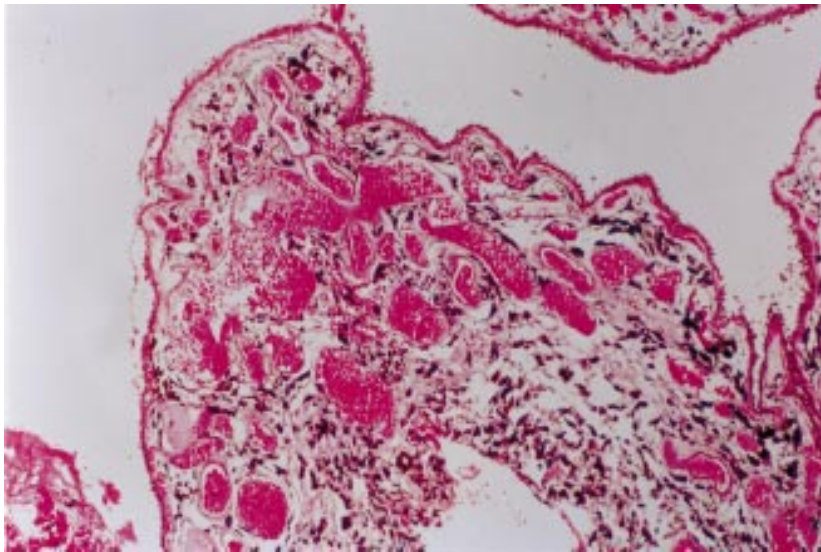


Figure 1 Photomicrograph showing iris tissue with blood channels lined by endothelium. (Haematoxylin and eosin, magnification  $\times 245$ .)

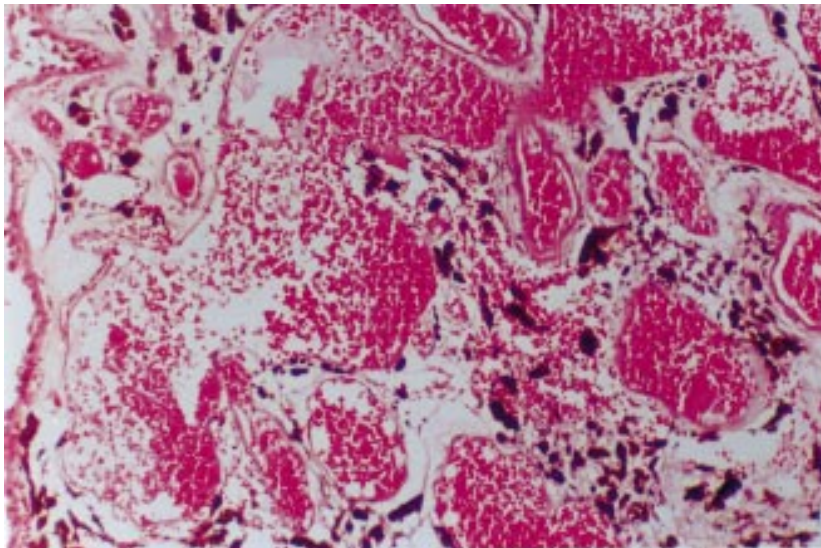


Figure 2 Higher power photomicrograph showing cavernous spaces lined by endothelium and containing blood. (Haematoxylin and eosin, magnification  $\times 650$ .)

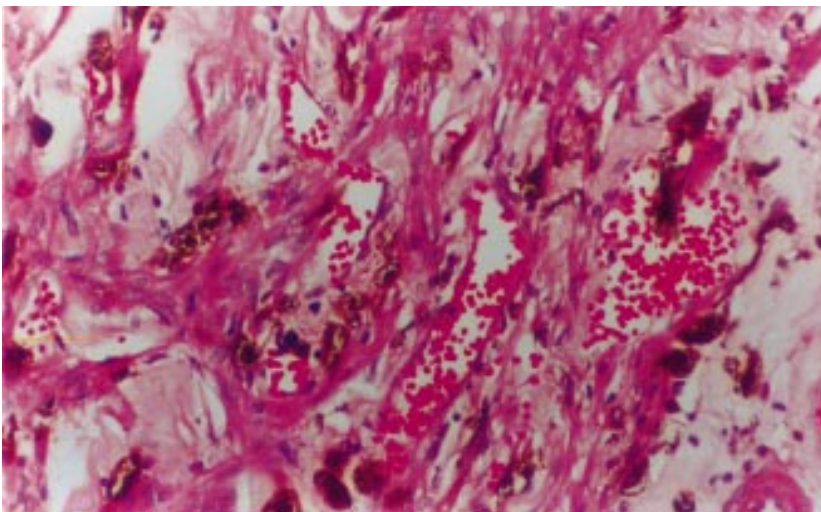


Figure 3 Photomicrograph showing thin walled cavernous blood vessels between the smooth muscle fibres of the iris. (Haematoxylin and eosin, magnification  $\times 325$ .)

any significant inflammation. An exhaustive search for acid fast bacilli was negative, as was to be expected in a borderline tuberculoid leprosy patient.

#### COMMENT

This benign tumour was an accidental discovery in the eviscerated ocular contents of this patient. Although it was present in a patient who had leprosy, the finding is not related to the disease. The patient did not demonstrate any of the syndromes associated with haemangiomas and the anterior and posterior ocular segments of the other eye did not show any abnormal features associated to the finding in the eviscerated eye.

Since haemangiomas of the iris are rare the probability that a prominently vascularised tumour of the iris is a true haemangioma is low.<sup>9</sup> There are few histopathologically proved iris haemangiomas.<sup>10</sup> Even those that have been histopathologically reported as iris haemangiomas have on re-examination and further sectioning proved to be juvenile xanthogranulomas<sup>11</sup> and malignant melanomas,<sup>12</sup> and the validity of the diagnosis of some reported haemangiomas have been questioned.<sup>9</sup> Haemangiomas of the uveal tissue are most frequently located in the choroid. In this patient the choroid tissue was normal and did not demonstrate any tumour. Clinically and histopathologically there was no evidence of juvenile xanthogranuloma or malignant melanoma. The cavernous nature of the haemangioma rules out a pyogenic source.

This histopathological study showing many thin walled blood channels just below the iris epithelium and clearly demonstrating the presence of these blood vessels amidst the smooth muscle fibres of the iris establishes that the haemangioma is from the iris. Since the tumour is rare and its histopathological demonstration scarce we have reported this finding.

GIGI J EBENEZER

Department of Histopathology and Experimental Pathology, Schieffelin Leprosy Research and Training Centre, Karigiri, NAA District, Tamilnadu, India 632106

EBENEZER DANIEL

Branch of Ophthalmology, Schieffelin Leprosy Research and Training Centre, Karigiri, NAA District, Tamilnadu, India 632106

CHARLES K JOB

Department of Histopathology and Experimental Pathology, Schieffelin Leprosy Research and Training Centre, Karigiri, NAA District, Tamilnadu, India 632106

Correspondence to: Ebenezer Daniel, Head, Branch of Ophthalmology, Schieffelin Leprosy Research and Training Centre, Karigiri, North Arcot District, Tamilnadu, India - 632106.

Accepted for publication 10 March 1997

- 1 Duke-Elder S. Diseases of the uveal tract. *System of ophthalmology*. St Louis: CV Mosby, 1966;9:775-937.
- 2 Oksala A, Lingren I, Ahlas A. Haemangioma of the ciliary body. *Br J Ophthalmol* 1964;48:669-72.
- 3 Ashton N. Primary tumours of the iris. *Br J Ophthalmol* 1964;48:650-68.
- 4 John S, Roul RK, Anderson GA. Cancer associated with leprosy. *Ind J Lepr* 1994;66:321-5.
- 5 Purtilo DT, Pangi C. Incidence of cancer in patients with leprosy. *Cancer* 1975;35:1259-61.
- 6 Oleinick A. Survival among leprosy patients with special consideration of cancer as a cause of death. *Int J Lepr* 1968;36:318-27.
- 7 WHO Study Group. Chemotherapy of leprosy for control programmes. Tech Rep Ser 675. Geneva: World Health Organisation, 1982.

- 8 Steinway DM, Fretzin DF. Acquired zosteriform cavernous hemangioma. *Arch Dermatol* 1977; **113**:848-9.
- 9 Ferry AP. Hemangioma of the iris and ciliary body. Do they exist? A search for a histologically proved case. *Int Ophthalmol Clin* 1972; **12**:177-94.
- 10 Naidoff MA, Kenyon KR, Green WR. Iris hemangioma and abnormal retinal vasculature in a case of diffuse congenital hemangiomas. *Am J Ophthalmol* 1971; **72**:633-44.
- 11 Zimmerman LE. Ocular lesions of juvenile xanthogranuloma (nevooxanthoendothelioma). *Trans Am Acad Ophthalmol Otolaryngol* 1965; **69**:412-42.
- 12 Baghdassarian SA, Spencer WH. Pseudoangioma of the iris: its association with melanoma. *Arch Ophthalmol* 1969; **82**:69-71.

### Sympathetic ophthalmia from inadvertent ocular perforation during conventional retinal detachment surgery

EDITOR.—Sympathetic ophthalmia is a rare complication of intraocular surgery. We report a patient in whom inadvertent scleral perforation at the time of buckle placement was complicated by sympathetic ophthalmia.

#### CASE REPORT

A 58-year-old myope with a 4 day history of floaters in the right eye was found on examination to have a temporal retinal detachment involving the macula. The visual acuity at presentation was 6/24 R and 6/6 L. There was no history of ocular trauma or inflammation. A superotemporal retinal tear was identified and, since this was very peripheral, non-drainage surgery was planned. Cryotherapy was applied and a 5 mm radial sponge, positioned under the tear, was secured with two 5/0 Ethibond sutures.

The globe was inadvertently perforated with the posterior suture, resulting in subretinal fluid drainage. At the end of surgery, the retina was flat, with no incarceration, and the break was closed on the indenting buckle. There was no haemorrhage. At discharge, the right visual acuity was 6/12, but 3 months later it had decreased to 6/18 due to macular pucker.

He returned 4 months postoperatively with a 5 day history of worsening right vision. The visual acuities were 6/60 R and 6/9 L. There was a bilateral granulomatous anterior uveitis. No posterior segment inflammation was noted. He was started on topical steroids and mydriatics. Five days later both visual acuities were reduced to 6/60. There were cells in the anterior vitreous and inferotemporal serous retinal detachments with a generalised 'blotchy' white retinal appearance. Mottled choroidal hyperfluorescence and disc leakage were evident on fluorescein angiography (Fig 1A and B) and patchy choroidal thickening with retinal surface irregularities were reported on ultrasound. He was referred to the uveitis clinic where sympathetic ophthalmia was diagnosed clinically. He was treated with prednisolone 80 mg daily. Within 48 hours, the subretinal fluid had cleared and the steroid dose was gradually reduced. Three months after the onset of inflammation, retinal pigment epithelial depigmentation was noted around the site of perforation and the right macula. Two years later, his visual acuities are 6/18 and 6/6, he is on prednisolone 5 mg orally and prednisolone eyedrops 0.3% to both eyes. These doses were briefly increased to treat two inflammatory episodes. A right trabeculectomy was performed for glaucoma.

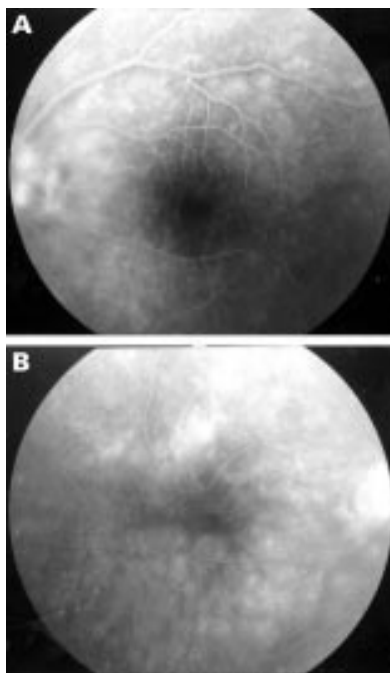


Figure 1 Fluorescein angiogram of right (A) and left (B) eyes showing patchy choroidal hyperfluorescence and disc leakage. The vascular pattern at the right macula is distorted by a macular pucker.

#### COMMENT

Sympathetic ophthalmia following intraocular surgery is rare. Liddy and Stuart estimated its incidence to be 0.007%.<sup>1</sup> Retinal detachment surgery was first implicated by Kornbluth and Stein<sup>2</sup> who reported a case following multiple scleral perforations in the management of giant tear. Pusin *et al*<sup>3</sup> described it in a patient with concurrent bacterial endophthalmitis and Wang<sup>4</sup> in a patient with globe rupture. In this patient, no known risk factors were identified; human leucocyte antigen (HLA) typing was A24(9) A30(19) B41 B51(5) Bw4 Bw6 Cw4 Dr4 Dr17(3) Dr52 Dr53. The latter can be associated with Vogt-Koyanagi-Harada disease, a possible differential diagnosis in this case. Gass, in a survey of retinal surgeons, reported an incidence of 0.01% after vitrectomy<sup>5</sup> and found drainage during a scleral buckling procedure to be the initial penetrating wound in three of 53 eyes enucleated for sympathetic ophthalmia.

The risk of sympathetic ophthalmia is rarely a consideration when deciding on the management of retinal detachment. Nevertheless, along with the commoner complications of subretinal fluid drainage (subretinal haemorrhage and retinal incarceration), its occurrence is a further argument for non-drainage surgery wherever possible. Clearly, however, closure of the retinal break is of paramount importance since failure to do so will entail reoperation, with an increased risk of proliferative vitreoretinopathy and, potentially, sympathetic ophthalmia.

It is important to recognise the significance of bilateral uveitis following even the smallest ocular perforation since early diagnosis and vigorous treatment of sympathetic ophthalmia are commonly associated with a good visual prognosis.<sup>6</sup>

CHRISTOPHER LYONS  
STEPHEN TUFT  
SUSAN LIGHTMAN

The Uveitis Clinic, Moorfields Eye Hospital,  
City Road, London EC1V 2PD

Correspondence to: S Tuft.

Accepted for publication 11 March 1997

- 1 Liddy BS, Stuart J. Sympathetic ophthalmia in Canada. *Can J Ophthalmol* 1972; **7**:157-9.
- 2 Kornbluth W, Stein R. Sympathetic ophthalmia following an operation for retinal detachment. *Br J Ophthalmol* 1953; **37**:755-7.
- 3 Pusin SM, Green WR, Tasman W, Griffith WR, Rodrigues M. Simultaneous bacterial endophthalmitis and sympathetic uveitis after retinal detachment surgery. *Am J Ophthalmol* 1986; **81**:57-61.
- 4 Wang WJ. Clinical and histopathological report of sympathetic ophthalmia after retinal detachment surgery. *Br J Ophthalmol* 1983; **67**:150-2.
- 5 Gass JDM. Sympathetic ophthalmia following vitrectomy. *Am J Ophthalmol* 1982; **93**:552-8.
- 6 Hakin KN, Pearson RV, Lightman SL. Sympathetic ophthalmia: visual results with modern immunosuppressive therapy. *Eye* 1992; **6**:453-5.

### Intraepithelial sebaceous neoplasia invading the lacrimal gland

EDITOR.—Intraepithelial sebaceous neoplasia of the ocular surface without an underlying invasive carcinoma is considered to be an incipient carcinoma. These lesions can remain in situ for prolonged periods without undergoing transformation to an invasive carcinoma.<sup>1</sup> The diagnosis of intraepithelial sebaceous neoplasia is established by map biopsies, determining the extent of intraepithelial spread, excluding an occult invasive carcinoma. This is a report of a case with extensive intraepithelial sebaceous neoplasia, with invasive growth in the lacrimal gland.

#### CASE REPORT

A 77-year-old woman presented with a long term history of a chronic irritated right eye. On clinical examination the tarsal and bulbar conjunctival surface was irregular with vascular ingrowth. Full thickness biopsies from the upper and lower eyelid revealed an intraepithelial sebaceous carcinoma of the Bowenoid type. Clinically, the major part of the conjunctiva was affected and it was decided to perform an exenteration.

#### OCULAR PATHOLOGY

Multicentric localisation of sebaceous carcinoma was found in Meibomian glands, glands of Zeis, and a diffuse intraepithelial sebaceous carcinoma (Fig 1), affecting the conjunctiva of the upper and lower eyelid. The contiguous large, atypical cells had a finely vacuolated cytoplasm with large nuclei, prominent nucleoli and a high mitotic rate. The intraepithelial extension involved more than 90% of the bulbar and tarsal conjunctiva, with extension into the epithelium of the eyelid margin, and the corneal epithelium. An intense secondary inflammation of the conjunctival stroma was noted. Although several areas of microinvasion were found, an underlying nodular invasive sebaceous carcinoma was not present. However, the intraepithelial carcinoma extended into the lacrimal duct (inset, Fig 2), and an invasive sebaceous carcinoma was found in the lacrimal gland (Fig 2), with chronic inflammation and atrophy of the surrounding lacrimal tissue. The lacrimal gland tumour measured 3 mm. Stains on intracellular mucins were negative. There was no wet tissue left to perform reliable staining on intracellular lipid. Lipid on paraffin embedded tissue is difficult to perform and interpret on conjunctival epithelium. On immunohistochemistry the cells were positive with antibodies against carcinoembryonic antigen (CEA) and epithelial membrane antigen (EMA), and negative for S100 protein and

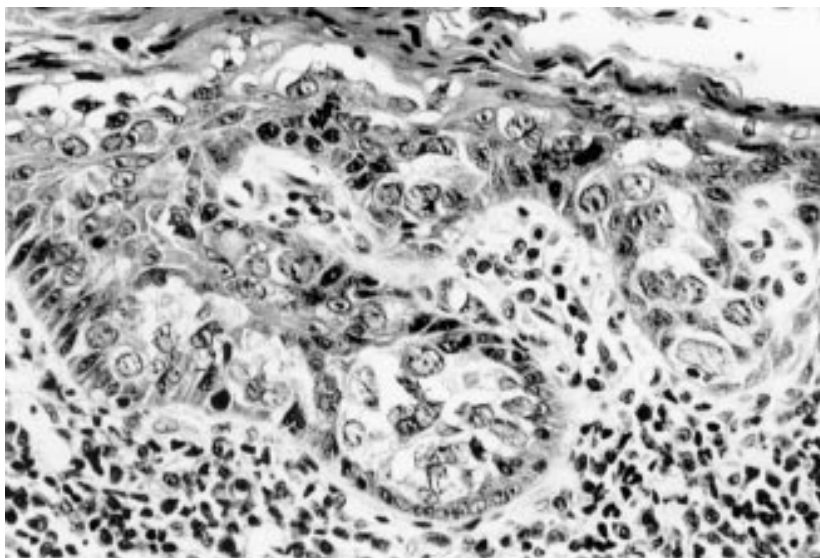


Figure 1 Diffuse intraepithelial sebaceous carcinoma in the eyelid. The contiguous large, atypical cells have a finely vacuolated cytoplasm with large nuclei, prominent nucleoli, and a high mitotic rate (haematoxylin and eosin  $\times 335$ ).

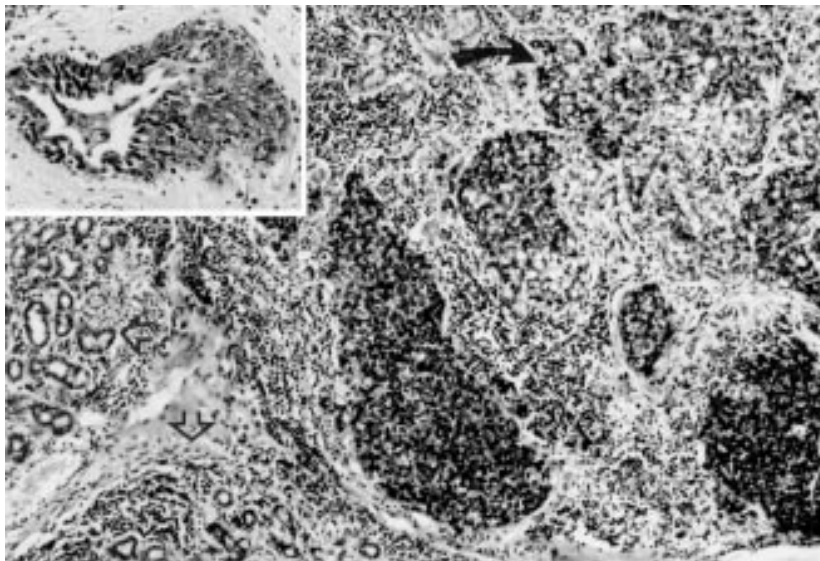


Figure 2 Invasive sebaceous carcinoma (black arrow) in the lacrimal gland, with chronic atrophic inflammation of the surrounding lacrimal tissue (open arrow) (haematoxylin and eosin  $\times 176$ ). Inset: intraepithelial sebaceous carcinoma spreading along the lacrimal duct (haematoxylin and eosin  $\times 133$ ).

HMB-45. This findings exclude (amelanotic) primary acquired melanosis and sweat gland differentiation, and are consistent with sebaceous differentiation.<sup>1</sup>

#### COMMENT

Ocular sebaceous carcinoma originate from the Meibomian glands, glands of Zeis, or sebaceous glands of the caruncle or eyelid

skin.<sup>2</sup> Intraepithelial spread to conjunctiva, cornea or skin of the eyelids in a manner similar to that of mammary and extramammary Paget's disease is frequently observed. Between 44% and 80% of ocular sebaceous carcinoma are associated with intraepithelial neoplasia<sup>3,4</sup> and a high mortality.<sup>4</sup>

In contrast, intraepithelial sebaceous neoplasia without an underlying nodular invasive

sebaceous carcinoma has been described less frequently,<sup>1,5,6</sup> and is associated with a prolonged clinical course.<sup>6</sup> These cases usually spread within the epithelium over 3–10 years, causing symptoms and signs of chronic blepharoconjunctivitis. Two patterns of intraepithelial spread have been recognised: (1) pagetoid spread, consisting of large individual neoplastic cells scattered throughout all layers of the epithelium; and (2) bowenoid spread, consisting of contiguous large atypical cells that partially or fully replace the epithelium. The diffuse intraepithelial neoplasia may have resulted from an intraepithelial migration from these affected glands, or from in situ development within the conjunctival epithelium.<sup>1</sup> The treatment of intraepithelial spread is controversial.<sup>7,8</sup> When intraepithelial spread is extensive, or the involved eye has a poor visual prognosis, an orbital exenteration may be indicated.<sup>1</sup> Intraepithelial tumour spread into the introitus of the lower lacrimal canaliculus has been described.<sup>6</sup> A lacrimal gland origin of the sebaceous carcinoma<sup>9</sup> seems unlikely considering the minimal size of the invasive tumour. Our patient represents a unique case of diffuse intraepithelial sebaceous neoplasia with invasive growth into the lacrimal gland. This case stresses the importance of including the lacrimal system in the surgical resection.

CORNELIA M MOOY

Department of Pathology and Ophthalmology,  
Erasmus University, Room Ee 993, PO Box 1738,  
3000 DR Rotterdam, Netherlands

Accepted for publication 10 April 1997

- Margo CE, Grossniklaus HE. Intraepithelial sebaceous neoplasia without underlying invasive carcinoma. *Surv Ophthalmol* 1995;**39**:293–301.
- Kass LG, Hornblass A. Sebaceous carcinoma of the ocular adnexa. *Surv Ophthalmol* 1989;**33**:477–90.
- Rao NA, McLean IW, Zimmerman LE. Sebaceous carcinoma of eyelids and caruncle: correlation of clinicopathologic features with prognosis. In: Jacobiec FA, ed. *Ocular and adnexal tumors*. Birmingham, AL: Aesculapius, 1978:461–76.
- Rao NA, Hidayat AA, McLean IW, Zimmerman LE. Sebaceous carcinoma of the ocular adnexa: a clinico-pathologic study of 104 cases, with five-year follow-up data. *Hum Pathol* 1982;**13**:113–22.
- Freeman LN, Iliff WJ, Iliff NT, Green WR. Extramammary Paget's disease/pagetoid change of the conjunctiva without underlying sebaceous gland carcinoma. *Invest Ophthalmol Vis Sci* 1988 (suppl);**29**:321.
- Margo CE, Lessner A, Stern GA. Intraepithelial sebaceous carcinoma of the conjunctiva, and skin of the eyelid. *Ophthalmology* 1992;**99**:227–31.
- Lisman RD, Jacobiec FA, Small P. Sebaceous carcinoma of the eyelids. The role of adjunctive cryotherapy in the management of conjunctival pagetoid spread. *Ophthalmology* 1989;**96**:1021–6.
- Jacobiec FA. Sebaceous tumors of the ocular adnexa. In: Albert DM, Jacobiec FA, eds. *The principles and practice of ophthalmology*. Vol 3. Philadelphia: WB Saunders, 1994:1745–70.
- Harvey PA, Parsons MA, Rennie IG. Primary sebaceous carcinoma of lacrimal gland: a previously unreported primary neoplasm. *Eye* 1994;**8**:592–5.

---

## CORRESPONDENCE

---

### The oculocardiac reflex in cataract surgery in the elderly

EDITOR.—According to a national sample survey of the disabled in 1987, cataract was the primary cause of blindness in China.<sup>1</sup> Since manipulations such as retrobulbar injection, ocular compression, and traction of the extraocular muscle were involved in cataract surgery, oculocardiac reflex could not be avoided theoretically. We have conducted a study to determine the incidence of the reflex in cataract surgery in the elderly.

Thirty patients over the age of 60 were involved. At least 60 seconds of dynamic electrocardiogram was recorded with a 24 hour Holter's monitor at each of the following steps: preoperation, retrobulbar anaesthesia, softening of the eyeball, superior rectus suture, corneoscleral incision, delivering the nucleus, and posterior chamber lens implantation. Oculocardiac reflex was defined as at least a 10% decrease in heart rate below relative baseline; that means electrocardiac activities after the beginning of each procedure were compared with those in the previous one, so as to judge more precisely influences of different procedures on electrocardiac activities.

Of the 30 patients included, 10 patients (33.3%) were noted to have 14 oculocardiac reflexes in all. Among them, six patients had abnormal preoperative electrocardiograms. An oculocardiac reflex was caused by softening of eyeball in five (35.7%) patients, retrobulbar anaesthesia in four (28.6%) patients, delivering the nucleus and intraocular lens implantation in two patients, and corneoscleral incision in one patient. The most significant drop in heart rate was 33 beats per minute from baseline. Three patients had more than one oculocardiac reflex during the operation. In addition, arrhythmia was noted in five (16.7%) patients and only two of them suffered oculocardiac reflex.

Our results indicate that most steps in cataract extraction procedure may elicit the oculocardiac reflex. Fortunately, the reflex encountered in our study is generally brief, resulting in no symptoms or any other sequelae. However, the reflex is potentially fatal and can cause cardiac arrest and even death.<sup>2,3</sup> As 64.3% (9/14) of the reflexes occurred at the time of retrobulbar anaesthesia and softening of eyeball, more attention should be paid when these procedures are performed. Surgeons who perform the operation should inform patients of this possibility, especially for aged people with severe heart disease.

GAO LEI

WANG QING

XU HAIFENG

Department of Ophthalmology,

Yantai Yuhuangding Hospital,

Yantai 264000, Shandong Province, P R China

TAO ZHIGANG

WU FALIANG

Department of Cardiology,

Yantai Yuhuangding Hospital,

Yantai 264000, Shandong Province, P R China

Correspondence to: Gao Lei, MD.

1 Gao Yongqing, Zhang Shiyuan, eds. National sample survey of cataract in China. In: *National conferences on cataract and intraocular lens implantation*. Beijing: Chinese Medical Association, 1992:15-8.

2 Smith RB. Death and the oculocardiac reflex. *Can J Anaesth* 1994;41:760.

3 Zhou Chengwei. Cardiac arrest induced by oculocardiac reflex in one patient. *Chinese Journal of Practical Ophthalmology* 1983;1:173.

---

## OBITUARY

---

### Jack Lindley Stewart Smith

Lindley Smith died on the 9th February just before his 83rd birthday. He was educated at Marlborough College before going to Christ's College, Cambridge and Westminster Hospital Medical School where he qualified in 1940.

He served in the Royal Army Medical Corps as an ophthalmic specialist in Normandy and India, attaining the rank of major. He liked to relate how before the war he had spent time exploring Germany on a motor bike and acquiring a knowledge of the language, but when he answered a call for volunteers able to speak German he was promptly posted to India.

He took his DOMS in 1947 and in 1950 became a lecturer in ophthalmic pathology in Manchester University. He had a keen interest and considerable expertise in skin tumours and was awarded his MD (Cantab) in 1954 for a thesis on sweat gland tumours. He developed an ocular pathology service based in the Manchester Royal Eye Hospital which soon attracted specimens from many other hospitals in the region. His major interest was in retinoblastoma and he collaborated closely with the Manchester Children's Tumour Registry in a study of their natural history and inheritance.

In 1957, he was appointed consultant ophthalmic pathologist to St Paul's Eye Hospital Liverpool. However, he retained his associations with Manchester and continued to provide an ophthalmic pathology service for much of the north west. He also pursued his interest in retinoblastoma. This involved driving many miles following up cases and examining their relatives and, incidentally, gaining an unrivalled knowledge of the best pubs in the north west and beyond. More importantly, this diligence identified over the years about a dozen arrested or regressed retinoblastomas of which he gave valuable clinical descriptions. He also managed to collect several eyes containing regressed tumours in which he was able to characterise the histopathological features of arrest or regression.

Lindley had an encyclopaedic knowledge of ophthalmic pathology built up by years of careful observation and supported by considerable clinical expertise. This made his contributions to discussions at meetings of the North of England Ophthalmological Society especially valuable. He was elected president of the society in 1973. He also made a considerable contribution to the training of ophthalmologists at St Paul's. Many former trainees will remember with affection and gratitude the patience with which he introduced them to the mysteries of ocular histopathology and the fatherly interest he showed in their careers.

I personally retain many fond memories of lengthy discussions over the microscope. His perceptive eye quickly picked out the salient features in difficult cases and I learned much from his profound wisdom which he willingly shared.

Golfing colleagues will remember him as a formidable opponent who achieved the distinction of becoming president of the Royal Birkdale Club.

He leaves a widow, Pamela, and two stepsons to whom we extend our deepest sympathy.

D R LUCAS

---

## NOTICES

---

### Diabetes and the eye

The latest issue of the *Journal of Community Eye Health* (no 20) focuses on the diagnosis and treatment of diabetic retinopathy, an increasing cause of blindness worldwide. The issue will feature the following articles: 'Diabetes is now a third world problem' by Dr H King and Dr M Rewers (World Health Organisation); 'Screening for diabetic retinopathy' by Dr L Jenkins and Dr V A Mayon-White; 'Clinical features and management of diabetic retinopathy' by Dr P Hykin; Editorial by Dr Murray McGavin. For further information please contact Ann Naughton, ICEH, Institute of Ophthalmology, 11-43 Bath Street, London EC1V 9EL. Tel: 0171 608 6910. Annual subscription: £25. Free to eye health workers in developing countries.

### European Association for the Study of Diabetic Eye Complications (EASDEC)

The 7th meeting of EASDEC will be held on 18-19 July 1997 at the Okura Hotel, Amsterdam, the Netherlands, as a pre-congress symposium of the 16th International Diabetic Federation (IDF) congress. Further details: Professor BCP Polak, Rotterdam Eye Hospital, PO Box 70030, 3000 LM Rotterdam, the Netherlands. (Fax: (31) 10 4017655.)

### Current Concepts in Ophthalmology 1997

The 17th annual current concepts in ophthalmology will be held on 25-27 July 1997 at the San Diego Marriott Mission Valley, San Diego, California, USA. Further details: Marie Krygier, Medical Education Coordinator, San Diego Eye Bank, 9444 Balboa Avenue, Suite 100, San Diego, CA 92123, USA. (Fax: (619) 565-7368.)

### Tübingen Practical Angiography Course

The Tübingen Practical Angiography Course (International Faculty) will take place on 6 September 1997 at the Auditorium, University Dental Clinic, Osianderstrasse 2-8, Tübingen, Germany. Further details; F Gelissen, MD, Congress Secretariat Dept III, Univer-

sity Eye Clinic, Schleichstrasse 12, 72076 Tübingen, Germany. (Tel: +49 (0) 7071 2987448; fax: +49 (0) 7071 293746; email: ingrid.kreissig@uni-tuebingen.de)

#### **5th International Symposium on Ocular Circulation and Neovascularisation**

The 5th International Symposium on Ocular Circulation and Neovascularisation will be held on 15–19 September 1997 in Kyoto, Japan. Further details: Professor Dr Masanobu Uyama, Secretary General of the Organising Committee, Department of Ophthalmology, Kansai Medical University, Moriguchi, Osaka 570, Japan. (fax: 81-6-997-3475.)

#### **2nd International Symposium on ARMD**

The 2nd International Symposium on ARMD will be held at Glasgow University, Scotland under the auspices of the Royal College of Ophthalmologists on 16–18 September 1997. Further details: Dr G E Marshall, Eye Department, Western Infirmary, 38 Church Street, Glasgow G11 6NT, UK. (Tel: 0141 211 2094; fax: 0141 339 7485; email: gem1b@clinmed.gla.ac.uk)

#### **XXXIst National Ophthalmology Congress**

The XXXIst National Ophthalmology Congress will be held on 16–20 September 1997 in the Istanbul Convention and Exhibition Centre, Istanbul, Turkey. Further details: Murat Karacorlu, MD, Congress Scientific Secretariat, Valikonagi Cad, Sezai Selek Sok No 8/5, Nisantasi, Istanbul 80200, Turkey. (Fax: +90 (212) 233 2425; email: mkaracorlu@iris.com.tr)

#### **6th International Paediatric Ophthalmology Meeting**

The 6th International Paediatric Ophthalmology Meeting will be held on 24–25 September 1997 in Dublin, Ireland. Topics include grand round, neuro-ophthalmology, strabismus, childhood tumours. Further details: Ms Kathleen Kelly, Suite 5, Mater Private Hospital, Eccles Street, Dublin 7, Ireland. (Tel: +3531 838 4444, ext 1759; fax: +3531 838 6314.)

#### **British and Eire Association of Vitreoretinal Surgeons (BEAVRS)**

A meeting of the British and Eire Association of Vitreoretinal Surgeons (BEAVRS) will be held in Birmingham on 16–17 October 1997. Further details: Mr Graham R Kirkby, consultant ophthalmic surgeon, The Birmingham and Midland Eye Centre, City Hospital, NHS Trust, Birmingham B18 7QU. (Tel: 0121-554 3801; fax: 0121-507 6791.)

#### **International Centennial Meeting on Pseudoxanthoma Elasticum**

PXE International, Inc, along with the National Institute of Arthritis, Musculoskeletal and Skin Diseases (NIH), is sponsoring an International Centennial Meeting on Pseudoxanthoma Elasticum (PXE) on 6–7 November 1997 in Bethesda, MD, USA. The meeting will focus on genetic, extracellular matrix, and clinical issues. Further details: Sharon Terry, MA, President PXE International, Inc, 23 Mountain Street, Sharon, MA 02067, USA. (Tel and fax: 617 784 3817; email: pxe@tiac.net)

#### **XXVIIIth International Congress of Ophthalmology**

The XXVIIIth International Congress of Ophthalmology will be held in Amsterdam on 21–26 June 1998. Further details: Eurocongres Conference Management, Jan van Goyenkade 11, 1075 HP Amsterdam, the Netherlands. (Tel: +31-20-6793411; fax: +31-20-6737306; internet <http://www.solution.nl/ico-98/>)

#### **2nd International Conference on Ocular Infections**

The 2nd International Conference on Ocular Infections will be held on 22–26 August 1998 in Munich, Germany. Further details: Professor J Frucht-Pery, Ocular Infections, PO Box 50006, Tel Aviv, 61500, Israel. (Tel: 972 3 5140000; fax: 972 3 5175674 or 5140077.)

#### **Correction**

Unfortunately, the acknowledgments were omitted from the paper by Hope, Bunday, Proops, and Fielder, which appeared in the January issue (*BJO* 1997;**81**:46–53). They read as follows:

This study was generously supported by the British Retinitis Pigmentosa Society and by the Birmingham Eye Foundation. The authors thank Peter Good, neurophysiologist, for carrying out vision function tests at the BMEH, Stuart Burrell and Mary Mills, audiologists, and John Werning, otolaryngology fellow, for undertaking audiovestibular evaluations.

We apologise for this omission.



## INSTRUCTIONS FOR AUTHORS

Adherence to the following guidelines is essential if efficient and expeditious processing of your manuscript is to be achieved. Manuscripts will be returned to authors for revision before peer review if they are submitted in incorrect format. Please indicate in a covering letter which category of paper your article represents.

The *British Journal of Ophthalmology* is an international journal covering all aspects of clinical ophthalmology and the visual/ophthalmic sciences. Contributors should consider the widely varying readership and write clear, simple articles with the minimum of technical detail. Space in the journal is limited and articles should therefore be as concise as possible. One page of text is approximately 1000 words.

Manuscripts should be sent to the editor who selects them on the basis of their suitability for the journal and of reports from independent referees. Manuscripts are acknowledged on receipt and the majority (>80%) are sent for review. Those that are not reviewed are returned to the author as rapidly as possible so that they may be submitted elsewhere.

Manuscripts may be processed by section editors who deal with specific areas of ophthalmology including surgical retina, medical retina, neuro-ophthalmology, glaucoma, paediatric ophthalmology, ocular motility, orbital disease, anterior segment disease, oncology, lens, optics and visual sciences, laboratory sciences, pathology, and immunology. A minimum of two referees, chosen for their specific expertise, review each article.

Papers are accepted on the understanding that they have not been and will not be published elsewhere, and that there are no ethical problems with the work described. If requested, authors shall produce the data upon which the manuscript is based for examination by the editor.

### Categories of papers

#### ORIGINAL ARTICLES

##### (a) Clinical science

Articles on clinical topics are research reports of a general or specialised nature comprising approximately 3000 words and 4-6 display items (Figures and Tables).

##### (b) Laboratory science

Articles on ophthalmic or visual sciences are research reports of experimental work generally of the same size as clinical research reports. Laboratory science papers will be included in a designated section of the journal.

Both types of original article should include the following: title; key words (up to four); address and which author address for correspondence; structured abstract (approx 200 words, headings 'Aims/background', 'Methods', 'Results', and 'Conclusion'); introduction; materials and methods; results and discussion sections; references and acknowledgements; legends for display items (Figures and Tables).

#### REVIEW ARTICLES

Substantive review articles will be included under the section 'Perspective' and will address any aspect of clinical or laboratory

ophthalmology. Review articles will be approximately 3000-5000 words in length including references and may contain display items (Figures and Tables). Most review articles are commissioned but uninvited reviews are welcomed. Prior discussion with the Editor is recommended. All reviews are subject to independent refereeing.

#### LETTERS TO THE EDITOR

Case reports will be published as 'Letters to the editor'. These are normally 500-600 words written in the form of a letter with a maximum of two display items (Figures and Tables). The letter should include an introductory section (without heading), the case report (heading: Case report) and a comment (heading: Comment), plus a maximum of 10 references.

#### CORRESPONDENCE

Letters are normally constructed in the form of scientific correspondence and are usually 200-300 words.

#### Preparation of manuscripts

Manuscripts will be received on the understanding that they have not been and will not be published elsewhere while under editorial review. Manuscripts may be subject to editorial revision with the author's agreement. All communications should be sent to the Editor, *British Journal of Ophthalmology*, Department of Ophthalmology, University of Aberdeen Medical School, Foresterhill, Aberdeen AB9 2ZD, Scotland, UK. (Tel: 01224 663812; Fax: 01224 663832.)

Manuscripts must be submitted in triplicate, and typed double spaced on one side of the paper only, with one inch margins. Each author must sign the covering letter as evidence of consent to publication. Revised manuscripts should be submitted as hard copy and on disk. Detailed instructions will be sent to authors on invitation to revise.

#### ILLUSTRATIONS

Illustrations must be submitted in triplicate. Transparencies must be accompanied by prints. Only salient detail should be included. All must be labelled with the author's name, numbered in the same order as they are cited in the text irrespective of whether they are in colour or black and white, and have the top indicated. Radiographs must be submitted as prints. Line drawings should be clearly labelled and will be redrawn to house style. The width of illustrations for the original articles should be 68 mm, 104 mm, 140 mm or, in exceptional circumstances, 176 mm, to fit the column layout of the journal. Illustrations for 'Letters to the editor' should be 56 mm or 116 mm. Stain used and a scale bar (or magnification) should be given. Legends must be typed on a separate sheet.

#### TABLES

Each table should be on a separate sheet, have a heading, and contain no vertical rules.

#### REFERENCES

In accordance with the Vancouver agreement references are cited by the numerical system. They must be typed double spaced.

References in the text must be cited in numerical order of first appearance. References in the list must be given in the numerical order in which they first appear in the text, not in alphabetical order of authors' names. References with one to six authors must include all authors' names; for references with more than six authors the first six should be given and then *et al.* Titles of journals should be abbreviated in accordance with the *Index Medicus* or given in full.<sup>1</sup> References to books must include names of editor(s) if there is one, town where published, name of publisher, year, volume, page numbers.<sup>2</sup>

- 1 Kaye SB, Shimeld C, Grinfield E, Maitland NJ, Hill TJ, Easty DL. Non-traumatic acquisition of herpes simplex virus infection through the eye. *Br J Ophthalmol* 1992; 76: 412-8.
- 2 Jakobiec FA, Font RL. Orbit. In: Spencer WB, ed. *Ophthalmic pathology: an atlas and textbook*. 3rd ed. Philadelphia: Saunders, 1986: 2461-76.

References will not be checked in the editorial office. Responsibility for their accuracy and completeness lies with the author.

#### SI UNITS

The work should be reported in the units used. If these were not SI units, the equivalent in SI units should be given in parentheses.

#### STATISTICS

Particular attention should be paid to the description of any sample selection process; in particular, the representativeness of the sample should be argued and the handling of any missing data justified. Authors are asked to check tables etc to ensure that missing data are accounted for, that percentages add up to 100 and that numbers in tables are not at variance with those quoted in the text. The policy of the *British Journal of Ophthalmology* is based on the statistical guidelines published in the *British Medical Journal* in 1983 and these are a useful source of information for authors (Altman DG, Gore SM, Gardner MJ, Pocock SJ. Statistical guidelines for contributors to medical journals, *BMJ* 1983; 286: 1489-93). Blanket statements on the use of statistical techniques should be avoided; it must be made quite clear in context which procedure is being used. Authors should bear in mind that relatively simple analyses are often quite adequate to support the arguments presented.

Advice may be available to authors before submission of papers.

#### Proofs

Contributors will receive ONE proof, and should read it carefully for printers' errors. Alterations to the original text should be kept to a minimum and may be charged to the author. Responsibility for validation of the proof lies with the author.

#### Reprints

These may be ordered from the Offprint Office when proofs are returned.