

## LETTERS TO THE EDITOR

**Visual recovery from no light perception in total retinal detachment with massive subretinal haemorrhage**

EDITOR,—In patients with no light perception (NLP) vision following extensive subretinal haemorrhage, visual recovery rarely occurs. In this patient, however, visual recovery occurred after total retinal detachment with massive subretinal haemorrhage of 3 months' duration. The eye, which had NLP vision, developed obstructed angle closure glaucoma that necessitated a subretinal tap and an anterior chamber deepening procedure. Further removal of blood from the vitreous resulted in counting fingers (CF) vision, suggesting that surgery may restore some vision despite relatively long lasting massive subretinal haemorrhage.

## CASE REPORT

A 60-year-old woman with total retinal detachment, severe ocular pain, and NLP vision was referred to us. The eye had a dark pupillary reflex, and the fundus was obscured upon ophthalmoscopy. On slit-lamp examination, a retinal detachment was observed behind the lens and blood cells were seen percolating slowly behind the detached retina. The detached retina pushed the lens-iris diaphragm forward, making the anterior chamber extremely shallow. The filtration angle was not visible. The intraocular pressure (IOP) was 43 mm Hg. The electroretinogram (ERG) and the visual evoked (VER) and electrically evoked responses (EER) were non-recordable. Medical evaluation revealed atrial fibrillation, chronic myelocytic leukaemia, and hypertension. The IOP responded only temporarily to topical medications and oral acetazolamide. The patient experienced nausea and severe ocular pain. Two days after the examination, a subretinal tap was performed. No fluid escaped after full thickness sclerotomy, indicating that there was no significant suprachoroidal fluid or a choroidal detachment. When the choroidal knuckle was pierced in the scleral wound, copious tar-coloured fluid

drained from the wound, and the eye softened. The anterior chamber deepened, the IOP normalised by injection of the balanced salt solution, and the ocular pain resolved postoperatively. The patient regained dim light perception in the inferior nasal projection 10 days postoperatively. The fundus was invisible because of blood in the vitreous. The ERG remained non-recordable until 7 months postoperatively when very small ERG responses were obtained by the computer summation technique. The VER and EER were recordable 5 months postoperatively. Encouraged by the recovery of light perception and the electrophysiological responses, and because the vitreous blood did not resolve after 7 months' observation, closed vitrectomy was performed. The retina was found reattached. Three months after the second surgery, the vision was CF at 4-5 feet. The visual field was constricted to the central 15 degrees, and the dark adaptation curve was monophasic with loss of the rod component and an elevated cone threshold. The retina stayed reattached but was blotchy with pigment clumping (Fig 1(A)). A dense, white subretinal sheet was seen nasally and inferiorly near the equator (Fig 1(B)). The retinal blood vessels and the optic nerve head appeared normal.

## COMMENT

Angle closure glaucoma secondary to extensive choroidal detachment occurs frequently. In the present case, there was no choroidal detachment but total retinal detachment with massive subretinal haemorrhage. The subretinal tap and anterior chamber deepening procedure lowered the IOP and relieved pain. Chronic leukaemia with a bleeding tendency<sup>1-3</sup> would have predisposed the patient to massive subretinal haemorrhage upon eye rubbing. No disciform macular scarring was observed, but presence of a peripheral subretinal neovascular membrane could not be excluded because subretinal organisation in the peripheral fundus was found postoperatively.

In animals, irreversible retinal damage from experimental subretinal haemorrhage occurs rapidly.<sup>4</sup> Even in cases operated on within 7 days of visual loss, the clots removed are more densely fibrous and more rigidly adherent to the surrounding tissues,<sup>5,6</sup> making visual recovery difficult. The possible mechanism of the loss of light perception in this patient is unclear: the IOP was not sufficiently high to stop intraocular circulation. The detached retina was visible behind the clear lens. In this respect, it is noteworthy that the initial EER was non-recordable, which indicated that the neural retinal network was impaired.

Visual recovery was reported after subretinal haemorrhage involving the macula,<sup>7</sup> but the haemorrhage was localised and brief in duration. When the retina was totally detached with massive subretinal haemorrhage of more than 3 months' duration, functional recovery was not reported when similar ocular conditions prevailed.<sup>1,2,8,9</sup>

Although the retina had deteriorated with diffuse pigmentation, the patient regained some vision, possibly because the blood in the subretinal space was not clotted, and the subretinal space was not packed with blood cells. Therefore, some retinal receptors escaped rapid deterioration from contact with dense blood. There might have been exudative or

transudative components in her retinal detachment. The patient later died from an acute leukaemic crisis; no necropsy was performed.

Ryo Suzuki, MD, was supported in part by Japanese Overseas Research Fund from the Ministry of Education, Science and Culture, Japan.

R SUZUKI

Department of Ophthalmology,  
Yamaguchi University School of Medicine  
Kogushi, Ube City 755, Yamaguchi, Japan

T HIROSE

Schepens Eye Research Institute,  
100 Charles River Plaza,  
Boston, MA 02114, USA

Correspondence to: R Suzuki, MD, PhD.

Accepted for publication 24 April 1997

- 1 Kozlowski IMD, Hirose T, Jalkh AE. Massive subretinal hemorrhage with acute angle-closure glaucoma in chronic myelocytic leukemia. *Am J Ophthalmol* 1987;103:837-8.
- 2 Glaser B, Smith JL. Leukemic glaucoma. *Br J Ophthalmol* 1966;50:92-4.
- 3 Leveille AS, Morse PH. Platelet-induced retinal neovascularization in leukemia. *Am J Ophthalmol* 1981;91:640-3.
- 4 Glatt H, Machemer R. Experimental subretinal hemorrhage in rabbits. *Am J Ophthalmol* 1982;94:762-73.
- 5 Bennett SR, Folk JC, Blodi CF, Klugman M. Factors prognostic of visual outcome in patients with subretinal hemorrhage. *Am J Ophthalmol* 1990;109:33-7.
- 6 Johnson MW, Olsen KR, Hernandez E. Tissue plasminogen activator thrombolysis during surgical evacuation of experimental subretinal hemorrhage. *Ophthalmology* 1992;99:515-21.
- 7 Vander JF, Federman JL, Greven C, Slusher MM, Gabel VP. Surgical removal of massive subretinal hemorrhage associated with age-related macular degeneration. *Ophthalmology* 1991;98:23-7.
- 8 Gass JDM. Pathogenesis of disciform detachment of the neuroepithelium: Senile disciform macular degeneration. *Am J Ophthalmol* 1967;63:45-64.
- 9 Wood WJ, Smith TR. Senile disciform macular degeneration complicated by massive hemorrhagic retinal detachment and angle closure glaucoma. *Retina* 1983;3:296-303.

**Bilateral angle closure glaucoma: an unusual presentation of Vogt-Koyanagi-Harada syndrome**

EDITOR,—Vogt-Koyanagi-Harada (VKH) syndrome is a bilateral, diffuse, granulomatous uveitis associated with exudative retinal detachment and central nervous system, auditory, and dermatological involvement.<sup>1</sup> It is a common cause of uveitis in Japan and, to a lesser extent, in parts of Latin America and the USA.

We report a case of VKH syndrome with an unusual presentation of bilateral secondary acute angle closure glaucoma (SAACG). Because of the rarity of this presentation of VKH syndrome (this being the first report, to our knowledge, of such a presentation outside the USA and Japan) we initially had difficulties in diagnosing and treating it in the optimal way. We thus stress the importance of clinicians being aware of such a VKH syndrome presentation, especially in those parts of the world where the disease is rare.

## CASE REPORT

A 20-year-old white woman presented in April 1996 complaining of sudden onset of blurred

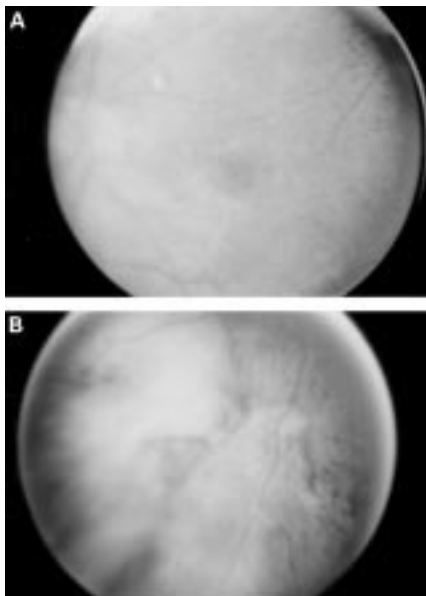


Figure 1 Posterior (A) and inferonasal (B) portions of the fundus after the second surgery.

vision in both of her eyes. Her past medical history and her family history were unremarkable.

Visual acuity was 6/24 in both eyes, improving to 6/12 with a pinhole. The corneas were slightly oedematous, without keratic precipitates. The anterior chambers were shallow, with +1 cells. The pupils were normal and reacted to light. Intraocular pressures were 26 mm Hg in the right eye and 29 mm Hg in the left eye. Gonioscopy revealed closed angles in both eyes. Owing to the corneal oedema and our reluctance to dilate the pupils at that stage, details of the posterior poles of the eyes could not be visualised with certainty.

The woman was thus diagnosed as suffering from bilateral SAACG and was treated with topical pilocarpine and timolol, combined with intravenous acetazolamide and oral glycerol. Since the intraocular pressures could not be controlled with this treatment, bilateral laser iridotomies were performed resulting in reduction of pressures to normal. This was accompanied by a progressive deepening of the anterior chambers.

At this stage we dilated the pupils and revealed +2 cells in the vitreous in both eyes. Ophthalmoscopy disclosed multiple areas of serous retinal detachment in the posterior poles, combined with bilateral inferior exudative retinal detachment (Fig 1). Fluorescein angiography demonstrated multifocal leakage of dye at the level of the retinal pigment epithelium in the early phase and late pooling of fluorescein under the areas of the detached retina in the late phase in both eyes (Fig 2).

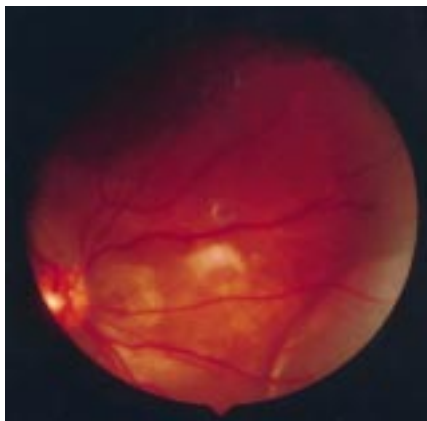


Figure 1 Fundus photography, showing multiple areas of serous retinal detachment at the posterior pole combined with inferior exudative retinal detachment.

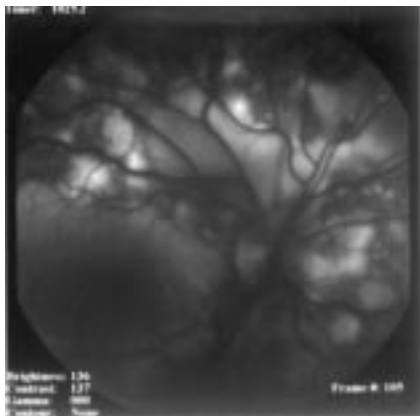


Figure 2 Fundus fluorescein angiogram (late phase), with pooling of fluorescein under the detached retina.

General physical examination, as well as neurological, dermatological, and auditory examinations were all normal. Lumbar puncture disclosed 127 lymphocytes per mm<sup>2</sup> of cerebrospinal fluid, with normal protein levels. Results of other laboratory tests, including chest x ray, complete blood count, erythrocyte sedimentation rate, serum chemistry, liver enzymes, rheumatoid arthritis titre, blood serology, including serological syphilitic tests, and urine analysis were all within normal limits.

Based on the presence of bilateral iridocyclitis, posterior uveitis with bilateral exudative retinal detachment, and cerebrospinal fluid pleocytosis the diagnosis of VKH syndrome was made.<sup>2</sup> The patient was treated with topical steroids and cycloplegia combined with 100 mg of oral prednisone daily, which was tapered down to 40 mg daily over the next month. During that period the retinal detachments resolved and the visual acuity improved to 6/6 in both eyes. A corneal endothelium cell count performed after the termination of the uveitic attack was normal.

#### COMMENT

Glaucoma occurs in 20% to 38% of patients with VKH syndrome.<sup>3,4</sup> We are aware of only 12 reported cases of bilateral SAACG in VKH syndrome,<sup>4,6</sup> of which in at least seven cases the glaucoma was the presenting symptom.

SAACG in cases of VKH syndrome is cyclocongestive in nature, resulting from ciliary body swelling<sup>5</sup> which may be combined with choroidal effusion. Pilocarpine is contraindicated in the management of such cases, because it increases the dilatation of the uveal blood vessels (and by that increases intraocular inflammation and angle congestion) and causes further shallowing of the anterior chamber.<sup>7</sup>

As pointed out by Kimura *et al*,<sup>5</sup> when pilocarpine is mistakenly prescribed for such cases, almost all patients will need an iridectomy or filtering operation. Since we did not diagnose the underlying disease initially and treated the patient with pilocarpine, we could not break the attack until bilateral YAG laser iridotomies were performed. This raises the suspicion that an additional element of pupillary block (possibly through an increased stickiness between the iris and the lens) was caused by the use of pilocarpine.

Corneal swelling is unusual in the presence of healthy corneal endothelium and mild anterior uveitis.<sup>8</sup> A corneal endothelium cell count performed on the patient after the termination of the uveitic attack was normal. Thus, explanations for the mild corneal oedema noted on the patient's presentation can only be speculative. It is not unreasonable to assume that the patient might have had a long standing asymptomatic anterior uveitis and that the sudden intraocular pressure rise resulted in mild corneal oedema.

In conclusion, in order to prevent unnecessary operations, pilocarpine should not be prescribed in SAACG due to uveitis. Since ultrasound is almost diagnostic in VKH syndrome<sup>9</sup> and may provide additional information about posterior segment pathology in other predisposing diseases,<sup>9</sup> it should be performed in suspected cases of SAACG before any medical iris manipulation is performed.

MAYA EIBSCHITZ-TSIMHONI  
YUVAL A GELFAND  
EEDY MEZER  
BENJAMIN MILLER

Department of Ophthalmology, Rambam Medical Center and the Bruce Rappaport Faculty of Medicine, Technion-Israel Institute of Technology, Haifa, Israel

Correspondence to: Dr Y A Gelfand, Department of Ophthalmology, Rambam Medical Center, POB 9602, 31096 Haifa, Israel.

Accepted for publication 11 March 1997

- 1 Moorthy RS, Inomata H, Rao NA. Vogt-Koyanagi-Harada syndrome. *Surv Ophthalmol* 1995;**39**:265-92.
- 2 Forster DJ, Cano MR, Green RL, Rao NA. Echographic features of the Vogt-Koyanagi-Harada syndrome. *Arch Ophthalmol* 1990;**108**:1421-6.
- 3 Ohno S, Char DH, Kimura SJ, O'Connor GR. Vogt-Koyanagi-Harada syndrome. *Am J Ophthalmol* 1977;**83**:735-40.
- 4 Forster DJ, Rao NA, Hill RA, Nguyen QH, Baerveldt G. Incidence and management of glaucoma in Vogt-Koyanagi-Harada syndrome. *Ophthalmology* 1993;**100**:613-8.
- 5 Kimura R, Sakai M, Okabe H. Transient shallow anterior chamber as initial symptom in Harada's syndrome. *Arch Ophthalmol* 1981;**99**:1604-6.
- 6 Kimura R, Kasai M, Shoji K, Kanno C. Swollen ciliary processes as an initial symptom in Vogt-Koyanagi-Harada syndrome. (Letter) *Am J Ophthalmol* 1983;**95**:402-3.
- 7 Lewis RA. Medical therapy of glaucoma. In: Tasman W, Jaeger EA, eds. *Duane's clinical ophthalmology*. Vol 3, Chapter 56. Philadelphia: Lippincott-Raven, 1996:5-6.
- 8 Van Meter WS, Holland EJ, Doughman DJ. Corneal edema. In: Tasman W, Jaeger EA, eds. *Duane's clinical ophthalmology*. Vol 4, Chapter 16A. Philadelphia: Lippincott-Raven, 1996:13-4.
- 9 Campo RV, Reiss GR. Glaucoma associated with retinal disorders and retinal surgery. In: Tasman W, Jaeger EA, eds. *Duane's clinical ophthalmology*. Vol 3, Chapter 54E. Philadelphia: Lippincott-Raven, 1996:14.

#### Ultrasound biomicroscopy of angle closure glaucoma with pseudoexfoliation syndrome

EDITOR.—The pseudoexfoliation syndrome is characterised by the presence of light grey or white flakes on the pupillary margin and anterior lens capsule, the surfaces of the iris, zonules, ciliary body, hyaloid, trabecular meshwork, and the endothelial surface of the cornea. This syndrome is generally thought to be accompanied by open angle glaucoma. However, in some reports, the anterior chamber angle is narrow,<sup>1-3</sup> and in other cases shown to be angle closure glaucoma.<sup>4,5</sup> The relation between the pseudoexfoliation syndrome and angle closure glaucoma is unclear. We used the ultrasound biomicroscope to determine the pathogenesis of angle closure glaucoma in a patient with the pseudoexfoliation syndrome.

#### CASE REPORT

An 80-year-old Japanese woman complained of blurred vision and pain in the left eye. Angle closure glaucoma of the left eye was diagnosed by an ophthalmologist. Pilocarpine eye drops were prescribed, and the patient was referred to our department. On initial examination, her corrected visual acuity was right eye 70/100 and left eye 20/100, and the intraocular pressures were right eye 13 mm Hg and left eye 37 mm Hg. Slit-lamp examination revealed a shallow anterior chamber in the right eye and a markedly shallow anterior chamber in the left eye. Pseudoexfoliative substance was observed on the pupillary margin of the both eyes; moderately dense cataract was present in both eyes. Gonioscopy revealed a narrow (grade 2) angle in the right and an even narrower angle (grade 1) in the left eye. A densely pigmented trabecular band was present in both eyes. Glaucomatous disc cup-

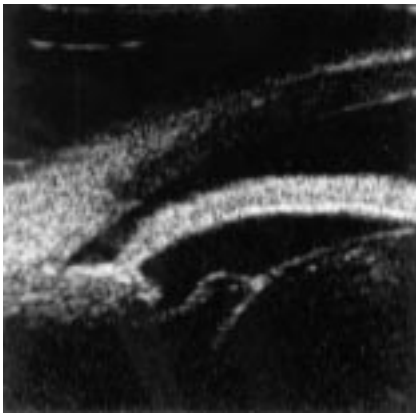

Figure 1 Ultrasound biomicroscopic image of the anterior segment of the inferior section in the right eye. Zonule is loose and the lens has a spherical shape. The iris shows a marked anterior bowing with the presence of pupillary block. The angle is narrow at the mid peripheral anterior chamber.

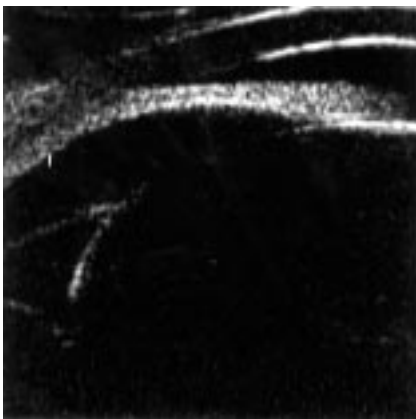


Figure 2 Ultrasound biomicroscopic image of the anterior segment of the inferior section in the left eye. Zonules are thick and well defined, and the lens has a spherical shape. The angle is closed with pupillary block.

ping was observed in both fundi by ophthalmoscopy performed without mydriasis.

An ultrasound biomicroscope (50 MHz Ultrasound BioMicroscope, Humphrey Instruments, Inc, San Leandro, CA, USA) was used to evaluate the mechanism of the angle closure glaucoma. Ultrasound biomicroscopy demonstrated a narrow angle at the mid peripheral anterior chamber in all sections of the right eye, and a slit-like, narrow or closed angle in the left eye (Figs 1, 2). Thick, well defined zonules were observed in all sections of both eyes, some of which were loose (Fig 1). Both lenses were spherically shaped, and anterior poles moved forward. The iris showed a marked anterior bowing that was consistent with pupillary block. The thickness of the right lens was 5.4 mm, as measured by A-scan echography. The thickness of the left lens could not be measured.

The administration of the pilocarpine drops was halted, and laser iridectomy was performed in both eyes. The anterior chambers of both eyes were of normal depth; the intraocular pressure fell to a normal level in the left eye after the procedure. Ultrasound biomicroscopic examination showed a normal, wide open angle, except for the inferior and superior segments of the left eye which showed persistent peripheral anterior synechiae. The iris showed a straight configuration. On the following day, when ultrasound biomicroscopy was performed after the instil-

lation of pilocarpine, numerous loosened zonules were seen in all sections of both eyes. Lens thickness as measured by A-scan echography was 5.9 mm in the left eye.

#### COMMENT

Ultrasound biomicroscopy revealed thick, well defined zonules that appeared to be coated with pseudoexfoliative materials. The resulting loosened zonules presumably caused the spherical shape of the lens and increased the axial thickness. The anterior pole of the lens appeared to have moved forward and increased the intraocular pressure by creating pupillary block.

In cases with a shallow anterior chamber or angle closure glaucoma accompanied by the pseudoexfoliation syndrome such as that presented here, an immediate laser iridectomy is indicated without the use of pilocarpine drops. The instillation of pilocarpine drops exacerbates pupillary block so that its use is contraindicated. When cataract surgery is performed in such cases, careful attention should be paid to zonular dialysis.

TAKASHI GOHDO  
HIROSHI TAKAHASHI  
HIROYUKI IJIMA  
SHIGEO TSUKAHARA

Department of Ophthalmology, Yamanashi Medical University, Yamanashi, Japan

Correspondence to: Shigeo Tsukahara, MD, Department of Ophthalmology, Yamanashi Medical University, Tamaho, Yamanashi, Japan 409-38.

Accepted for publication: 10 March 1997

- 1 Wishart PK, Spaeth GL, Poryzees EM. Anterior chamber angle in the exfoliation syndrome. *Br J Ophthalmol* 1985;69:103-7.
- 2 Layden WE, Shaffer RN. Exfoliation syndrome. *Am J Ophthalmol* 1974;78:835-41.
- 3 Ritch R. Exfoliation syndrome and occludable angles. *Trans Am Ophthalmol Soc* 1994;92:845-944.
- 4 Herbst RW. Angle closure glaucoma in a patient with pseudoexfoliation of the lens capsule. *Ann Ophthalmol* 1976;8:853-6.
- 5 Skuta GL, Parrish II RK, Hodapp E, Forster RK, Rockwood EJ. Zonular dialysis during extracapsular cataract extraction in pseudoexfoliation syndrome. *Arch Ophthalmol* 1987;105:632-4.

#### The cotton bud as a missile causing penetrating eye injury

EDITOR,—Airguns have been responsible for a substantial number of eye injuries over the past 70-80 years. In published series airguns have accounted for up to 7% of severe eye injuries.<sup>1</sup> Sevel and Atkins reported a final visual acuity of 6/60 or less in 77% of patients following an airgun pellet injury to the eye.<sup>2</sup> A recent study demonstrated that injuries caused by the discharge of airguns were the commonest cause of enucleation secondary to trauma in the paediatric and adolescent population.<sup>3</sup> We report an unusual case of severe eye injury resulting from an apparently harmless household item used inappropriately as air weapon ammunition.

#### CASE REPORT

A 15-year-old boy broke a plastic cotton bud and fired it from a 0.22 air rifle. The cotton bud hit his older brother from a range of 5-7 metres. The cotton bud penetrated the eyelid, sclera, and pars plana in the superonasal quadrant of the right eye. As an impulsive action the patient removed the cotton bud from his eye immediately. On examination in the accident and emergency department he had a scleral wound with ciliary body exposed and no perception of light in the affected eye

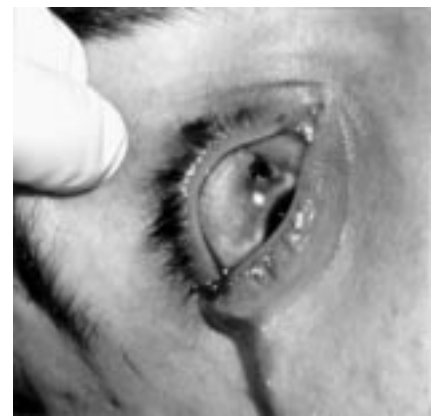

Figure 1 Clinical photograph of right eye on presentation with penetrating injury in superior sclera.

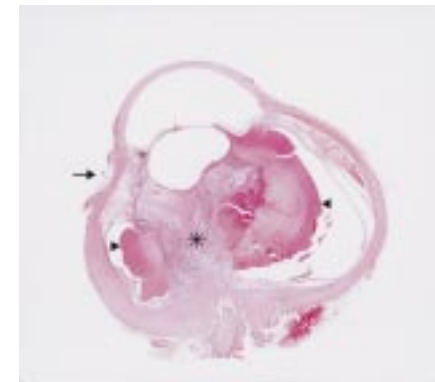


Figure 2 Enucleated eye with total fibrotic funnel retinal detachment (asterisk), massive subretinal haemorrhage (arrowheads), and site of penetrating injury (arrow) (haematoxylin and eosin,  $\times 1.5$ ).

(Fig 1). The cornea was oedematous and no view of the fundus was possible. At primary repair apposition of the scleral wound was not possible and therefore closure was achieved using an autologous half thickness scleral flap.

The patient had no perception of light at 1 day, 1 week, and 1 month following the operation. The eye became hypotonous and phthisical and remained uncomfortable. Five months after the injury the eye was enucleated. Histological examination of the eye (Fig 2) demonstrated a superonasal penetrating wound resulting in massive subretinal haemorrhage and subsequent organisation causing a total fibrotic funnel retinal detachment. There were occasional areas of chronic inflammation within the eye but no evidence of sympathetic ophthalmitis.

#### COMMENT

Eye injuries from the discharge of airguns tend to be accidental rather than malicious.<sup>4</sup> The injury described in this report can be regarded as the result of poor gun safety rather than a deliberate attempt to injure.

In a series of 105 eye injuries caused by discharge of airguns<sup>5</sup> only one penetrating injury avoided enucleation and in this case final vision was reduced to hand movements only. More recently in a series of 60 ocular airgun injuries 11 out of 16 penetrating injuries required enucleation and none of the eyes retained visual acuity better than counting fingers.<sup>6</sup> In all of these cases the injury resulted from lead pellets, or ball bearings, or darts. We know of only one other case of eye injury resulting from unconventional airgun ammu-

nition, a contusional injury caused by a piece of pear fired from an air weapon.<sup>6</sup>

Most air rifles available in the UK have muzzle velocities of between 600 and 800 feet per second (185 m/s to 250 m/s). It has been demonstrated that an airgun pellet only requires a velocity of 236 feet per second (72 m/s) to penetrate the globe.<sup>7</sup> In our case a missile weighing less than 0.13 g was responsible for a devastating injury. We contend that air weapons belong on the shooting range rather than in the back garden.

We wish to thank Mr T Rimmer for allowing us to report the details of his patient and Dr Ian Cree for carrying out the pathological examination.

GREGOR L CAMPBELL-HEWSON  
CONOR V EGGLESTON  
SUSAN M ROBINSON

Accident and Emergency Department,  
Addenbrooke's Hospital, Cambridge CB2 2QQ

Correspondence to: Gregor L Campbell-Hewson.  
Accepted for publication 26 March 1997

- 1 LaRoche R, McIntyre L, Schertzer RM. The epidemiology of severe eye injuries in childhood. *Ophthalmology* 1988;**95**:1603-7.
- 2 Sevel D, Atkins A. Pellet gun injuries of the eye. *S Afr Med J* 1978;**54**:566.
- 3 Marshall DH, Brownstein S, Addison DJ, MacKenzie SG, Jordan DR, Clarke WN. Air guns: the main cause of enucleation secondary to trauma in children and young adults in the greater Ottawa area in 1974-1993. *Can J Ophthalmol* 1995;**30**:187-92.
- 4 Schein OD, Enger C, Tielsch JM. The context and consequences of ocular injuries from air guns. *Am J Ophthalmol* 1994;**117**:501-6.
- 5 Bowen DI, Magauran DM. Ocular injuries caused by air gun pellets: an analysis of 105 cases. *BMJ* 1973;**1**:333-7.
- 6 Moore AT, McCartney AC, Cooling RJ. Ocular injuries associated with the use of airguns. *Eye* 1987;**1**:422-9.
- 7 De Lori F, Pomerantzeff O, Cox MS. Perforation of the globe under high speed impact; its relation to contusion injuries. *Invest Ophthalmol* 1969;**8**:290-301.

### Ankyloblepharon filiforme adnatum

EDITOR,—Ankyloblepharon filiforme adnatum is a rare benign congenital anomaly first described by Von Hasner in 1881.<sup>1</sup> Fusion of the eyelid margins is a normal stage in human development but an abnormal occurrence at birth.<sup>1</sup> The developing eyelid margins remain fused until the fifth gestational month, but may not be completely separated until the seventh month.<sup>2</sup> Ankyloblepharon is characterised by full thickness fusion of the lid margins.

Ankyloblepharon filiforme adnatum comprises single or multiple fine bands of extensible tissue connecting the lid margins at the grey line and it reduces the palpebral fissure by interfering with the movements of lids.

The abnormality has been reported as an isolated finding, in association with other anomalies or as a part of a well defined syndrome.

#### CASE REPORT

A 7lb 5oz (3317 g), white female baby was born at 40 weeks' gestation to a 26-year-old third gravida. The pregnancy was normal and the mother denied having taken any drugs or being exposed to x rays. The previous two siblings, aged 4 and 2 years, both males, were healthy. There was no family history of congenital anomalies or consanguinity.

The baby was noted to have fused left eyelids at birth; apart from this she was perfectly healthy. A detailed paediatric assessment failed to reveal any other congenital abnormalities.

A more detailed ophthalmic examination showed that there was a single adhesion between the eyelid margins of the left eye (Fig 1). The lids could be easily parted to reveal an underlying normal eye. Ocular motility, anterior segment, and fundus were normal. This adhesion was extensible and was divided by a No 15 blade. There was minimal bleeding. At her follow up appointment 4 months later no abnormality was noted.

#### COMMENT

This was the third case of isolated ankyloblepharon filiforme adnatum seen at our hospital in the past 15 years. The other two babies, a boy and a girl, were also completely normal apart from the ankyloblepharon filiforme adnatum. The annual birth rate is 4500, giving an incidence of 4.4 per 100 000 births.

Ankyloblepharon filiforme is usually a solitary malformation of sporadic occurrence or a part of one of three Mendelian disorders.<sup>3</sup>

In most familial cases it occurs together with cleft lip and palate, as an autosomal dominant condition in otherwise healthy relatives (MIM 106250).<sup>4</sup> In some patients it appears as a part of Hay-Wells syndrome,<sup>4</sup> also known as ankyloblepharon-ectodermal dysplasia-clefting syndrome (MIM 106260) or as a part of the popliteal pterygium syndrome (MIM 263650), characterised by intercranial webbing of the lower limbs.<sup>4</sup>

CHANDS (curly hair-ankyloblepharon-nail dysplasia) also has it as a part of its phenotype (MIM 214350). Other reported associations include hydrocephalus, meningocele and imperforate anus,<sup>5</sup> bilateral syndactyly, cardiac problems such as patent ductus arteriosus and ventricular septal defects, ectodermal syndromes,<sup>5</sup> and Edwards syndrome.<sup>6</sup> The histology of these connecting strands has been shown to consist of vascularised central core surrounded by stratified squamous epithelium.<sup>7</sup>

The aetiology of this abnormality is unknown and a number of theories have been proposed. The currently accepted theory is that this condition is due to an interplay of temporary epithelial arrest and rapid mesenchymal proliferation, allowing union of lids at abnormal positions.<sup>8</sup>

The innocuous appearance of ankyloblepharon filiforme adnatum belies its clinical importance. Although it may appear as a solitary anomaly in an otherwise healthy infant, it is frequently associated with a wide range of systemic malformations. The eye itself has not been reported to be abnormal except in a recent case report where ankyloblepharon fili-

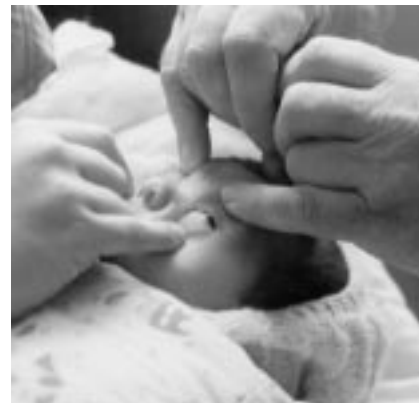

Figure 1 Ankyloblepharon filiforme adnatum showing an extensible band of tissue connecting eyelid margins.

forme adnatum was seen to be associated with infantile glaucoma and iridogoniodysgenesis.<sup>8</sup> The bands frequently resolve spontaneously after a few months or may be released by a simple operative procedure.<sup>4</sup>

The major practical importance of this anomaly is that when it occurs, it should alert the physician to the possible presence of other congenital problems.

SUNILA JAIN  
ANTHONY J ATKINSON  
BRYAN HOPKISSON

Eye Department, Northampton General Hospital,  
Cliftonville, Northampton NN1 5BD

Correspondence to: Sunila Jain, Eye Department,  
Leicester Royal Infirmary, Infirmary Square, Leicester LE1 5WW.

Accepted for publication 28 April 1997

- 1 Duke-Elder S. *System of ophthalmology*. Vol III. London: Kimpton, 1964:869-71.
- 2 Weiss AH, Riscile G, Kousseff BG. Ankyloblepharon filiforme adnatum. *Am J Med Genet* 1992;**42**:369-73.
- 3 McKusick VA. *Mendelian inheritance of man*. 9th ed. Baltimore: Johns Hopkins Press 1990:71, 240, 1434.
- 4 Hay RJ, Wells RS. The syndrome of ankyloblepharon, ectodermal defects and cleft lip and palate: an autosomal dominant condition. *Br J Dermatol* 1976;**94**:277-89.
- 5 Kayarian EL, Goldstein P. Ankyloblepharon filiforme adnatum with hydrocephalus, meningocele and imperforate anus. *Am J Ophthalmol* 1977;**84**:355-7.
- 6 Clark DI, Patterson A. Ankyloblepharon filiforme adnatum in trisomy 18 (Edwards syndrome). *Br J Ophthalmol* 1985;**69**:471-3.
- 7 Judge H, Mott W, Gabriels J. Ankyloblepharon filiforme adnatum. *Arch Ophthalmol* 1929;**2**:702-8.
- 8 Scott MH, Richard JM, Farris BK. Ankyloblepharon filiforme adnatum associated with infantile glaucoma and iridogoniodysgenesis. *J Pediatr Ophthalmol Strabismus* 1994;**31**:93-5.

### Discoid corneal oedema and high intraocular pressure following PRK

EDITOR,—We present an unusual corneal oedema which was observed following scleral indentation during a buckling procedure in a patient who had undergone successful photorefractive keratectomy (PRK), and in a second patient who presented with steroid induced high intraocular pressure following PRK.

#### CASE REPORTS

##### Patient 1

A 33-year-old man underwent bilateral PRK by the Visx 20/20 excimer laser, with a 6 mm ablation zone. The refraction before the procedure was  $-6.00/-2.00 \times 177^\circ$  in the right eye and  $-5.00/-1.75 \times 180^\circ$  in the left. The corrected visual acuity was 20/20. Five months after PRK the patient's uncorrected vision was 6/9 in both eyes. With correction of plano/ $-0.75 \times 175^\circ$  in the right eye and  $-0.50$  in the left, his vision was 20/20 in each eye. The steroid drops were stopped a month previously.

Six months after PRK, he noticed a shadow on the nasal field of his right eye and deterioration of vision. On admission the visual acuity in the right eye was 6/60 and the IOP 15 mm Hg. The cornea showed no pathology and there was no noticeable haze. The anterior chamber was deep and clear. Funduscopy revealed detachment of the temporal and inferior retina with two peripheral horseshoe tears at 9 and 6 o'clock. Examination of the left eye was unremarkable apart from a +1 paracentral arcuate corneal subepithelial haze.

During buckling procedure, at the stage of scleral indentation and localisation of the

tears, while elevating the IOP close to arterial pressure, the central cornea became very hazy, to the point where it was almost impossible to visualise the retina. The corneal oedema occupied the whole 6 mm zone of PRK ablation and involved the epithelium and subepithelial layers. An attempt to scrape the oedematous epithelium over the central cornea was difficult and we realised that there was oedema deeper to the epithelium. Therefore the procedure was stopped after several strikes. Subsequently, the eye was kept soft by repeated paracentesis of the anterior chamber. The localisation of the retinal tears was continued and cryopexy performed through the hazy cornea with great difficulty. Twenty five minutes later, while placing the scleral sutures of the sponge, the cornea became clearer and the retinal tears were clearly observed. The location of the tears was double checked and found to be correct. During the rest of the surgery, the PRK zone continued to be oedematous, while the rest of the cornea was clear.

The following day, the cornea was found to be perfectly normal, except for small punctate epithelial erosions. The retina was well attached. Endothelial specular microscopy performed 1 week after the surgery revealed a normal and equal cell count of 2500 cells/mm<sup>2</sup> in both eyes.

#### Patient 2

A 56-year-old man underwent PRK in his left eye for moderate myopia in July 1993. His best corrected visual acuity of that eye before PRK was 6/6(-) with correction of -5.75/-0.50 × 180°. The IOP was 18 mm Hg bilaterally; the anterior and posterior segments were unremarkable.

The patient was treated with dexamethasone (0.1%) drops six times a day following PRK, and after 6 weeks of local steroid treat-

ment he presented with a complaint of left visual blur. On admission, his best corrected visual acuity was 6/60 in this eye. The IOP was found to be 18 mm Hg in the right eye and 52 mm Hg in the left eye. A central discoid 6 mm zone of epithelial and subepithelial oedema was observed. The anterior chamber was deep and there was no evidence of papillary block. The IOP was reduced within 2 hours to 20 mm Hg by local application of Iopidine (0.5%), Tiloptic (0.5%), and pilocarpine (2%) drops and intravenous injection of 500 mg acetazolamide. The discoid corneal oedema completely regressed within 4 hours. He was subsequently treated by Tiloptic (0.5%) drops twice daily and FML drops four times daily which were tapered off within 3 months. Final refraction, 2 years later, revealed visual acuity of 20/20(-) with -0.50 spherical correction. The cornea was found to be completely normal with no evidence of haze. Specular microscopy 2 years after PRK revealed a normal and equal cell count of 2300 cells/mm<sup>2</sup> in both eyes.

#### COMMENT

Histopathological studies have characterised the changes occurring during healing of rabbit and monkey corneas following PRK. In these models, a subepithelial haze develops at 3 weeks after ablation and is caused by a subepithelial accumulation of active keratocytes, vacuoles containing glycosaminoglycans, and newly synthesised type III collagen fibres, with greater interfibre spacing than normal.<sup>1,2</sup> This subepithelial newly formed extracellular matrix<sup>2</sup> persisting for several months, may facilitate the accumulation of subepithelial fluids when IOP is significantly increased, enhancing the diffusion of water into the corneal stroma from the anterior chamber through the endothelial barrier. The newly formed hyperplastic epithelium is probably

more permeable to water than its neighbouring peripheral epithelium<sup>3</sup> and may become oedematous during this period. The absence of Bowman's layer may also contribute to the subepithelial and intraepithelial fluid accumulation. Infrequently there is a need to remove an oedematous epithelium during buckling procedure, for better visualisation of the retina. In our two patients, it seems that both the epithelium itself and the subepithelial tissue became oedematous. The only common pathogenic mechanism among these two patients is the high IOP, which compromised the homeostasis of the PRK treated cornea. The relative rapidity of development and regression of the superficial corneal oedema may be explained mainly by the hydrostatic effect of a significantly increased IOP. It seems that with the future increase in PRK procedures in myopic patients, we will be facing a new intraoperative complication which has not yet been reported in the English literature.

GIORA TREISTER  
ORLY HAREL

*Herzlia Medical Center, Herzlia, Israel*

ISRAEL KREMER

*Ein Tal Eye Center, Tel-Aviv, Israel*

Correspondence to: Israel Kremer, MD, Ein Tal Eye Center, 17 Brandeis Street, Tel-Aviv, Israel.

Accepted for publication 28 April 1997

- 1 SundarRaj N, Geiss MJ III, Fantes F, Hanna K, Anderson SC, Thompson KP, *et al.* Healing of excimer laser ablated monkey corneas: an immunohistological evaluation. *Arch Ophthalmol* 1990;208:1604-10.
- 2 Lohamnn C, Gartry DS, Kerr Muir MG, Timberlake GT, Fitzke FW, Marshall J. 'Haze' in photorefractive keratectomy: origins and consequences. A review. *Lasers Light Ophthalmol* 1991;4:15-34.
- 3 Malley DS, Steinert RF, Puliafito CA, Dobi ET. Immunofluorescence study of corneal wound healing after excimer laser anterior keratectomy in the monkey eye. *Arch Ophthalmol* 1990;108:1316-22.

---

## CORRESPONDENCE

---

### Coeliac disease and Behçet's disease

EDITOR.—A large number of diseases have been reported to be associated with coeliac disease, many with a probable immunological pathogenesis.<sup>1</sup> Behçet's disease and coeliac disease share the feature of recurrent oral ulceration and indeed this may be the only presenting feature of coeliac disease.<sup>2</sup> A recent report suggested that there may be an association between these two diseases and that screening for evidence of coeliac disease by antibody screening might be useful in Behçet's disease to detect otherwise asymptomatic individuals.<sup>3</sup> That study tested only 11 individuals but found one with positive antibody tests for coeliac disease, the diagnosis being confirmed by jejunal biopsy.

We have tested the sera of 52 patients attending the supraregional Behçet's disease clinic at Leeds. All patients fulfilled the diagnostic criteria of the Behçet's Disease International Study Group.<sup>4</sup> We used four coeliac antibody tests (IgG and IgA anti-gliadin antibodies (AGA), IgG anti-reticulon antibodies (ARA), and IgG anti-endomysial antibodies (EMA)). The EMA was negative in all cases, as was the IgA AGA and IgG ARA. Four patients were weakly positive for IgG AGA.

The combination of IgA AGA and IgG EMA has been suggested as the most sensitive and specific combination of serological screening tests for coeliac disease<sup>5</sup> and these findings do not support the previously reported association.

Work in the authors' laboratories is supported by the UK Medical Research Council, Northern and Yorkshire Health Authority and The Wellcome Trust.

M A ALDERSLEY  
Department of Medicine,  
St James's University Hospital, Leeds

T E JAMES  
Department of Ophthalmology,  
St James's University Hospital, Leeds

A F MARKHAM  
Molecular Medicine Unit,  
St James's University Hospital, Leeds

P D HOWDLE  
Department of Medicine,  
St James's University Hospital, Leeds

1 Corazza GR, Gasbarrini G. Coeliac disease in adults. *Baillière's clinical gastroenterology* 1995;9:329-50.

2 Ferguson R, Basu MK, Asquith P, Cooke WT. Jejunal mucosal abnormalities in patients with recurrent aphthous ulceration. *BMJ* 1976;1:11-3.

3 Triolo G, Triolo G, Accardo-Palumbo A. Behçet's disease and coeliac disease. *Lancet* 1995; 346:1495.

4 International Study Group for Behçet's disease. Criteria for diagnosis of Behçet's disease. *Lancet* 1990;335:1078-80.

5 Corrao G, Corazza GR, Andreani ML, Torchio P, Valentini RA, Galatola G, et al. Serological screening of coeliac disease: choosing the optimal procedure according to various prevalence values. *Gut* 1994;35:771-5.

---

## BOOK REVIEW

---

**Sports Ophthalmology.** By Bruce Zagelbaum. Pp 280. £67.50. Oxford: Blackwell Scientific, 1996.

I found this excellent text both interesting and enjoyable. It provides a systematic and clear approach to ophthalmology in relation to sport with some fascinating anecdotes to illustrate the points being addressed.

The book is divided into four main areas. Firstly, there is an introduction to sports ophthalmology with a broad overview of the subject. Secondly, several sports are examined in detail—looking at how they are played, how injuries occur, and how they can be prevented. The sports discussed indicate that this text is clearly aimed at a North American audience as it concentrates on baseball, basketball, (ice) hockey, and (American) football, although other important sports such as the racquet sports and boxing are included.

The third part of the book looks at the details of ocular injuries which can occur during sport. This is divided into a chapter on the anatomy of the eye and orbit, followed by a breakdown of anterior segment and posterior segment injuries. This is a very clear and the majority of injuries should be well understood by medical and non-medical readers alike.

Finally, there are a couple of short chapters on medical legal aspects of sports ophthalmology and visual training.

The book is well illustrated, mainly in black and white or line diagrams, but there is also an excellent array of colour photographs of injuries. The emphasis of this book is very strongly on injuries of the eye associated with sport and methods of protecting and preventing the eye from suffering these injuries; although there is no specific chapter regarding a general approach to prevention. There is very little in the way of optimum methods of correcting vision or the various visual requirements for each different sport. These areas are possibly of more concern to the sports optometrist. The book however is aimed at 'ophthalmologists, optometrists, team doctors, trainees, and primary care physicians'. In view of the emphasis on injury, this perhaps casts the net a little too wide and indeed at almost £70.00 this may perhaps put it out of reach of anyone other than those with a very strong interest in this field.

C McEWAN

---

## NOTICES

---

### Traditional healers

The latest issue of the *Journal of Community Eye Health* (no 21) focuses on the role of traditional healers in the prevention of blindness in the developing world. Editorial by Paul Courtright and Susan Lewallen, and articles on traditional healers in Zimbabwe, Nepal, and northern Nigeria. For further information please contact Ann Naughton, ICEH, Institute of Ophthalmology, 11-43 Bath Street,

London EC1V 9EL. Tel: 0171 608 6910. Annual subscription: £25. Free to eye health workers in developing countries.

### Tübingen Practical Angiography Course

The Tübingen Practical Angiography Course (International Faculty) will take place on 6 September 1997 at the Auditorium, University Dental Clinic, Osianderstrasse 2-8, Tübingen, Germany. Further details; F Gelissen, MD, Congress Secretariat Dept III, University Eye Clinic, Schleichstrasse 12, 72076 Tübingen, Germany. (Tel: +49 (0) 7071 2987448; fax: +49 (0) 7071 293746; email: ingrid.kreissig@uni-tuebingen.de)

### 5th International Symposium on Ocular Circulation and Neovascularisation

The 5th International Symposium on Ocular Circulation and Neovascularisation will be held on 15-19 September 1997 in Kyoto, Japan. Further details: Professor Dr Masanobu Uyama, Secretary General of the Organising Committee, Department of Ophthalmology, Kansai Medical University, Moriguchi, Osaka 570, Japan. (fax: 81-6-997-3475.)

### 2nd International Symposium on ARMD

The 2nd International Symposium on ARMD will be held at Glasgow University, Scotland under the auspices of the Royal College of Ophthalmologists on 16-18 September 1997. Further details: Dr G E Marshall, Eye Department, Western Infirmary, 38 Church Street, Glasgow G11 6NT, UK. (Tel: 0141 211 2094; fax: 0141 339 7485; email: gem1b@clinmed.gla.ac.uk)

### XXXIst National Ophthalmology Congress

The XXXIst National Ophthalmology Congress will be held on 16-20 September 1997 in the Istanbul Convention and Exhibition Centre, Istanbul, Turkey. Further details; Murat Karacorlu, MD, Congress Scientific Secretariat, Valikonagi Cad, Sezai Selek Sok No 8/5, Nisantasi, Istanbul 80200, Turkey. (Fax: +90 (212) 233 2425; email: mkaracorlu@iris.com.tr)

### 6th International Paediatric Ophthalmology Meeting

The 6th International Paediatric Ophthalmology Meeting will be held on 24-25 September 1997 in Dublin, Ireland. Topics include grand round, neuro-ophthalmology, strabismus, childhood tumours. Further details: Ms Kathleen Kelly, Suite 5, Mater Private Hospital, Eccles Street, Dublin 7, Ireland. (Tel: +3531 838 4444, ext 1759; fax: +3531 838 6314.)

### British and Eire Association of Vitreoretinal Surgeons (BEAVRS)

A meeting of the British and Eire Association of Vitreoretinal Surgeons (BEAVRS) will be held in Birmingham on 16-17 October 1997. Further details: Mr Graham R Kirkby, consultant ophthalmic surgeon, The Birmingham and Midland Eye Centre, City Hospital,

NHS Trust, Birmingham B18 7QU. (Tel: 0121-554 3801; fax: 0121-507 6791.)

### Diabetic Retinopathy and Vireoretinal Surgery Advanced Topics

A meeting under the auspices of the Office of Continuing Medical Education will be held on 17–18 October 1997 at the Thomas B Turner Building, Johns Hopkins Medical Institutions, Baltimore, Maryland, USA. Further details: Office of Continuing Medical education, Johns Hopkins Medical Institutions, Turner 20, 720 Rutland Avenue, Baltimore, MD 21205-2195, USA. (Tel: (410) 955-2959; fax: (410) 955-0807; email: cmenet@som.adm.jhu.edu)

### International Centennial Meeting on Pseudoxanthoma Elasticum

PXE International, Inc, along with the National Institute of Arthritis, Musculoskeletal and Skin Diseases (NIH), is sponsoring an International Centennial Meeting on Pseudoxanthoma Elasticum (PXE) on 6–7 November 1997 in Bethesda, MD, USA. The meeting will focus on genetic, extracellular matrix, and clinical issues. Further details: Sharon Terry, MA, President PXE International, Inc, 23 Mountain Street, Sharon, MA 02067, USA. (Tel and fax: 617 784 3817; email: pxe@tiac.net)

### 10th Annual Wilmer Institute's Current Concepts in Ophthalmology

The 10th Annual Wilmer Institute's Current Concepts in Ophthalmology will be held on 11–13 December 1997 at the Johns Hopkins Medical Institutions, Baltimore, Maryland. Further details: Program Coordinator, Johns Hopkins Medical Institutions, Office of Continuing Medical education, Turner 20/720 Rutland Avenue, Baltimore, MD 21205, USA. (Tel: 410 955-2959; fax: 410 955-0807; email: cmenet@som.adm.jhu.edu; homepage: http://ww2.med.jhu.edu.cme)

### 20th Annual Wilmer Institute's Current Concepts in Ophthalmology

The 20th Annual Wilmer Institute's Current Concepts in Ophthalmology will be held on 5–10 February 1998 at the Hyatt Regency Cerromar Beach Hotel, Dorado, Puerto Rico. Further details: Program Coordinator, Johns

Hopkins Medical Institutions, Office of Continuing Medical education, Turner 20/720 Rutland Avenue, Baltimore, MD 21205, USA. (Tel: 410 955-2959; fax: 410 955-0807; email: cmenet@som.adm.jhu.edu; homepage: http://ww2.med.jhu.edu.cme)

### 15th Annual Wilmer Institute's Current Concepts in Ophthalmology

The 15th Annual Wilmer Institute's Current Concepts in Ophthalmology will be held on 15–20 March 1998 at Manor Vail Lodge, Vail, Colorado. Further details: Program Coordinator, Johns Hopkins Medical Institutions, Office of Continuing Medical education, Turner 20/720 Rutland Avenue, Baltimore, MD 21205, USA. (Tel: 410 955-2959; fax: 410 955-0807; email: cmenet@som.adm.jhu.edu; homepage: http://ww2.med.jhu.edu.cme)

### XXVIIIth International Congress of Ophthalmology

The XXVIIIth International Congress of Ophthalmology will be held in Amsterdam on 21–26 June 1998. Further details: Eurocongress Conference Management, Jan van Goyenkade 11, 1075 HP Amsterdam, the Netherlands. (Tel: +31-20-6793411; fax: +31-20-6737306; internet http://www.solution.nl/ico-98/)

### First Combined International Symposium on Ocular Immunology and Inflammation

The First Combined International Symposium on Ocular Immunology and Inflammation will be held in Amsterdam on 27 June–1

July 1998. The meeting is sponsored by the International Ocular Immunology and Inflammation Society, the International Uveitis Study Group, and the Immunology and Immunopathology of the Eye organisation. Further details: Professor Aize Kijlstra, The Netherlands Ophthalmic Research Institute, PO Box 12141, 1100 AC Amsterdam, Netherlands (email: a.kijlstra@amc.uva.nl)

### 2nd International Conference on Ocular Infections

The 2nd International Conference on Ocular Infections will be held on 22–26 August 1998 in Munich, Germany. Further details: Professor J Frucht-Pery, 2nd International Conference on Ocular Infections, PO Box 50006, Tel Aviv, 61500, Israel. (Tel: 972 3 5140000; fax: 972 3 5175674 or 5140077; email: ocular@kenes.com)

### Correction

Errors occurred in the abstract and Table 1 of the paper by Riise *et al* that appeared in the May issue of the *BJO* (1997;81:378–385).

The first sentence in the Methods section of the abstract should read as follows:

'The phenotypes of affected siblings in 11 Scandinavian families with two or more members who had at least three of the features: retinal dystrophy, polydactyly, obesity, hypogonitalism, and mental retardation, were compared.'

The correct version of Table 1 appears below. We apologise for these errors.

Table 1 Features of the patients in the families described by various groups

Authors	Laurence-Moon	Bardet	Biedl	Solis-Cohen Weiss	Alström
No of patients in the family	4	2	2	4	3
No of patients with features:					
Retinal dystrophy	4	2	2	4	3
Obesity	2	2	2	4	3
Hypogonitalism	4	2	2	3	1
Polydactyly	—	2	2	2	0
Brachydactyly	—	2	2	3	0
Short stature	3	—	—	2	0
Mental retardation	4	—	2	4	0
Diabetes mellitus	—	—	—	1	3
Nerve deafness	—	—	—	—	3
Renal disease	—	—	—	1	2
Paraplegia	3	—	0	—	—

— = not described; 0 = not found.

## INSTRUCTIONS FOR AUTHORS

Adherence to the following guidelines is essential if efficient and expeditious processing of your manuscript is to be achieved. Manuscripts will be returned to authors for revision before peer review if they are submitted in incorrect format. Please indicate in a covering letter which category of paper your article represents.

The *British Journal of Ophthalmology* is an international journal covering all aspects of clinical ophthalmology and the visual/ophthalmic sciences. Contributors should consider the widely varying readership and write clear, simple articles with the minimum of technical detail. Space in the journal is limited and articles should therefore be as concise as possible. One page of text is approximately 1000 words.

Manuscripts should be sent to the editor who selects them on the basis of their suitability for the journal and of reports from independent referees. Manuscripts are acknowledged on receipt and the majority (>80%) are sent for review. Those that are not reviewed are returned to the author as rapidly as possible so that they may be submitted elsewhere.

Manuscripts may be processed by section editors who deal with specific areas of ophthalmology including surgical retina, medical retina, neuro-ophthalmology, glaucoma, paediatric ophthalmology, ocular motility, orbital disease, anterior segment disease, oncology, lens, optics and visual sciences, laboratory sciences, pathology, and immunology. A minimum of two referees, chosen for their specific expertise, review each article.

Papers are accepted on the understanding that they have not been and will not be published elsewhere, and that there are no ethical problems with the work described. If requested, authors shall produce the data upon which the manuscript is based for examination by the editor.

### Categories of papers

#### ORIGINAL ARTICLES

##### (a) Clinical science

Articles on clinical topics are research reports of a general or specialised nature comprising approximately 3000 words and 4-6 display items (Figures and Tables).

##### (b) Laboratory science

Articles on ophthalmic or visual sciences are research reports of experimental work generally of the same size as clinical research reports. Laboratory science papers will be included in a designated section of the journal.

Both types of original article should include the following: title; key words (up to four); address and which author address for correspondence; structured abstract (approx 200 words, headings 'Aims/background', 'Methods', 'Results', and 'Conclusion'); introduction; materials and methods; results and discussion sections; references and acknowledgements; legends for display items (Figures and Tables).

#### REVIEW ARTICLES

Substantive review articles will be included under the section 'Perspective' and will address any aspect of clinical or laboratory

ophthalmology. Review articles will be approximately 3000-5000 words in length including references and may contain display items (Figures and Tables). Most review articles are commissioned but uninvited reviews are welcomed. Prior discussion with the Editor is recommended. All reviews are subject to independent refereeing.

#### LETTERS TO THE EDITOR

Case reports will be published as 'Letters to the editor'. These are normally 500-600 words written in the form of a letter with a maximum of two display items (Figures and Tables). The letter should include an introductory section (without heading), the case report (heading: Case report) and a comment (heading: Comment), plus a maximum of 10 references.

#### CORRESPONDENCE

Letters are normally constructed in the form of scientific correspondence and are usually 200-300 words.

#### Preparation of manuscripts

Manuscripts will be received on the understanding that they have not been and will not be published elsewhere while under editorial review. Manuscripts may be subject to editorial revision with the author's agreement. All communications should be sent to the Editor, *British Journal of Ophthalmology*, Department of Ophthalmology, University of Aberdeen Medical School, Foresterhill, Aberdeen AB9 2ZD, Scotland, UK. (Tel: 01224 663812; Fax: 01224 663832.)

Manuscripts must be submitted in triplicate, and typed double spaced on one side of the paper only, with one inch margins. Each author must sign the covering letter as evidence of consent to publication. Revised manuscripts should be submitted as hard copy and on disk. Detailed instructions will be sent to authors on invitation to revise.

#### ILLUSTRATIONS

Illustrations must be submitted in triplicate. Transparencies must be accompanied by prints. Only salient detail should be included. All must be labelled with the author's name, numbered in the same order as they are cited in the text irrespective of whether they are in colour or black and white, and have the top indicated. Radiographs must be submitted as prints. Line drawings should be clearly labelled and will be redrawn to house style. The width of illustrations for the original articles should be 68 mm, 104 mm, 140 mm or, in exceptional circumstances, 176 mm, to fit the column layout of the journal. Illustrations for 'Letters to the editor' should be 56 mm or 116 mm. Stain used and a scale bar (or magnification) should be given. Legends must be typed on a separate sheet.

#### TABLES

Each table should be on a separate sheet, have a heading, and contain no vertical rules.

#### REFERENCES

In accordance with the Vancouver agreement references are cited by the numerical system. They must be *typed double spaced*.

References in the text must be cited in numerical order of first appearance. References in the list must be given in the numerical order in which they first appear in the text, not in alphabetical order of authors' names. References with one to six authors must include all authors' names; for references with more than six authors the first six should be given and then *et al*. Titles of journals should be abbreviated in accordance with the *Index Medicus* or given in full.<sup>1</sup> References to books must include names of editor(s) if there is one, town where published, name of publisher, year, volume, page numbers.<sup>2</sup>

- 1 Kaye SB, Shimeld C, Grinfield E, Maitland NJ, Hill TJ, Easty DL. Non-traumatic acquisition of herpes simplex virus infection through the eye. *Br J Ophthalmol* 1992; **76**: 412-8.
- 2 Jakobiec FA, Font RL. Orbit. In: Spencer WB, ed. *Ophthalmic pathology: an atlas and textbook*. 3rd ed. Philadelphia: Saunders, 1986: 2461-76.

References will not be checked in the editorial office. Responsibility for their accuracy and completeness lies with the author.

#### SI UNITS

The work should be reported in the units used. If these were not SI units, the equivalent in SI units should be given in parentheses.

#### STATISTICS

Particular attention should be paid to the description of any sample selection process; in particular, the representativeness of the sample should be argued and the handling of any missing data justified. Authors are asked to check tables etc to ensure that missing data are accounted for, that percentages add up to 100 and that numbers in tables are not at variance with those quoted in the text. The policy of the *British Journal of Ophthalmology* is based on the statistical guidelines published in the *British Medical Journal* in 1983 and these are a useful source of information for authors (Altman DG, Gore SM, Gardner MJ, Pocock SJ. Statistical guidelines for contributors to medical journals, *BMJ* 1983; **286**: 1489-93). Blanket statements on the use of statistical techniques should be avoided; it must be made quite clear in context which procedure is being used. Authors should bear in mind that relatively simple analyses are often quite adequate to support the arguments presented.

Advice may be available to authors before submission of papers.

#### Proofs

Contributors will receive ONE proof, and should read it carefully for printers' errors. Alterations to the original text should be kept to a minimum and may be charged to the author. Responsibility for validation of the proof lies with the author.

#### Reprints

These may be ordered from the Offprint Office when proofs are returned.