

## LETTERS TO THE EDITOR

### Congenital toxoplasma chorioretinitis transmitted by preconceptionally immune women

EDITOR.—During pregnancy primary toxoplasmic infection of the mother is a well known cause of congenital chorioretinitis due to fetal contamination by *Toxoplasma gondii*. It is generally thought that women infected before conception have no risk of transmitting the disease to the fetus unless they are severely immunocompromised.<sup>1</sup> We report two children with severe ocular lesions due to congenital toxoplasmosis transmitted by preconceptionally immune mothers.

#### CASE 1

A 1 year old girl presented with a convergent squint as a consequence of bilateral large macular scars. She was the first child of a healthy immunocompetent mother. Three months before conception, the systematic French prenatal serological screening of the mother showed a recent toxoplasmic infection diagnosed by a high titre of specific immunoglobulin M (IgM) (IgM 5200, Biotrol Merck (normal <200), IgG= 40 IU/ml) (Table 1). She was treated with spiramycin 3 MIU per day for a month. At the time of referral, the mother's titre of IgM had significantly decreased (IgM 200) and showed a slightly higher rate of IgG (140 IU/ml). Her daughter's serological status showed a high titre of specific IgG (624 IU/ml), the presence of specific IgA (6/12 index ISAGA; immunosorbent agglutination assay, Biomérieux, index 0-12) and specific IgM (11/12 index ELISA) confirming a fetal infection. Intracerebral calcifications, suggestive of congenital toxoplasmosis, were found on the computed tomogram (Fig 1). The child was otherwise healthy and was not treated.

#### CASE 2

A 1 month old boy was referred because of a congenital cataract in the right eye and a macular atrophic lesion surrounded by an active whitish ring. He was the third child of an immunocompetent woman, a native of Saint-Domingue (Haïti).<sup>1</sup> She had long standing toxoplasmic immunity, confirmed by the absence of specific IgM and stable IgG rates at the fourth and the 10th weeks of her pregnancy (ELISA, IgG 49 and 54 IU/ml respectively) providing proof of an anterior toxoplasmic infection (Table 1). The serology of the neonate showed evidence of active *T gondii* infection with a high IgG titre (ELISA >1200 IU/ml), a positive specific IgM (10/12 index ISAGA) as well as a positive specific IgA (6/12 specific ISAGA). The serological study of the mother, after the birth, showed a

dramatically increased level of IgG (ELISA IgG > 1200 IU/ml) with specific IgA (12/12 index ISAGA); however, no specific IgM was detected. The child was operated on for his cataract and was treated orally with pyrimethamine and sulphadiazine.

#### COMMENT

Congenital chorioretinitis may be a challenging clinical situation for which fetal infections must be considered, in particular, congenital toxoplasmosis.

Because of the concept that the offspring of an immune woman is protected, the diagnosis of infection by *T gondii* may be overlooked in rare cases especially when there are only ocular manifestations.

In our two cases, the mothers were considered to be immune to *T gondii*; nevertheless, they transmitted the disease to their children who presented with sight threatening manifestations and no systemic symptoms. The mothers were not immunocompromised, thus excluding toxoplasmosis reactivation due to immunodeficiency.<sup>2</sup> Different pathophysiological mechanisms may be suggested and may be illustrated by our two cases.

Regarding our first patient, it has been reported recently that, exceptionally, congenital toxoplasmosis may be a consequence of primary maternal toxoplasmosis infection preceding conception.<sup>3,4</sup> Despite medical treatment, the parasitaemia may remain active even months after the onset of the disease and could be responsible for fetal contamination. An emerging immune response as well as the mother's treatment, reducing the parasitaemia of the child, may explain the attenuated clinical manifestation<sup>5</sup> leading to ocular manifestations without other clinical systemic involvement and without miscarriage.

The development of toxoplasmosis in the second case may be explained by reinfection of the mother.<sup>5</sup> The mother's positive specific IgA suggested that there was reinfection of the mother by the parasite, as these immunoglobulins are produced during the digestive phase of the acute infection.<sup>1,5</sup> Strains of different virulence have been described, and reinfection by a particularly virulent strain could explain the inability of the mother's immune system to protect the fetus.<sup>6</sup> The absence of IgM in the mother after the birth of the child is striking and the origin remains unclear although a similar serological status has already been described in a case of spontaneous abortion due to presumed reinfection of a preconceptionally immune mother.<sup>5</sup>

The possibility of the rupture of endometrial toxoplasmic cysts, contaminating the fetus during pregnancy or at birth, can be raised according to Langer<sup>7</sup> but this theory has been considered with reservation by other authors.<sup>8</sup> Nevertheless, because of the IgA level in the mother of our second patient, we assume that there is reinfection and not reactivation.

Consecutive toxoplasmic infection in siblings may occur. Indeed, siblings with ocular toxoplasmosis have been reported<sup>9-11</sup> and pose

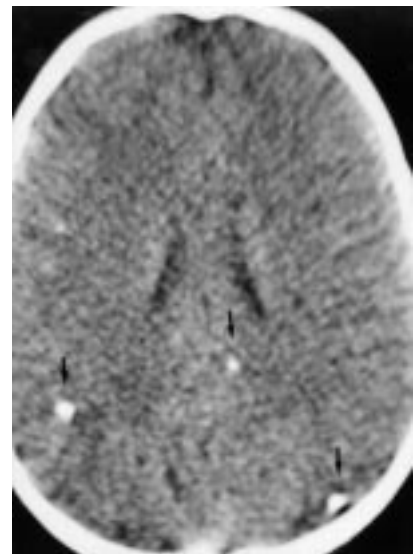


Figure 1 Intracerebral calcifications (arrows) suggestive of congenital toxoplasmosis found on the computed tomogram.

the question of congenital or acquired origin of these iterative intrafamilial toxoplasmic infections. In none of these papers has the congenital origin of the infection been proved calling into question congenital reinfection of these siblings.

Positive toxoplasmic screening before or at the beginning of the pregnancy may be wrongfully reassuring and may lead to an underestimate the toxoplasmic origin of some congenital chorioretinitis. The presentation of these two children with severe ocular manifestations of congenital toxoplasmosis shows indeed that this diagnosis cannot be totally excluded even if the mother has been infected by the parasite before conception.

We thank Mr Carlos Pavesio (London), consultant ophthalmic surgeon, for interesting comments concerning our two cases and Mr Phillip Harris (Edinburgh) for his help.

HÉLÈNE DOLLFUS

PASCAL DUREAU

Service d'Ophtalmologie, Hôpital Necker-Enfants Malades, Université Paris V, Paris, France

CHRISTOPHE HENNEQUIN

Service de Microbiologie, Hôpital Necker-Enfants Malades, Université Paris V, Paris, France

YVES UTEZA

Service d'Ophtalmologie, Hôpital Necker-Enfants Malades, Université Paris V, Paris, France

ALAIN BRON

Service d'Ophtalmologie, Hôpital Général de Dijon, Dijon, France

JEAN LOUIS DUFIER

Service d'Ophtalmologie, Hôpital Necker-Enfants Malades, Université Paris V, Paris, France

Correspondence to: Dr Hélène Dollfus, 8 Avenue des Vosges, 67140 Barr, France.

Accepted for publication 3 June 1998

Table 1 Main serological findings in the two cases

	Child			Mother before conception			Mother after birth		
	IgM	IgG	IgA	IgM	IgG	IgA	IgM	IgG	IgA
Case 1	+	+	+	++	+	NA	+	+	NA
Case 2	+	+	+	-	+	-	-	++	++

Level of specific antibodies against *Toxoplasma gondii*: (+ to ++) present, (-) not present, or (NA) not available.

- Hennequin C, Dureau P, N'Guyen L, et al. Congenital toxoplasmosis acquired from an immune woman. *Pediatr Infect Dis J* 1997;16:75-7.
- Marty P, Bongain A, Thulliez P, et al. Prenatal diagnosis of severe fetal toxoplasmosis as a result of toxoplasmic reactivation in a HIV-1 seropositive woman. *Prenatal Diagn* 1994;14:414-15.
- Pons JC, Sigrand C, Grangeot-Keros L, et al. Toxoplasmose congénitale: transmission au fœtus d'une infection maternelle antéconceptionnelle. *Presse Méd* 1995;24:3-5.
- Desmont G, Couvreur J, Thulliez P. Toxoplasmose congénitale et toxoplasmose ganglionnaire maternelle préconceptionnelle. *Presse Méd* 1991;20:387-8.

- 5 Fortier B, Aissa E, Ajana F, *et al.* Spontaneous abortion and reinfection by *Toxoplasma gondii*. *Lancet* 1991;338:444.
- 6 Howe DK, Sibley LD. *Toxoplasma gondii* comprises three clonal lineages: correlation of a parasite genotype with human disease. *J Infect Dis* 1995;172:1561-6.
- 7 Langer H. Repeated congenital infection with *Toxoplasma gondii*. *Obstet Gynecol* 1963;21:318-29.
- 8 Remington JS. Toxoplasmosis. In: Remington and Klein, eds, *Infectious diseases of the fetus and newborn infant*. 4th ed. Philadelphia: Saunders, 1995:89-195.
- 9 Lou P, Kazdan J, Kumar Basu P. Ocular toxoplasmosis in three consecutive siblings. *Arch Ophthalmol* 1978;96:613-14.
- 10 Stern G, Romano PE. Congenital ocular toxoplasmosis. Possible occurrence in siblings. *Arch Ophthalmol* 1978;96:615-17.
- 11 Asbell PE, Vermund SH, Hofeldt AJ. Presumed toxoplasmic retinochoroiditis in four siblings. *Am J Ophthalmol* 1982;94:656-63.

### Shinty and ocular trauma in north west Scotland

EDITOR.—Sports related eye injuries account for up to 42% of ocular trauma requiring hospitalisation<sup>1</sup> and 10% of ruptured globes.<sup>2</sup> The commonest cause of sports related ocular trauma seen in this department is shinty.

Shinty is a parochial game with a devoted following and a playing area which stretches from Argyll and Bute in the south to Inverness in the east to Skye in the west. It is derived from hurling and is thought to have been introduced by St Bridget who travelled to Scotland with St Columba to promote Christianity in the highlands.

The game itself is not unlike hockey with two opposing teams who attempt to score more goals than the opposition using a curved stick or "camán". Two notable differences exist between the two games, however. There is no restriction on the height above which the camán may be raised or above which the ball may travel.

We report two cases of ocular trauma which are representative of the cases commonly seen in this department during the shinty season.

#### CASE 1

A 30 year old man was admitted after being struck on the face with a shinty stick.

Visual acuity was perception of light only. A 10 mm horizontal upper lid laceration was noted with a 200 degree superior iridodialysis. The lens was subluxated inferiorly with zonal dehiscence above. Intraocular pressure was 15 mm Hg with no orbital fracture.

After initial primary repair of the lid the patient was treated with topical steroids and antibiotics. The eye settled with visual acuity of counting fingers. One month after the original injury an acute rise in intraocular pressure to 54 mm Hg was lowered medically before lensectomy and anterior vitrectomy. Much of the disinserted iris was also removed.

Six months after the original injury visual acuity was 6/12 with an aphakic correction.

#### CASE 2

A 29 year old man was struck on the left eye by a shinty ball. Visual acuity was no perception of light. A partial thickness upper lid laceration was present and the globe was clearly ruptured and disorganised.

Examination under anaesthesia revealed a full thickness laceration of the globe extending for a total of 20 mm and involving the whole corneal diameter. Uveal tissue and vitreous were seen to be prolapsing through the wound with no identifiable lens. A primary enuclea-

tion was performed. The patient currently has visual acuity of 6/5 in the right eye with no evidence of sympathetic ophthalmia.

#### COMMENT

Shinty related ocular trauma causes significant ocular morbidity and occasionally the injuries are devastating. Patients are exclusively male.

Unfortunately, the globe is particularly vulnerable owing to the nature and dimensions of the equipment used in shinty. The diameter of the ball (6.03–6.36 cm) and the head of the camán (no greater than 6 cm wide)<sup>3</sup> allow portions of both to traumatise the globe with only partial protection from the orbital rim. The ball is also very hard, comprising an inner core of dense cork with an outer layer of leather<sup>3</sup> and can reach speeds of up to 80 miles per hour.

The recent spate of shinty related injuries has reopened the debate as to whether the wearing of faceguards or helmets should be compulsory during formal matches and practice sessions. At present, such protection is optional, including physical education at school.

We feel that faceguards and helmets should be worn at all levels of the game and should be compulsory with particular emphasis on enforcement at school and junior levels. Until the traditionalists who feel that the game is in some way "spoiled" by protective headgear relent, this easily preventable sports injury will continue to cause serious ocular morbidity in the highlands of Scotland.

AT PURDIE  
IF WHYTE

Department of Ophthalmology, Raigmore Hospital,  
Inverness IV2 3UJ

Correspondence to: Dr Purdie.

Accepted for publication 3 June 1998

- 1 Macewen CJ. Eye injuries: a prospective study of 5671 cases. *Br J Ophthalmol* 1989;73:888-94.
- 2 Schein OD, Hibberd PL, Shingleton PL, *et al.* The spectrum and burden of ocular injury. *Ophthalmology* 1988;95:300-5.
- 3 The Cammanachd Association Annual 1997-1998.

### Ultrastructural alterations in the stroma adjacent to non-inflammatory corneal perforations associated with long standing rheumatoid arthritis

EDITOR.—Patients with rheumatoid arthritis commonly have two types of corneal ulceration. One is a peripheral corneal ulceration thought to be caused by complex mediated hypersensitivity.<sup>1</sup> The other is a paracentral corneal ulceration that tends to perforate the cornea rapidly. Its pathogenesis remains unknown, though a key feature is the lack of inflammation, leading to the suggestion that it is the result of surface disease (drying).

#### CASE REPORTS

We examined two individuals, a 38 year old woman and a 76 year old woman, with unilateral corneal epithelial defects and aqueous tear deficiencies. Both patients had been treated for rheumatoid arthritis for several years; however, neither had been on systemic corticosteroids. The 76 year old had had successful cataract surgery 1 week previously and was using 0.1% betamethasone eye drops. At the time of presentation both women had severe dry eye (possibly secondary Sjögren's syndrome, though no biopsies were taken to

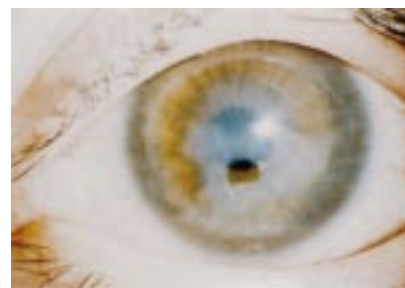

Figure 1 Paracentral corneal perforation (38 year old woman). There is little or no inflammation on the ocular surface. The anterior chamber is maintained by a therapeutic contact lens.

confirm this) as assessed by detailed slit lamp examination with fluorescein and rose bengal staining, and by the Schirmer test. The 38 year old was started on 0.1% fluorometholone and 0.3% norfloxacin and dibekacin eye drops four times a day, and the 76 year old was switched to the topical application of 0.1% betamethasone and 0.3% ofloxacin ointments four times a day. A few weeks later paracentral corneal perforations developed suddenly, though without pain (Fig 1). Unlike peripheral corneal ulceration, little or no inflammation was seen on the ocular surface at any time. Penetrating keratoplasties were performed and a treatment regimen was begun that included artificial tears (for dry eye) and 0.1% betamethasone topically four times a day. In addition, the 76 year old received 2 mg betamethasone intravenously once a day and 1 g flomoxef sodium intravenously twice a day for the first 3 days after surgery; this was followed by betamethasone (1 mg) and antibiotic (300 mg cefzilil; 100 mg, three times a day) taken internally for 1 week. At the time of writing, topical steroids (in both cases 0.1% betamethasone) continue to be used, and both patients are doing well 7 years (38 year old) and 5 years (76 year old) after surgery, with no sign of another perforation.

At the time of surgery, corneal tissue directly adjacent to the paracentral perforation, as well as tissue in the peripheral cornea, was obtained for histopathological study. In line with the lack of clinically detectable inflammation (Fig 1), light microscopic examination of both cases revealed only a few inflammatory cells surrounding the perforation and none in more peripheral areas (data not shown). In both patients' corneas, electron microscopy documented many electron dense deposits in the extracellular stromal matrix (Fig 2). These amorphous deposits were intimately associated with collagen, and might represent degraded and/or aggregating collagen fibrils resulting from the melting process. Also detected were numerous atypical, thin fibrils (Fig 2; inset). These were fairly widely interspersed with normal diameter collagen though, on occasion, they appeared in groups. Interestingly, these abnormal electron microscopic features were observed not only in stroma right at the edge of the perforation, but in more peripheral regions of the cornea as well.

#### COMMENT

The general clinical presentations of both these individuals, especially the lack of inflammation, are similar to previous reports of perforated paracentral corneas.<sup>2</sup> Often, infiltrating macrophages and T cells that are associated with HLA class II antigens are located around corneal ulcers,<sup>3</sup> and various

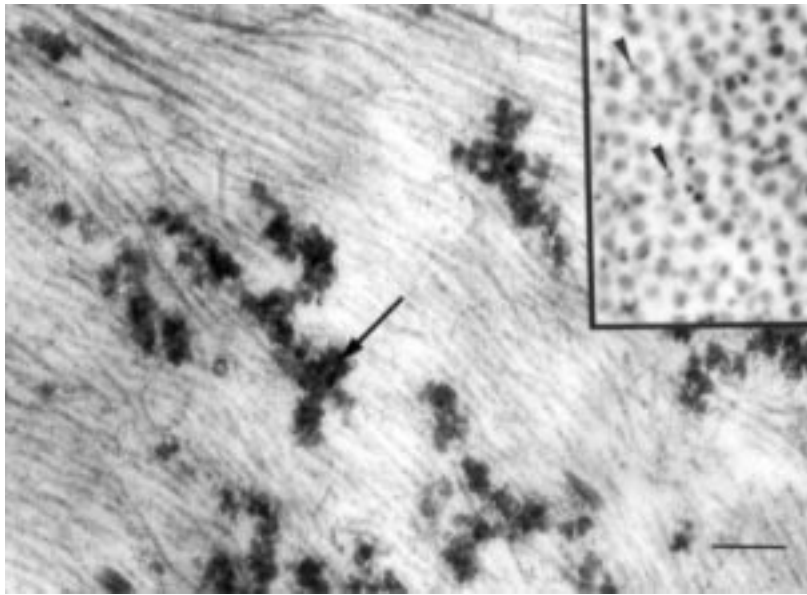


Figure 2 Corneal stroma surrounding the perforated area (76 year old woman). Electron dense material (arrow), possibly aggregated collagen, is located throughout the extracellular matrix. Also (inset), many atypical, thin fibres (arrowheads) are interspersed with collagen. Bar=200 nm (main figure) and 100 nm (inset).

cytokines and proteinases secreted from these cells are thought to trigger a corneal perforation. However, this pathogenesis is unlikely in our cases because little or no inflammatory cell infiltration was detected.

As in all connective tissues, collagen imparts to stroma by far the majority of its tensile strength. It follows that ultrastructural collagen alterations might cause our patients' corneas to become somewhat fragile, predisposing them to non-inflammatory corneal perforations. With this in mind, it is noteworthy that the alterations of the corneal extracellular matrix we report here closely resemble those seen in ruptured hand tendons of rheumatoid arthritis patients.<sup>4</sup> It is possible, therefore, that a similar structural weakening of both these connective tissues occurs and is associated with collagen abnormalities in long standing rheumatoid arthritis.

WAKAKO ADACHI  
KOHJI NISHIDA

ANDREW J QUANTOCK  
SHIGERU KINOSHITA

Department of Ophthalmology, Kyoto Prefectural  
University of Medicine, Kyoto, Japan

YASUO ISHII

Department of Ophthalmology, Shinkawabashi General  
Hospital, Tokyo, Japan

Correspondence to: Kohji Nishida, MD, PhD,  
Department of Ophthalmology, Kyoto Prefectural  
University of Medicine, Kawaramachi Hirokoji,  
Kyoto 602, Japan.

Accepted for publication 29 July 1998

- 1 Mondino BJ. Inflammatory disease of the peripheral cornea. *Ophthalmology* 1988;95:463-72.
- 2 Cohen KL. Sterile corneal perforation after cataract surgery in Sjögren's syndrome. *Br J Ophthalmol* 1982;66:179-82.
- 3 Kervick GN, Pflugfelder SC, Haimovici R, et al. Paracentral rheumatoid corneal ulceration: clinical features and cyclosporine therapy. *Ophthalmology* 1992;99:80-8.
- 4 Neurath MF, Stofft E. Ultrastructural causes of rupture of hand tendons in patients with rheumatoid arthritis. *Scand J Plast Reconstr Hand Surg* 1993;27:59-65.

#### Overt chorioretinitis after patient acquired toxoplasmosis in an immunocompetent subject

EDITOR.—Acquired *Toxoplasma gondii* infection is usually asymptomatic and uncomplicated unless it occurs in severely immunodepressed patients or in particular epidemiological settings.<sup>1,2</sup>

We report a case of toxoplasmic chorioretinitis (CR) occurring 15 months after patent primary infection with cervical adenopathies in an immunocompetent woman.

#### CASE REPORT

VK, a 31 year old woman, presented with blurred vision in the left eye, which had started a few days previously. Visual acuity on this side was preserved at 16/20. Split lamp examination showed a negative Tyndall in the

anterior chamber. Ocular pressure was 10 mm Hg. Retinal examination with the three mirror method revealed a fresh and strictly peripheral chorioretinal lesion at 10 o'clock, suggestive of toxoplasmosis, with no evidence of previous scarring. Peripapillary haemorrhage and a moderate vitreal reaction were also noted. The right eye was strictly normal. Two small cervical adenopathies could be felt.

Fifteen months previously this nulliparous woman had developed cervical adenopathies, with serum anti-toxoplasmic antibody kinetics typical of very recent seroconversion (Table 1).<sup>3</sup> Specific IgA antibodies persisted 8 months after seroconversion and the woman, who wished to become pregnant, was referred to the Reims Toxoplasmosis Group to assess the risk of maternofetal transmission.<sup>4,5</sup>

Eight days after onset of the visual disorders the anterior chamber was sampled by puncture. Aqueous humour and peripheral blood were tested for toxoplasmic DNA by polymerase chain reaction (PCR)<sup>6</sup> and/or blood circulating *T gondii* research, and for specific IgG, IgM, and IgA antibodies by immunocapture tests; the Witmer-Desmonts coefficient (C) was calculated.<sup>7,7</sup> Serological tests for viral and other parasitic infections were also done, and her immune status was thoroughly investigated (Table 2). Anti-toxoplasma chemotherapy was started immediately, with a combination of pyrimethamine-sulphadiazine and calcium folinate for 1 month. The visual disorders improved and the chorioretinal lesion healed rapidly.

#### COMMENT

This case is unusual in that a chorioretinal toxoplasmic lesion occurred 15 months after seroconversion in a healthy adult.

The precise date of infection was deduced from clinical arguments and the results of biological tests. The first battery of serological tests, at the onset of cervical adenopathies (T0), was carried out because the patient was intending to have children. Eight months later the persistence of specific IgA antibodies pointed to active toxoplasmosis. As we had previously observed cases of congenital transmission after preconceptional seroconversion with adenopathies, the patient was advised not to become pregnant yet.<sup>3,5</sup> This position was borne out by the onset of chorioretinitis some months later. The ocular involvement was confirmed by sampling the anterior chamber (positive Witmer-Desmonts coefficient, and local synthesis of specific IgA) less than 8 days after the onset of visual disorders.

Ocular lesions were long considered to be a sometimes very late complication of congenital toxoplasmosis, except in case of immunodepression (human immunodeficiency virus, organ transplantation, etc).<sup>1,2,8</sup> Our patient's immune status was strictly normal; she was

Table 1 Kinetics of anti-toxoplasmic IgG, IgM and IgA antibodies (months) from the first serological tests at the time of onset of cervical adenopathies (T0). T8 months corresponds to the first immunological study in parasitological laboratory and T15 months to the onset of chorioretinitis. Note that the first serological tests (undertaken in another laboratory) were based only on immunoenzymatic methodology (IgG and IgM (MEIA))

Methods	IgG-Ab (MEIA) (IU/ml)	IgG-Ab* (U/HSDA/ml)	IgM-Ab (MEIA) (index)	IgM-Ab (ICT-M)† 0-12	IgA-Ab (ICT-A)† 0-12
Cut off	3	10	0.5	9	2
T 0 (onset of cervical adenopathies)	71	ND	9.9	ND	ND
T 0.5	855	ND	8.3	ND	ND
T 2	4030	ND	3.6	ND	ND
T 4	4200	ND	1.5	ND	ND
T 8 (pregnancy contraindicated)	1820	6400	1.4	11	10.5
T 12	880	3200	1.0	10.5	10
T 15 (onset of chorioretinitis)	680	6400	1.1	11	10

\*Detection of IgG antibodies by high sensitivity direct agglutination (HSDA).

†Detection of IgM and IgA antibodies by immunocapture test with revelation by a tachyzoite suspension (ICT-M, ICT-A).

Table 2 Results of the different tests performed on serum and aqueous humour

	Blood/serum	Aqueous humour	Interpretation
Herpesvirus, CMV, EBV, Lyme, <i>Larva migrans</i>	Negative	ND	No viral or other parasitic infection
HIV	Negative	ND	HIV seronegative
Immunological examination and lymphocyte subpopulations	Normal	ND	No immune deficiency
<i>T gondii</i> DNA	Negative	Positive with one probe	Doubtful result on aqueous humour
Total IgG g/l	12.8	0.056	Witmer-Desmonts coefficient: 4.6 (suggesting local IgG-Ab synthesis)
Anti-toxoplasmic IgG (U/HSDA/ml)	6400	128	Presence of serum IgM-Ab; no intraocular IgM-Ab synthesis
Specific IgM (ICT-M)	11/12	0/4	Presence of serum IgA-Ab; intraocular IgA-Ab synthesis
Specific IgA (ICT-A)	10/12	4/4	
Detection of circulating parasite by mouse and cell culture inoculation	Negative	ND	No circulating toxoplasma

ND = not done.

not on immunosuppressive drugs and had no intercurrent infections. The persistence of two small cervical adenopathies and specific IgA antibodies 15 months after the primary infection illustrates the long duration of the active phase of infection in this case complicated by secondary chorioretinitis.<sup>1,9</sup> With a well defined interval before onset, this case of chorioretinal involvement (isolated, unilateral, and without pre-existing lesions) differs from other reported cases in which the date of seroconversion was less precise and the chorioretinitis was often associated with neurological manifestations.<sup>1,8,10</sup>

This case of secondary toxoplasmic chorioretinitis in an immunocompetent woman suggests that all patients with persistent adenopathies and serological markers of active *T gondii* infection should have regular ocular monitoring.

Financial support was provided by the Programme Hospitalier de Recherche Clinique (1994), Direction des Hôpitaux, Ministère des Affaires Sociales, de la Santé et de la Ville, Paris, France.

C MARX-CHEMLA  
I VILLENA  
F FOUADRINIER  
J M PINON

Reims Toxoplasmosis Group, Laboratoire Parasitologie,  
Hôpital Maison Blanche (UPRESEA 2070, IFR 53),  
CHU, Reims Cedex France

A GOTZAMANIS  
F HAMON  
A DUCASSE

Reims Toxoplasmosis Group, Services Ophtalmologie,  
Hôpital Robert Debré, CHU, Reims Cedex France

Correspondence to: C Marx-Chemla, Laboratoire de Parasitologie, Hôpital Maison Blanche, 45 rue Cognacq Jay, 51092 Reims Cedex France.

Accepted for publication 18 June 1998

- Holland GN, O'Connor GR, Belfort R Jr, et al. Toxoplasmosis. In: Pepose JS, Holland GN, Wilhelmus KR, eds. *Ocular infection and immunity*. 1st ed. St Louis: Mosby Yearbook, 1996;1183-223.
- Cochereau-Massin I, LeHoang P, Lautier-Frau M, et al. Ocular toxoplasmosis in human immunodeficiency virus-infected patients. *Am J Ophthalmol* 1992;114:130-5.
- Thulliez P, Daffos F, Forestier F. Diagnosis of toxoplasma infection in the pregnant woman and the unborn child: current problems. *Scand J Infect Dis* 1992;Suppl 84:18-22.
- Villena I, Chemla C, Quereux C, et al. Prenatal diagnosis of congenital toxoplasmosis transmitted by an immunocompetent woman infected before conception. *Prenatal diagnosis* (in press)
- Desmonts G, Couvreur J, Thulliez P. Congenital toxoplasmosis. Five cases with mother-to-child transmission of pre-pregnancy infection. *Presse Med* 1990;19:1445-9.
- Thelliez E, Aubert D, Ducasse A, et al. Patients sans toxoplasmose oculaire, résultat de la PCR et de l'immunocapture. *Ophtalmologie* 1996;10:207-9.
- Thelliez E, Ducasse A, Marx C, et al. Etude des immunoglobulines spécifiques de la toxoplasmose dans l'humeur aqueuse. *Bull Soc Oph* 1994;1:51-6.
- Montoya JG, Remington JS. Toxoplasmic chorioretinitis in the setting of acute acquired toxoplasmosis. *Clin Infect Dis* 1996;23:277-82.

- Fouadrinier F, Marx C, Aubert D, et al. Value of specific immunoglobulin A detection by two immunocapture assays in the diagnosis of toxoplasmosis. *Eur J Clin Microbiol Infect Dis* 1995;14:585-90.
- Thulliez P. Acquired toxoplasmosis with ocular or neurologic involvement. *Presse Med* 1996;25:438-42.

### Anterior segment complications of indirect diode laser in diabetic patients

EDITOR,—We describe two cases of recurrent corneal epithelial breakdown following indirect diode laser panretinal photocoagulation (PRP) in diabetic patients. The particular nature of diode laser burns may have contributed to this event.

#### CASE 1

A 21 year old insulin dependent diabetic woman underwent bilateral indirect diode laser PRP under general anaesthesia for proliferative diabetic retinopathy (PDR). She presented 4 weeks later with a 3 week history of a painful left eye. Visual acuity was 6/12 and a 3 mm × 2 mm infiltrative corneal ulcer was noted. There was total corneal anaesthesia bilaterally and both pupils were mid dilated and non-reactive to light and accommodation. Microbiology was negative and the ulcer gradually healed with intensive topical antibiotic treatment. Over the next 3 months corneal anaesthesia persisted in the left eye, but resolved in the right. She had two further episodes of corneal epithelial breakdown on the left which were successfully managed with topical lubricants. One year after laser treatment visual acuity was 6/6 in the right eye and 6/12 in the left, with residual stromal scarring on the left (Fig 1). Both pupils remained mid dilated and non-reactive.

#### CASE 2

A 26 year old insulin dependent diabetic woman underwent indirect diode PRP to the left eye under general anaesthesia for PDR. One week later she presented with a dilated and non-reactive left pupil, complained of not being able to focus, and had an anaesthetic cornea. Subsequently she underwent two further treatment sessions to both eyes for persistent PDR. She then developed a large

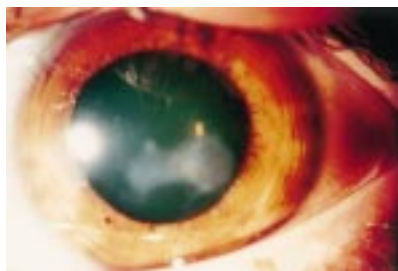


Figure 1 Scarring in left cornea, case 1.

epithelial defect of the left cornea, total corneal anaesthesia bilaterally, and semidilated pupils non-reactive to light and accommodation. The epithelial defect was managed with topical antibiotics and lubricants with slow resolution. She went on to have three further episodes of epithelial breakdown on the left and two on the right. Topical lubrication and padding proved to be the most effective treatment. Eighteen months after initial laser treatment, corneal sensation had recovered, visual acuity was 6/18 in both eyes, and there was mild central stromal scarring bilaterally.

#### COMMENT

Corneal sensation and innervation of the pupil and accommodation is supplied by the long and short posterior ciliary nerves which pierce the eye posteriorly and run forward in the suprachoroidal space. Disruption of this anatomical pathway could therefore lead to the problems experienced by the patients described above. Indeed, pupillary abnormalities and a temporary reduction in corneal sensitivity have been noted following argon, xenon, and krypton laser PRP.<sup>1,2</sup> However, to our knowledge, such profound corneal abnormalities with ulceration and scarring have not been described previously.

The histopathological damage inflicted by laser burns has been studied in both the animal and human eye.<sup>3-5</sup> Clinically burns can be classified as follows: grade 1 consists of a greyish retinal discoloration only; grade 2 shows whitish discoloration surrounded by a greyish periphery; and finally grade 3 burns have a distinct white centre, representing the highest intensity burn.

High intensity laser burns have been shown to damage choroidal nerves in humans and animals.<sup>2-6</sup> The thermal damage profile of a retinal burn caused by the diode laser (wavelength 810 nm) extends deeper into the choroid than that from an argon blue green

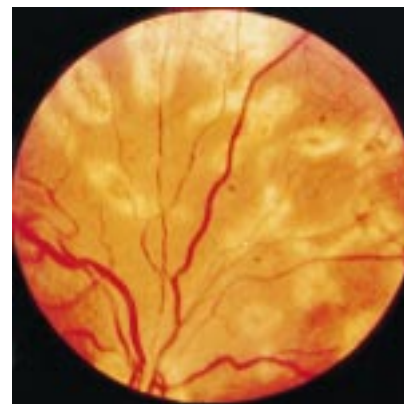

Figure 2 Final scarring pattern of panretinal photocoagulation as seen typically in both patients.

laser (488–514.5 nm).<sup>3,5</sup> This is due to the lower absorption within melanin of the longer diode laser wavelength. Hence there is potentially a greater risk of choroidal nerve damage from the diode laser, particularly with an excessively intense burn. The burn size associated with indirect laser tends to be larger than that achieved with direct laser, particularly if the working distance increases during PRP, thus causing thermal damage to a greater area of retina. Indeed, the post PRP fundus photographs of both patients show large burns tending towards confluence (Fig 2).

Diabetics with and without retinopathy have significantly increased epithelial fragility when compared with normal controls.<sup>7</sup> Diabetics also have reduced corneal sensitivity when compared with normal controls.<sup>8</sup> However, before laser treatment, neither of our two patients had ever had any symptoms or signs of corneal disease. All the corneal problems started post laser and were associated with a total lack of corneal sensation. As the corneal sensation recovered over the months the frequency of the epithelial erosions diminished.

The optics of the diode laser beam mean that it is possible to clip the edges of the iris in the laser beam during treatment.<sup>9,10</sup> It is possible that this could account for some of the pupillary abnormalities post PRP, but taking into account the corneal anaesthesia and

reduced accommodation, it would seem more likely to be a result of damage to a common denominator.

We hypothesise that the large area involved in performing an indirect PRP, and the depth of the burn achieved with diode laser, damaged a large number of choroidal nerves causing the pupillary and corneal abnormalities.

We propose the following measures to avoid choroidal nerve damage when performing indirect diode laser PRP. Grade 1 to 2 burns should be discretely placed so as to prevent confluence certainly avoiding high intensity grade 3 burns. Under peribulbar and general anaesthesia, it is particularly important to use less intense burns as the painful feedback from choroidal nerve damage is absent. Care should be taken with the working distance of the laser indirect to avoid unduly large burns. Particular caution should be exercised when treating in the horizontal retinal meridia, the typical location of the long ciliary nerves. Finally, the patient should be warned of possible effects on the anterior segment which may occur after indirect diode laser PRP.

S A BUCKLEY  
D N PARMAR  
H JACKSON  
J D A MCHUGH  
P A HUNTER

King's College Hospital, London

Correspondence to: Miss Buckley.  
Accepted for publication 18 June 1998

- Schiodte SN. Effects on choroidal nerves after panretinal xenon arc and argon laser photocoagulation. *Acta Ophthalmol* 1984;62:244–55.
- Menchini U, Scialdone A, Pietroni C, et al. Argon vs krypton PRP side effects on the anterior segment. *Ophthalmologica* 1990;201:66–70.
- Wallow IHL, Spouse WE, Stevens TS. Clinicopathologic correlation of diode laser burns in monkeys. *Arch Ophthalmol* 1991;109:648–53.
- Tso MO, Wallow IHL, Elgin S. Experimental photocoagulation of the human retina. *Arch Ophthalmol* 1977;95:1035–50.
- McHugh JDA, Marshall J, Capon M, et al. Transpupillary retinal photocoagulation in the eyes of rabbit and human using a diode laser. *Lasers Light Ophthalmol* 1988;2:125–43.
- Kaufmann PL, Rohen JW, Gabelt BT, et al. Parasympathetic denervation of the ciliary muscle following panretinal photocoagulation. *Curr Eye Res* 1991;10:437–55.
- Saini JS, Khandalavla B. Corneal epithelial fragility in diabetes mellitus. *Can J Ophthalmol* 1995;30:142–6.
- Ruben ST. Corneal sensation in insulin dependent and non-insulin dependent diabetics with proliferative retinopathy. *Acta Ophthalmol* 1994;72:576–80.
- Woon WH, fytche TJ, Hamilton AMP, et al. Iris clipping of a diode laser beam when performing retinal photocoagulation. *Br J Ophthalmol* 1991;75:386–90.
- Mills M, Schulman JA, Kooragayala LM, et al. Significant ocular complications following diode laser treatment for retinopathy of prematurity. *Invest Ophthalmol Vis Sci* 1996;37(suppl):606.

## British Journal of Ophthalmology - <http://www.bjophthalmol.com>

Visitors to the world wide web can now access the *British Journal of Ophthalmology* either through the BMJ Publishing Group's home page (<http://www.bmjpub.com>) or directly by using its individual URL (<http://www.bjophthalmol.com>). There they will find the following:

- Current contents list for the journal
- Contents lists of previous issues
- Members of the editorial board
- Information for subscribers
- Instructions for authors
- Details of reprint services.
- BMJ Publishing Group home page
- British Medical Association web site
- Online books catalogue
- BMJ Publishing Group books.

A hotlink gives access to:

The web site is at a preliminary stage and there are plans to develop it into a more sophisticated site. Suggestions from visitors about features they would like to see are welcomed. They can be left via the opening page of the BMJ Publishing Group site or, alternatively, via the journal page, through "about this site".