

LETTERS TO THE EDITOR

Gaze evoked amaurosis in neurofibromatosis type II

EDITOR.—The electroretinogram (ERG) and visual evoked potential (VEP) to pattern reversal stimulation became degraded in association with visual loss in a young patient with gaze evoked amaurosis who had a mass at the apex of the left orbit. His visual symptoms improved following left orbital decompression and Snellen acuity was maintained at 6/6; however, the pattern VEP was attenuated and degraded compared with before surgery.

CASE REPORT

A 9 year old boy with neurofibromatosis type II initially presented with a history of intermittent visual disturbance affecting the left eye when in left gaze. The right eye had a retinal hamartoma and a visual acuity of 6/12. He had undergone previous surgery to correct a right divergent squint. A partial third nerve palsy on the left side was present.

On examination, visual acuity of the left eye was 6/6 when viewing in the primary position, and pupillary reactions were normal. However, acuity became perception of light on sustained left lateral gaze, and a mild relative

afferent pupillary defect became detectable at this stage in the left eye. Intraocular pressure by applanation tonometry was 10 mm Hg in the right eye and 12 mm Hg in the left. No proptosis was detectable. Ophthalmoscopy revealed a normal right optic nerve and marked swelling of the left optic disc (Fig 1). An enlarged blind spot was evident on visual field testing.

Computed tomography and magnetic resonance imaging demonstrated a small rounded mass just to the left of the brainstem which appeared to involve the third nerve and extended forwards to the cavernous sinus. The mass was thought to represent a third nerve neuroma. In addition, imaging showed the optic chiasm was displaced downwards. There was also small mass extending forwards medial to the optic nerve at the apex of the left orbit and this was thought to be an intraorbital extension of the third nerve neurofibroma (see Fig 2).

ERG and VEP recording following flash and pattern reversal stimulation gave normal responses for each eye when looking straight ahead. However, the pattern ERG (recorded with a corneal electrode) and pattern VEP to 50' checks occupying a large stimulus field (28 degrees horizontally by 21 degrees vertically) became progressively degraded and eventually

non-detectable on sustained left lateral gaze (see Fig 3). In contrast, the flash ERG and VEP were attenuated to a relatively minor extent on sustained left gaze (on average, 14% smaller). Retinal and occipital pattern responses normalised rapidly when the eyes returned to straight ahead viewing. He underwent an optic nerve decompression, following which he had some degradation of the pattern VEP but did not experience any further episodes of gaze evoked amaurosis.

COMMENT

Amaurosis fugax is a well recognised symptom associated with carotid occlusive disease in older patients. Our case demonstrates that it may also be a sign associated with an intraorbital mass, and can occur in younger patients.

Gaze evoked amaurosis has been reported to occur occasionally in patients with cavernous haemangiomas, optic nerve sheath meningiomas, and osteoma.^{1,2} Mechanisms proposed to cause gaze amaurosis include optic nerve or retinal ischaemia, disruption of axonal conduction due to optic nerve compression, and compression leading to ischaemia of the globe.^{1,3} Our case had an intraorbital extension of the third nerve neurofibroma down the medial branches of the lower division of the third nerve. The left optic nerve appeared to be

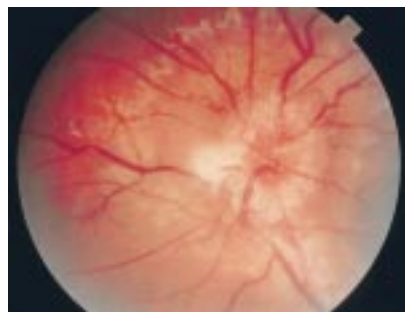


Figure 1 Left optic disc swelling.

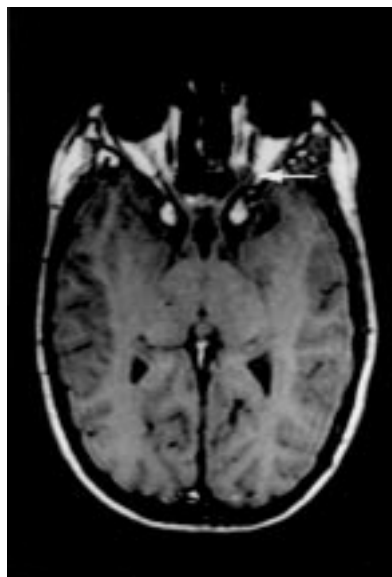
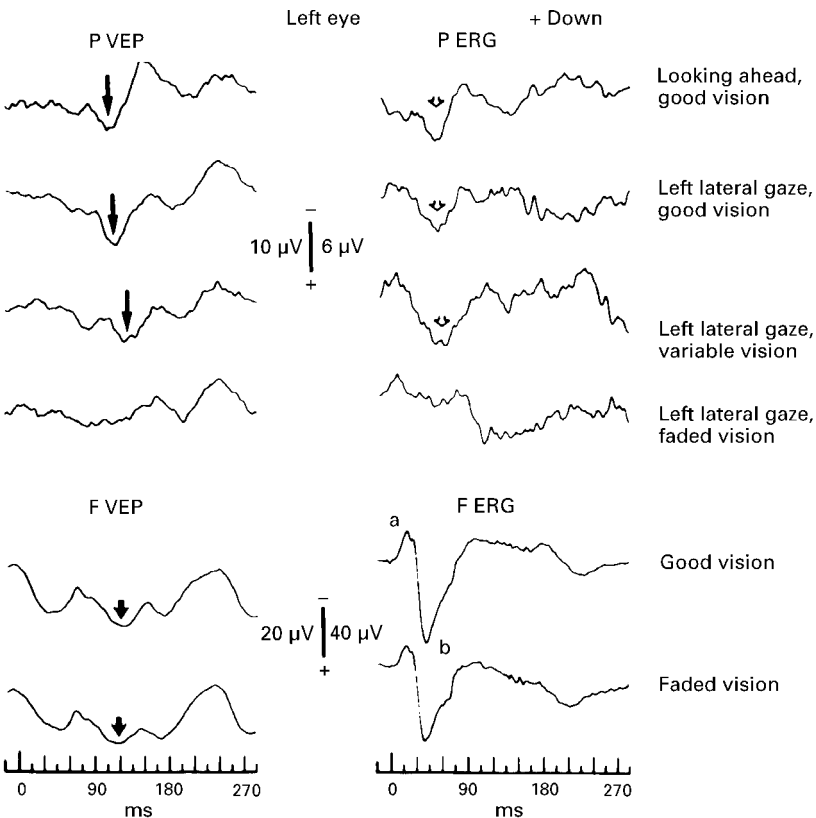


Figure 2 Magnetic resonance imaging scan demonstrating tumour of left optic nerve (arrowed).



DC 14 years

Figure 3 Pattern reversal VEPs (upper left; P100 arrowed) and corneal pattern reversal ERGs (upper right; P50 arrowed) for stimulation with 50' checks, when the left eye vision was at normal levels and when faded on left lateral gaze. Note marked attenuation of both P ERG and P VEP when vision was poor. Lower traces are flash ERG and VEP responses recorded when vision was good, and faded on left lateral gaze. Both retinal and occipital responses were marginally attenuated (by around 14%) when vision was faded.

mildly stretched over the mass, and to become more stretched on extreme left gaze. This process is similar to that described by Manor *et al*⁴ in 1996 involving reading evoked amaurosis. Interestingly, in our patient, pattern ERG and VEP testing indicated that, during the periods of gaze evoked visual loss, macular function was more severely compromised, compared with extramacular function (reflected in flash ERG and VEP results). The rapid reversibility of the pattern ERG changes suggests that ischaemic mechanisms, rather than disruption in axonal conduction by direct compression, may be predominantly responsible for the visual loss. This notion is supported by the observations of Knapp *et al*⁵ who used Doppler blood flow studies to demonstrate reduction of blood flow in the central retinal artery during gaze evoked amaurosis. Our patient had no further episodes of amaurosis after the surgery. Visual acuity remained 6/6 postoperatively. It thus appears from our case, and other cases, of gaze evoked amaurosis that the transient visual loss is not predicative of permanent disability, but that its presence can be an important clinical sign and indicate optic function near the threshold of disruption.

L SMITH
A KRISS
R GREGSON
D THOMPSON
D TAYLOR

Department of Ophthalmology, Great Ormond Street
Hospital NHS Trust, London WC1N 3JH

Correspondence to: Miss L F F Smith.
Accepted for publication 19 November 1997

- 1 Orcutt JC, Tucker WM, Mills RP, *et al*. Gaze evoked amaurosis. *Ophthalmology* 1987;94:213-18.
- 2 Wilkes SR, Trautman JC, DeSanto LW, *et al*. Osteoma: an unusual cause of amaurosis fugax. *Mayo Clinic Proc* 1979;54:258-60.
- 3 Wright JE. Primary optic nerve meningiomas: clinical presentation and management. *Trans Am Acad Ophthalmol Otolaryngol* 1977;83:617-25.
- 4 Manor RS, Yassur Y, Hoyt WF. Reading evoked visual dimming. *Am J Ophthalmol* 1996;12:212-14.
- 5 Knapp EP, Flaharty PM, Sergott RC, *et al*. Gaze induced amaurosis from central retinal artery compression. *Ophthalmology* 1992;99:238-40.

Retinal pigment epithelial detachment: an unusual presentation in ocular sarcoidosis

EDITOR.—Sarcoidosis is a systemic granulomatous disease of unknown aetiology that most often affects lungs, lymph nodes, liver, and the skin. Ocular involvement occurs in about a quarter of patients.^{1,2} More often it affects the anterior segment and the adnexal tissues. However, posterior segment involvement in sarcoidosis is not uncommon^{3,4} and various manifestations include vitreous inflammation, retinal periphlebitis, candlewax drippings, optic nerve, choroidal and chorioretinal granulomas. Optic disc swelling and macular oedema can also be seen. Choroidal and optic disc neovascularisation are a rare occurrence as well as optic nerve atrophy. Exudative detachments of neurosensory retina have been described in a few patients^{1,5} but to the best of our knowledge retinal pigment epithelial (RPE) detachments have never been described. We report the clinical features of a case of RPE detachment in sarcoidosis.

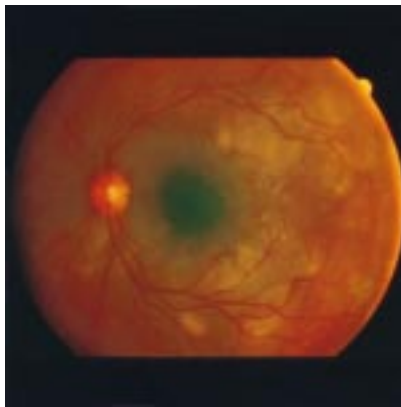


Figure 1 Fundus photograph showing small choroidal infiltrates as well as RPE detachments scattered throughout the posterior pole of the left eye.

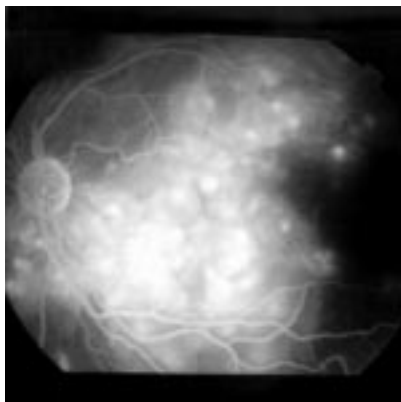


Figure 2 Late venous phase (10 minutes) of fluorescein angiogram of the same eye showing multiple hyperfluorescence areas of different sizes in the posterior pole.

CASE REPORT

A 47 year old black woman presented with sudden bilateral vision decrease. Her medical history was remarkable for histologically proved sarcoidosis that had been diagnosed 6 years previously during an episode of lupus pernio associated with pulmonary disease. This patient was treated for 3 years with hydroxychloroquine sulphate (200 mg a day) for the dermatological manifestations of the disease. The pulmonary disease was thought quiet until the occurrence of the ocular symptoms.

On examination, her best corrected visual acuity was 20/70 in the right eye and 20/30 in left eye. Slit lamp examination showed mutton fat keratic precipitates with 2+ cells and flare in both eyes. Intraocular pressure was normal in both eyes. On fundus examination, mild vitreous haze, yellowish small choroidal infiltrates, as well as RPE detachments could be seen scattered throughout the posterior pole in both eyes (Fig 1). There was no overlying sensory retinal detachment. The retinal vessels seemed to be normal. Fluorescein (Fig 2) and indocyanine green angiography showed early hypofluorescence and late hyperfluorescence corresponding to RPE detachments. There was no prior history of ocular trauma or surgery and no extraocular signs (no neurological, skin, or hair manifestations). The systemic sarcoidosis was not active at the time of ocular manifestations.

Systemic (1 g intravenous pulses of methylprednisone daily for 3 days followed by oral prednisone 1 mg/kg a day), periocular, and

topical corticosteroids were then administered. On follow up, 1 month later, visual acuity improved to 20/25 in both eyes and fluorescein angiograms showed complete disappearance of the abnormal leakage with only transmission defects due to pigment epithelial atrophy. Systemic steroids were then tapered. Two months later a recurrence of inflammation and the same fundus presentation occurred.

In spite of an initial sensitivity to systemic steroid therapy, four new relapses occurred and corticosteroid dependence at around 40 mg a day was observed. Azathioprine therapy was necessary to obtain a complete remission.

COMMENT

The aetiology of most RPE detachments occurring in young patients (under 50 years old) is unknown. These detachments are usually solitary and unilateral.⁶ RPE detachments are also commonly seen in association with inflammatory diseases such as sympathetic ophthalmia and Harada's disease. In this last disease, multiple bilateral RPE detachments associated with secondary sensory retinal detachments may occur, and extraocular signs including alopecia, vitiligo, hearing loss, and encephalitis are often noted. RPE detachments may be associated with systemic corticotherapy.⁶

To the best of our knowledge, RPE detachments have never been associated with sarcoidosis.

In this case, there was no concurrent diagnosis other than sarcoidosis that could account for RPE detachments. Indeed, this patient had no other sign for Vogt-Koyanagi-Harada syndrome or sympathetic ophthalmia and no prior steroid therapy. The appearance of RPE detachments was concomitant with the onset of a typical anterior granulomatous uveitis and the lesions were dramatically improved by steroid therapy. These facts as well as the dependence on steroid therapy strongly suggest that RPE detachments and the choroidal infiltrates are inflammatory in nature. We can hypothesise that choriocapillary inflammation is a possible patho-aetiology of these manifestations as it can be seen in other inflammatory diseases.

In conclusion, RPE detachments were identified in one patient with biopsy proved sarcoidosis and could be considered as a rare manifestation of ocular sarcoidosis.

T BOURCIER
L LUMBROSO
N CASSOUX
C FARDEAU
P LEHOANG

Ophthalmology Department, Pitié-Salpêtrière Hospital,
Paris, France, 47-83, boulevard de l'Hôpital, Paris
Cedex 13, France

Correspondence to: Professor P Lehoang.
Accepted for publication 5 November 1997

- 1 Jabs DA, Johns CJ. Ocular involvement in chronic sarcoidosis. *Am J Ophthalmol* 1986;102:297-301.
- 2 Siltzbach LE, James DG, Neville E, *et al*. Course and prognosis of sarcoidosis around the world. *Am J Med* 1974;57:847-52.
- 3 Chumbley LC, Kearns TP. Retinopathy of sarcoidosis. *Am J Ophthalmol* 1972;73:123-31.
- 4 Spalton DJ, Sanders MD. Fundus changes in histologically confirmed sarcoidosis. *Br J Ophthalmol* 1981;65:348-58.
- 5 Marcus DF, Bovino JA, Burton TC. Sarcoid granuloma of the choroid. *Ophthalmology* 1982;89:1326-30.
- 6 Schatz H, Burton TC, Yannuzzi LA, *et al*. In: *Interpretation of fluorescein angiography*. St Louis: CV Mosby, 1978:666-96.

Keratoacanthoma of the bulbar conjunctiva

EDITOR.—Keratoacanthoma is a relatively common benign tumour of exposed areas of skin and occurs predominantly in the white-skinned races.¹ In contrast, keratoacanthoma of the conjunctiva occurs rarely.²⁻⁴ Reported here is the fourth case of conjunctival keratoacanthoma and the first to be reported in a black patient.

CASE REPORT

A 37 year old Ethiopian civil engineer, resident in Germany for 10 years, presented with foreign body symptoms in the conjunctiva of the left eye to his ophthalmologist 2 weeks after grinding metal at work. A small white elevated lesion was observed at the limbus and the patient was referred to our hospital with the diagnosis of conjunctival foreign body granuloma. On examination, a white nodular mobile tumour with a centrally hyperkeratotic area, approximately 5 × 4 × 4 mm in size, was apparent at the nasal limbus in the left eye and was surrounded by moderate conjunctival injection (Fig 1). The remaining ophthalmological and systemic examination proved unremarkable; in particular, he was HIV negative. Radiological investigations excluded intraocular radio-opaque foreign material.

The limbal lesion was excised under retrobulbar anaesthesia; it was not adherent to the underlying sclera or adjacent cornea. The excised specimen, placed immediately in 10% formalin, was processed through paraffin for conventional histological examination (haematoxylin and eosin, periodic acid Schiff, and Prussian blue for iron). Additional immunohistochemical investigations were performed using the primary monoclonal antibodies MIB-1 (antigen Ki-67), pan-cytokeratin marker, MNF-116, p53 (clone DO7), and one directed against human papillomavirus (HPV) capsid antigen types 6, 11, 16, and 18.

Histological examination showed a central crater-like acanthotic epithelium surrounded

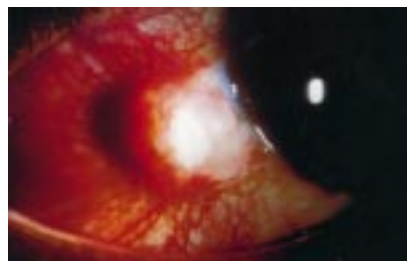


Figure 1 Clinical photograph of the mobile conjunctival mass with a centrally hyperkeratotic area.

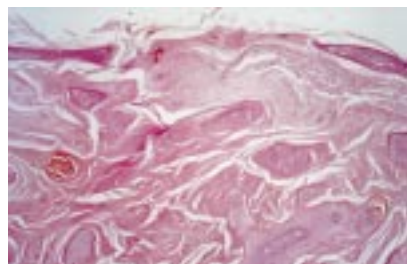


Figure 2 Low power of the histological section of the lesion illustrating a central crater-like area of metaplastic keratinising squamous epithelium with reduced number of goblet cells (haematoxylin and eosin, × 10).

by a collarette of metaplastic but well differentiated squamous epithelium (Fig 2), positive for MNF-116. The surrounding epithelium contained cohesive rounded squamous "eddy" with an intact epithelial basal membrane. Normal conjunctival epithelium was observed at the resection edges. The conjunctival stroma demonstrated marked elastotic degeneration and a moderate diffuse chronic inflammatory infiltrate. Birefringent material or a siderosis was not identified. Immunohistochemical investigations demonstrated a restricted basal cell proliferation (MIB-1) and positivity for p53. All stains for HPV were negative. The lesion had been completely removed.

Follow up of the patient at 24 months after excision did not reveal any recurrence of the lesion.

COMMENT

The first case of conjunctival keratoacanthoma was described by Freeman *et al*² and two further definite cases have been reported in the literature.^{3,4} The present case is unusual in that it occurred in a black patient; all previously reported cases of conjunctival keratoacanthoma occurred in white patients.²⁻⁴

The appearance of keratoacanthoma is that of a nodule with rounded edges and a central keratin filled crater in its mature form approximately 1–2 cm in diameter in size.¹ Cutaneous keratoacanthomas are characterised by an initial period of rapid growth (4–8 weeks) followed by spontaneous regression, usually complete within 6 months. A similar behaviour has been described in conjunctival lesions with presenting symptoms including a sudden onset of conjunctival injection or irritation or a rapidly enlarging mass. Our patient's association of a foreign body sensation following metal grinding in this case proved to be coincidental. The natural course of conjunctival keratoacanthoma is unknown owing to their early excision.²⁻⁴ The histological criteria for the diagnosis of keratoacanthoma are characteristic with the keratin filled crater and overhanging edges of squamous epithelium, surrounded by an acanthotic epithelium with cohesive rounded epithelial whorls and an intact basal cell layer. The surrounding dermis or conjunctival stroma may demonstrate sun exposure related elastotic degeneration in older patients.

The main differential diagnosis of keratoacanthoma is squamous cell carcinoma which develops more slowly than keratoacanthoma, is less well demarcated, and is not usually characterised by the central keratin filled crater. Histologically, squamous cell carcinoma is characterised by disruption of the epithelial basal membrane, deeper stromal growth, marked epithelial dysplasia, abnormal mitotic figures, extensive desmoplastic reaction, and blood or lymphatic vessel invasion.

Immunohistochemically, cell proliferation and positivity for p53 is no longer restricted to the basal layer. These morphological and immunohistochemical features were not observed in the present case. Where an association between conjunctival neoplasia and HPV has been reported,⁵ this has yet to be demonstrated in keratoacanthoma at any site. Grossniklaus *et al* reported cases of conjunctival keratoacanthoma with invasive features.⁶ Although it remains controversial whether squamous cell carcinoma can arise from keratoacanthoma, it is more likely that such tumours are well differentiated squamous cell carcinoma mimicking closely the histological features of keratoacanthoma.¹ Such cases

underline the importance of close follow up of all patients with diagnosed conjunctival keratoacanthoma.

SARAH E COUPLAND

Department of Pathology, Universitätsklinikum Benjamin Franklin, Freie Universität, Berlin, Germany

HEINRICH HEIMANN

ULRICH KELLNER

NORBERT BORNFIELD

MICHAEL H FOERSTER

Department of Ophthalmology, Universitätsklinikum Benjamin Franklin, Freie Universität, Berlin, Germany

WILLIAM R LEE

Department of Pathology, Western Infirmary, University of Glasgow, Scotland

Correspondence to: Dr Coupland.

Accepted for publication 27 November 1997

- 1 McKee PH. In: *Pathology of the skin*. 2nd ed. London: Mosby Wolfe, 1996;14:28–31.
- 2 Freeman RG, Cloud TM, Knox JM. Keratoacanthoma of the conjunctiva. A case report. *Arch Ophthalmol* 1961;65:817–9.
- 3 Bellamy ED, Allen JH, Hart NL. Keratoacanthoma of the bulbar conjunctiva. *Arch Ophthalmol* 1963;70:512–4.
- 4 Roth AM. Solitary keratoacanthoma of the conjunctiva. *Am J Ophthalmol* 1978;85:647–50.
- 5 McDonnell JM, McDonnell PJ, Mounts P, *et al*. Demonstration of papillomavirus capsid antigen in human conjunctival neoplasia. *Arch Ophthalmol* 1986;104:1801–5.
- 6 Grossniklaus HE, Wojno TH, Yanoff M, *et al*. Invasive keratoacanthoma of the eyelid and ocular adnexa. *Ophthalmology* 1996;103:937.

Magnetic resonance image changes following optic nerve trauma from peribulbar anaesthetic

EDITOR.—In this case a grand mal seizure occurred after a short peribulbar anaesthetic needle was used, permanent visual loss resulted, and magnetic resonance imaging (MRI) confirmed optic nerve damage.

CASE REPORT

A 49 year old myopic woman was diagnosed as having normal tension glaucoma. A year previously she underwent uncomplicated right trabeculectomy with 5-fluorouracil under local anaesthetic, and surgery to the left eye was planned. Her medication included levobunolol HCl 0.5% twice daily to the left eye, and atenolol for hypertension.

Before left trabeculectomy, with 5-fluorouracil, corrected vision was 6/9 right eye, and 6/5 left. Intraocular pressures were 12 mm Hg and 20 mm Hg respectively.

A painless peribulbar anaesthetic of prilocaine 4% was administered with a 25 mm 27 gauge needle. One injection of 3 ml was given inferotemporally and a second injection of 2.5 ml at the medial canthus.

The eye remained in the primary position throughout. Light ocular compression was applied and after 10 minutes she was prepared for surgery. She then felt cold and started to shiver, and after 5 minutes developed a grand mal fit. Her vital signs remained stable and oxygen and diazepam were administered. The convulsion lasted 90 seconds and by 20 minutes she had recovered, was fully lucid, and surgery proceeded uneventfully.

The following day corrected vision in the left eye was reduced to hand movements. A bleb was formed, the anterior chamber was deep and the intraocular pressure measured 4 mm Hg. There was a dense afferent pupillary defect and fundal examination revealed cupping of the optic disc as preoperatively.

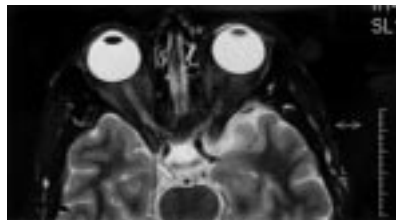


Figure 1 Magnetic resonance image demonstrated swelling of the left optic nerve over a distance of 8 mm immediately behind the globe.

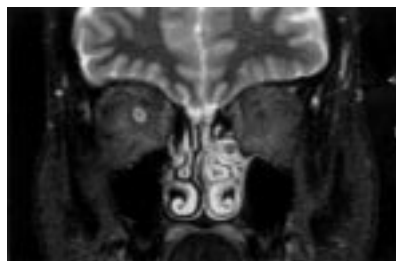

Figure 2 Magnetic resonance image showing the surrounding optic nerve sheath effaced.

An unenhanced computed tomograph scan performed a week later showed no abnormality of the orbits or optic nerves. An MRI was performed at 4 weeks. T1 and T2 weighted, fat suppressed 4.0 mm images were performed axially at 0.4 mm intervals through the orbits. The images demonstrated swelling of the left optic nerve over a distance of 8 mm immediately behind the globe (Fig 1). The surrounding optic nerve sheath was effaced (Fig 2), and the nerve returned an abnormally low signal on T2 weighted images. No other abnormalities were detected.

Six weeks after the operation she underwent intravenous pulsed methylprednisolone 1 g a day for 3 days; however, there was no improvement in visual acuity. Her intraocular pressures remain less than 12 mm Hg.

A follow up MRI scan at 6 months demonstrated complete resolution of the optic nerve swelling and restoration of the nerve sheath with the development of optic atrophy particularly in the portion of the optic nerve behind the globe. A gradient echo sequence confirmed the absence of any optic nerve haemorrhage.

COMMENT

Peribulbar anaesthesia has been advocated as a safer technique than retrobulbar anaesthesia as the risk of optic nerve damage is significantly less.¹ Injection of anaesthetic in the optic nerve sheath can cause brainstem anaesthesia and is well described with retrobulbar blockade.²⁻⁵ The risk of brainstem anaesthesia increases with the length of needle used, and if the eye is in the Atkinson position.^{1,2,5} Even with planned peribulbar block it has been estimated that an intracanal anaesthetic has been given in 1.3% of cases.¹

Direct trauma to the optic nerve can occur after orbital block, characteristically without associated brainstem anaesthesia.^{6,7} The visual loss may be associated with signs of a retinal artery occlusion,⁸ subhyaloid haemorrhage,⁷ or a retinal vein occlusion.⁹ In some of these cases the optic nerve sheath swelling was confirmed by ultrasonography or CT, and intraneural sheath haemorrhage was treated in

one case by optic nerve sheath decompression with limited visual improvement.⁹

Prilocaine (Citanest) was used as the anaesthetic agent; it is similar to lignocaine, and has the advantage of being 50% less toxic, with reduced local irritation and slower systemic absorption.¹⁰ Contraindications include anaemia and at high concentrations it can cause methaemoglobinemia.

In this case we suggest that some prilocaine was injected into the nerve sheath causing a grand mal fit, with loss of the cerebrospinal fluid space and local optic nerve swelling. The latter may be due to direct injection into the optic nerve or an associated ischaemic swelling.

This complication occurred, despite using a 25 mm needle with the eye in the primary position, and when the anaesthetic was administered by an experienced anaesthetist (more than 8000 orbital blocks).

The MRI images were able to demonstrate the subtle changes in the optic nerve and sheath that were undetected by the CT scans. Our experience was that it provided superior detail, and the gradient echo sequence would demonstrate if haemorrhage was present.

Earlier corticosteroid treatment would be advised, although it is not known whether the initial optic nerve swelling was reversible. Unfortunately treatment was given 6 weeks after the event and was of no benefit.

To our knowledge there are no published reports of optic nerve changes of this type following brainstem anaesthesia.⁹

S E DOREY
I H GILLESPIE

Department of Ophthalmology, The Royal Eye Unit,
Kingston Hospital,

F BARTON

Anaesthetic Department, The Royal Eye Unit, Kingston
Hospital,

E MACSWEENEY

Department of Neuroradiology, Atkinson Morley
Hospital, Wimbledon

Correspondence to: Miss S E Dorey, Moorfields Eye
Hospital, City Rd, London EC1V 2PD.

Accepted for publication 27 November 1997

- 1 Davis DB, Mandel MR. Efficacy and complication rate of 16,224 consecutive peribulbar blocks. *J Cataract Refract Surg* 1994;20:327-37.
- 2 Liu C, Youl B, Moseley I. Magnetic resonance imaging of the optic nerve in extremes of gaze. Implications for the positioning of the globe for retrobulbar anaesthesia. *Br J Ophthalmol* 1992; 76:728-33.
- 3 Meyer EF, Ramirez RC, Boniuk I. Grand mal seizures after retrobulbar block. *Arch Ophthalmol* 1978;96:847-9.
- 4 Hamilton RC. Brainstem anaesthesia following retrobulbar blockade. *Anaesthesiology* 1985;63: 688-90.
- 5 Hamilton RC. Brainstem anaesthesia as a complication of regional anaesthesia for ophthalmic surgery. *Can J Ophthalmol* 1992;27: 323-5.
- 6 Smith GB, Hamilton RC, Carr CA. Complications of orbital regional anaesthesia. *Ophthalmic anaesthesia*. 2nd ed. London: Arnold, 1996.
- 7 Pautler SE, Grizzard WS, Thompson LN, et al. Blindness from retrobulbar injection into the optic nerve. *Ophthalmic Surg* 1986;17:334-7.
- 8 Hersch M, Baer G, Dieckert JP, et al. Optic nerve enlargement and central retinal artery occlusion secondary to retrobulbar anaesthesia. *Ann Ophthalmol* 1989;21:195-7.
- 9 Sullivan KL, Brown GC, Forman AR, et al. Retrobulbar anaesthesia and retinal vascular obstruction. *Ophthalmology* 1983;90:373-7.
- 10 Henderson TRM, Franks W. Peribulbar anaesthesia for cataract surgery; prilocaine versus lignocaine and bupivacaine. *Eye* 1996;10:497-500.

Anterior uveitis associated with cat scratch disease

EDITOR.—Cat scratch disease (CSD) is a relatively common and self limited infection causing fever and lymphadenopathy mainly in children and adolescents.¹ Previously reported ocular complications of CSD include Parinaud's oculoglandular conjunctivitis,² papillitis,³ neuroretinitis,⁴ peripapillary angiomatosis,⁵ and serous neurosensory retinal detachment.⁶ We present a case of CSD associated with anterior uveitis, a scenario previously unreported.

CASE REPORT

A 51 year old man presented to us with a 2 week history of a painful, red left eye associated with a reduction in vision. He gave a clear account of being scratched by his kitten, over the left eyebrow 3 weeks earlier. The ensuing fever, rigors, and submandibular lymphadenopathy had led his general practitioners to prescribe a course of oral clarithromycin for presumed CSD. Our patient developed pain and redness of a moderate degree in his left eye during a conference in Denmark 1 week after the scratch. He was seen by a local ophthalmologist who made a diagnosis of Parinaud's oculoglandular conjunctivitis and prescribed tetracycline four times daily to the affected left eye. His symptoms, however, failed to improve on this treatment.

When seen by us he had a 4 cm by 1 cm ulcerating papular skin lesion just above the medial aspect of the left eyebrow, extending onto the lateral aspect of the upper nose (Fig 1). There was a solitary non-tender submandibular lymph node on the left side.

Best corrected visual acuity was right eye 6/4-1, left eye 6/9. Slit lamp examination revealed mild circumcorneal injection, large non-pigmented keratic precipitates (Fig 2),

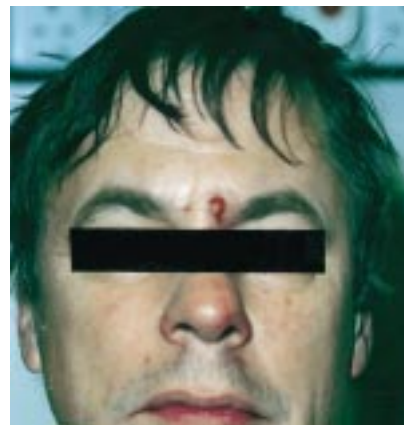

Figure 1 Note the large ulcerating papular skin lesion medial and superior to the left eyebrow. Appearance at first presentation to us 3 weeks after the cat scratch.

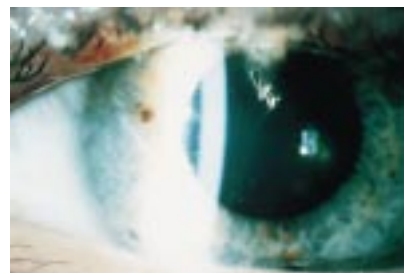


Figure 2 Non-pigmented keratic precipitates mainly in the lower cornea. At initial presentation.

and anterior chamber cells +2 and flare +2. The intraocular pressure was normal and the vitreous showed no inflammatory activity. There were no fundal abnormalities. The fellow eye was normal. He was treated with betamethasone 0.1% 2 hourly and cyclopentolate 1% twice daily. Over the following 3 weeks his anterior uveitis resolved, visual acuity improved to left eye 6/5-1, and the ulcerated skin lesion healed.

Immunofluorescent antibody studies at 3 weeks from the cat scratch demonstrated a positive (1/16) titre for *Bartonella henselae* confirming the clinical diagnosis of cat scratch disease. For this test, antigen was derived from *Bartonella henselae* grown in Vero cells, and a whole antibody test was used. We felt it unnecessary to obtain a tissue diagnosis by histopathology. He was HLA B27 positive with a sacroiliac radiograph reported as normal. Further investigations revealed no deviation from normal in blood count, angiotensin converting enzyme level, and chest radiograph. The autoantibody screen proved negative.

COMMENT

To our knowledge this is the first case of anterior uveitis occurring in association with CSD. Our patient had completed a 2 week course of oral clarithromycin. Although this drug is not widely reported to be the first line treatment for CSD, our patient did not exhibit signs of systemic infection on presentation to us and the uveitis was successfully treated with topical steroids and mydriatic. This case is unusual with respect to the location of the inoculation site. Previously reported cases of ocular involvement in cat scratch disease have had an inoculation site either on the conjunctiva or the eyelids² whereas in this case the inoculation site was not directly on ocular structures. The anterior uveitis could be coincidental but the short time interval between the cat scratch and development of the anterior uveitis tend to support a causal relation between CSD and anterior uveitis in this case. Another possibility is that the uveitis occurred as a side effect of clarithromycin or tetracycline; however, uveitis is not a reported side effect of either of these two drugs. A number of Gram negative bacteria have been implicated in the pathogenesis of HLA B27 related anterior uveitis including *Klebsiella* sp, *Salmonella* sp, and *Yersinia enterocolitica*.⁷ *Bartonella henselae* is a Gram negative pleomorphic bacillus which may have the ability to cause such a reaction in patients with the HLA B27 antigen and is thus deserving of further attention.

SHAFIQ UR REHMAN
TIMOTHY W METCALFE
Department of Ophthalmology, Harrogate District
Hospital, Lancaster Park Road, Harrogate HG2 7SX

MIKE BARNHAM

Department of Microbiology, Harrogate District
Hospital, Lancaster Park Road, Harrogate HG2 7SX

Correspondence to: Mr T W Metcalfe.

Accepted for publication 27 November 1997

- Hunt L. Ocular cat scratch disease. *Insight* 1995;20:28-9.
- Hugh A, Carithers MD. Oculoglandular disease of Parinaud. *Am J Dis Child* 1978;132:1195-200.
- Golnik KC, Marotto ME, Fanous MM, et al. Ophthalmic manifestations of Rochalimea species. *Am J Ophthalmol* 1994;118:145-51.
- Bar S, Segal M, Shapira R, et al. Neuroretinitis associated with cat scratch disease (letter). *Am J Ophthalmol* 1990;110:703-5.
- Fish RH, Hogan RN, Nightingale SD, et al. Peripapillary angiomas associated with cat scratch neuroretinitis. *Arch Ophthalmol* 1992;110:323.
- Zacchei AC, Newman NJ, Sternberg P. Serous retinal detachment of the macula associated with cat scratch disease. *Am J Ophthalmol* 1995;120:796-7.
- Wakefield D, Montanaro A, McCluskey P. Acute anterior uveitis and HLA B27. *Surv Ophthalmol* 1991;36:223-32.

Anaphylactic shock after a single oral intake of acetazolamide

EDITOR.—We encountered a case of serious anaphylactic shock caused by a single oral intake of acetazolamide, a frequent used medication by several medical specialties especially in ophthalmology.

CASE REPORT

A 70 year old man was admitted to our emergency department presenting symptoms and signs of shock. The patient had successfully undergone surgery for cataract under local anaesthesia. Five hours after the end of the operation a tablet of acetazolamide 250 mg was given in order to control his postoperative intraocular pressure. Half an hour later he complained of nausea, became cyanotic, and suffered acute respiratory failure. At the initial evaluation the following findings were noted: systolic pressure 70 mm Hg, heart rate 180/min, tachypnoea (40 breaths per minute), temperature 36.7°C. On chest auscultation diminished alveolar murmur and a prolonged expiration were found. Arterial blood gases when breathing room air were P_{aO_2} : 6.34 kPa (47 mm Hg), P_{aCO_2} : 4.99 (kPa) (37 mm Hg), pH 7.31, HCO_3^- 7.9 mEq/l.

Negative perfusion lung images ruled out pulmonary embolus. Right side heart catheterisation excluded a high pressure pulmonary oedema while two dimensional echocardiography was negative. Ventilatory support was initiated by using positive pressure assisted ventilation through a nasal mask in combination with 35% oxygen administration. He was given vasopressors, and noradrenaline 0.05 µg/kg/min to 0.1 µg/kg/min.

His systolic pressure started to rise half an hour later. Intravenous hydrocortisone and diphenhydramine were given for presumed anaphylaxis. Clinical improvement was seen 12 hours later and the ventilatory and haemodynamic support were discontinued. After the patient was clinically stabilised a skin test to a sulphonamide solution was performed. A positive skin reaction confirmed that he had a sulphonamide hypersensitivity. The patient experienced a full recovery and was discharged 3 days later.

COMMENT

Serious anaphylactic reactions to carbonic anhydrase inhibitors such as acetazolamide are infrequent. Although there have been reports of adverse effects of acetazolamide. There is only one previous report of anaphylactic shock caused by the oral intake of acetazolamide.¹ Our patient had not been treated with acetazolamide previously but he had a hypersensitivity to sulphonamides. Acetazolamide is a sulphonamide derivative and, like other sulphonamides, may cause bone marrow depression, skin toxicity,² and allergic reactions in patients hypersensitive to sulphonamides.^{1,2} The anaphylactic reaction in our patient could have been related to sulphonamide hypersensitivity caused by a cross sensitivity with other drugs in the same family such as carbonic anhydrase.

In conclusion, clinicians and ophthalmologists should be aware if any sign of anaphylactic shock are experienced in patients who take acetazolamide orally. We also suggest the careful monitoring of patients who have history of allergic reactions to sulphonamides or to other drugs during the oral administration of the first dose of acetazolamide.

N TZANAKIS
G METZIDAKI

Department of Thoracic Medicine, School University of
Crete, Greece

K THERMOS
CH SPYRAKI

Department of Pharmacology, Medical School
University of Crete, Greece

D BOUROS

Department of Thoracic Medicine, School University of
Crete, Greece

Correspondence to: Dr N Tzanakis, Department of
Thoracic Medicine, University Hospital of Heraklion,
PO Box 1352, 71110 Heraklion, Crete, Greece.
Accepted for publication 9 December 1997

1 Peralta J, Abelairas J, Fernandez-Guardiola J. Anaphylactic shock and death after oral intake of acetazolamide (letter). *Am J Ophthalmol* 1992;114:367.

2 Lanctot KL, Ghajar BM, Shear NH, et al. Improving the diagnosis of hypersensitivity reactions associated with sulfonamides. *J Clin Pharmacol* 1994;34:1228-33.