

## LETTERS TO THE EDITOR

**Ocular signs associated with a rhodopsin mutation (Cys-167→Arg) in a family with autosomal dominant retinitis pigmentosa**

EDITOR,—Retinitis pigmentosa (RP) comprises a group of hereditary progressive retinal degenerative conditions characterised by typical fundus alterations, loss in visual field, and severely reduced or unrecordable electroretinograms (ERG). The first reported disease related mutations in the human rhodopsin gene, described in 1990 by Dryja *et al.*,<sup>1</sup> was a heterozygous C→A transversion in the second nucleotide of codon 23. Since then many further mutations have been identified to a current total of about 90.<sup>2</sup>

Here we describe, for the first time in the literature, the clinical phenotype associated with a Cys-167→Arg mutation (TGC→CGC in exon 2) in an Italian family affected by autosomal dominant retinitis pigmentosa (ADRP). The same mutation was noted by Dryja *et al.*,<sup>3</sup> but there has been no report of correlated clinical data.

**CASE REPORT**

Four patients (see Fig 1) of a family from the Campania region of southern Italy, have been studied.

**Patient II-1**

The patient, a 45 year old woman, had central visual acuity 20/50 in both eyes with  $-3 -3 \times 180^\circ$  in right eye and  $-4 -2.50 \times 180^\circ$  in left. Nascent posterior subcapsular cataract and vitreous corpuscles were present. Fundus examination revealed waxy optic disc pallor, attenuated retinal vessels, atrophic retinal pigment epithelium (RPE), and bone spicules in the middle periphery on  $360^\circ$  (Fig 2). Goldmann kinetic visual field examination showed a concentric isoptere shrinkage up to  $10^\circ$  in the centre in each eye (I,4 and II,4). No peripheral vision island was observed. Goldmann-Weekers adaptometry showed a high depression of the photopic and scotopic curve in both eyes. Electroretinography showed no photopic and scotopic curve. Acromatopsia was found in the colour test.

**Patient III-1**

This patient, a 11 year old male had central visual acuity 20/25 in both eyes with  $+1 -3 \times$

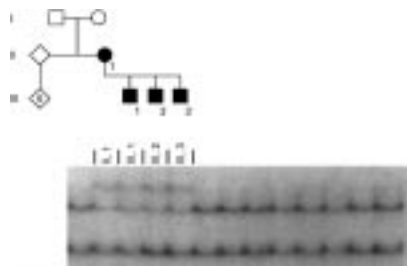


Figure 1 SSCP analysis and pedigree of the family. To detect point mutations, the entire rhodopsin coding sequence, including the five exons and their exon-intron junctions, was amplified using a "multiplex-PCR".<sup>3</sup> Shaded symbols represent those affected.

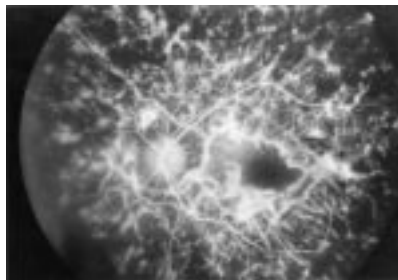


Figure 2 Fluorescein angiogram of patient II-1.

$180^\circ$  in the right and left eye. Fundus examination showed a rose coloured optic disc, attenuated retinal vessels, an atrophic RPE area over  $360^\circ$ , and a very rare osteoblast pigment cluster in the peripheral. The Goldmann visual field examination using I and 4, II and 4 mires showed mild concentric shrinkage of the peripheral isoptres. Goldmann-Weekers adaptometry showed a mild depression of the scotopic and photopic curve in both eyes. ERG gave microvoltage photopic graphs with implicit wave periodicity of 40.60 ms and implicit b wave periodicity of 58 ms; the differential width was  $3.921 \mu\text{V}$ . The scotopic ERG was extinguished in both eyes. The colour test was normal.

**Patient III-2**

This patient, a 8 year old male showed a corrected visus 20/25 in both eyes with  $+1.50 \times 100^\circ$  in the right and left eye. The fundus, Goldmann visual field and the Goldmann-Weekers adaptometry examination are similar to the patient III-1. ERG showed a microvoltage photopic graph with implicit time of the a wave equal to 32 ms and implicit time of the b wave equal to 52.20 ms, with a differential width of  $10.75 \mu\text{V}$ . The scotopic graph was extinguished.

**Patient III-3**

This male patient was first examined at 16 months. Fundus examination showed atrophic RPE changes and bone spicules in mild periphery. At age 7, he was re-examined and found to have a corrected visus of 20/25 in both eyes with  $+1$ . Goldmann visual field examination showed a marked reduction in retinal sensitivity in both eyes, especially in the nasal sectors. ERG showed a microvoltage photopic graph with an implicit wave time of 32.40 ms and an implicit b wave time of 53.70 ms, with a differential width of  $14.7 \mu\text{V}$ . The scotopic graph was extinguished.

**COMMENT**

This study has correlated a mutation Cys-167→Arg of the rhodopsin gene with phenotypic type I in an Italian family. The mutation segregated with the clinical disease, and all affected patients showed a similar phenotype. The disease has a very early onset: in the youngest subject the diagnosis was made at 16 months of age. The first symptoms in all subjects were night blindness and visual field shrinkage (restricted side vision). Examination of the fundus of the eye identified a typical RP form, with vessel narrowing and

osteoblast-like pigmentation in the middle retinal peripheral area in four sectors.

Atrophic changes of the RPE in the macular region and in the middle periphery were identified only in the patient II-1. Electroretinography showed an early alteration of rod function, whereas cone function was not completely compromised until almost age 18. Clinical examination repeated yearly for up to 7 years in three subjects indicated that the disease progresses very slowly.

Furthermore, the exact mechanism involved in affecting the visual cycle is difficult to imagine. Cysteine at position 167 of the rhodopsin gene is highly conserved during the evolution of mammals, but its relation to early death of visual cells is unknown. Also, only rods express the rhodopsin gene, and the cones use different photopigments, so that it remains mysterious that both cones and rods are affected in RP. In many cases of retinal degeneration cells undergo apoptotic death; but it is not known whether apoptosis is involved in all the forms of induced or degenerative photoreceptor death.<sup>4</sup> Such mechanisms are just coming under scrutiny.

The authors would like to thank the family for its contribution to these studies. The authors were also grateful to Professor G Imbucci, of ORAO association; A Terracciano for technical assistance, and to Servizio di Tecnologie Biomolecolari, Area di Ricerca CNR Naples, where the sequences were performed. This work was supported by Telethon-Italy, grant no E546 to AC and CNR grant no CTB.94.2863 to ER; MGM is a Telethon-Italy fellow.

FRANCESCA SIMONELLI  
MARIO RINALDI  
ANNA NESTI  
FRANCESCO TESTA  
ERNESTO RINALDI  
*Eye Clinic, Second University of Naples*

ALFREDO CICCOCICOLA  
LUISA FLAGIELLO  
MARIA GIUSEPPINA MIANO  
VALERIO VENTRUTO  
MICHELE D'URSO  
*International Institute of Genetics and Biophysics,  
CNR, Naples, Italy*

Correspondence to: Professor Ernesto Rinaldi, Eye Clinic, Second University of Naples, Via Pansini, 5-80131 Naples, Italy.

Accepted for publication 21 January 1998

- 1 Dryja TP, McGee TL, Reichel E, *et al.* A point mutation of the rhodopsin gene in one form of retinitis pigmentosa. *Nature* 1990;343:364-6.
- 2 Gal A, Apfelstedt-Sylla E, Janecke AR, *et al.* Rhodopsin mutation in inherited retinal dystrophies and dysfunction. *Prog Retinal Eye Res* 1997;16:51-79.
- 3 Dryja TP, Hahn LB, Cowley GS, *et al.* Mutation spectrum of rhodopsin gene among patients with autosomal dominant retinitis pigmentosa. *Proc Natl Acad Sci USA* 1991;88:9370-4.
- 4 Papermaster DS, Windle J. Apoptosis inherited retinal degeneration. *Invest Ophthalmol Vis Sci* 1995;36:977-83.

**Haemangioma of the breast, metastatic to the ciliary body and iris**

EDITOR,—Angiomatous tumours of the ciliary body and iris are very rare. Even metastatic foci of angiosarcomas are not seen often in this location.<sup>1</sup> This is why we are publishing our case of disseminated haemangioma

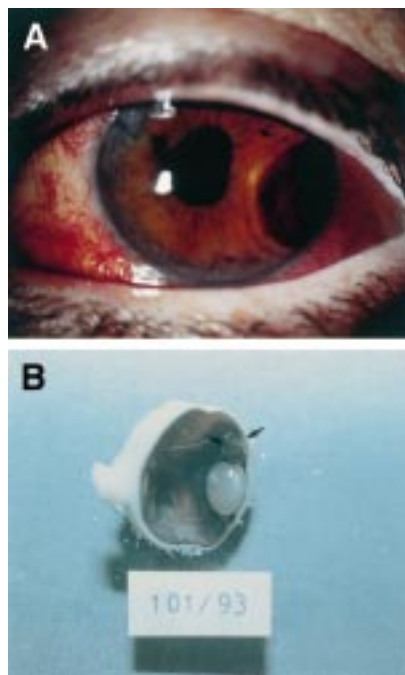
with metastatic involvement of the ciliary body and the iris. The eye maintained useful function until the patient's death 1 year after the appearance of the focus in the eye.

#### CASE REPORT

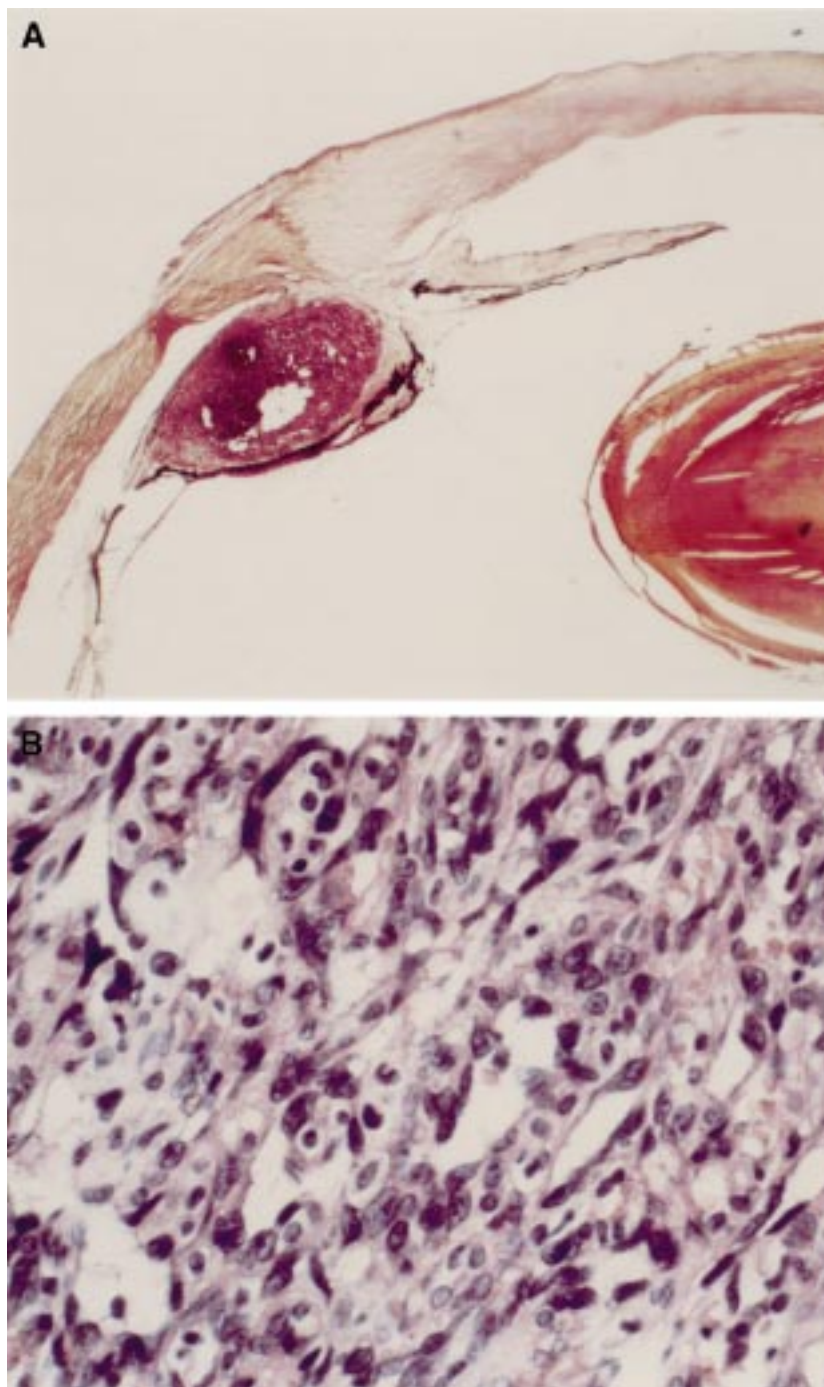
##### *Clinical observation*

A 53 years old woman was admitted to our eye clinic for deterioration of vision in her left eye and headaches. A tumorous focus involving the ciliary body and the radical part of the iris was revealed both clinically by ultrasound and with magnetic resonance imaging (MRI). The tumour had grown laterally at the 3 o'clock position (see Fig 1A and appeared to have a solid structure. The diameter of its base was about 6 mm. The vision was 6/12 when the patient was first examined but quickly deteriorated to light perception only, because of the blood in the anterior chamber. After removal of the blood from the anterior chamber, the vision improved again to 6/12. The intraocular pressure was normal (18–20 mm Hg) at all times.

Haemangiosarcoma of the right breast treated by ablation and actinotherapy was noticed in the patient's medical history. The original tumour had grown within the breast stroma. Its diameter was about 3–4 cm. The histological pattern varied from relatively well formed vascular channels surrounded by multilayering endothelium to poorly differentiated solid areas formed by poorly differentiated cells with frequent mitoses. Epithelioid differentiation was not noticed. Some areas were haemorrhagic. There were no risk factors for angiosarcoma such as previous radiotherapy<sup>2</sup> in the patient's history. The patient was HIV negative. Because of tumorous dissemination in the skin and brain, ocular surgery was abandoned. Removal of blood from the anterior chamber was necessary once more before the patient's death, 1 year



**Figure 1** (A) Patient's left eye at the time of diagnosis of the intraocular tumorous focus. (B) The same eye removed after the patient's death before postmortem histological processing. The arrows indicate half rounded tumorous focus within the ciliary body. Note the difference in the size of tumorous focus.



**Figure 2** (A) Histological section from the same eye in the low power magnification. Note the haemorrhage and the artificial cavity after another haemorrhage within the tumour. Anterior synechiae closing the chamber angle in the region around the tumorous focus are also visible. Haematoxylin and eosin staining, magnification  $\times 12.5$ . (B) The same specimen as in (A), tumorous infiltrate under high power magnification. Note the tendency to form blood vessel spaces and cellular atypias. Haematoxylin and eosin staining, magnification  $\times 500$ .

later; otherwise, chemotherapy remained the only suitable treatment. However, the intraocular focus stopped its macroscopical growth and even partly regressed after chemotherapy by cyclophosphamide and vincristine (compare Fig 1A and B). The eye maintained useful function with measurable vision for 1 year until the patient's death due to haemorrhage from metastasis in the brain at the end of July 1993. Postmortem examination of the left eye confirmed histologically the haemangiosarcomatous origin of the intraocular focus.

#### *Histopathology*

##### *Gross examination of the eyeball*

The enucleated left eyeball measured  $23 \times 23 \times 22$  mm with 4 mm of optic nerve. The pupil was slightly oval owing to lateral pressure on the nasal side. Transillumination and opening of the globe revealed approximately half rounded infiltrate which involved the lateral part of the ciliary body (see Figs 1B and 2A). The centre of this infiltrate was at the 3 o'clock position, its vertical diameter was 5 mm and horizontal diameter was 3.5 mm. The aqueous and vitreous were clear. The



anterior chamber was shallow but still maintained. The retina was attached and the other parts of the globe were without remarkable macroscopically apparent changes.

### Histology

The tumorous focus seen in the figures is apparently of an angiomatous nature, and involves only the ciliary body (see Fig 2A and B). Cellular atypias, mitoses, and several haemorrhages are observable within the tumour (see Fig 2A and B). No clearly tumorous structures are present in the radical part of the iris (1 year before death there was a clinically observed and documented expansion of the tumour (see Fig 1A). There is no major growth of tumorous tissue from the focus within the ciliary body to the other surrounding structures of the eye. There is angle closure in the region of the tumour as a result of larger anterior synechiae (see Fig 2A). However, the angle of the anterior chamber remains narrow but without closure for the major part of the circumference of the anterior chamber. The other parts of the globe are without remarkable changes. Immunohistochemical positivity for factor VIII related antigen was later revealed in both primary tumour and ocular and skin metastases (particularly in the relatively more vasoformative areas), confirming the vascular nature of tumour.<sup>3,4</sup>

### COMMENT

Angiomatous tumours of the iris and ciliary body, both primary and secondary foci, are reported generally as very rare. Even in the breast angiosarcoma is a relatively rare tumour.<sup>5,6</sup> After histological examination, the angiosarcomatous nature of the described tumorous focus was confirmed. The rarity of this type of intraocular tumorous metastatic focus makes this case remarkable. The secondary intraocular foci of various carcinomas are reported more often.<sup>1</sup> Some rules observed in cases of intraocular metastatic cancer are common with other histological types of malignancies. Metastatic foci in the anterior segment of the eye are reported as much more rare than in the posterior segment.<sup>1,7</sup> On the other hand, the breast (our case) and the lung are the most frequent primary sites of the intraocular metastases.<sup>1</sup> Median survival time of patients with metastasis to the anterior segment is only 5.4 months, which is significantly worse than with metastasis to the orbit (15.6 months) or posterior pole of the eye (7.2 months).<sup>8</sup> The overall survival of patients with any form of angiosarcoma is very limited.<sup>9</sup> Since survival of our patient was 1 year after diagnosis of the intraocular metastasis, chemotherapy seems to have been relatively beneficial for our patient.<sup>10</sup>

JOSEF SACH  
JOHANA KREPELKOVA  
PAVEL KUCHYNKA  
Eye Clinic of 3rd Medical Faculty, Charles University,  
Prague, Czech Republic

Correspondence: Josef Sach, MD, Eye Clinic of 3rd Medical Faculty, Srobarova 50, 100 00, Prague 10 - Vinohrady, Czech Republic.

Accepted for publication 20 January 1998

- Shields JA, Shields CL. *Intraocular tumors: a text and atlas*. Philadelphia: WB Saunders, 1992:207-48.
- Buatti JM, Harari PM, Leigh BR, et al. Radiation induced angiosarcoma of the breast. Case report and review of the literature. *Am J Clin Oncol* 1994;17:444-7.
- Poblet E, Gonzales-Palacios F, Jimenez FJ. Different immunoreactivity of endothelial

markers in well and poorly differentiated areas of angiosarcomas. *Virchows Arch* 1996;428:217-21.

- Ohsawa M, Naka N, Tomita Y, et al. Use of immunohistochemical procedures in diagnosing angiosarcoma. Evaluation of 98 cases. *Cancer* 1995;75:2867-74.
- Kohler U, Horn LC, Rosenkranz M, et al. Primaries Angiosarkom der Mamma (Primary angiosarcoma of the breast). *Zentralbl Gynakol* 1996;118:295-8.
- Zincone GE, Perego P, Rossi GM, et al. A case of breast angiosarcoma: diagnostic imaging and review of the literature. *Tumori* 1995;81:387-96.
- Sanders TE. Metastatic carcinoma of the iris. *Am J Ophthalmol* 1938;21:646-51.
- Ferry AP, Font RL. Carcinoma metastatic to the eye and orbit. II: A clinicopathologic study of 26 patients with carcinoma metastatic to the anterior segment of the eye. *Arch Ophthalmol* 1975;29:472-82.
- Bobin Y, Dolbeau D, Besnard C, et al. L angiosarcoma du sein. A propos de quatre cas avec revue de la littérature. (Angiosarcoma of the breast. Apropos of 4 cases with a review of the literature). *Bull Cancer* 1991;78:1037-44.
- Silverman LR, Deligdisch L, Mandeli J, et al. Chemotherapy for angiosarcoma of the breast: case report of 30-year survival and analysis of the literature. *Cancer Invest* 1994;12:142-55.

### Persistent pupillary membranes

EDITOR.—Persistent pupillary membranes (PPMs) which are large enough to interrupt the visual axis are uncommon. If left untreated they may cause stimulus deprivation amblyopia.<sup>1</sup> There is evidence that early treatment to remove obstructions of the visual axis in infants may minimise the risk of amblyopia.<sup>2</sup> We report a case of bilateral persistent pupillary membranes which were successfully treated surgically before the patient was 6 weeks old.

### CASE REPORT

A healthy baby induced at 41 weeks was born by normal vaginal delivery following a normal pregnancy. He weighed 8 lb 8 oz (3.8 kg) and was noted to have an abnormal red reflex from both eyes on routine ophthalmic check by a paediatrician before discharge from hospital after birth. He appeared to fix briefly on a light but did not really look at toys. The red reflexes were significantly reduced centrally and there were peripheral spoke-like opacities. Even with dilatation only a poor fundal view was obtained. The view was particularly poor on the right eye. An ultrasound scan of the posterior pole was normal for each eye. Further examination under anaesthetic showed that the child had hyperplastic persistent pupillary membranes in both eyes (Fig 1). Blood could be seen flowing through the blood vessels within the membranes under the operating microscope. There were no other abnormal examination findings. Screening tests for toxoplasmosis, cytomegalovirus, rubella, and treponemal antibodies were all negative. There was no known history of substance abuse by the mother. The visual axis especially on the right side was significantly obstructed even when the pupils were dilated and consequently we thought that the risk of stimulus deprivation amblyopia was high if they were left in place. The membranes were removed from the right eye when the child was 4 weeks old and from the left eye when he was 5 weeks old.

The same operative technique was used for each eye. A small superior corneal section was made and a further side incision was made. Provisc (Healon) was injected between the membrane and the lens in order to protect the lens from coming into contact with the surgical instruments. Intraocular diathermy of the membrane vessels was attempted but this

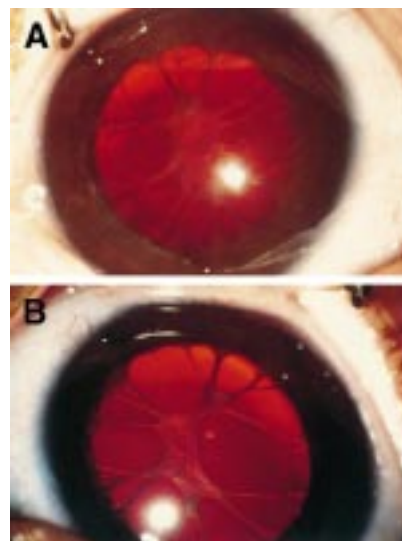


Figure 1 Persistent pupillary membranes shown in the right eye (A) and the left eye (B) of a 4 week old child after dilating drops have been given.

failed to have any effect. The membrane strands were cut with vitreous scissors and the freed membrane was removed with intraocular forceps. There was a small amount of bleeding from one of the more vascularised strands of membrane but the other smaller vessels retracted without bleeding. The Provisc was removed with a Simco irrigation/aspiration canula. The corneal wounds each required a single 10/0 nylon suture which were removed under anaesthetic 3 months postoperatively.

The visual axis was clear following surgery and there was no evidence of cataract. Histology showed a thin membrane of spindle-shaped cells some of which were pigmented. A fine network of blood vessels extended through the membrane.

Follow up of the child 5 months after the operation revealed no evidence of cataract formation in either eye. The eyes were straight and visual assessment showed that he objected to occlusion of each eye equally with a binocular acuity of 6/19 using Cardiff cards.

### COMMENT

Remnants of pupillary membranes are very common occurring in 95% of normal newborn babies.<sup>3</sup> Early development of the crystalline lens at about the sixth week coincides with the growth of the tunica vasculosa lentis which nourishes it. The anterior portion of this is continuous with the pupillary membrane which draws its blood supply from the capillaries which arise from the branches of the long posterior ciliary arteries and the major arterial circle.<sup>4</sup> The pupillary membrane is fully developed by 9 weeks' gestation. These blood vessels begin to undergo remodelling and regression in a process involving phagocytosis by macrophages at around 5 months' gestation. Dysfunction of macrophage invasion and phagocytosis is thought to play a role in the pathogenesis of PPMs.<sup>5</sup>

PPMs are thought to be derived from the tunica vasculosa lentis (TVL) and have normally disappeared by the 34th week of gestation.<sup>6</sup> These membranes are often observed by neonatologists as they are frequently seen in premature babies. They can be used to identify the gestational age of a newborn infant (between 27 and 34 weeks)<sup>7</sup> and they

continue to regress at the same rate as if the child had not been born prematurely.<sup>8</sup> There is some more recent evidence that intrauterine stress, particularly from chronic maternal hypertension, may accelerate the disappearance of these membranes.<sup>9</sup>

PPMs should be distinguished from congenital idiopathic microcoria which results from underdevelopment of the dilator pupillae.<sup>10</sup>

Although not commonly associated with any other pathology there has been a previous report of positive toxoplasma serology occurring in a 30 week premature baby with PPMs.<sup>3</sup> There has also been a report of PPMs occurring in an infant with congenital rubella virus.<sup>6</sup> We believe that any child with a congenital abnormality of the anterior chamber should be screened for possible intrauterine infections. A series of five cases of persistent membranes associated with congenital dystrophia myotonica have been described.<sup>11</sup> There have also been reports of PPMs occurring with a variety of other abnormalities of the anterior chamber which in some cases seem to be familial with autosomal dominant inheritance but in our case there was no family history.<sup>12-13</sup> There have been case reports of spontaneous haemorrhage occurring from PPMs but these are unusual.<sup>14</sup>

When present PPMs are usually so small as to need no treatment since they shrink significantly over the first year of life. There is some evidence that not all PPMs behave in this way. Some membranes appear to become more hyperplastic after birth rather than regressing.<sup>15</sup> Some authors believe that hyperplastic membranes should be considered as a distinct type of PPM<sup>16</sup> and that they may be less likely to regress than thinner membranes that appear simply to be persistent rather than hyperplastic although no formal study has looked at this.<sup>17</sup>

Smaller membranes than the ones we report have been successfully treated with mydriatic therapy until spontaneous involution occurred.<sup>18</sup> However, the smallest useful pinhole size (and presumably pupil aperture) is thought to be 1.5 mm<sup>19</sup> without which normal visual development is unlikely to take place. In our patient the visual axis, especially on the right side, was significantly obstructed even when the pupils were dilated and consequently we thought that the risk of amblyopia using this treatment strategy was high. Early surgery has been described in this condition at 5 days of age with good fixation and a clear visual axis a year later.<sup>17</sup> If there is clear evidence that the membranes are shrinking over the first few weeks of life then it may be reasonable to wait for spontaneous resolution. In our case there was no evidence of resolution over a period of 3 weeks and this contributed towards the decision to operate. There have been reports of neodymium:YAG laser treatment to remove similar membranes from teenage children for cosmetic reasons.<sup>20-21</sup> The long term risk of cataracts from this technique is likely to be high particularly if it were to be used on an infant. There are no published studies of long term follow up of these patients. We believe that a conventional surgical technique is more appropriate than laser treatment in an infant although the operator must be aware of the risk of inducing cataract from unnecessary contact with the lens.

There is growing evidence that the severity of deprivation amblyopia is minimised by earlier treatment to remove any obstruction to the visual axis particularly in the case of

unilateral congenital cataracts.<sup>2</sup> It is likely that a similar critical period applies to bilateral visual obstruction. Some authors feel that there is no visual advantage to be gained by removing these membranes after the sensitive period for visual development is over<sup>16</sup> although modest improvements have been reported<sup>20-21</sup> in teenagers.

If bilateral membranes are large enough to put a child at significant risk of amblyopia then it is our view that a surgical approach to this condition should be taken within the first 6 weeks of life as after this time the amount of irreversible visual dysfunction from amblyopia may well increase. Patients treated surgically for this condition should be followed up carefully because of the long term risk of developing cataract,<sup>15</sup> amblyopia requiring patching, and glaucoma which may accompany congenital abnormalities of the anterior segment.

BJL BURTON

G G W ADAMS

Moorfields Eye Hospital, City Road,  
London EC1V 2PD

Correspondence to: Miss Adams.

Accepted for publication 21 January 1998

- Jacobs M, Jaouni Z, Crompton J, et al. Persistent pupillary membranes. *J Pediatr Ophthalmol Strabismus* 1991;28:215-18.
- Birch EE, Stager DR. The critical period for surgical treatment of dense congenital unilateral cataract. *Invest Ophthalmol Vis Sci* 1996;37:1532-8.
- Tanzer DJ, McClatchey SK. Spontaneous hyphema secondary to a prominent pupillary membrane in a neonate. *J Pediatr Ophthalmol Strabismus* 1997;34:318-20.
- Cook CS, Ozanics V, Jakobiec FA. Prenatal development of the eye and its adnexae. In: Tasman W, Jaeger EA, eds. *Foundations of clinical ophthalmology*. Philadelphia: JB Lippincott, 1996, vol 1, chapter 2:40-1.
- Cook CS, Ozanics V, Jakobiec FA. Prenatal development of the eye and its adnexae. In: Tasman W, Jaeger EA, eds. *Foundations of clinical ophthalmology*. Philadelphia: JB Lippincott, 1996, vol 1, chapter 2:44-6.
- Hittner HM, Speer ME, Rudolph AJ. Examination of the anterior vascular capsule of the lens: III. Abnormalities in infants with congenital infection. *J Pediatr Ophthalmol Strabismus* 1981;18:55-60.
- Hittner HM, Hirsch NJ, Rudolph AJ. Assessment of gestational age by examination of the anterior vascular capsule of the lens. *J Pediatr* 1977;91:455-8.
- Skapinker R, Rothberg AD. Postnatal regression of the tunica vasculosa lentis. *J Perinatol* 1987;7:279-81.
- Hadi HA, Hobbs CL. Effect of chronic intrauterine stress on the disappearance of tunica vasculosa lentis of the fetal eye: a neonatal observation. *Am J Perinatol* 1990;7:23-5.
- Lambert SR, Amaya L, Taylor D. Congenital idiopathic microcoria. *Am J Ophthalmol* 1988;106:590-4.
- Blayney M, Clarke WN. Persistent tunica vasculosa lentis as a sign of congenital myotonic dystrophy. *J Pediatr Ophthalmol Strabismus* 1994;31:384-6.
- Cruysberg JRM, Pinckers A. Ectopia lentis et pupillae syndrome in three generations. *Br J Ophthalmol* 1995;79:135-8.
- Hamming N, Wilensky J. Persistent pupillary membrane associated with aniridia. *Am J Ophthalmol* 1978;86:118-20.
- McLean DW. An unusual case of intra-ocular haemorrhage. *Br J Ophthalmol* 1946;30:758.
- Matsue N, Okabe S, Seki Y. Prenatal fibroplasia from pupillary membrane. *Jap J Clin Ophthalmol* 1973;27:37-42.
- Merin S, Crawford JS, Cardarelli J. Hyperplastic pupillary membrane. *Am J Ophthalmol* 1971;72:717-19.
- Reynolds JD, Hiles DA, Johnson BL, et al. Hyperplastic persistent pupillary membrane: Surgical management. *J Pediatr Ophthalmol Strabismus* 1983;20:149-52.
- Miller SD, Judisch GF. Persistent pupillary membrane: successful medical management. *Arch Ophthalmol* 1979;97:1911-13.
- Miller D, Johnson R. Quantification of the pinhole effect. *Surv Ophthalmol* 1977;21:347-50.

20 Vega LF, Sabates R. Neodymium:YAG laser treatment of persistent pupillary membrane. *Ophthalmic Surg* 1987;18:452-4.

21 Kumar H, Sakhuja N, Sachdev MS. Hyperplastic pupillary membrane and laser therapy. *Ophthalmic Surg* 1994;25:189-90.

### **Candida glabrata endophthalmitis following penetrating keratoplasty**

EDITOR.—Transmission of infection by donor tissue is a well known, albeit rare, complication of corneal transplantation.<sup>1</sup> We have found two reports<sup>2,3</sup> of *Candida glabrata* endophthalmitis, one with an organ cultured cornea when systemic antifungal treatment contributed to the patient's death.<sup>2</sup>

#### CASE REPORT

A 43 year old man with keratoconus had two previous right corneal grafts. The first, in 1974, became vascularised and oedematous after several months; the second, in 1990, failed after two rejection episodes. In February 1995 he underwent further right penetrating keratoplasty using tissue typed material, stored in organ culture for 20 days and transport medium (5% dextran) for 2 days. On the first postoperative day UK Transplant Support Service Authority reported culture of a yeast from the transport medium, subsequently identified as *Candida glabrata*. Clinically the graft was satisfactory but topical econazole 1% (in arachis oil) was given prophylactically six times daily.

Increasing anterior uveitis was treated by increasing topical prednisolone acetate 1% from 2 hourly to hourly at postoperative day 4 and adding oral prednisolone 80 mg daily at day 11. At this stage a tiny white endothelial deposit developed at the graft interface. Over 4 days this became a white plaque of 2 mm diameter (Fig 1) but remained asymptomatic. The lesion was aspirated by paracentesis; microscopy showed a yeast and subsequently *Candida glabrata* was cultured. Amphotericin B 5 µg in 0.1 ml was injected into the anterior chamber immediately and 3 days later, and topical amphotericin B 0.15% commenced 1 hourly. The graft remained clear and the uveitis settled. Oral steroid was withdrawn completely over 7 weeks.

Further threatened rejection with anterior uveitis associated with loose corneal sutures occurred 5 months postoperatively. This was treated with hourly drops of prednisolone acetate 1%. Three weeks later an enlarging

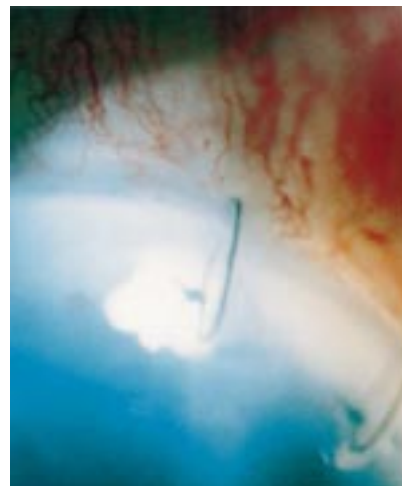


Figure 1 Eleven days postoperatively: white endothelial plaque near graft-host interface.



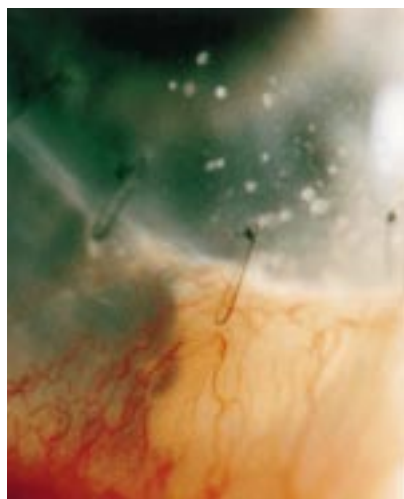


Figure 2 Almost 6 months postoperatively: white mass at different site on host endothelium.

white mass, initially 0.75 mm in diameter, appeared elsewhere on the host endothelium (Fig 2). Aspiration and subsequent culture again confirmed *Candida glabrata*.

Amphotericin B 10 µg in 0.1 ml was injected into the anterior chamber, with subconjunctival injection of amphotericin B 300 µg in 0.3 ml. Topical amphotericin B 0.15% 1 hourly and prednisolone 1% 2 hourly were given. Both injections were repeated at 3 and 20 days. The uveitis settled, topical amphotericin was discontinued, and the graft remains clear 2.5 years later on prednisolone drops once daily.

No toxic effects have been noted from intracameral or topical amphotericin B.

#### COMMENT

Endophthalmitis flared up twice associated with intensive topical and/or oral steroid. *Candida glabrata* was cultured from the transport medium and the recipient anterior chamber, implicating the donor cornea as the source of infection. *Candida glabrata* is a relatively resistant organism and treatment was guided by antifungal susceptibility testing of the isolate. This suggested that the isolate was resistant to fluconazole (minimum inhibitory concentration, MIC >128 mg/l) and itraconazole (MIC 16 mg/l), but was of intermediate sensitivity to econazole (MIC 1 mg/l and 4 mg/l variously on different tests) (Table 1). The latter may explain econazole's failure to prevent infection becoming established. Although the isolate was sensitive to amphotericin (MIC <0.25 mg/l) this was avoided as prophylaxis because of potential toxicity; however, no toxic effects occurred when it was subsequently used.

Failure of amphotericin B in the organ culture medium to eradicate *Candida glabrata*, despite its apparent sensitivity, has been described.<sup>4</sup> A recent report<sup>5</sup> showed 1.1% bacterial or fungal contamination of organ cultured corneas accepted for transplantation

Table 1 Antifungal susceptibility testing of initial *Candida glabrata* isolate

Antifungal	MIC (mg/l)	Interpretation
Amphotericin B	0.25	sensitive
Fluconazole	>128	resistant
Itraconazole	16	resistant
Econazole	1 and 4 (variously on different tests)	intermediate

despite use of antimicrobial agents in the medium. Over 2.5 years Bristol Eye Bank records showed four occasions, including the present incident, when corneas were grafted and the transport medium was subsequently found to be infected. Two cases developed endophthalmitis (*Candida* spp and *glabrata*), while two remained clear of infection (*Pseudomonas* sp and *Penicillium* sp). Over 4500 corneas from the Bristol Eye Bank were grafted during this time, thus the incidence of known graft transmitted endophthalmitis is 0.04%. While accepting that some cases may go unreported, this can be compared with an overall incidence of postoperative endophthalmitis in the literature of 0.1–0.8%<sup>6–9</sup> after corneal grafting with corneas stored at 4°C, and of 0.09%<sup>10</sup> following extracapsular extraction.

This patient remained asymptomatic throughout; close monitoring allowed early detection and successful treatment of the infection.

FIONA M CHAPMAN

Department of Ophthalmology, Royal Victoria Infirmary, Newcastle upon Tyne NE1 4LP

KATHERINE E ORR

Department of Microbiology, Freeman Hospital, Newcastle upon Tyne NE7 2DN

W JOHN ARMITAGE

DAVID L EASTY  
Department of Ophthalmology, Bristol Eye Hospital, Bristol BS1 2LX

DAVID G COTTRELL

Department of Ophthalmology, Royal Victoria Infirmary, Newcastle upon Tyne NE1 4LP

Correspondence to: D G Cottrell.

Accepted for publication 21 January 1998

- Ghandi SS, Lamberts DW, Perry HD. Donor to host transmission of disease via corneal transplantation. *Surv Ophthalmol* 1981;25:306–11.
- Larsen PA, Lindstrom RL, Doughman DJ. Torulopsis glabrata endophthalmitis after keratoplasty with an organ-cultured cornea. *Arch Ophthalmol* 1978;96:1019–22.
- Cameron JA, Antonios SR, Cotter JB, et al. Endophthalmitis from contaminated donor corneas following penetrating keratoplasty. *Arch Ophthalmol* 1991;109:54–9.
- Nelson JD, Mindrup EA, Chung CK, et al. Fungal contamination in organ culture. *Arch Ophthalmol* 1983;101:280–3.
- Borderie VM, Lopez M, Laroche L. Donor corneo-scleral rim cultures after organ culture. *Br J Ophthalmol* 1997;81:516.
- Pardos GJ, Gallagher MA. Microbial contamination of donor eyes. *Arch Ophthalmol* 1982;100:1611–13.
- Leveille AS, McMullan FD, Cavanagh HD. Endophthalmitis following penetrating keratoplasty. *Ophthalmology* 1983;90:38–9.
- Guss RB, Koenig S, De La Pena W, et al. Endophthalmitis after penetrating keratoplasty. *Am J Ophthalmol* 1983;95:651–8.
- Aiello LP, Javitt JC, Canner JK. National outcomes of penetrating keratoplasty. Risks of endophthalmitis and retinal detachment. *Arch Ophthalmol* 1993;111:509–13.
- Kattan HM, Flynn HW, Pflugfelder SC, et al. Nosocomial endophthalmitis survey. Current incidence of infection after intraocular surgery. *Ophthalmology* 1991;98:227–38.

#### Bilateral orbital fat prolapse in cutis laxa

EDITOR.—The association of ocular abnormality with cutis laxa has been described only in de Barsey syndrome, a rare condition in which cutis laxa is associated with corneal clouding, mental retardation, and athetosis.<sup>1,2</sup> Orbital fat prolapse is not uncommon and occasionally occurs bilaterally, usually in older patients. We describe the occurrence of bilateral orbital fat prolapse at an unusually young age in a patient with autosomal recessive cutis laxa.

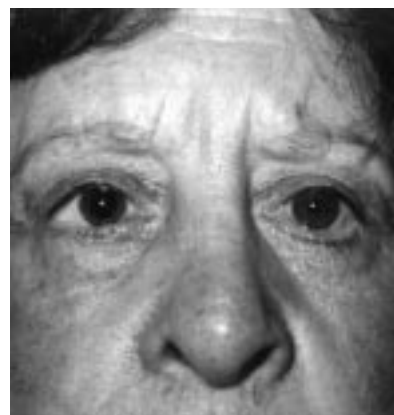

Figure 1 Characteristic facies of cutis laxa in a 37 year old woman showing a prematurely aged appearance, lax redundant skin, downward slanting palpebral fissures, and a broad flat nose. Prolapsed orbital fat is visible beneath temporal subconjunctiva of the right eye.

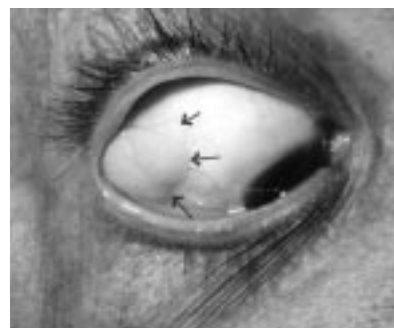

Figure 2 Prolapsed orbital fat beneath temporal bulbar conjunctiva of the right eye. The anterior edge is indicated by arrows.

#### CASE REPORT

A 37 year old woman with autosomal recessive cutis laxa and characteristic facies (Fig 1) presented with a soft, mobile, pale yellow mass beneath the temporal bulbar conjunctiva of each eye, but more prominently on the right (Figs 1 and 2). The overlying conjunctiva was mobile and neither mass had a visible posterior limit. There was no history of previous periocular pathology, trauma, or surgery and ocular examination was otherwise normal.

Incisional biopsy of each mass was performed under local anaesthetic to relieve irritation. The tissue was located in the sub-Tenon's space and continuous posteriorly with intraconal orbital fat. Histological examination revealed normal adipose tissue without dermal elements.

#### COMMENT

Cutis laxa (generalised elastolysis) is characterised clinically by generalised lax pendulous skin which hangs in redundant folds and recoils only slowly after stretching.<sup>2,3</sup> Histologically, there is sparsity, fragmentation, and aggregation of elastic fibres in the dermis.<sup>2,3</sup> Possible pathogenic mechanisms are increased tropoelastin degradation and reduced elastin production—skin fibroblasts have diminished mRNA for elastin in some patients.<sup>2</sup>

Cutis laxa may be inherited (autosomal dominant or recessive) or acquired.<sup>2</sup> In the commoner, recessive form, characteristic facies have downward slanting palpebral fissures, a broad flat nose, sagging cheeks, and large ears producing a bloodhound or prema-

turely aged appearance. Herniae, diverticula, pulmonary emphysema, cor pulmonale, and aortic aneurysm are important complications resulting from abnormal elastic fibres. Acquired forms of cutis laxa may follow inflammatory skin disease or may be associated with hypersensitivity reactions, multiple myeloma, systemic lupus erythematosus, amyloidosis, or maternal penicillamine therapy.<sup>2</sup>

Tenon's capsule normally separates intracanal and extraconal orbital fat from sclera. Surgical or traumatic dehiscence of the capsule more than 10 mm from the limbus may allow forward prolapse of intraconal fat beneath Tenon's capsule.<sup>4</sup> In the elderly, fat prolapse may occur without such an antecedent event and is more frequently located superotemporally.<sup>4,5</sup> Orbital fat prolapse is usually diagnosed clinically,<sup>5</sup> but may be mistaken for a dermolipoma, dermoid cyst,

lacrimal gland tumour, infiltration or granuloma, extraocular muscle enlargement, or an orbital lymphoid proliferation.<sup>6,7</sup>

The largest case series of orbital fat prolapse reports 15 patients aged between 49 and 94 years (average 65 years) of whom 33% were affected bilaterally.<sup>5</sup> The case we report is significantly younger. Although the occurrence bilaterally of this finding at a young age may be coincidental, it suggests that abnormal elastin in Tenon's capsule allowed it to dehisce, creating a route between intraconal fat and the sub-Tenon's space. This report suggests an association between cutis laxa and orbital fat prolapse.

MICHAEL J GREANEY  
ANDREW B RICHARDS

Department of Ophthalmology, Royal Berkshire  
Hospital, London Road, Reading RG1 5AN

Correspondence to: Mr Greaney, Department of Ophthalmology, Queen Alexandra Hospital, Cosham, Portsmouth PO6 3LY.

Accepted for publication 21 January 1998

- 1 de Barsey AM. Dwarfism, oligophrenia and degeneration of the elastic tissue in skin and cornea. *Helv Paed Acta* 1968;23:305-13.
- 2 Champion R, Burbon JL, Ebling FJG, eds. In: *Textbook of dermatology*. 5th ed. Oxford: Blackwell Scientific Publications, 1992;1769-82.
- 3 FitzPatrick TB, Elsen AZ, Wolff K, et al, eds. In: *Dermatology in general medicine*. 4th ed. New York: McGraw-Hill, 1993;1969-71.
- 4 Jordan DR, Tse DT. Herniated orbital fat. *Can J Ophthalmol* 1987;22:173-7.
- 5 Glover AT, Grove AS. Subconjunctival orbital fat prolapse. *Ophthalmic Plast Reconstr Surg* 1987;3:83-86.
- 6 Jordan DR. Orbital fat prolapse. *Arch Ophthalmol* 1993;111:583.
- 7 Lee WR. In: *Ophthalmic histopathology*. London: Springer-Verlag, 1993;259-85.