

Ultrasonic assessment of rhinostomy size following external dacryocystorhinostomy

Eric Ezra, M Restori, G E Mannor, Geoffrey E Rose

Abstract

Aim—To assess the dimensions and patency of the surgical epithelial fistula after external dacryocystorhinostomy, using B mode ultrasonography to define the postoperative soft tissue anastomosis.

Methods—12 patients undergoing 16 external dacryocystorhinostomies, with the creation of large osteotomies, were included in a prospective study. The horizontal and vertical dimensions of the bone ostium was recorded during surgery and compared with the ultrasonographic dimensions of the soft tissue anastomosis at 1 day, 2 weeks, and 6 months after surgery. Functional patency was confirmed with dye testing and irrigation.

Results—Compared with an osteotomy of between 100 and 380 mm² (mean 235 mm²), the soft tissue anastomosis on the day after surgery was, in all cases, markedly smaller (72–252 mm²; mean 144 mm², or 61% of the bone window). The soft tissue anastomosis decreased to between 8 and 208 mm² (mean 98 mm²; 68% of immediate postoperative value) at 2 weeks and 3–208 mm² (mean 71 mm²; 49% of immediate postoperative value) at 6 months. 14 of the 16 (88%) dacryocystorhinostomies were functional at the end of the study, the two failures being associated with marked contracture of the soft tissue anastomosis; the outcome of surgery correlated significantly with the area of the anastomosis at 2 weeks ($\chi^2 = 16.3$; $p < 0.01$) and at 6 months ($\chi^2 = 16.0$, $p = 0.01$).

Conclusions—B mode ultrasonography provides a simple and effective method for assessing the size of the soft tissue anastomosis after external dacryocystorhinostomy and there is a significant reduction in size after surgery, to which the functional outcome of surgery appears related. As the initial soft tissue anastomosis cannot be larger than (and is, on average, about 60% of) the area of the osteotomy, this emphasises the paramount importance of a large rhinostomy to the success of lacrimal surgery.

(*Br J Ophthalmol* 1998;82:786-789)

Since the introduction of external dacryocystorhinostomy (DCR) in 1904,¹ subsequent modifications^{2,3} have ensured a high success rate and established the procedure as the operation of choice for nasolacrimal duct obstruction. Silicone intubation may be used at the time of surgery in cases where anastomosis

is difficult or where healing of the epithelial anastomosis may be compromised with, for example, chronic sepsis or nasal disease.^{4,5}

The success of DCR should routinely be greater than 90%⁶⁻⁹ and may be improved by creating a large osteotomy, often in conjunction with a partial ethmoidectomy, with removal of bone well anterior to the lacrimal sac fossa and by the extensive suturing of nasal mucosa to lacrimal sac mucosa.⁶⁻⁸ Although DCR failure is commonly as a result of fibrosis of a small anastomosis, other causes include untreated distal common canalicular obstruction (which may be caused by intraoperative trauma), medial common canalicular obstruction, or proximal canalicular disease.⁶

Postoperative assessment of the drainage fistula may include functional assessment, by dye disappearance or Jones I tests, or anatomical evaluation, by the Jones II test and dacryocystography. Previous measurements of the soft tissue anastomosis after lacrimal drainage surgery have been based upon nasal endoscopy.¹⁰

B mode ultrasonography, a technique previously reported in the outpatient investigation of lacrimal sac disease,¹¹⁻¹⁶ was used in this study to assess the area of the soft tissue epithelial anastomosis after external DCR. In some cases, colour coded Doppler ultrasonography was used in an attempt to assess the flow characteristics of the healed surgical anastomosis during lacrimal irrigation; the results were, however, difficult to interpret because of associated artefact due to even the finest movements of the lids or syringe during irrigation.

Patients and methods

Patients undergoing external DCR for nasolacrimal duct obstruction were recruited from the lacrimal clinic at Moorfields Eye Hospital. All patients gave informed consent before entering the study.

External DCR was performed under general (14 operations in 10 patients) or local anaesthesia (two patients, two procedures), the rhinostomy being extended to about 1 cm anterior to the anterior lacrimal crest, superiorly to the skull base and inferiorly to the level of the inferior orbital rim; anterior ethmoidectomy was performed in all cases. The vertical and anteroposterior dimensions of the rhinostomy were measured intraoperatively using calipers. To promote primary intention healing of the mucosal surfaces, both the anterior and posterior nasal and sac flaps were sutured with multiple 6/0 Vicryl sutures.

All patients were reviewed on the day after surgery and at 2 weeks and 6 months after surgery. At each visit the soft tissue anastomosis

Moorfields Eye Hospital, London EC1V 2PD
Eric Ezra
M Restori
G E Mannor
Geoffrey E Rose

Correspondence to:
Mr Geoffrey E Rose,
Adnexal Service, Moorfields
Eye Hospital, City Road,
London EC1V 2PD.

Accepted for publication
22 January 1998

Table 1 Estimates for the area of the rhinostomy at surgery and the soft tissue fistula at three times over 6 months after 16 external dacryocystorhinostomies in 12 patients

Case No	Estimated area of intraoperative bone aperture (mm ²)	Area of soft tissue aperture (mm ²)		
		Day 1 Area (%*)	Day 14 Area (%*)	Month 6 Area (%*)
Successful cases:				
1	148	91 (61%)	87 (59%)	84 (57%)
2	144	99 (69%)	50 (35%)	30 (21%)
3	380	198 (52%)	130 (34%)	52 (14%)
4	340	252 (74%)	195 (57%)	84 (25%)
6	100	72 (72%)	72 (72%)	72 (72%)
7	174	145 (83%)	98 (56%)	98 (56%)
8	306	240 (78%)	180 (59%)	126 (41%)
9	240	189 (79%)	162 (68%)	115 (48%)
10	262	247 (94%)	208 (79%)	156 (60%)
11	210	187 (89%)	144 (69%)	138 (66%)
12	255	108 (42%)	84 (33%)	80 (31%)
13	255	117 (46%)	70 (27%)	50 (20%)
15	248	120 (48%)	27 (11%)	12 (5%)
16	288	85 (30%)	42 (15%)	36 (13%)
Mean (n=14)	240	153 (64%)	111 (46%)	81 (34%)
Unsuccessful cases:				
5	208	64 (31%)	10 (5%)	4 (2%)
14	210	88 (42%)	8 (4%)	3 (1%)
Mean (n=2)	209	76 (36%)	9 (4%)	3.5 (2%)

*Percentages expressed as proportion of the area of rhinostomy.

was assessed by B mode ultrasonography and, at the final visit, the patency of the anastomosis was assessed by symptoms and by dye disappearance and Jones I tests. Anatomical patency was evaluated by irrigation. Surgery was considered successful if the patient was free of epiphora and functional patency was confirmed by the dye disappearance and Jones I test at 6 months. The area of the rhinostomy and the soft tissue anastomoses were estimated from the product of the vertical and horizontal dimensions.

B MODE ULTRASONOGRAPHY

The vertical and anteroposterior dimensions of the soft tissue anastomosis were measured by B

mode ultrasonography using an Acuson 128 XPART system with a 7 Hz vector probe; the B mode image being refreshed at a rate of 25 scans/second. Structures such as bone and fibrous tissue have a high acoustic reflectivity and appear as highly "echogenic", compared with fluid filled cavities, which have low reflectivity at the frequency used. The interface between bone and soft tissue could not be accurately imaged, so it was not possible to determine the postoperative dimensions, or degree of reduction (if any), of the bone defect.

Ultrasound examination was performed with the patient semierect and amethocaine drops instilled into the conjunctival sac. A coupling gel was applied to the area around the medial canthus and the vertically orientated probe placed over the medial canthal tendon, perpendicular to the lateral nasal wall. The probe was swept anteroposteriorly, with the maximum vertical measurement being taken as the vertical height of the ostium. To assess the anteroposterior dimensions, the probe was orientated horizontally and swept vertically.

Measurements were taken using the calibrated cursors directly on screen. Accuracy of the linear measurements is dependent upon lateral resolution (in the transverse axis; 0.8 mm for the system used and reproducibility of the measurements is 3%. (The system assumes an average velocity of sound in tissue to be 1540 m/s. Velocities of sound in bone are in the range 2000–3000 m/s, so that a depth scaling factor in the order of 0.5–0.8 exists in areas of bone—that is, bony tissues appear "compressed" in depth by a factor equal to the ratio of the assumed system velocity to that of the actual bone velocity. This scaling factor does

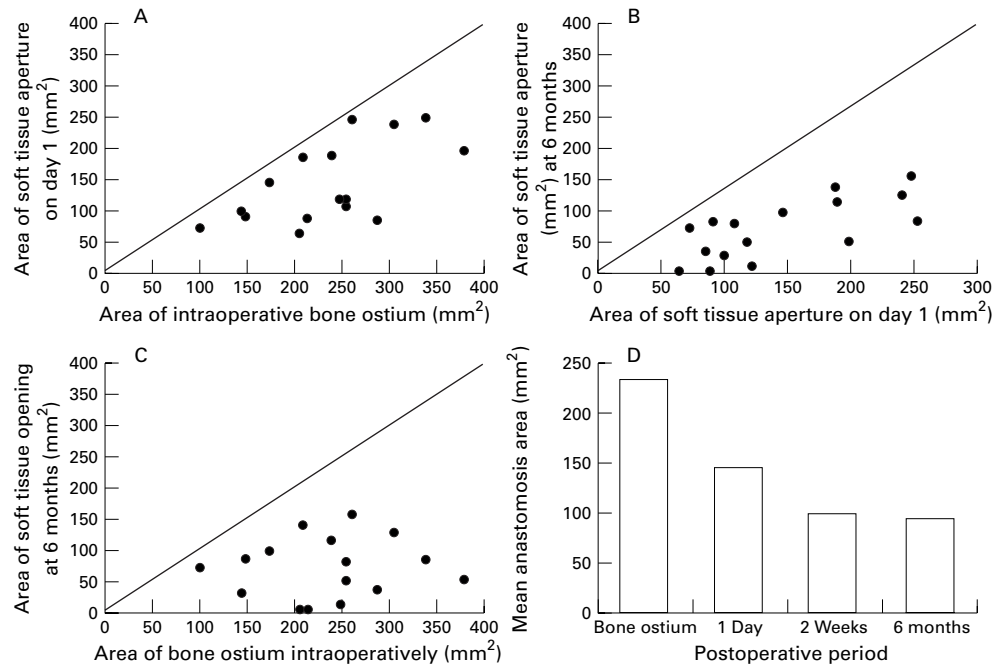


Figure 1 Change in the estimated area of the soft tissue anastomosis immediately after surgery in 16 dacryocystorhinostomies (DCRs) and (A) the bone window measured at surgery or (B) the soft tissue anastomosis when healed at 6 months. Likewise, the size of the fistula at 6 months is related to that immediately after surgery (C). The mean areas of the rhinostomy and the soft tissue anastomosis at 1 day, 2 weeks, and 6 months are compared, this showing that contracture of the mucosal fistula occurs mainly during the first 2 weeks after surgery (D). The oblique lines (A–C) represent the loci of equality, demonstrating that all anastomoses become smaller with time.

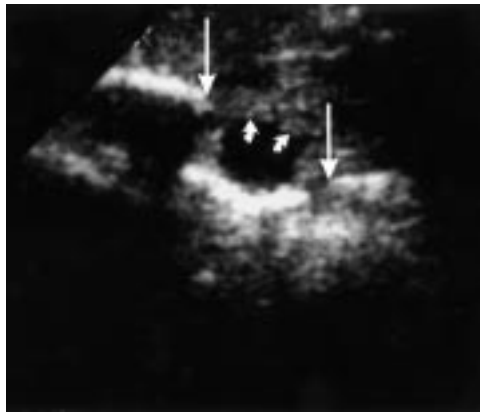

Figure 2 Preoperative ultrasound image (case 6) showing a dilated lacrimal sac (small arrows) and the vertical limits of the lacrimal sac fossa (large arrows).

not, however, affect measurements taken in the transverse axis, as were used throughout this study.)

Results

The dimensions of the postoperative bone window and the postoperative soft tissue anastomosis were available for 16 procedures performed in 12 patients (Fig 1). From the first postoperative day, the soft tissue anastomosis was smaller than the rhinostomy (Fig 1A) and showed marked contraction during the healing phase (Fig 1B). The mean intraoperative size of rhinostomy was 235 mm² (100–380 mm²) and the soft tissue anastomosis declined from an immediate postoperative mean of 144 mm²

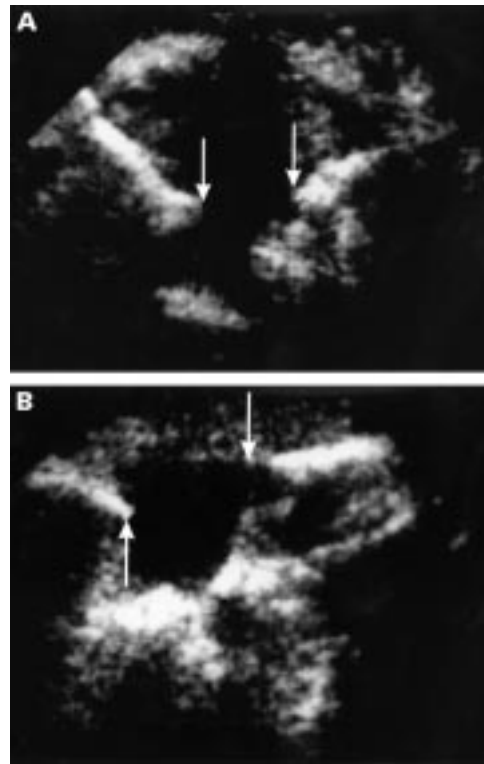


Figure 3 B mode ultrasonogram of the soft tissue anastomosis at 2 weeks after surgery (case 6) showing (A) the anteroposterior dimensions (8.0 mm; between arrows) and (B) the vertical dimensions (9.0 mm; between arrows).

(range 64–252 mm²; 61% of the operative bone window) to 98 mm² at 2 weeks (8–208 mm²; 42% of rhinostomy area; 68% of initial soft tissue fistula) and 71 mm² (4–208 mm²; 40% of rhinostomy; 49% of initial soft tissue fistula) at 6 months (Fig 1D). Over 90% of the total contracture of the soft tissue anastomosis occurred, therefore, within 2 weeks of surgery (Table 1).

Fourteen of the 16 DCRs (88%) were successful at 6 months, with cure of symptoms and patent lacrimal drainage on Jones testing and irrigation. The two procedures that failed (cases 5 and 14) had relatively small anastomoses (64 and 88 mm²) on the day after surgery, these undergoing a marked and rapid fibrosis—to areas of 10 and 8 mm² at 2 weeks and 4 and 3 mm² at 6 months. There was no significant correlation between the success of surgery and the size of intraoperative rhinostomy or the soft tissue aperture immediately after surgery. Success was, however, correlated to the area at 2 weeks ($\chi^2 = 16.3$; $p < 0.01$) and at 6 months ($\chi^2 = 16.0$; $p < 0.01$).

The dilated lacrimal sac may be shown on preoperative B mode ultrasonography (Fig 2; case 6) and the edges of a widely patent soft tissue opening demonstrated as a highly reflective interface with an echolucent gap between them (Fig 3); medial to the anastomosis, the nasal cavity and septum are seen as echolucent and reflective areas, respectively. If silicone intubation was used, this may be readily imaged (Fig 4).

Extensive contracture of the anastomosis, to only 2 mm diameter, was readily evident at 6 months after surgery (Fig 5; case 5). In both of the cases (cases 5 and 14) that failed, no haematoma was clinically evident and irrigation and probing at 6 months confirmed the strictures. Neither case had a significant “sump” of residual, unopened, lacrimal sac.

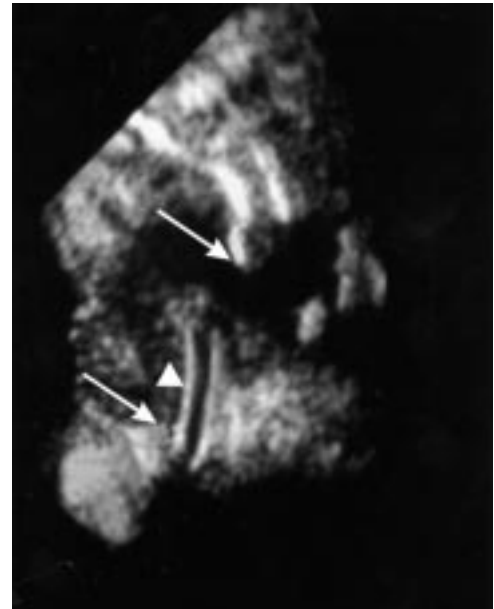


Figure 4 Ultrasonogram of a postoperative anastomosis at 2 weeks (case 11, right side), showing vertical limits of 11.3 mm (arrows). A part of the silicone intubation (arrowhead) is seen to pass inferiorly through this plane of section.

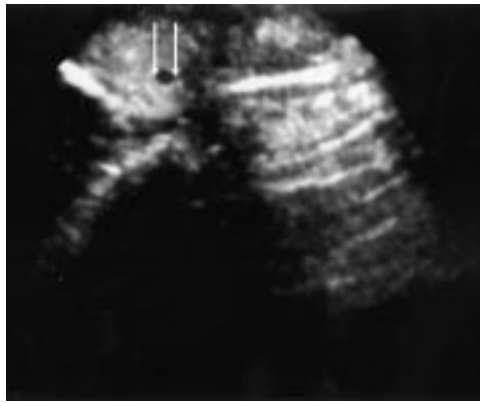


Figure 5 Failed anastomosis at 6 months after surgery (case 14), the vertical dimension of the soft tissue aperture being 2 mm (arrows).

Discussion

Ultrasonography has been well described in the diagnosis of lacrimal drainage system disease associated with gross anatomical changes including dacryocystitis, mucoceles, and dacryoliths.^{11–16} It is a relatively simple outpatient procedure which may be performed on the day after surgery without discomfort to the subject, this being in contrast with intranasal endoscopy which is difficult immediately after surgery, owing to intranasal haematoma and tissue tenderness, and may be uncomfortable if the patient has narrow anterior nares.

Both bone and soft tissues have high acoustic reflectivity at the frequency used and B mode ultrasonography is unable to determine accurately the junction between bone and soft tissue, although some areas of soft tissue do show intermediate reflectance (Fig 3). The measurements obtained represent, therefore, the dimensions of the soft tissue opening—which is clinically relevant to the function of the fistula.

The area of the soft tissue anastomosis on the first postoperative day was, on average, about 61% of the rhinostomy. Naturally, the mucosal anastomosis cannot be as large as the surrounding bone window, but some of the 39% reduction in area is probably attributable to oedema in the soft tissues at the operative site. Although resolution of the oedema would be expected to increase the fistular area, contraction due to fibrosis had, by the second week, reduced the area to about 40% of the rhinostomy; there being only very little further contracture by 6 months after surgery. Of the final difference in mean area between the rhinostomy and the soft tissue opening at 6 months, 56% of the reduction was present on the first day and over 90% by 2 weeks after surgery.

These findings are in agreement with those described after intranasal endoscopy,¹⁰ although the extent of contraction appears to be less marked in our experience; this possibly being attributable to a larger osteotomy, combined with partial ethmoidectomy, and extensive mucosal suturing—the latter encour-

aging healing by primary intention. As might be expected with the variability of healing response in different individuals (Table 1), the correlation between the intraoperative bone window and the final size of the healed anastomosis is only limited (Fig 1C).

The failures in our cases were clearly linked to a marked contracture of the surgical fistula; although a functional result may be achieved with a fistula of 6 mm²,¹⁰ such a small opening is more likely to be associated with a “sump” syndrome as a result of poorly draining remnants of lacrimal sac. The necessity for the largest possible rhinostomy is immediately evident as a large soft tissue anastomosis has—in the face of about 50% contracture during healing—the greatest probability of remaining patent; moreover, the actual thickness of the mucosa appears to preclude an initial fistular area of more than 60% of the bone window (Table 1). Indeed, the higher failure rate generally reported for endonasal DCR is probably attributable to a smaller rhinostomy and greater postoperative fibrosis, where healing of tissues is largely by secondary intention; creation of a large rhinostomy during endonasal surgery being impeded by difficulty in removing the frontal process of the maxilla.

B mode ultrasonography appears, therefore, to be an effective, non-invasive technique for assessing the size of a soft tissue anastomosis following DCR. It is safe and relatively simple to perform and, in conjunction with dye tests and syringing, may provide sufficient functional and anatomical information in the outpatient setting to obviate the need for dacryocystography or nasal endoscopy.

- 1 Toti A. Nuovo metodo conservatore di cura radicale delle suppurazioni croniche del sacco lacrimale. *Clin Mod Firenze* 1904;10:385–9.
- 2 Ohm J. Verbesserungen an meinem nystagmographen. *Klin Monatsbl Augenheilkd* 1926;1:791–4.
- 3 Pico G. A modified technique for external dacryocystorhinostomy. *Am J Ophthalmol* 1971;72:679–90.
- 4 Anderson RL, Edwards JJ. Indications, complications and results with silicone stents. *Ophthalmology* 1979;86:1474–87.
- 5 Rosen N, Sharir M, Moverman DC, Rosner M. Dacryocystorhinostomy with silicone tubes: evaluation of 253 cases. *Ophthalmic Surg* 1989;20:115–9.
- 6 Hecht SD. In: Hornblass A, ed. *Dacryocystorhinostomy: oculoplastic, orbital and reconstructive surgery*. Baltimore: Williams & Wilkins, 1990:1433–40.
- 7 Viers ER. *Lacrimal disorders*. St Louis: CV Mosby, 1976:122.
- 8 Dupuy-Dutemps, Bourguet. Procède plastique de dacryocystorhinostomie et ses résultats. *Ann Ocul* 1921;158:241–61.
- 9 Walland MJ, Rose GE. Factors affecting the success rate of open dacryocystorhinostomy. *Br J Ophthalmol* 1994;78:888–91.
- 10 Linberg JV, Anderson RL, Bumsted RM, et al. Study of intranasal ostium in external dacryocystorhinostomy. *Arch Ophthalmol* 1982;100:1758–62.
- 11 Oksala A. Diagnosis by ultrasound in acute dacryocystitis. *Acta Ophthalmol* 1959;37:176–80.
- 12 Dutton J. Standardised echography in the diagnosis of lacrimal drainage dysfunction. *Arch Ophthalmol* 1989;107:1010–5.
- 13 Divine RD, Anderson RL, Bumsted RM. Bilateral congenital lacrimal sac mucoceles with nasal extensions and drainage. *Arch Ophthalmol* 1983;101:246–50.
- 14 Montanara A, Mannino G, Contestabile MT. Macrodacryocystography and echography in diagnosis of disorders of the lacrimal pathways. *Surv Ophthalmol* 1983;28:33–45.
- 15 Scott WE, Fabre JA, Ossoinig KC. Congenital mucocele of the lacrimal sac. *Arch Ophthalmol* 1979;97:1656–9.
- 16 Jedrzynski MS, Bullock JD. Lacrimal ultrasonography. *Ophthalmic Plast Reconstr Surg* 1994;10:114–20.