

LETTERS TO THE EDITOR

Retinopathy associated with pancreatitis in a child with maple syrup urine disease

EDITOR.—Retinopathy associated with pancreatitis is an uncommon condition first described in 1975.¹ To date, fewer than 50 cases have been reported, all involving adults. We report a case of pancreatitis with retinopathy in a young child with maple syrup urine disease, a rare metabolic disorder.

CASE REPORT

A 7 year old Indian female presented with maple syrup urine disease (MSUD) diagnosed in infancy. She has been maintained on a special diet since then, enjoying normal development. However, during December 1995 she was admitted to the hospital for management of acute gastroenteritis and dehydration. Laboratory studies included serum amylase and lipase which were within normal limits. She received hyperalimentation with glucose and intralipids through a femoral catheter. On her third hospital day she was noted to have mental status changes which improved with hydration. However, on her sixth hospital day her mental status deteriorated again. Her abdomen became diffusely tender. Laboratory studies revealed serum amylase 453 U/l (normal limits 40-128), calcium 8.2 mg/dl, phosphorus 2.2 mg/dl, albumin 2.6 g/dl, total protein 5.1 g/dl, and a white cell count of $12.4 \times 10^6/l$. The serum was noted to be lipaemic despite her receiving only intravenous dextrose in 1/2 normal saline solutions. All other routine laboratory values were within normal limits. Arterial blood

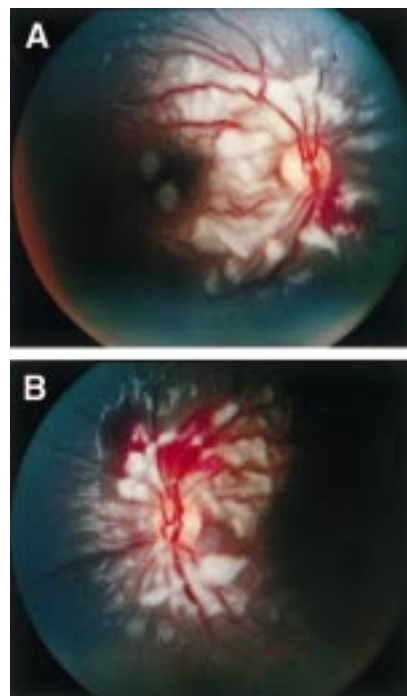


Figure 1 Fundus photographs (A) right eye, (B) left eye. Note dilated vessels, haemorrhage, and numerous cotton wool spots in the posterior pole.

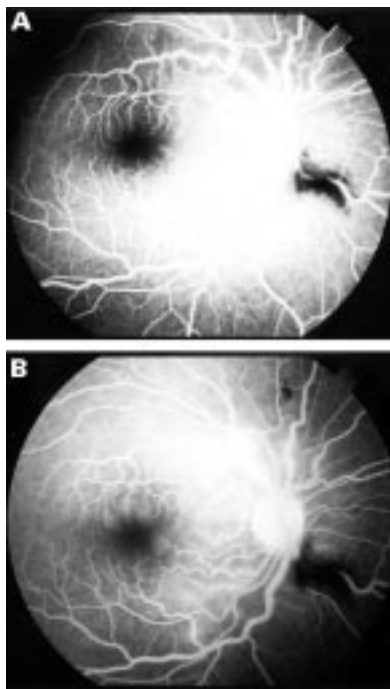


Figure 2 Fluorescein angiograms of right eye (A) early (B) late. The macular circulation is essentially normal except for some oedema along the superior and inferior arcades.

gases were within normal limits. Amino acid levels of isoleucine, histidine, and valine were within normal limits while leucine was 12.9 mg/dl (normal limits 1.0-5.2). During a neurological examination white lesions were noted in both fundi. In the next 48 hours, the patient's general status improved. Her serum amylase levels declined while lipase levels increased to reach a peak of 2485 U/l (normal limits 23-208).

An ophthalmic evaluation 2 days after the initial elevation in serum amylase revealed visual acuity of 20/50 in both eyes (Snellen E) both at distance and at near. No afferent pupillary defect was recorded. Ocular versions were intact. Slit lamp biomicroscopy was unremarkable. Dilated fundus examination revealed the presence of bilateral white fluffy lesions and areas of haemorrhage (Fig 1). Findings were concentrated in the posterior poles only. Fluorescein angiography showed minimal capillary non-perfusion (Fig 2).

The patient slowly improved spontaneously. On follow up examination 1 month later, visual acuity was 20/25 in both eyes with no correction. Fundus examination was completely normal, with full resolution both of cotton wool spots and of haemorrhages.

COMMENT

Maple syrup urine disease is caused by a defect in branched chain ketoacid (BCKA) dehydrogenase.² Ocular complications of untreated disease or late diagnosis include optic atrophy, nystagmus, ophthalmoplegia, strabismus, and cortical blindness.³

Pancreatitis is a known complication of branched chain organic acidurias (BCOA).

In a series of 108 paediatric patients with BCOA, nine cases of pancreatitis were found during a 10 year period. One of these cases was in a patient with MSUD.⁴

Retinopathy as a rare complication of acute pancreatitis was first described in 1975.¹ It has been reported to occur either before⁵ or after the manifestation of acute pancreatitis.^{1,6-10} All reported cases to date have been in young adults (ages 25-40 years), often associated with a history of ethanol misuse. None of the previously reported cases had associated systemic metabolic diseases.

The aetiology of retinopathy of pancreatitis is debatable. An older theory, supported by some experimental data,¹¹ holds that fat emboli found in many organs in cases of acute pancreatitis^{12,13} cause ischaemic retinal infarcts. Retinal fat emboli have also been found in Purtscher's retinopathy,¹⁴ a condition remarkably similar to pancreatitis associated retinopathy.

Another theory proposes embolisation of retinal vessels by complement induced fibrin clots and leucoaggregates as the causative mechanism.¹⁵ However, experimental studies have failed to reproduce various features of the clinical picture of retinopathy of pancreatitis.¹⁶

The presence of lipaemia in our patient argues for the lipid embolism theory. Hypovolaemia and hypoxia did not occur and are thus unlikely to have been involved in the pathogenesis of the retinal picture. Although our patient maintained almost normal levels of leucine, isoleucine, and valine throughout the above episode, it is unclear whether the presence of MSUD predisposed her to the development of retinopathy of pancreatitis.

This work was supported in part by an unrestricted grant from Research to Prevent Blindness Inc, New York, NY, USA.

JOHN DANIAS
EDWARD L RAAB
ALAN H FRIEDMAN

Department of Ophthalmology, Mt Sinai Medical Center, CUNY, New York, USA

Correspondence to: Dr Friedman, Mt Sinai Medical Center, Box 1183, 1 Gustave L Levy Place, New York, NY 10029, USA.

Accepted for publication 13 January 1998

- Inkeles DM, Walsh JB. Retinal fat emboli as a sequela to acute pancreatitis. *Am J Ophthalmol* 1975;80:935-8.
- Korein J, Sansaricq C, Kalmijn M, et al. Maple syrup urine disease: clinical, EEG and plasma amino acid correlations with a theoretical mechanism of acute neurotoxicity. *Int J Neurosci* 1994;79:21-45.
- Burke JP, O'Keefe M, Howell R, et al. Ophthalmic findings in maple syrup urine disease. *Metab Pediatr Syst Ophthalmol* 1991;14:12-15.
- Kahler SG, Sherwood WG, Woolf D, et al. Pancreatitis in patients with organic acidurias. *J Pediatr* 1994;124:239-43.
- Semlacher EA, Chan-Yan C. Acute pancreatitis presenting with visual disturbance. *Am J Gastroenterol* 1993;88:756-9.
- Flores MSD, Rodriguez IN, Bernal IL, et al. Retinopathy as a systemic complication of acute pancreatitis. *Am J Gastroenterol* 1994;90:321-4.
- Slater G, Goldblum SE, Tzamaloukas AH, et al. Renal cortical necrosis and Purcher's retinopathy in hemorrhagic pancreatitis. *Am J Med Sci* 1984;288:37-9.
- Jacob HS, Goldstein IM, Shapiro I, et al. Sudden blindness in acute pancreatitis. Possible role of

- complement-induced retinal leukoembolization. *Arch Intern Med* 1981;141:134-6.
- 9 Kincaid MC, Green WR, Knox DJ, et al. A clinicopathological case report of retinopathy of pancreatitis. *Br J Ophthalmol* 1982;66:219-26.
 - 10 Snady-McCoy L, Morse PH. Retinopathy associated with acute pancreatitis. *Am J Ophthalmol* 1985;100:246-51.
 - 11 Ashton N, Henkin P. Experimental occlusion of retinal arteriols. *Br J Ophthalmol* 1965;49:225-34.
 - 12 Edmondson HA, Fields IA. Relation of calcium and lipids to acute pancreatic necrosis. *Arch Intern Med* 1942;69:177-94.
 - 13 Hackelbusch R. Fetteembolie des Netzhautarterien nach akuter pankreatitis. *Klin Monatsbl Augenheilkd* 1984;185:50-2.
 - 14 Kearns TP. Fat embolism of the retina. *Am J Ophthalmol* 1956;41:1-12.
 - 15 Behrens-Baumann W, Scheurer G, Schroer H. Pathogenesis of Purcher's retinopathy. *Graefes Arch Clin Exp Ophthalmol* 1992;230:286-91.
 - 16 Hollo G, Popik E. Is retinopathy in pancreatitis caused by leucocyte emboli? *Acta Ophthalmol* 1992;70:820-3.

Immediate postoperative objective refraction as an indication to final refraction in phacoemulsification surgery

EDITOR,—The goal of cataract surgery is the rapid attainment of good visual acuity, ideally unaided for the intended focal distance and this is dependent on accurate intraocular lens (IOL) power calculation. Refractive prediction errors, if substantial, can be problematic for the patient.

If the problem is one of symmetrical ametropia, spectacle correction is usually successful. Contact lens fitting may be necessary for those patients with anisometropia in whom spectacle wear would induce significant and intolerable aniseikonia. IOL exchange as a secondary procedure may have to be considered in cases refractory to these measures.

In our study, we aimed to ascertain whether objective refraction at the end of surgery was feasible and if so, to determine how this refraction related to the final refraction at 4-7 weeks postoperatively with a view to suggesting guidelines for immediate exchange of implant in cases of gross refractive prediction errors.

CASE REPORT

Consecutive patients undergoing phacoemulsification cataract surgery after continuous curvilinear capsulorhexis with capsular bag implantation of Chiron C10UB injectable IOLs were refracted at the end of surgery on the table objectively with a streak retinoscope, and at 4-7 weeks postoperatively when objective refractions were refined subjectively for best visual acuity. Viscoelastic used was Provisc (sodium hyaluronate 1%). The immediate postoperative refraction results were not available to the ophthalmologist performing the final refractions. Patients with glaucoma, diabetic retinopathy, macular degeneration, preoperative, and/or postoperative complications and patients who failed to attain 6/9 or better Snellen visual acuity at final refraction were excluded.

Twenty six eyes of 26 patients were included (six males and 20 females, 16 right eyes and 10 left eyes). Ages ranged from 62 to 86 years with a mean of 78.9. Twenty four patients had topical anaesthesia and two had peribulbar injections followed by application of Honan balloon. IOL powers ranged from 16 D to 27 D with a median of 22.5 D.

Data were analysed using statistical software on Macintosh computer.

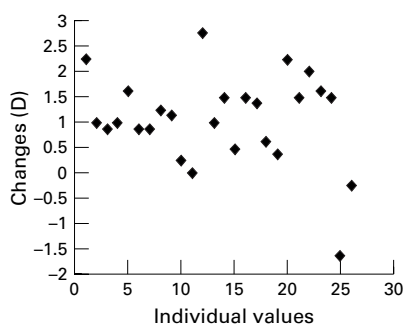


Figure 1 Scattergram of refractive change from immediate postoperative refraction to final refraction.

We were unable to refract two patients owing to the presence of corneal epithelial haze.

Figure 1 shows a few values clustering around the neutral—that is, “no change” line, and a single significant myopic change but the predominant feature is the shift towards hypermetropia. The single significant myopic change occurred in a patient who had topical anaesthesia.

The mean change in refraction was 1.11 D hypermetropia with a standard deviation of plus or minus 0.94 D. The range was from 1.63 D myopic change to 2.75 D hypermetropic change. The 95% confidence interval was 0.73 D, 1.48 D. Paired two tailed Student's *t* test performed on the immediate postoperative and final refraction results gave a *p* value of <0.001.

COMMENT

Høvding *et al* reported that about a third of the 188 patients in whom a PC-IOL was implanted after extracapsular cataract extraction ended up with more than plus or minus 1.0 D deviation from the predicted postoperative refraction. In about a tenth deviations of more than plus or minus 2.0 D from the calculated value were found.¹

The earliest reported IOL exchange was performed on the first postoperative day.² In other studies the average interval between the primary surgery and the implant exchange ranged from 3.5 years to over 5 years.^{3,4}

We found that following phacoemulsification surgery, the preservation of corneal clarity together with the minimally induced surgical astigmatism allowed us to perform immediate postoperative objective refractions satisfactorily in most cases.

There was a statistically significant hypermetropic shift. We think that the most likely explanation lies in the reduced effectivity of the IOL as it settles back in the postoperative period. After phacoemulsification cataract surgery with continuous curvilinear capsulorhexis, the depth of anterior chamber has been found to increase gradually, the anterior capsular size to narrow, and the refraction to tend towards hypermetropia.⁵ The IOL used in our study was a Chiron C10UB—a plate haptic lens with no angulation and a predicted final anterior chamber depth of 5.59 mm.

Various factors which can affect the accuracy of immediate postoperative refraction should be considered. Corneal haze from any cause or presence of a posterior capsular plaque can interfere with retinoscopic reflexes. Viscoelastic should be removed completely at the end of surgery especially from behind the IOL. We made sure that the globe was firm, neither too soft nor too hard, before we refracted. If a gross refractive error is detected,

we would advise a fundal examination be performed to exclude any posterior pole lesions hitherto undetected.

In conclusion, objective refraction immediately following phacoemulsification surgery is feasible; if a gross refractive prediction error is found, immediate implant exchange may be considered, taking into account the mean hypermetropic shift of about 1 dioptre from immediate postoperative objective refraction to the final refraction in the postoperative period in cases where the Chiron C10UB lens has been implanted.

KYAW LIN TU
ALAN GASKELL

Department of Ophthalmology, Ayr Hospital,
Ayr KA6 6DX

Correspondence to: Dr Tu.

Accepted for publication 20 January 1998

- 1 Høvding G, Natvik C, Sletteberg O. The refractive error after implantation of a posterior chamber intraocular lens. *Acta Ophthalmol Copenh* 1994;72:612-16.
- 2 Allan B, Duguid G, Dart J. Intraocular lens exchange on day one after surgery. *J Cataract Refract Surg* 1994;20:676-7.
- 3 Sinskey RM, Amin P, Stoppel JO. Indications for and results of a large series of intraocular lens exchange. *J Cataract Refract Surg* 1993;19:68-71.
- 4 Lyle WA, Jin J-C. An analysis of intraocular lens exchange. *Ophthalmic Surg* 1992;23:453-8.
- 5 Nishigaki S, Inaba I, Minami H, et al. The postoperative change of depth of anterior chamber, refraction and anterior capsulorhexis size after intraocular lens implantation. *Nippon Ganka Gakkai Zasshi* 1996;100:156-8. (English abstract)

Retinal haemorrhage caused by “ecstasy”

EDITOR,—“Ecstasy” (3,4-methylenedioxyamphetamine (MDMA)) is an amphetamine derivative classified as a class A drug under the Misuse of Drugs Act 1971. It is a recreational drug and can be bought under a variety of names (XTC, Adam, E, yellow burger, etc). The drug is a white powder and comes in coloured tablets or capsules. Usual doses are from 30 to 150 mg.

A patient is described who developed retinal haemorrhage after taking one ecstasy capsule.

CASE REPORT

A 22 year old white woman took an ecstasy capsule while sitting down in a night club. After 30 minutes she felt the effects of the ecstasy. During this time she had sat at a table and had not exerted herself, vomited, danced,

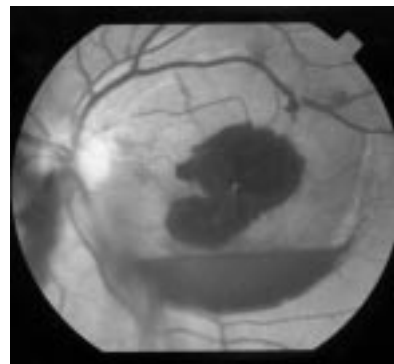


Figure 1 Photograph of the left fundus showing a subinternal limiting membrane haemorrhage at the centre of the macula. The haemorrhage has broken through the internal limiting membrane into the vitreous.

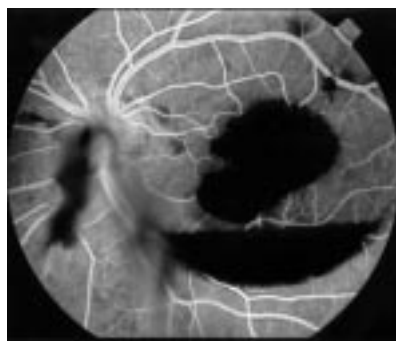


Figure 2 Photograph of the left fundus at the mid venous phase of an intravenous fluorescein angiogram showing masking by the subinternal limiting membrane haemorrhage.

or performed any valsalva manoeuvre. She developed sudden loss of the central vision in her left eye and felt unwell. She then left the club. She presented at the casualty department 2 days later. On examination her right visual acuity was 6/5 and left visual acuity was 1/60. She had no relative afferent pupillary defect. The anterior segments were normal and intraocular pressure was 15 mm Hg in the right eye and 17 mm Hg in the left eye. The right fundus was normal. The left fundus revealed a 3 disc diameter subinternal limiting membrane haemorrhage at the centre of the macula (Fig 1). There were retrohyaloid haemorrhages inferior and superonasal to the macula. General examination including cardiovascular and neurological assessment was normal, blood pressure was 120/70, and the pulse was 70 beats per minute. Intravenous fluorescein angiogram showed masking from the subinternal limiting membrane haemorrhage with no evidence of choroidal neovascularisation (Fig 2). The following blood investigations were performed: haemoglobin 13.2 g/dl, white cell count $11.0 \times 10^9/l$, platelets $329 \times 10^9/l$, erythrocyte sedimentation rate 2 mm in the first hour, antinuclear antibodies, and an autoantibody screen were negative. Fasting glucose was 3.7 mmol/l, international normalised ratio = 1.01, activated partial thromboplastin time = 0.95 and fibrin, protein S and C levels were normal. Computerised tomography scan of the brain was normal. Three months later the haemorrhages had resolved and the visual acuity was 6/9 in the left eye. There was no evidence clinically or angiographically of choroidal neovascularisation.

COMMENT

Ecstasy is known to cause hypertension,¹ ventricular fibrillation,¹ tachycardia, hyperpyrexia,² and intracerebral haemorrhage.³ The positive chronotropic effects and hypertension are caused by stimulating noradrenaline release from sympathetic nerve endings. A sudden rise in blood pressure could have caused a retinal haemorrhage in a similar fashion to the intracerebral haemorrhage.³ Methamphetamine and cocaine are known to cause retinal haemorrhage when taken nasally.⁴

It is known that there is a rich supply of autonomic and vasoactive nerves in the choroid but not in the retina.⁵ This makes the retinal circulation vulnerable to sudden changes in the blood pressure, which may have been important in this patient.

The retinal haemorrhage in this case may have been caused by ecstasy. This suggests that any patient attending with problems from

ecstasy should have a thorough ophthalmic examination and medical consultation including temperature assessment, blood pressure monitoring, and possibly overnight observation in hospital.

ANDREW S JACKS
PHILIP G HYKIN
Moorfields Eye Hospital, City Road,
London EC1V 2PD

Correspondence to: Mr Jacks.

Accepted for publication 21 January 1998

- 1 Dowling GP, McDonough ET, Bost RO. 'Eve' and 'ecstasy' a report of five deaths associated with the use of MDEA and MDMA. *JAMA* 1987;257:1615-7.
- 2 Chadwick IS, Linsley A, Freemont AJ, et al. Ecstasy, 3-4 methylenedioxymethamphetamine (MDMA), a fatality associated with coagulopathy and hyperthermia. *J R Soc Med* 1991;84:371.
- 3 Harries DP, De Silva R. 'Ecstasy' and intracerebral haemorrhage. *Scott Med J* 1992;37:150-2.
- 4 Wallace RT, Brown GC, Benson W, et al. Sudden retinal manifestations of intranasal cocaine and methamphetamine abuse. *Am J Ophthalmol* 1992;114:158-60.
- 5 Alm A, Bill A. In: Moses RA, Hart WM, eds. *Adler's physiology of the eye*. St Louis: Mosby, 1987:183-203.

Latanoprost and cystoid macular oedema in a pseudophake

EDITOR,—Latanoprost (0.005%) is a prostaglandin F-2 α analogue licensed for primary open angle glaucoma. We describe the occurrence of cystoid macular oedema in a pseudophakic patient following its use.

CASE REPORT

A 50 year old pseudophakic myope (-4.50 D) was prescribed latanoprost once daily, because of raised intraocular pressure despite treatment with twice daily betaxolol (1/2%) drops. The right eye was blind from retinal detachment and the left eye had undergone three retinal detachment repairs including one vitrectomy. He had required betaxolol twice daily in the left eye to control the intraocular pressure since then. In January 1994, a left phacoemulsification cataract extraction with posterior lens implant restored the left visual acuity to 6/6.

In March 1997, latanoprost was prescribed to control the rising intraocular pressure, 7 weeks after which the vision dropped to 6/9, the patient describing a central scotoma.

Cystoid macular oedema was evident on examination with a left disc haemorrhage and a superonasal, peripapillary subretinal haemorrhage without evidence of other vascular abnormalities (Fig 1). Fundus fluorescein

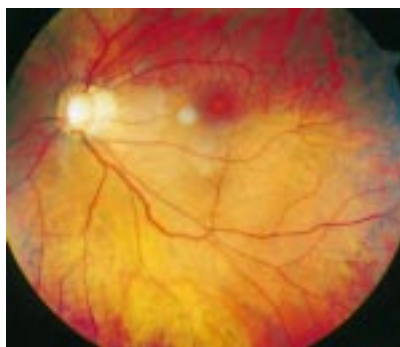

Figure 1 Left fundus photograph shows superonasal peripapillary haemorrhage and cystoid macular oedema.

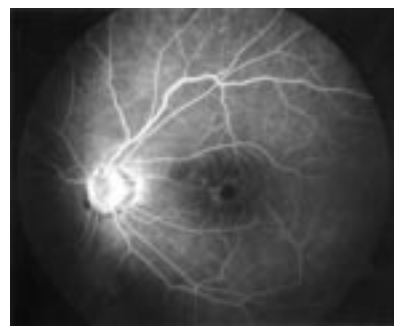


Figure 2 Left fundus fluorescein angiogram shows cystoid macular oedema.

angiography (FFA) showed a petaloid appearance typical of cystoid macular oedema (Fig 2). The latanoprost was stopped, and within 2 weeks the symptoms of visual blurring and the cystoid macular oedema had improved. The patient continued on betaxolol to the left eye but inadequate intraocular pressure control made further filtering surgery necessary.

COMMENT

This eye had undergone retinal detachment repairs including scleral buckling, cryotherapy, vitrectomy, and then phacoemulsification and lens implantation. There was a 3 year gap before latanoprost was prescribed. These procedures may each be associated with cystoid macular oedema^{1,2} and selective use of pars plana vitrectomy used in its treatment,³ but all procedures occurred over 2 years previously with 6/6 vision in the intervening period. While we cannot exclude pre-existing subclinical, angiographically positive cystoid macular oedema,⁴ the timing of onset and relief of clinical symptoms and signs with latanoprost administration was striking.

Hoynig *et al*⁵ administered latanoprost (0.006%) twice daily for a month to uncomplicated pseudophakic patients and fluorescein angiography showed no retinal leak. Six aphakic cynomolgus monkeys given seven times the usual daily dose for 6 months failed to develop cystoid macular oedema.⁵ However, intravitreal injections of PGF-2 α to pigmented rabbits showed a small but statistically significant leak by vitreous fluorophotometry.⁶ Animal work needs to be interpreted circumspectly, particularly regarding the rabbit which shows an atypical response to inflammation.⁷ These experimental results suggest that aphakic or pseudophakic primates do not normally develop cystoid macular oedema in response to prostaglandins.

Miyake and colleagues' work on rabbits and baboons confirmed that aphakia and pseudophakia may be associated with impaired removal of prostaglandins by the ciliary processes (Bito's pump), with resulting accumulation in the eye, since prostaglandins are not broken down intraocularly.^{8,9} Possibly Bito's pump was impaired in our patient, further raising prostaglandin levels and increasing the concentration gradient.

This patient had already had a peripheral anterior vitrectomy during the second left retinal detachment repair, and in such a case it probably would facilitate diffusion of prostaglandins posteriorly.

Furthermore, there were extensive and repeated vitreoretinal procedures performed before administration of the medication and this was a complex case of posterior chamber pseudophakia. This case confirms the

importance of continued vigilance during the post-marketing phase of medications. This medication is currently not advised for cases of aphakia and anterior chamber pseudophakia.

However, we cannot infer that straightforward cases of pseudophakia should be denied another medical option in the ophthalmologist's armamentarium simply on the basis of one case.

D R A WARDROP
P K WISHART

*Glaucoma Clinic, St Paul's Eye Unit,
8Z Link Corridor, Royal Liverpool University Hospital,
Daulby Street, Liverpool L7 8XP*

Correspondence to: Dr Wardrop.

Accepted for publication 21 January 1998

- Girard P, Karpouzias I. Visual acuity after scleral buckling surgery. *Ophthalmologica* 1995;209:323-8.
- Powe NR, Schein OD, Gieser SC, et al. Synthesis of the literature on visual acuity and complications following cataract extraction with intraocular lens implantation. *Arch Ophthalmol* 1994;112:239-52.
- Geol SD, Thompson JT, Glaser BM, et al. Pars plana vitrectomy for chronic pseudophakic cystoid macular edema with no pre-operative evidence of vitreous adhesions. *Invest Ophthalmol Vis Sci* 1996;37:5254 (abstract).
- Mishima H, Masuda K, Miyake K. The putative role of prostaglandins in cystoid macular edema. In: Bito LJ, Stjernschantz J, eds. *The ocular effects of prostaglandins and other eicosanoids*. New York: Alan R Liss, 1989:251-64.
- Hoyn PFJ, Rulo AH, Greve EL, et al. Fluorescein angiographic evaluation of the effect of latanoprost treatment on blood-retinal barrier integrity: a review of studies conducted on pseudophakic glaucoma patients and on phakic and aphakic monkeys. *Surv Ophthalmol* 1997;41:583-8.
- Sen HA, Campochiaro PA. Stimulation of cyclic adenosine monophosphate accumulation causes breakdown of the blood-retinal barrier. *Invest Ophthalmol Vis Sci* 1991;32:2006-10.
- Bito LZ. Prostaglandins. Old concepts and new perspectives (Editorial). *Arch Ophthalmol* 1987;105:1036-9.
- Miyake K, Shirasawa E, Hikita M. Active transport system of prostaglandins: clinical implications and considerations. *J Cataract Refract Surg* 1992;18:100-5.
- Miyake K, Shirasawa E, Hikita M. Hypotheses on the role of prostaglandins in the pathogenesis of epinephrine maculopathy and aphakic cystoid macular edema. In: Bito LJ, Stjernschantz J, eds. *The ocular effects of prostaglandins and other eicosanoids*. New York: Alan R Liss, 1989:265-76.

Factor V Leiden mutation in association with idiopathic intracranial hypertension

EDITOR.—Idiopathic intracranial hypertension has an association with prothrombotic conditions. The recently described thrombophilic defect of activated protein C (APC) resistance, caused by the factor V Leiden mutation, has been postulated to be a factor in some cases.¹ To the best of our knowledge, we describe the first two cases reported of the factor V Leiden mutation identified in association with idiopathic intracranial hypertension. Both patients had been previously well and there was no past history to suggest a clotting disorder.

CASE REPORTS

Case 1

A 20 year old obese white female presented to the ophthalmic department with transient obscurations of vision. She had not been taking the oral contraceptive pill. Snellen visual acuity was right eye 6/12, left eye 6/12 and gross papilloedema with macular stars was noted. Computerised tomography and

magnetic resonance angiography were normal and a lumbar puncture showed an opening pressure of 75 cm of water. CSF protein, glucose, and cell count were normal as were U&Es, LFTs, TFTs, glucose, full blood count, and plasma viscosity. She was started on 250 mg of Diamox four times daily and advised to lose weight. Over the next few days acuity reduced to right eye 6/24, left eye 3/60 with extensive field restriction. Urgent optic nerve fenestration of the left eye was undertaken followed by the right 12 days later as acuity began to worsen in this eye also. Partial recovery occurred with Snellen visual acuities of right eye 6/60, left eye 6/36 but, unfortunately, the extensive field restriction remained. On thrombophilia screening, the APC resistance ratio was reduced at 1.9 (normal 2.2-4.2) on two occasions and a heterozygous factor V Leiden mutation was identified. She was referred to the haematology department to consider anticoagulation which, on discussion, was not undertaken as she was thinking of planning a family.

Case 2

A 31 year old obese white female was referred by her general practitioner complaining of transient visual loss in her left eye for the previous 5 months and non-specific headaches for 2 years. She had stopped the oral contraceptive pill 5 years previously. Snellen visual acuity was right eye 6/5, left eye 6/5 and field analysis showed an enlarged blind spot in the left eye. Funduscopy revealed established papilloedema in the left eye and early papilloedema in the right. Urgent computerised tomography was normal and a lumbar puncture had an opening pressure of 37 cm of water. CSF and blood investigations were unremarkable. Visual acuity and fields remained stable on Diamox SR 250 mg twice daily and she has been able to lose weight from 15 stones. A thrombophilia screen showed a reduced APC resistance ratio of 1.9 on two occasions and a heterozygous factor V Leiden mutation was found. She was also referred to the haematology department for consideration of anticoagulation and, after discussion, was begun on warfarin.

COMMENT

Prothrombotic abnormalities have recently been implicated in the pathogenesis of "benign intracranial hypertension" (BIH).¹ It has been suggested that reduced CSF reabsorption due to damaged arachnoid villi, secondary to microthrombus formation, could be the cause of raised intracranial pressure. Arachnoid villi dysfunction causing BIH has also been postulated in SLE and may be the result of venulitis, aseptic meningitis, or immune complex deposition and, in the antiphospholipid syndrome, possibly due to micro-occlusion.² Such mechanisms affecting the optic nerves in addition could cause the poor outcome in case 1.

APC resistance is gaining greater recognition in the pathogenesis of ophthalmic disorders and has been implicated as a cause of central retinal vein occlusion in patients younger than 50 years.³ The factor V Leiden mutation may be heterozygous or homozygous and carries a lifelong increased thrombotic risk of 5-10 fold and 50-100 fold respectively.⁴ As 5% of the population has the factor V Leiden mutation,⁵ it is felt that most individuals carrying the defect will never experience a thrombotic event unless they carry another genetic defect, such as a deficiency of protein C or S,^{6,7} or are exposed

to a precipitating factor such as oral contraceptives, pregnancy, or surgery.^{8,9} Currently the criteria for anticoagulation in idiopathic intracranial hypertension are unknown owing to the absence of controlled clinical trials. It is reasonable for haematologists to offer warfarin as a short course or continuously in symptomatic patients, especially if the event is severe, and in those exposed to other risk factors who have a familial thrombotic tendency.

Without further studies addressing the association of idiopathic intracranial hypertension and thrombophilia, routine testing for the factor V Leiden mutation and other thrombophilic factors cannot be recommended in patients with idiopathic intracranial hypertension outside a clinical trial basis. However, if the mutation is found, referral should be made to a haematologist for advice concerning anticoagulation, bearing in mind the increased bleeding risk and teratogenicity of warfarin. First degree blood relatives of the patient should be warned to avoid smoking and to seek medical advice before taking oral contraceptives or accepting elective surgery: the factor V Leiden mutation is of dominant inheritance.¹⁰

O BACKHOUSE

Leeds General Infirmary, Leeds

T METCALFE

P GOULDING

M MCEVOY

M MENAGE

Harrogate District Hospital, Harrogate

Correspondence to: O Backhouse, Department of Ophthalmology, Leeds General Infirmary, Leeds, West Yorks LS2 9NS.

Accepted for publication 29 January 1998

- Sussman J, Leach M, Greaves M, et al. Potentially prothrombotic abnormalities of coagulation in benign intracranial hypertension. *J Neurol Neurosurg Psychiatry* 1997;62:229-33.
- Orefice G, De Joanna G, Coppola M, et al. Benign intracranial hypertension: a non-thrombotic complication of the primary antiphospholipid syndrome? *Lupus* 1995;4:324-6.
- Larsson J, Olafsdottir E, Bauer B. Activated protein C resistance in young adults with central retinal vein occlusion. *Br J Ophthalmol* 1996;80:200-2.
- Dahlback B. Physiological anticoagulation. Inherited resistance to activated protein C and venous thromboembolism. *J Clin Invest* 1994;94:923-7.
- Dahlback B, Carlsson M, Svensson P. Familial thrombophilia due to a previously unrecognized mechanism characterised by poor anticoagulant response to activated protein C. *Proc Natl Acad Sci USA* 1993;90:1004-8.
- Koeleman B, Reitsma P, Allaart C, et al. Activated protein C resistance as an additional risk factor for thrombosis and protein C-deficient families. *Blood* 1994;84:1031-5.
- Koelman B, van Rumpft D, Hamulyak K, et al. Factor V Leiden: an additional risk factor for thrombosis in protein S deficient families? *Thromb Haemost* 1995;74:580-3.
- Dahlback B. Inherited thrombophilia: resistance to activated protein C as a pathogenic factor for venous thromboembolism. *Blood* 1995;85:607-14.
- Vandenbroucke J, Koster T, Briet E, et al. Increased risk of venous thrombosis in oral contraceptive users who are carriers of factor V Leiden mutation. *Lancet* 1994;344:1453-7.
- Svensson P, Dahlback B. Resistance to activated protein C as a basis for venous thrombosis. *N Eng J Med* 1994;330:517-22.

Do all patients with CMV retinitis require life long anti-CMV therapy?

EDITOR.—It is becoming clear that some patients with cytomegalovirus (CMV) retinitis who respond to highly active antiretroviral therapy in terms of their CD4 count and reduced HIV viral load, undergo no further

reactivations of their retinitis despite having no specific anti-CMV therapy. However, the factors underlying this improved immunity to CMV are not entirely clear. We report the case of a patient on highly active antiretroviral therapy (HAART) who has had no reactivation of CMV retinitis after 6 months without anti-CMV treatment. The unusual feature of this case is that the CD4 count has remained persistently low.

We discuss factors that may be relevant in the improved immune response to CMV infection and may be useful in isolating a group of patients on HAART who do not require lifelong maintenance with anti-CMV therapy.

CASE REPORT

A 33 year old man with a CD4 count of 27 cells $\times 10^6/l$ who had been diagnosed with AIDS in 1992 developed CMV retinitis in zones 1, 2, and 3 of the left eye in March 1996.

Treatment was commenced with intravenous ganciclovir 10 mg/kg and maintenance therapy consisted of oral ganciclovir. After 3 months reactivation and progression of the retinitis necessitated a further induction course of intravenous ganciclovir with subsequent maintenance therapy with daily intravenous foscarnet.

Further reactivation led to the use of intravitreal ganciclovir and further re-induction course of intravenous foscarnet. As a result of difficulties with intravenous line sepsis intravenous zidovudine was commenced. In March 1997 the patient was started on HAART including protease therapy but despite this the CD4 count remained low at 22 cells $\times 10^6/l$.

The patient decided to discontinue anti-CMV therapy in April 1997 and has undergone frequent ophthalmological review since. He has received no anti-CMV therapy for 6 months and despite a continuing low CD4 count of 28 cells $\times 10^6/l$ and a HIV-1 viral load of 201 637 RNA copies/ml there has been no further reactivation of CMV retinitis.

COMMENT

Before the use of HAART, maintenance therapy with anti-CMV medication was required in all patients with CMV retinitis. Without therapy the average time to progression of retinitis was 2–3 weeks.¹

Several cases have been reported which describe lack of progression of CMV retinitis in patients treated with HAART and in each of these cases there was an associated rise in CD4 counts.^{2,3} There have also been reports of newly diagnosed CMV retinitis after commencement of HAART with improving CD4 counts,⁴ although considerable doubt has been shed on whether these were in fact new cases of CMV retinitis and not just reactivation of previously undetected disease.⁵ In this case the CD4 count remains persistently low and the HIV viral load high despite HAART.

This suggests that the immune response to CMV is not solely related to the CD4 count and that other factors are also involved in the recovery of immunity to CMV following treatment with HAART.

Bowen *et al* have demonstrated by quantitative and qualitative measurements of CMV DNA by polymerase chain reaction based assays that CMV viral load may be an indicator of patients at increased risk of reactivation of CMV retinitis.⁶ They suggest that this measurement can help with clinical manage-

ment. It has also been shown that the detection of the early CMV antigen (p65 antigen) suggests elevated susceptibility to CMV infection.⁷

Transforming growth factor β (TGF- β) inhibits the IL-2 induced proliferation of T lymphocytes, and expression of TGF- β may be increased in CMV infection.^{8,9} Measurement of TGF- β and other cytokines may also be useful in the monitoring of patients at risk of CMV disease.

By performing a controlled prospective trial involving measurement of CMV and HIV viral load, together with these immunological markers it may be possible to identify a subgroup of patients on HAART who do not require long term anti-CMV therapy.

However, early reports from Martin *et al* on the results of their study of the use of combined oral ganciclovir and intravitreal implant for treatment of CMV retinitis suggest that there is still a survival benefit from continued use of oral ganciclovir in the HAART environment.¹⁰

This once again raises the debate over whether CMV is just an opportunist taking advantage of immunosuppression or is it a cofactor acting in partnership with HIV.

WINIFRED NOLAN

Department of Ophthalmology, Chelsea and Westminster Hospital, London SW10 9NH

SUZANNE MITCHELL

St. Stephen's Centre, London SW10 9NH

Correspondence to: Miss Suzanne Mitchell, Chelsea and Westminster Hospital, 369 Fulham Road, London SW10 9TH.

Accepted for publication 29 January 1998

- Jabs DA, Enger C, Bartlett JG. Cytomegalovirus and acquired immunodeficiency syndrome. *Arch Ophthalmol* 1989;107:75–80.
- Whitcup SM, Fortin E, Nussenblatt RB, *et al*. Therapeutic effect of combination therapy in cytomegalovirus retinitis. *JAMA* 1997;277:1519.
- Uthayakumar S, Birtwhistle K, Dalton R, *et al*. Letter. *Lancet* 1997;350:588–9.
- Jacobson MA, Zegans M, Pavan PR, *et al*. Cytomegalovirus retinitis after initiation of highly active antiretroviral therapy. *Lancet* 1997;349:1443–5.
- Mitchell SM, Youle MS, Membrey WL, *et al*. Letter. *Lancet* 1997;350:588.
- Bowen EF, Wilson P, Cope A, *et al*. Cytomegalovirus retinitis in AIDS patients: influence of cytomegalovirus load on response to ganciclovir, time to recurrence and survival. *AIDS* 1996;10:1515–20.
- Weber B, Bram W, Cinati J Jr, *et al*. Humoral response to human cytomegalovirus infection: diagnostic potential of immunoglobulin class and IgG subclass antibody response to human cytomegalovirus early and late antigens. *Clinical Investigator* 1993;71:270–6.
- Haagmans BL, Teerds KJ, van den Eijnden-van Raaij AJM, *et al*. Transforming growth factor β production during rat cytomegalovirus infection. *J Gen Virol* 1997;78:205–13.
- Michelson S, Alcami J, Kim S-J, *et al*. Human cytomegalovirus infection induces transcription and secretion of transforming growth factor β 1. *J Virol* 1994;68:5730–7.
- Martin D, Kuppermann R, Wolitz A, *et al*. Abstract. 37th ICAAC conference: 1997: No 905.

Spontaneous and sustained resolution of CMV retinitis in patients receiving highly active antiretroviral therapy

EDITOR.—Cytomegalovirus (CMV) retinitis predominantly occurs in severely immunocompromised patients with CD4+ counts below 50 cells $\times 10^6/l$. Before the use of combinations of protease inhibitors and other antiretroviral agents, CMV retinitis invariably progressed in the absence of specific anti-

CMV therapy. This highly active antiretroviral therapy (HAART) can decrease human immunodeficiency virus (HIV) load and increase CD4 T cell counts in patients with AIDS.^{1,2} In this study we describe two patients receiving HAART, who present with probable inactive CMV retinitis although they never received anti-CMV therapy. In one of these patients, CMV retinitis recurred shortly after his CD4+ cell counts fell below 50 cells $\times 10^6/l$ despite continued combination antiretroviral therapy.

CASE REPORTS

Patient No 1

A 28 year old man with AIDS and a history of one positive blood culture for CMV and a CD4+ cell count of 13 cells $\times 10^6/l$ was placed on zidovudine, zalcitabine, and lamivudine in April 1996. Within 2 months the CD4+ cell count increased to 65 cells $\times 10^6/l$ and the patient developed blurred vision and floaters in his left eye. Examination of the left eye revealed mild vitritis and a large area of retinal atrophy with several small haemorrhages at the border. Examination of the right eye revealed mild vitritis and a large area of retinal atrophy with several small haemorrhages at the border, consistent with inactive CMV retinitis (Fig 1). The right eye was normal. He was placed on no anti-CMV therapy. The haemorrhages resolved and no new progression of the retinitis was observed.

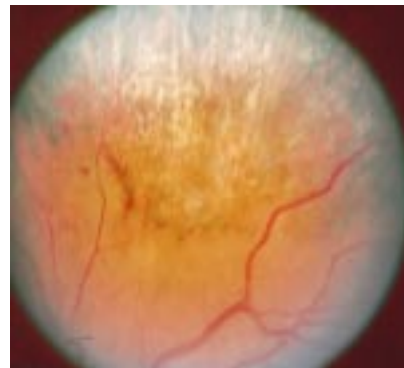


Figure 1 Retinal photograph of the left eye of patient no 1 showing a large area of retinal atrophy with a few retinal haemorrhages at the border.

In January 1997 the patient's CD4+ cell count fell to 21 cells $\times 10^6/l$ despite continued combination antiretroviral therapy. Eye examination revealed active CMV retinitis in the right eye; the retinal scar in the left eye remained unchanged. The patient was treated with intravenous ganciclovir and the CMV retinitis became inactive.

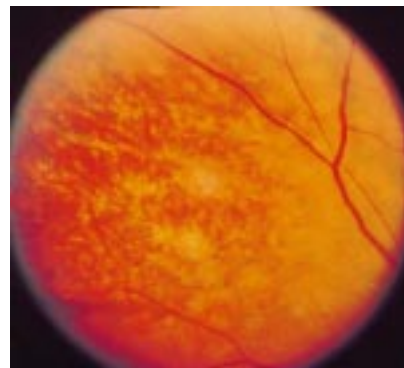


Figure 2 Retinal photograph of the left eye of patient no 2 showing an area of atrophic retina consistent with inactive CMV retinitis.

Patient No 2

A 44 year old white man with AIDS had a CD4+ cell count of 25 cells $\times 10^6/l$ and no evidence of CMV retinitis on serial eye examinations. Combination antiretroviral therapy with saquinavir, zidovudine, and lamivudine was begun in March 1996 and 1 month later the patient developed a temporal scotoma in his left eye. Examination of the left eye showed mild anterior uveitis, vitritis, and a large area of retinal atrophy in the nasal midperiphery consistent with inactive CMV retinitis (Fig 2). The area of inactive retinitis has remained stable over the past 12 months despite the fact that he has received no anti-CMV therapy. A CD4+ T cell count in October 1996 was 111 cells $\times 10^6/l$.

COMMENT

We describe two patients who presented with mild uveitis and an area of retinal atrophy consistent with inactive CMV retinitis despite never having received specific anti-CMV therapy. Both patients had prior CD4+ cell counts below 50 cells $\times 10^6/l$, and each experienced an elevation to above 50 cells $\times 10^6/l$ in response to combination antiretroviral therapy concurrent with the onset of their symptoms. We hypothesise that these patients developed subclinical CMV retinitis in the setting of severely suppressed CD4+ T cell counts, but became symptomatic when HAART induced elevations of their CD4+ cell counts enhanced the immune response to CMV. This led to the development of a significant and symptomatic uveitis, a finding uncommon in patients with CMV retinitis before the use of HAART. These observations support the notion that HAART induced restoration in immune function can lead to spontaneous and sustained resolution of CMV retinitis. The fact that patient no 1 developed reactivation of CMV retinitis soon after his CD4+ T lymphocyte count fell below 50 cells $\times 10^6/l$ supports the initial diagnosis of CMV retinitis. Additionally, CD4+ cell counts may continue to provide valuable information regarding the risk of reactivation of opportunistic infections in patients receiving HAART. These findings are in accordance with recent publications addressing the relation between protease inhibitors and sustained inactivity of CMV retinitis.^{3,4} Additional studies are required to further delineate the role of HAART and CD4+ cell counts in the natural history of CMV retinitis.

SCOTT M WHITCUP

National Eye Institute, National Institutes of Health,
Bethesda, MD, USA

EMMETT T CUNNINGHAM JR

Francis I Proctor Foundation for Research in
Ophthalmology, University of California,
San Francisco, CA, USA

MICHAEL A POLIS

National Institute of Allergy and Infectious Diseases,
National Institutes of Health, Bethesda, MD, USA

ERIC FORTIN

National Eye Institute, National Institutes of Health,
Bethesda, MD, USA

Correspondence to: Scott M Whitcup, MD,
National Eye Institute, 10 Center Drive, Bldg 10 Rm
10N 202, Bethesda, MD 20892-1858, USA.

Accepted for publication 29 January 1998

- Collier AC, Coombs RW, Schoenfeld DA, *et al.* Treatment of human immunodeficiency virus infection with saquinavir, zidovudine, and zalcitabine. *N Engl J Med* 1996;334:1011-17.
- Whitcup SM, Fortin E, Muccioli C, *et al.* Therapeutic effect of highly active antiretroviral therapy on cytomegalovirus retinitis. *JAMA* 1997;277:1519-20.
- Reed JB, Schwab IR, Gordon J, *et al.* Regression of cytomegalovirus retinitis associated with protease-inhibitor treatment in patients with AIDS. *Am J Ophthalmol* 1997;124:199-205.

Successful penetrating keratoplasty in an infant after extended storage of infantile donor cornea

EDITOR,—Despite the fact that infantile corneas are such a rare and valuable material in our eye banks they are not always properly utilised.

Infantile corneas, because of their characteristics (steepness, flexibility, elasticity), are not preferred for transplantation in emmetropic adults if other tissue is available.¹ On the other hand it has been suggested that for infants undergoing penetrating keratoplasty, donor and recipient age should be matched as closely as possible.² Such age matching however is not always possible in the existing corneal storage system.

According to the United Kingdom Transplant Support Services Authority (UKTSSA) statistics, in 1996 there were 15 recipients in the 0-5 age group. Forty four infantile corneas

were retrieved in the same period. Only five infantile recipients, however, received corneas from the same age group, while the other 10 received corneas from older donors, in some cases the age difference exceeded 50 years (Fig 1A). Of the available infantile corneas, apart from the five transplanted into infants, 17 were transplanted to recipients of various ages (11-40), and 22 were not used at all because they could not be allocated to suitable recipients within the required time (which for most eye banks is 4 weeks) or for other reasons such as inadequate endothelial cell density (Fig 1B).

CASE REPORT

Keratec Eye Bank recently obtained donor tissue from a child aged 13 months. After 22 days in culture one cornea was transplanted into a recipient aged 5 years. For the second cornea, however, no suitable recipient could be found, either through UKTSSA or Bio Implant Services (BIS, Eurotransplant). Rather than discard the tissue after the standard 4 weeks in culture we placed it into 75 ml of fresh medium in the hope of extending the preservation period until a suitable recipient could be found.

Within a few weeks a male infant aged 3 months with bilateral Peters' anomaly (Fig 2a,b) was referred to St George's Hospital for penetrating keratoplasty. The left penetrating keratoplasty was carried out with the infantile cornea which, at that time, had been

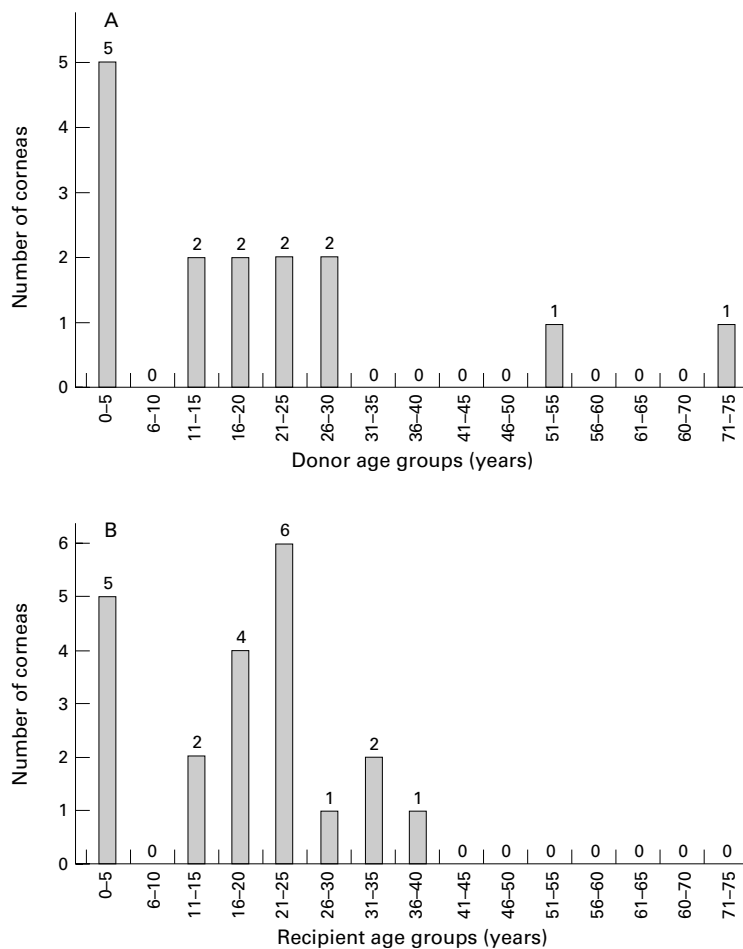


Figure 1 Matching the ages of donors and recipients. (A) Number of corneal transplants placed into recipients aged 0-5 in 1996, by age of donors. Total 15. (B) Utilisation of corneas from donors aged 0-5 in 1996, by age of recipient. Total 44 (22 not used, and one allocated to recipient of unknown age). Data from UKTSSA.

1 Perelson AS, Essunger P, Markowitz M, *et al.* HIV-1 dynamics in vivo: virion clearance rate, infected cell life-span, and viral generation time. *Science* 1996;271:1582-6.

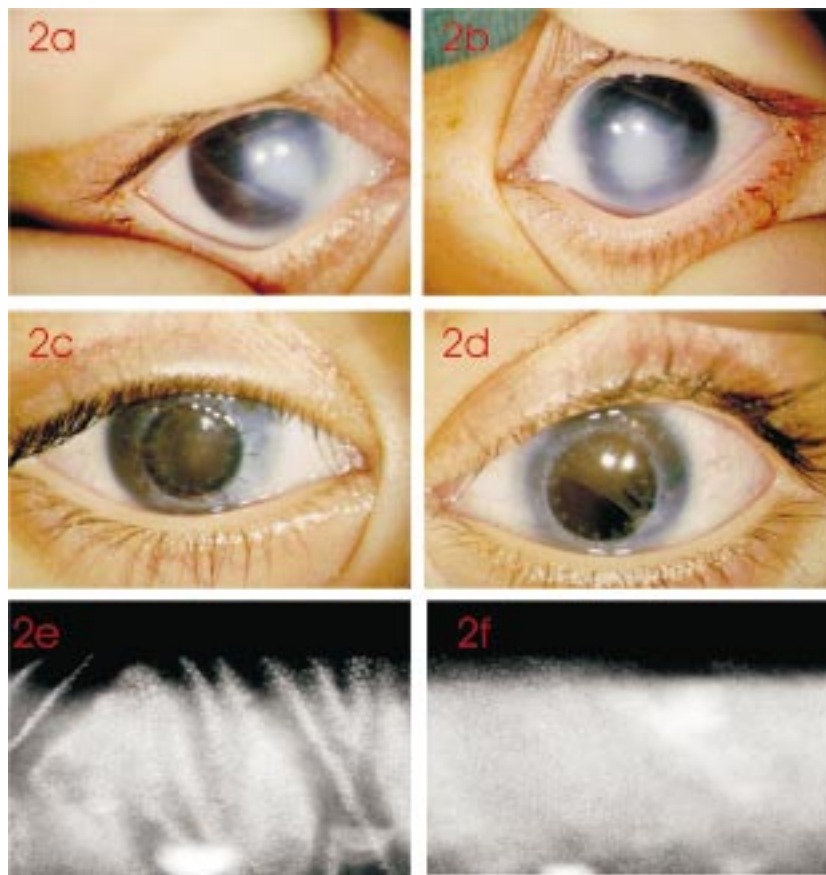


Figure 2 (a) Right eye, and (b) left eye of 3 month old infant with Peters' anomaly preoperatively. (c) Right eye 8 weeks after penetrating keratoplasty with cornea from 20 year old donor. (d) Left eye 9 weeks after penetrating keratoplasty with cornea from 13 month old donor preserved in organ culture for 9 weeks. (e) Contact specular microscopy of right eye 1 year postoperatively with cell density of 1410 cells/mm². (f) Contact specular microscopy of left eye 1 year postoperatively with cell density of 2235 cells/mm².

maintained in culture for 68 days (over 9 weeks), the final endothelial assessment, by vital staining and light microscopy, having confirmed its suitability for use. The right eye was operated on 1 week later using a cornea from a 25 year old donor as no infantile cornea was available.

At 2 months postoperatively at examination under anaesthesia both corneal grafts were clear (Fig 2c,d). Examination under anaesthesia was repeated 1 year later. Again both grafts were clear, and specular microscopy of the graft endothelium revealed a cell density of 2235 cells/mm² in the graft from the infantile donor, and 1410 cells/mm² in the graft from the older donor (Fig 2e,f). Retinoscopy showed high myopia in both eyes, but both fundi appeared normal.

COMMENT

In most eye banks organ cultured corneas that are not transplanted within 4–5 weeks of retrieval are discarded. This is based on the finding that the rate of decline of endothelial cell density increases after 35 days of culture in a single aliquot of culture medium.³

Pels *et al* reported that storage of corneas in culture for 3–7 weeks induced a mean cell loss of about 11% while preservation for 9–17 weeks (medium changed after 6 weeks), resulted in a mean cell loss of about 43%. The actual cell loss, however, varied significantly among examined corneas and therefore it has been suggested that the suitability of an individual cornea for transplantation should be based on the quality of the endothelium

during final assessment rather than the length of storage.⁴ It has also been suggested that the increased cell loss after 40 days of culture might be caused by the depletion of nutrients and accumulation of waste products in the culture medium. A larger volume of medium, or the renewal of the medium, may postpone or prevent this process. However, with prolonged organ culture endothelial survival is not the only factor in determining the suitability of tissue for transplantation. If there is epithelial overgrowth onto the posterior corneal surface this can potentially lead to problems of implantation of epithelial cells into the anterior chamber.

There has been a report of corneas safely preserved in culture for 7 weeks before transplantation,⁵ and we have found that an infantile cornea preserved for 9 weeks in organ culture can be transplanted successfully.

There is usually no need to extend the storage time of adult corneas, but it may be appropriate to extend the preservation time of some infantile corneas in order to maximise the chance of their most appropriate utilisation, and further research is needed to optimise storage methods and evaluate the cost/benefit of longer storage times.

EWA MORRIS

Keratec Eye Bank, St George's Hospital Medical School, London SW17 0RE

J ROB FULLER

CHAD K ROSTRON

St George's Hospital, London SW17 0QT

Correspondence to: Dr Rostron.

Accepted for publication 22 January 1998

- 1 Koenig SB. Myopic shift in refraction following penetrating keratoplasty with pediatric donor tissue. *Am J Ophthalmol* 1986;101:740.
- 2 Koenig SB, Graul E, Kaufman HE. Ocular refraction after penetrating keratoplasty with pediatric donor corneas. *Am J Ophthalmol* 1982; 94:534.
- 3 Pels E, Schuchard Y. Organ culture in Netherlands. In: Brightbill FS, ed. *Corneal surgery: theory, technique and tissue*. 2nd ed. St Louis: Mosby, 1993:622–31.
- 4 Pels E, Schuchard Y. The effects of high molecular weight dextran on the preservation of human corneas. *Cornea* 1984;5:3:219–27.
- 5 Frueh BE, Bohnke M. Corneal grafting of donor tissue preserved for longer than four weeks. *Cornea* 1994;13:102–3.

Choroidal melanoma in a patient with retinitis pigmentosa and Usher's syndrome

EDITOR,—Usher's syndrome is an autosomal recessive condition characterised by retinitis pigmentosa and hearing loss. It is the most common cause of combined blindness and deafness in the USA. Usher's syndrome has two well defined subtypes including type I and type II.¹ Type I has more severe and early onset findings.

CASE REPORT

A 59 year old woman with retinitis pigmentosa and type I Usher's syndrome developed blurred vision in the left eye over a 4 month period. The best corrected visual acuity was 20/50 in the right eye and 20/80 in the left eye. Anterior segment examination and intraocular pressures (16 mm Hg) were normal bilaterally. Ophthalmoscopic examination showed mild optic disc pallor, marked vascular attenuation, and retinal pigmentary changes in both eyes. Inferotemporally in the left eye, there was a 15 × 10 mm dome-shaped choroidal melanoma with a secondary retinal detachment affecting the inferior half of the fundus (Fig 1). There was no evidence of retinal invasion or seeding. A-scan and B-scan ultrasonography demonstrated a 5.0 mm thick choroidal mass with low to medium internal reflectivity, acoustic hollowness, and a secondary retinal detachment (Fig 2). Goldmann perimetry showed marked constriction of visual fields with only 5 degrees of central field remaining in both eyes. Electroretinographic testing under photopic and scotopic conditions revealed that the b-wave was isoelectric.

The patient was treated with iodine-125 plaque radiotherapy with tumour apex dose of 9000 cGy, base dose of 43 000 cGy, and optic disc dose of 3700 cGy. The tumour showed a

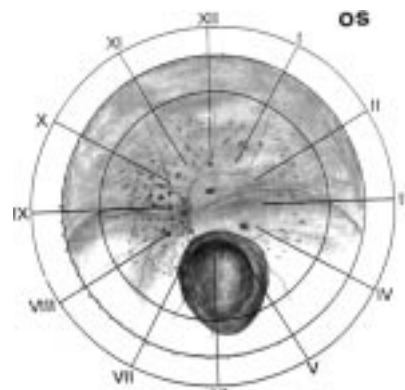


Figure 1 Fundus drawing showing spiculated retinal pigmentary changes and a choroidal melanoma with inferior hemiretinal serous detachment.

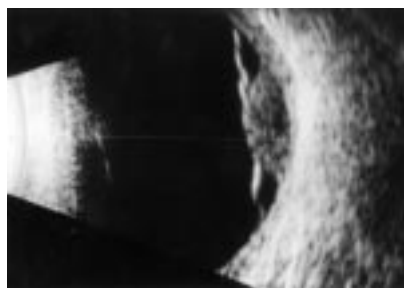

Figure 2 B-scan ultrasonogram showing an acoustically hollow choroidal mass with associated retinal detachment.

satisfactory response to radiation. At 10 months' follow up, the subretinal fluid dried up completely but radiation papillopathy developed. The papillopathy resolved over 5 months, leaving more optic disc pallor. At 22 months' follow up, the patient underwent cataract surgery with posterior chamber lens implantation in both eyes because of advanced posterior subcapsular cataract. At 40 months' follow up, the vision was hand movements in the right eye and tumour thickness was 2.8 mm. There was no radiation retinopathy or metastatic disease.

COMMENT

Abnormalities involving chromosomes 1 (type II), 11, and 14 (type I) have been observed in patients with Usher's syndrome.¹ Reported

chromosome alterations in uveal melanoma involve chromosomes 3, 6, 8, and 9²; therefore, the simultaneous occurrence of these two conditions, as in our patient, is probably coincidental.

The development of retinal detachment in a patient with retinitis pigmentosa is rare because of adhesions between the retinal pigment and sensory epithelium. Only a few cases of retinitis pigmentosa with retinal detachment have been reported.³ Our patient illustrates a non-rhegmatogenous retinal detachment with retinitis pigmentosa.

Our patient developed radiation papillopathy with an optic disc dose less than 5000 cGy, which is unusual.⁴ The atrophy/gliosis of the optic disc in retinitis pigmentosa might increase the susceptibility of the disc to irradiation. On the other hand, she did not develop radiation retinopathy despite a high dose of radiation to the retina. Perhaps the atrophic retina in retinitis pigmentosa was unable to elicit a radiation response.

Choroidal melanoma can rarely lead to a pseudoretinitis pigmentosa picture secondary to retinal invasion and dispersion of melanoma cells on the retina.⁵ Retinal invasion was not present in our patient and retinal pigmentary changes were noted in both eyes, ruling out pseudoretinitis pigmentosa.

Retinitis pigmentosa can be associated with several fundus tumours including giant drusen resembling astrocytoma and acquired vasoproliferative tumours.⁶ To our knowledge,

this is the first report of choroidal melanoma in a patient with retinitis pigmentosa.

Supported by the Paul Kayser International Award of Merit in Retina Research, Houston, TX (J Shields) and Eye Tumor Research Foundation, Philadelphia, PA, USA

The authors wish to thank Dr Andy Hay for referring the patient.

KAAN GÜNDÜZ
JERRY A SHIELDS
CAROL L SHIELDS
DA YOU ZHAO

Oncology Service, Wills Eye Hospital, Thomas Jefferson University, Philadelphia, PA, USA

Correspondence to: Jerry A Shields, MD, Director, Oncology Service, Wills Eye Hospital, 900 Walnut Street, Philadelphia, PA, 19107, USA.

Accepted for publication 29 January 1998

- 1 Smith RJ, Lee EC, Kimberling WJ, *et al.* Localization of two genes for Usher syndrome type I to chromosome 11. *Genomics* 1992;14:995-1002.
- 2 Singh AD, Wang MX, Donoso LA, *et al.* Genetic aspects of uveal melanoma: a brief review. *Semin Oncol* 1996;23:768-72.
- 3 Edwards RS, Calder IG, Crews SJ. Retinal detachment in retinitis pigmentosa. *Trans Ophthalmol Soc UK* 1985;104:315-8.
- 4 Lommatzsch PK, Alberti W, Lommatzsch R, *et al.* Radiation effects on the optic nerve observed after brachytherapy of choroidal melanomas with 106 Ru/106 Rh plaques. *Graefes Arch Clin Exp Ophthalmol* 1994;232:482-7.
- 5 Eagle RC Jr, Shields JA. Pseudoretinitis pigmentosa secondary to preretinal malignant melanoma cells. *Retina* 1982;2:51-5.
- 6 Shields CL, Shields JA, Barrett J, *et al.* Vasoproliferative tumors of the ocular fundus. Classification and clinical manifestations in 103 patients. *Arch Ophthalmol* 1995;113:615-23.