

## LETTERS TO THE EDITOR

### Vogt-Koyanagi-Harada disease masquerading anterior ischaemic optic neuropathy

EDITOR,—Vogt-Koyanagi-Harada (VKH) disease is a chronic panuveitis associated with poliosis, alopecia, vitiligo, dysacusia, and meningeal signs.<sup>1</sup> In VKH, optic disc involvement is not unusual and disc oedema is one of the hallmarks of the disease.<sup>2</sup> However, severe visual loss, altitudinal visual field defect, and sector filling defect on fluorescein angiography that suggest anterior ischaemic optic neuropathy (AION) are not usual presentations. We describe a case of VKH masquerading AION.

#### CASE REPORT

The patient was a 68 year old man who had decreased right visual acuity. He had systemic hypertension and multiple small brain infarction. On initial examination, the visual acuity was 20/50 in the right eye and 20/30 in the left. On the next day, his visual acuity declined to 20/100 in the right eye and 2/200 in the left. Slit lamp examination showed no signs of ocular inflammation but fundus examination revealed swelling of the both optic discs. Eight days later, keratic precipitates and cells in the anterior chamber were found. Multiple serous retinal detachments in the both eyes occurred on the 14th days. Enlargement of the Marriote blind spot and central scotoma were demonstrated by Goldmann visual field examination. Pleocytosis of the cerebrospinal fluid and human leucocyte antigen (HLA) type DR4 were

found. Computed tomography showed small infarctions in the bilateral basal ganglia and the pons.

Fluorescein angiography (FA) showed a wedge-shaped filling defect in the optic disc of the left eye in the early phase and later leakage of the dye from both optic discs (Fig 1A). On the day 8, bilateral hyperfluorescence in the posterior pole typical of VKH was observed. Indocyanine green (ICG) videoangiography showed filling delay of choroidal circulation.<sup>3</sup> Choroidal vessels were indistinct and speckled hypofluorescence on the diffuse background fluorescence was seen in the early to late phase (Fig 1B). Three months later, the fundus showed depigmentation typical of VKH. The visual function of the right eye showed some recovery but visual acuity in the left eye was 15/200 and no recovery in the visual field defect was observed.

#### COMMENT

In this case, at the early stage of disease, signs and symptoms suggestive of AION were found. Typical features of VKH emerged on later examinations. Although disc oedema is a common finding in VKH,<sup>2</sup> severe visual loss, sector filling defect, and visual field loss are unusual in VKH. Sector filling defect in the disc on FA and altitudinal visual field defect are more compatible with AION. Whether AION was caused independently of VKH or inflammatory cells in the choroid<sup>4</sup> caused circulatory disturbances is hard to determine because the patient was at high risk of circulatory disorders. But disturbed choroidal circulation by inflammatory cells in VKH<sup>5</sup> may support the latter idea. Indeed, Perry and Font<sup>6</sup> reported pathology of severe cases of VKH. In their cases, infiltration of the leptomeninges by lymphocytes and mild to moderate arachnoidal proliferation were found. Severe visual loss from optic nerve involvement in VKH is an important but not well documented complication of VKH.

ATSUSHI YOKOYAMA  
KOUICHI OHTA  
HIDENOBU KOJIMA  
NAGAHISA YOSHIMURA

Department of Ophthalmology, Shinshu University  
School of Medicine, Matsumoto, Japan

Correspondence to: Nagahisa Yoshimura, MD, Department of Ophthalmology, Shinshu University School of Medicine, Matsumoto 390-8621, Japan.  
Accepted for publication 11 September 1998

- 1 Beniz J, Forster D, Lean JS, *et al*. Variations in clinical features of the Vogt-Koyanagi-Harada syndrome. *Retina* 1991;11:275-80.
- 2 Rubsamen PE, Gass JDM. Vogt-Koyanagi-Harada syndrome. Clinical course, therapy, and long term visual outcome. *Arch Ophthalmol* 1991;109:682-7.
- 3 Oshima Y, Harino S, Hara Y, *et al*. Indocyanine green angiographic findings in Vogt-Koyanagi-Harada disease. *Am J Ophthalmol* 1996;122:56-66.
- 4 Kahn M, Pepose JS, Green WR, *et al*. Immunocytologic findings in a case of Vogt-Koyanagi-Harada syndrome. *Ophthalmology* 1993;100:1191-8.
- 5 Perry HD, Font R. Clinical and histopathological observations in severe Vogt-Koyanagi-Harada syndrome. *Am J Ophthalmol* 1977;83:242-54.

### Acute retinal necrosis after neonatal herpes encephalitis

EDITOR,—We read with interest the letter of Pavesio *et al* reporting acute retinal necrosis (ARN) in a 17 year old who had had neonatal herpes simplex virus (HSV) encephalitis.<sup>1</sup> We would like to report a patient who also had neonatal HSV encephalitis who had been

treated with parenteral aciclovir and developed ARN 16 years later.

#### CASE REPORT

A 16 year old white woman with a history of mental retardation and seizures as a result of neonatal HSV encephalitis presented with a 5 day history of her left eye being red and apparently uncomfortable. On presentation she was found to have moderate anterior chamber and vitreous inflammation and peripheral retinal necrosis in her left eye for 8 clock hours. There were no chorioretinal scars or optic atrophy indicating earlier infection. The right eye was normal. The diagnosis of ARN was made and she was treated with intravenous aciclovir. There was no history of any recurrent HSV and she was otherwise in good health. Her seizure disorder remained well controlled on her usual dose of carbamazepine.

After 6 days of treatment her retinitis was responding to parenteral aciclovir but she was found to have a small peripheral retinal detachment and a vitrectomy was performed. Polymerase chain reaction (PCR) was performed at the National Eye Institute on the vitreous biopsy and revealed the presence of HSV DNA.

#### COMMENT

Both our patient and the patient reported by Pavesio *et al*<sup>1</sup> developed ARN at about the same age, but it will take a larger series to know whether this is significant. Thompson *et al* reported two patients with neonatal and infantile central nervous system (CNS) HSV infections who developed ARN at ages 10 and 4, respectively.<sup>2</sup> A 30 year old woman with ARN who first had intraocular inflammation in her mid-twenties and who may have had neonatal HSV encephalitis has also been reported.<sup>3</sup>

The role of long term prophylaxis with aciclovir in children who had herpetic encephalitis as suggested by Pavesio *et al*,<sup>1</sup> is an important issue. Prophylaxis could be considered after HSV encephalitis to prevent ARN or after ARN to prevent second eye involvement. Aciclovir used as prophylaxis for recurrent genital HSV infection in adults for 5 or more years has been associated with minimal toxicity and the selection of resistant strains has not been demonstrated,<sup>4,5</sup> but there is little experience with the duration of prophylaxis that would have been necessary to prevent ARN in our patients. The presence or absence of earlier ocular involvement may not be a good indication of the need for long term prophylaxis to prevent ARN after HSV encephalitis as has been suggested.<sup>1</sup> One child reported by Thompson *et al* had recurrent presumed cutaneous herpes and the other had chorioretinal scars,<sup>2</sup> and the patient reported by Pavesio *et al* had optic atrophy before the diagnosis of ARN.<sup>1</sup> Our patient had no apparent previous ocular findings nor has she had any other recurrent HSV disease, although small lesions in the periphery may have been obscured by the active retinitis. Whether such findings are indicative of an increased risk of the development of ARN cannot be determined from isolated case reports.

Second eye involvement in ARN is not uncommon.<sup>6</sup> Although Palay *et al* reported that treatment of ARN with aciclovir does decrease second eye involvement in the short term in an adult population with most cases likely to be from varicella zoster virus, they did not recommend long term prophylaxis.<sup>6</sup> Like

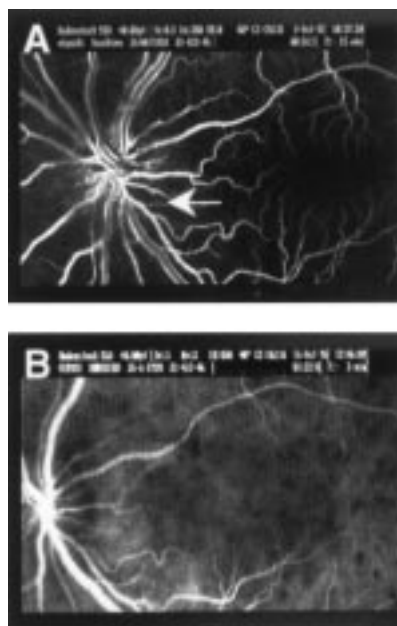


Figure 1 (A) Fluorescein angiography of the left eye. A wedge-shaped filling defect was found in the optic disc (arrow). (B) Indocyanine green angiography of the left eye. Indistinct choroidal vessels and speckled hypofluorescence on the diffuse background fluorescence were found.

Pavesio *et al*<sup>1</sup> we have chosen to continue oral aciclovir as long term prophylaxis against second eye involvement, but more data are needed to guide us in the appropriate management of these patients.

RALPH D LEVINSON  
ROBERT REIDY  
MARK T CHIU

*Retina and Uveitis Services, Eye Associates of New Mexico and Southwest Colorado*

Correspondence to: Ralph Levinson, MD, Eye Associates of New Mexico and Southwest Colorado, 806 Martin Luther King Jr Avenue NE, Albuquerque, NM 87102, USA.

Accepted for publication 22 September 1998

- 1 Pavesio CE, Conrad DK, McCluskey PJ, *et al*. Delayed acute retinal necrosis after herpetic encephalitis. *Br J Ophthalmol* 1997;**81**:415-16.
- 2 Thompson WS, Culbertson WW, Smiddy WE, *et al*. Acute retinal necrosis caused by reactivation of herpes simple virus type 2. *Am J Ophthalmol* 1994;**118**:205-11.
- 3 el-Azazi M, Samuelsson A, Linde A, *et al*. Intrathecal antibody production against viruses of the herpesvirus family in the acute retinal necrosis syndrome. *Am J Ophthalmol* 1991;**112**:76-82.
- 4 Goldberg LH, Kaufman R, Kurtz TO, *et al*. Long-term suppression of recurrent genital herpes with acyclovir. *Arch Dermatol* 1993;**129**:582-7.
- 5 Fife KH, Crumpacker CS, Mertz GJ, *et al*. Recurrence and resistance patterns of herpes simplex virus following cessation of > or = 6 years of chronic suppression with acyclovir. Acyclovir Study Group. *J Infect Dis* 1994;**169**:1338-41.
- 6 Palay DA, Sternberg P, Davis J, *et al*. Decrease in the risk of bilateral acute retinal necrosis by acyclovir therapy. *Am J Ophthalmol* 1991;**112**:250-5.

### Retinoschisis associated with disc coloboma

EDITOR.—Among a variety of optic disc anomalies, colobomas and optic nerve pits are known to be closely related.<sup>1</sup> Previous studies<sup>2</sup> have shown that retinal detachment in eyes with choroidal coloboma is often caused by retinal breaks within the coloboma. However, the pathogenesis of non-rhegmatogenous retinal detachment correlating with optic disc coloboma has not been well defined. Here, we report a case of optic disc and choroidal coloboma associated with an unusual form of macular detachment complicated by retinoschisis.

#### CASE REPORT

A 35 year old Japanese woman complaining of blurred vision in the left eye was referred to

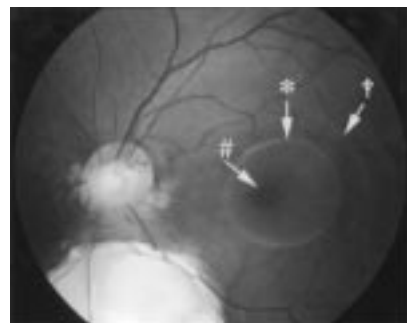

Figure 1 Fundus photograph of the left eye showing dome-shaped macular detachment (\*) with an outer lamellar macular hole with irregular margins (#) surrounded by a schisis-like separation between the inner and outer retina (+). Note the optic and adjacent choroidal coloboma.

Kyorin University Hospital on 1 October 1996. Her best corrected visual acuity was 20/20 in the right eye and 20/200 in the left. Indirect ophthalmoscopy of the left eye revealed a serous macular detachment associated with an apparent macular hole with irregular margins (Fig 1). Slit lamp fundus biomicroscopy with a +90 D preset lens disclosed a serous detachment of macula with a schisis-like separation between the inner and outer retina and an outer lamellar macular hole. The macular hole appearing to be of full thickness under indirect ophthalmoscopy was determined to be a lamellar hole of the outer retina. Posterior vitreous detachment was not present. Scanning laser ophthalmoscopy (SLO) using argon laser also showed the inner retinal layer covering the detached outer layer, creating a double ring appearance. Fluorescein angiography (FA) confirmed hypofluorescence of the disc coloboma during its early phase but revealed hyperfluorescence during the late phase with no leakage from the retinal vessels. The region with retinoschisis and retinal detachment did not demonstrate hyperfluorescence at any phase (Fig 2).

#### COMMENT

Disc colobomas and optic nerve pits are often complicated with sensory macular retinal detachment, but their symptoms rarely become significant before the age of 20.<sup>3</sup> Based on a review of 15 patients with optic nerve pits and maculopathy, Lincoff and associates<sup>4</sup> suggested that the retinal elevation is most often due to communication between the optic nerve pit and a schisis-like separation of the inner and outer retinal layers and that a full thickness macular retinal detachment may occur secondarily and in association with an outer lamellar macular hole. This finding was recently confirmed by optical coherence tomography (OCT).<sup>5</sup> In addition, OCT suggests that the formation of an outer lamellar macular hole may be secondary to chronic cystoid macular oedema. To our knowledge, however, this mechanism has not been identi-

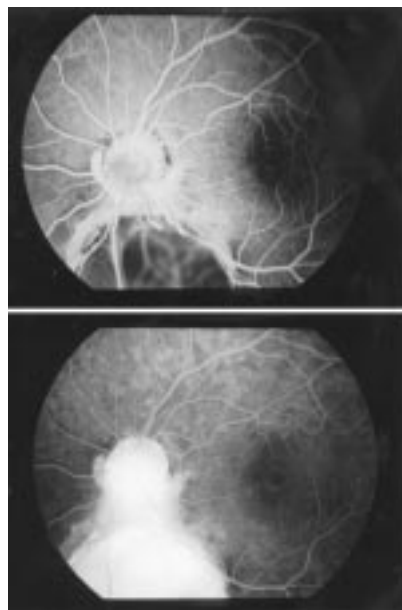


Figure 2 Fluorescein angiogram of the left eye showing early (top) and late (bottom) hyperfluorescence of the disc and choroidal coloboma. Note the lack of hyperfluorescence in the macular region.

fied in eyes with optic disc coloboma. Lincoff *et al* suggested that in eyes with a maculopathy associated with optic disc pits, the fluid from the pits entering the disc elevates the nerve fibre layer, causing a schisis-like separation of the inner retinal layers. Even though FA of the present case did not show the origin of subretinal fluid, we were able to confirm our diagnosis of retinoschisis and lamellar macular hole based on fundus examinations including SLO and FA, which clearly revealed an elevated inner layer connected to the disc coloboma. These findings are very similar to those of Lincoff *et al*'s cases demonstrating an irregular and partial thickness macular hole and schisis with an outer layer detachment which does not extend to the optic disc. Non-rhegmatogenous retinal detachment may occur in association with disc colobomas. We believe that the pathogenesis of the schisis-like separation identified in optic nerve pits and optic disc colobomas may be similar.

KAZUKI HOTTA  
AKITO HIRAKATA  
TETSUO HIDA

*Department of Ophthalmology, Kyorin University School of Medicine, Tokyo, Japan*

Correspondence to: Kazuki Hotta, MD, Department of Ophthalmology, Kyorin University School of Medicine, 6-20-2 Shinkawa, Mitaka, Tokyo 181, Japan.

Accepted for publication 30 July 1998

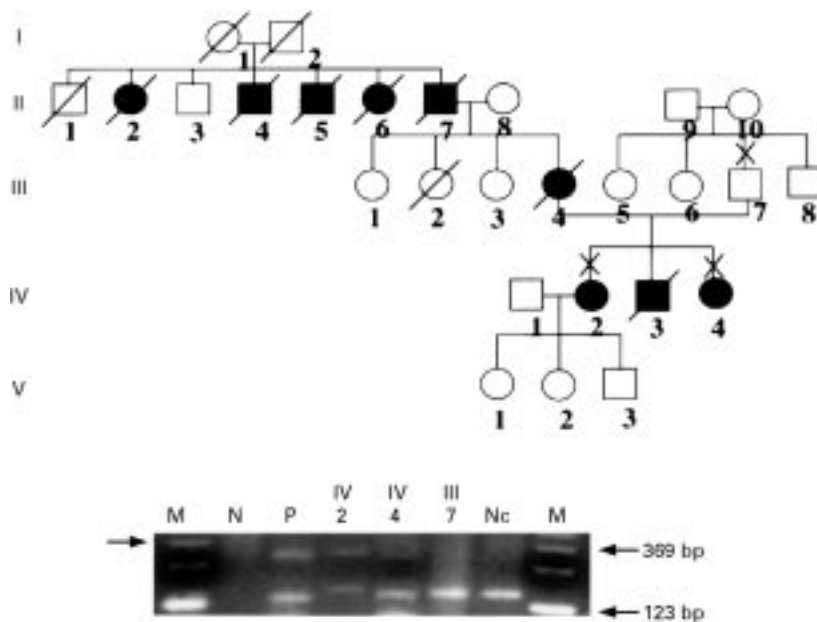
- 1 Sugar HS. Congenital pits of the optic discs and their equivalents (congenital colobomas and coloboma-like excavations) associated with submacular fluid. *Am J Ophthalmol* 1967;**63**:298-307.
- 2 Wang K, Hilton GF. Retinal detachment associated with coloboma of the choroid. *Trans Am Ophthalmol Soc* 1985;**83**:49-62.
- 3 Shatz H, McDonald HR. Treatment of sensory retinal detachment associated with optic nerve pit or coloboma. *Ophthalmology* 1988;**95**:178-86.
- 4 Lincoff H, Lopez R, Kreissig I, *et al*. Retinoschisis associated with optic nerve pits. *Arch Ophthalmol* 1988;**106**:61-7.
- 5 Rutledge BK, Puliafito CA, Duker JS, *et al*. Optical coherence tomography of macular lesions associated with optic nerve head pits. *Ophthalmology* 1996;**103**:1047-53.

### Corneal endothelial changes and trinucleotide repeat expansion of DRPLA gene

EDITOR.—Dentatorubral and pallidolusian atrophy (DRPLA) is an autosomal dominant disorder that manifests in a combination of chorea, myoclonus, seizure, ataxia, and dementia. It is caused by the unstable expansion of a CAG trinucleotide repeat coding for glutamine in the DRPLA gene.<sup>1</sup> Several other genes with an unstable trinucleotide repeat expansion of CAG were cloned in some types of spinocerebellar degeneration (SCD). Several reports have also suggested an association between ocular changes and SCD.<sup>2,3</sup> We report here the association of ocular changes in patients with an expanded allele of the trinucleotide repeat of the DRPLA gene.

#### CASE REPORTS

A 46 year old woman (IV-2 in Fig 1) noticed gait disturbance and truncal ataxia at age 36 years. When we visited her, her general condition was very severe, and visual acuities were not examined. Pupils, ocular media, and fundus examination showed normal findings. Corneal endothelial cell density was 762 cells/mm<sup>2</sup> right eye and 540 cells/mm<sup>2</sup> left eye by specular microscopy (Fig 2). DNA



**Figure 1** Pedigree of the family with spinocerebellar degeneration and trinucleotide examination of DRPLA gene showing generations (roman numerals) of affected (solid symbols) and unaffected (open symbols) members. Squares indicate male members; circles, female; X, examined; and slash, deceased. The results of PCR showed that the affected patients (IV-2 and IV-4) had expanded allele of DRPLA gene, when they were compared with an unaffected family member (III-7) or normal healthy control (Nc). Primers used for amplification of the gene were described elsewhere.<sup>4</sup> N is a negative control without DNA and P is a positive control as we previously reported.<sup>4</sup> M is a marker of 123 base pair. The arrow in the left margin indicates the larger bands due to expanded allele of the DRPLA gene.

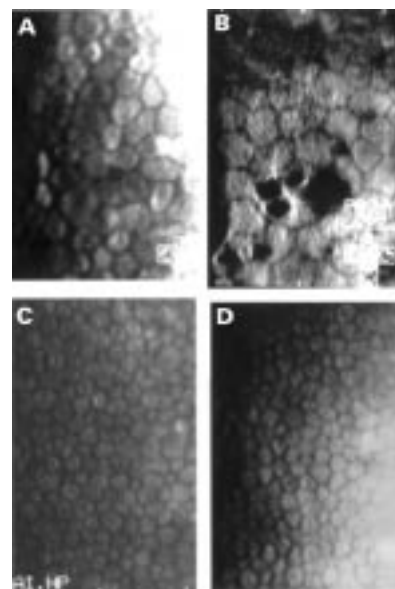
analysis from peripheral lymphocytes revealed that she had an expanded allele of the DRPLA gene with a normal allele (expanded/normal allele; 67/20), which was estimated by a fluorescein isothiocyanate (FITC) labelled primer used for polymerase chain reaction (PCR) amplification, according to our previous methods.<sup>4</sup>

A 39 year old woman (IV-4 in Fig 1) noticed truncal ataxia at age 36 years, and the symptoms have gradually increased. When she consulted us her visual acuity was 1.0 in both eyes. Pupillary reactions, intraocular pressures, ocular media, and fundus examination results; Humphrey visual field analysis; Ishihara colour vision; and ERG examination findings were normal. Corneal endothelial cell density was 951 cells/mm<sup>2</sup> right eye and 866 cells/mm<sup>2</sup> left eye by specular microscopy (Fig 2). DNA analysis from peripheral lymphocytes revealed that she had an expanded allele of the DRPLA gene with a normal allele (expanded/normal allele; 66/19).

#### COMMENT

Neither patients had a history of trauma, inflammation, or surgery of the eye. The difference in corneal endothelial cell density was statistically significant, compared with that in

healthy members of the family; in patients with Machado-Joseph disease, who have a trinucleotide repeat expansion allele with a normal repeat allele of the Machado-Joseph disease gene; and in age matched normal healthy controls in our clinic ( $p=0.004$ , unpaired  $t$  test) (data not shown).<sup>5</sup> The enlargement of the cell may be generated by a cytopathological condition of the cell due to an impropriety function of the DRPLA protein (termed atrophin-1), which may be expressed in corneal endothelial cells or adjacent cells. Previously, decreased corneal endothelial cell density, optic atrophy, and mild attenuation of oscillatory potentials observed on ERG in patients with spinocerebellar degeneration with trinucleotide expansion of spinocerebellar ataxia type 1 (SCA1) gene have been reported.<sup>3</sup> However, our patients showed only decreased corneal endothelial cell density and were free of other ocular changes. Although we will continue to follow these patients for other ocular symptoms, our patient IV-2 has had a long history of the disease (10 years), and we believe that the findings are specific to the mutation of the DRPLA gene. We will also examine other families with the mutation of the DRPLA gene to exclude of the possibility of corneal endothelial dystrophy.



**Figure 2** Specular microscopy reveals that patients with the mutated allele of DRPLA gene show severely decreased cell density in the corneal endothelium. Endothelial photographs of (A) patient IV-4 in Figure 1; (B) patient IV-2 in Figure 1; (C) family member III-7 in Figure 1 (2724 cells/mm<sup>2</sup>); and (D) a patient with Machado-Joseph disease who has a trinucleotide expansion allele with a normal repeat allele of the Machado-Joseph disease gene (2814 cells/mm<sup>2</sup>). Actual cell densities are reported in the text.

We thank Ms Maxine A Gere for correcting the manuscript.

TOSHIAKI ABE  
NORHIRO YAMADA  
KOJI ABE  
MAKOTO TAMAI

Department of Ophthalmology and Neurology,  
Tohoku University School of Medicine, Japan

Correspondence to: Dr Abe, Department of Ophthalmology, Tohoku University School of Medicine, 1-1 Seiryomachi, Aobaku, Sendai, Miyagi 980, Japan.

Accepted for publication 18 August 1998

- 1 Koide R, Ikeuchi T, Onodera O, *et al*. Unstable expansion of CAG repeat in hereditary dentatorubral-pallidolusian atrophy (DRPLA). *Nature Genet* 1994;6:9-13.
- 2 de Jong PIVM, de Jong JGY, de Jong-Ten Doeschate JMM, *et al*. Olivopontocerebellar atrophy with visual disturbances: an ophthalmic investigation into four generations. *Ophthalmology* 1980;87:793-804.
- 3 Abe T, Abe K, Aoki M, *et al*. Ocular changes in patients with spinocerebellar degeneration and repeated trinucleotide expansion of spinocerebellar ataxia type 1 gene. *Arch Ophthalmol* 1997; 115:231-6.
- 4 Aoki M, Abe K, Kameya T, *et al*. Maternal anticipation of DRPLA. *Hum Mol Genet* 1994;3: 1197-8.
- 5 Abe T, Nakazawa M, Kimizuka Y, *et al*. Factors influencing endothelial damage of the cornea in diabetic patients. *Atarashii Ganka* 1990;7:1647-51.