

# Full text reading with a central scotoma: pseudo regressions and pseudo line losses

Avinoam B Safran, Florence Duret, Marc Issenhuth, Christophe Mermoud

## Abstract

**Aims**—To investigate the reading strategy of a patient with central scotoma, using several preferred retinal loci (PRL).

**Methods**—A 47 year old man with Stargardt's disease was asked to decipher texts projected onto his retina using a scanning laser ophthalmoscope. A recording of the fundus image, on which the projected texts were superimposed, was analysed frame by frame.

**Results**—The subject used a combination of three PRL, located above the scotoma and laterally to the left and right of it. He first used his left PRL to search for the beginning of a line, then switched to his right PRL, thus performing an apparent regression which was called "pseudo regression", to read the line with successive rightward saccades. To decipher a particularly difficult word, he switched to his upper PRL, showing an apparent line loss which was called ("pseudo line loss"), and then used his three PRL in combination.

**Conclusion**—The patient used a complex, well structured reading strategy. These data showed that backward saccades and unexpected line losses, hitherto thought to be inappropriate and uneconomical, may in fact represent purposeful changes of PRL. It is thought that this is the first structured reading behaviour ever identified in such a condition. Such adaptive oculomotor behaviour should be taken into account when considering rehabilitation procedures.

(Br J Ophthalmol 1999;83:1341–1347)

Patients with a macular scotoma often develop a single, strongly preferred retinal locus (PRL), used to perform tasks requiring fixation, as for reading. It is commonly located in an area adjacent to the scotoma, in the lower and left part of the visual field.<sup>1–6</sup> However, there appears to be no simple rule by which it is selected. It has recently been shown that two different loci may be used, according to the size<sup>5,7</sup> or illumination<sup>8</sup> of the target.

In a previous study using a scanning laser ophthalmoscope (SLO), we found that two affected patients with macular disorders can use several PRL in a structured combination when deciphering single words, each PRL having a specific function.<sup>9</sup> In the present study, we conducted a detailed reading analysis in one of these patients, by projecting full texts onto his retina using an SLO. We showed that a combination of three PRL was used, both to

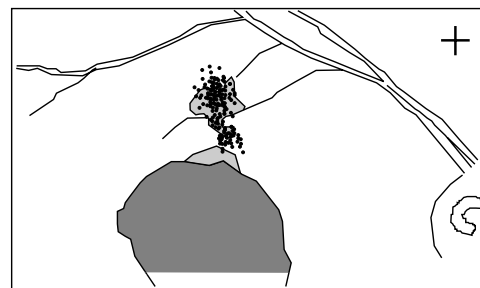decipher single words and to read full texts. However, the functions of the PRL changed according to reading conditions.

This is the first time, to our knowledge, that a complex, well structured reading strategy, adapted to the presence of a central scotoma has been identified. Our observations have shown that certain movements, hitherto thought to be inappropriate and uneconomical, may actually reflect purposeful changes in the fixation mode. We also demonstrated the value of our methodological approach in understanding the oculomotor behaviour by patients with a central scotoma.

## Subject and method

We studied a 47 year old man with bilateral central scotoma caused by Stargardt's disease. The condition had been diagnosed at the age of 16. Visual acuity was 16/200 in each eye. In everyday life the subject used monocular reading aids, choosing preferentially his right eye, which therefore we tested. His visual field defect was evaluated using the microperimetry software of an SLO made by Rodenstock (Munich, Germany) (Fig 1). The figure shows the direct ophthalmoscopic image of the retina of the right eye, with superposition of the scotoma, delineated using SLO scotometry.

In a previous SLO study<sup>9</sup> we found that this subject used a combination of three PRL to read single words. They were located above, to the left, and to the right of the lesion (Fig 2). To read single words, the upper PRL was consistently used in association with one or both of the other PRL. When using the upper PRL, the whole word was projected beyond the scotoma borders, whereas when using the left or right



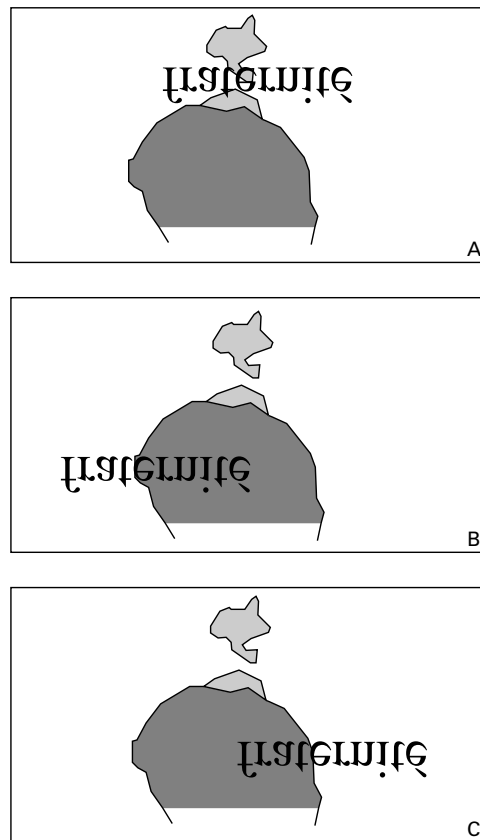
**Figure 1** Retinal fixation area and delineation of visual field defect, obtained during a microperimetry evaluation performed using the SLO. Visual field defect delineated with the Goldmann IV size target is shown in dark grey, and that delineated with the Goldmann II size target is shown in light grey. Locations of the centre of the fixation cross recorded at each presentation of the Goldmann targets are shown by dots. The shape and relative size of the fixation cross are shown in the top right hand corner of the figures. The illustration shows the direct ophthalmoscopic image of the retina of the right eye, with superposition of the scotoma, delineated using SLO scotometry.

Ophthalmology Clinic,  
Geneva University  
Hospitals, Geneva,  
Switzerland

A B Safran  
F Duret  
M Issenhuth  
C Mermoud

Correspondence to:  
Avinoam B Safran, MD,  
Ophthalmology Clinic,  
Geneva University Hospitals,  
CH-1211, Geneva 14,  
Switzerland

Accepted for publication  
19 July 1999



*Figure 2* Locations of the three PRL used when deciphering a single word. An association of three PRL was consistently used to decipher a single word. (A) When using the upper PRL, the whole word was projected beyond the deep scotoma borders. (B) When using the left PRL, only the first letters of the word were outside the scotoma borders. This PRL provided a higher spatial discrimination than the upper PRL. (C) When using the right PRL, only the last letters of the word were outside the scotoma borders. This PRL gave a higher spatial discrimination than the upper PRL.

PRL only the first or last letters of the word, respectively, were outside the scotoma area. The upper PRL provided global recognition of a single word, whereas each lateral PRL offered better discrimination but a more limited field of view. The upper PRL was used predominantly, and was always used for the initial fixation of a word. When switching from one lateral PRL to the other, the subject transiently projected the word onto the upper PRL two out of three times. Then, during monitoring of the fixation pattern using the SLO and a verbal interaction with the examiner, the patient could become aware of his use of several areas of the visual field to decipher a word. Eventually, he could localise these areas in relation to his scotomas and describe the specific functions of each PRL. Thus, the results of the patient's own analysis of his reading strategies corroborated our previous findings, based on the analysis of our video recordings.

In the present study, we evaluated the combined use of these PRL when reading a full text, using the SLO with a specific program developed in our laboratory for projecting targets onto the ocular fundus.

During the examination procedure, a column of 16 lines of text, with an average of 22 characters per line, was projected into the subject's right eye, using the SLO. The letters were 0.9 degrees high, a size similar to that used by the subject in everyday life to read fluently. The font was Times New Roman. The patient was asked to read aloud the projected texts. The superimposed images of the fundus and the projected targets were displayed on a computer screen and were video recorded at a frequency of 25 Hz, using a U-matic magnetoscope. Verbal comments of the patient were also recorded.

The examination recording was analysed frame by frame as follows. A sketch of the fundus, with the border of the scotoma, the optic disc, and the main vessels was outlined on a sheet of transparent paper. Then, for each successive frame of the video recording, the position of the projected text relative to the fundus structures was plotted on the paper.

Our research conformed to the Declaration of Helsinki. The subject gave his informed consent to the test procedures, and approval was obtained from the appropriate human experimentation committee.

## Results

The subject used three PRL in association to read full texts. The same reading pattern was used consistently for all the texts projected onto his retina, and was as follows.

During left to right reading, the subject reads along the line using his right PRL, by performing successive rightward saccades. Each saccade displaced the right PRL forward over a distance of 2–10 characters (mean 5.4;  $n = 39$ ) (Figs 3.5–8; 3.11–12; 3.15–17; 3.22–23; 3.28–29; 3.31–32; 3.33–35). At the end of a line of text, the subject located the beginning of the next line using retinal areas peripheral to his left PRL. He then performed one to three saccades to the left, to position his left PRL at the beginning of the new line; these saccades were occasionally hypometric (Figs 3.2–4) or hypermetric (Figs 3.20–21), requiring an additional saccade to reach the beginning of the line. In this position, 0–5 letters were projected beyond the left border of the scotoma. Once the left PRL was positioned at the beginning of the new line of text, the subject switched fixation to his right PRL, to carry on reading the line. When switching from the left to the right PRL, the right PRL was positioned on the text at the exact location where the left PRL had been. This switch was performed by a leftward saccade, which looked like a regressive saccade. We called this movement a “pseudo regression” (Figs 3.4–5; 3.21–22; 3.30–31). Such saccades were occasionally hypometric (Figs 3.14–15).

In contrast, when confronted with a line segment that was difficult to decipher—that is, when the subject could not read it fluently or stumbled on a word, he used his three PRL in association to scrutinise the segment (Figs 3.8–10; 3.23–26). When switching back and forth from a lateral PRL to the upper PRL, he performed oblique movements (Figs 3.9–10;





Figure 3 Combined use of the three PRL when reading a full text. The superposition of the text and the fundus image with corresponding scotoma borders, is shown when reading a full text. Reading a line of text, using the right PRL and successive rightward saccades, is demonstrated in pictures 5–8, 11–12, 15–17, 22–23, 28–29, 31–32, 33–35. The pattern used to reach and start reading the next line, using first the left PRL, then the right PRL, with “pseudo regressions”, is shown in pictures 4–5, 21–22, and 30–31. Finally, scrutinising difficult segments of the text, using the three PRL in association, with “pseudo line losses”, is shown in pictures 8–10, 17–18, and 23–28. The arrows indicate the location of the PRL presumably being employed. The line being read is shown darker than the other lines. The texts and retina are shown as they appeared in the image presented on the SLO video screen, upon where the scotoma read were superimposed. Please note that, on the SLO image, the text begins at the lower left side of the figure and ends in the upper right corner. Inverting the image shown in the figure using a mirror allows the text and the presented reading strategies to be viewed normally.

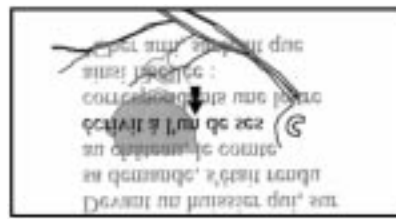Figure 3 (continued)




3.10–11; 3.25–26; 3.27–28), which could be mistaken for line losses; we therefore called this phenomenon “pseudo line losses”. Moreover, when the subject switched from his right PRL to his left one (Figs 3.8–9; 3.17–18; 3.23–24), he performed rightward saccades, simulating

progressions. We therefore called this movement a “pseudo progression”. In addition, the subject occasionally performed leftward saccades that were real regressions—that is, bringing the same PRL backwards along the line (Fig 3.32–33).

Figure 3 (continued)



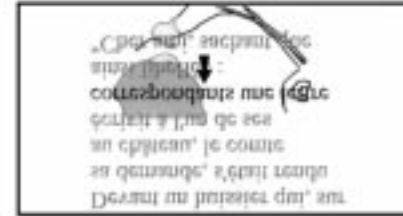
25



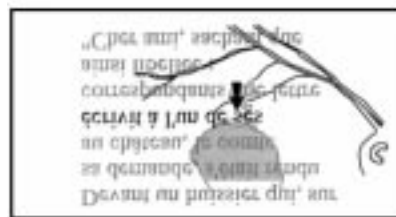31



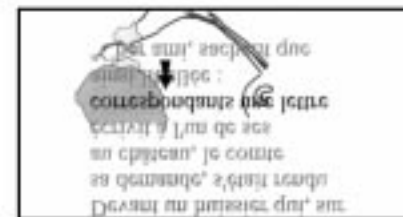
26




32




27




33




28




34



29



35



30

**Discussion**

In this study, we showed that a subject with a central scotoma can read full texts using multiple PRL in a structured pattern. Two reading strategies were observed in combination: one

for fluent reading and the other for scrutinising a difficult segment in a line of text.

The fluent reading strategy consisted of two stages: the first for left to right reading of the line of text, and the second for starting to read

the beginning of the next line. To read a line from left to right, the subject consistently used his right PRL. Thus, while his visual span was limited by the scotoma to the left of his fixation point, he could take advantage of his right visual span to process left to right reading. In contrast, to locate the beginning of the next line, the subject consistently used his left PRL. Thus, while his visual span was limited to the right of his fixation point, he could take advantage of his left visual span. These findings are in accordance with previous observations of reading disturbances in patients with homonymous hemianopia: left sided field loss gave reduced visual span to the left of the fixation point, and impaired leftward eye movement to reach the beginning of a line, whereas right sided field loss gave reduced visual span to the right, associated with reduced amplitude of saccades to the right, prolonged fixation times, and many regressive saccades.<sup>10</sup> Our subject used his two lateral PRL alternately, respectively for reading along the line and for starting to read a new line, in order to benefit from their respective advantages.

The second strategy we recognised was used to decipher difficult segments in a line of text. In this case, our subject used the single word reading pattern described in our previous study, consisting of the use of his three PRL in association, to benefit from the visual advantages of each one. In this strategy, the upper PRL was used for global viewing. It was used in association with the left or right PRL, which offered better discrimination of the beginning or end of a word, but with a more limited field of view.

Thus, in both reading conditions—that is, for fluent reading and for deciphering a difficult segment in a line of text, the subject used two or three PRL in association, each having different functions. He was able to change his ocular strategy according to the visual requirements of the task and the visual abilities of his PRL.

Up to now, it has generally been considered that patients who are well adapted to their defect have developed an oculomotor behaviour based on a single PRL, which is well defined and well circumscribed, and is used to perform tasks requiring fixation. White and Bedell<sup>4</sup> suggested that this adaptation process is associated with a change in the coordinates of the retinomotor centre from the non-functioning fovea to the newly developed PRL. These authors reported that about one third of their patients developed such an oculomotor adaptation. Later studies, however, have indicated that to perform two different visual tasks two PRL are occasionally used.<sup>5,7,8</sup> Our results clearly showed that several PRL can be used in association to perform a single visual task, and that reorganisation occurs in the oculomotor control, transforming a reading process based on one retinomotor centre into one in which three fixation areas are used in combination.

It has been reported that, in patients with macular disorders, frequent regressions and vertical saccades occur when reading texts.<sup>7</sup> Our results show that such movements, hith-

erto thought to be inappropriate, may in fact reflect purposeful changes in the fixation mode. We called them “pseudo regressions” and “pseudo line losses”. “Pseudo regressions” may be confused with unsuitable saccadic regressions. In fact, after fixating the beginning of a new line, a switch from the left PRL to the right PRL was performed in order to obtain a visual span to the right of the fixation area and continue reading along the line. “Pseudo line losses” could also be confused with unsuitable changes of lines. In fact, they were due to a switch from a lateral PRL to the upper PRL, or vice versa, in an attempt to decipher a particularly difficult part of the line. In addition, we observed “pseudo progressions”, which could be confused with suitable progressive saccades. In fact, they were the result of a switch from the right PRL to the left PRL, which was a manoeuvre for also scrutinising a particularly difficult part of the line.

These conclusions were reached thanks to our previous observations in our study on single word reading patterns, which enabled us to locate, in this patient, the three PRL that were used successively or in combination. Indeed, when analysing SLO recordings of the fundus, analysis of single word reading made it easier to recognise the image area to which attention was being paid, and to correlate the part of the image being scrutinised with the retinal area participating in the deciphering. Moreover, when analysing the subject’s verbal comments on what he was experiencing while deciphering single words, having him read the words aloud gave more precise information on the reading process.

It has been suggested that, when patients have a central scotoma in each eye, the monocular characteristics of PRL cannot always be extrapolated to binocular viewing tasks.<sup>11</sup> For technical reasons, we performed our study under monocular conditions. This probably did not affect the validity of our conclusions in everyday life, as our subject was used to reading under monocular conditions. In our experimental setting, he apparently employed his usual PRL and associated gaze strategies.

The results of our study could lead to an alternative approach to rehabilitation, in which the use of one or several PRL, and the analysis of their respective functions may be considered. Instead of assuming that each affected subject has adapted to his central scotoma by changing his retinomotor centre, therapists should bear in mind that some patients may use different PRL to perform different visual tasks, and even several PRL in association to perform a single task. The results of our study should also be taken into account when planning functional evaluation before laser treatment. Such evaluations usually take into account location of the PRL used when fixating a simple target. Our results clearly show that the location and function of PRL used for one visual task cannot always be extrapolated to other visual tasks.

In this study, we have described a well adapted, structured reading pattern, which was consistently used by one subject. To our

knowledge, this is the first structured reading behaviour ever identified in such a condition. Obviously, however, the reading pattern reported in this study is not used by every subject with a macular disorder. Eye movements during reading probably depend on a variety of factors, including the size, location, depth, and sharpness of the border of the scotoma, and adaptive abilities according to age. In particular, it might be important to determine whether the adaptive oculomotor behaviour of subjects affected early in life by the macular condition, as occurred in our patient, can also occur in subjects affected later in life—for example, by age related macular degeneration (AMD). In this respect, our previous observations<sup>9</sup> that an 82 year old patient with AMD demonstrated a sensorimotor adaptation implicating several PRL for deciphering single words, which was similar to that of a 46 year old patient with Stargardt's disease, suggested that age at onset of the disorder might not be a significantly limiting factor in oculomotor adaptation processes. Further studies are needed to determine the proportion of affected subjects who use such a reading pattern, and the conditions required for learning such behaviour. Additional studies may also allow us to recognise other reading patterns.

Finally, when considering the functional rehabilitation of affected patients, it will be

necessary to compare the efficiency of reading strategies, in order to redesign rehabilitation procedures.

This investigation was supported by the grant no 32-49594.96 from the Swiss National Fund for Scientific Research, by the Association pour le Bien des Aveugles, Geneva, Switzerland, and by the AETAS Foundation.

- 1 Von Noorden GK, Mackensen G. Phenomenology of eccentric fixation. *Am J Ophthalmol* 1962;53:642.
- 2 Cummings RW, Whittaker SG, Watson GR, et al. Scanning characters and reading with a central scotoma. *Am J Optom Physiol Opt* 1985;62:833-43.
- 3 Timberlake GT, Peli E, Essock EA, et al. Reading with a macular scotoma. II. Retinal locus for scanning text. *Invest Ophthalmol Vis Sci* 1987;28:1268-74.
- 4 White JM, Bedell HE. The oculomotor reference in humans with bilateral macular disease. *Invest Ophthalmol Vis Sci* 1990;31:1149-61.
- 5 Guez JE, Le Gargasson J-F, Rigaudiere F, et al. Is there a systematic location for the pseudo-fovea in patients with central scotoma? *Vis Res* 1993;33:1271-9.
- 6 Fletcher DC, Schuchard RA. Preferred retinal loci relationship to macular scotomas in a low-vision population. *Ophthalmology* 1997;104:632-8.
- 7 Trauzettel-Klosinski S, Teschner C, Tornow RP, et al. Reading strategies in normal subjects and in patients with macular scotoma assessed by two new methods of registration. *Neuro-Ophthalmology* 1994;14:15-30.
- 8 Lei H, Schuchard RA. Using two preferred retinal loci for different lighting conditions in patients with central scotomas. *Invest Ophthalmol Vis Sci* 1997;38:1812-18.
- 9 Duret F, Safran AB, Issenhuth M. Combined use of several preferred retinal loci in patients with macular disorders. *Vis Res* 1999;39:874-9.
- 10 Schuchard RA, Fletcher DC. Preferred retinal locus. A review with applications in low vision rehabilitation. *Ophthalmol Clin N Am* 1994;7:243-56.
- 11 Zihl J. Eye movement patterns in hemianopic dyslexia. *Brain* 1995;118:891-912.