

LETTERS TO THE EDITOR

Viridans group *Streptococcus* subretinal abscess

EDITOR.—Subretinal abscess is an unusual entity, occurring primarily in immunocompromised individuals. Reported causative organisms include fungi^{1,2} and Gram negative rods.^{3,4} Here we report a subretinal infection resulting from the Gram positive organism viridans group *Streptococcus* in a pancytopenic patient.

CASE REPORT

A 56 year old man undergoing chemotherapy for IgG multiple myeloma presented with 3 days of fever. He denied injecting drug abuse. He had a temperature of 101.5°F, poor dentition, a quiet indwelling catheter site on the chest, and no cardiac murmur. He was pancytopenic with a haematocrit of 14.2% (normal 39–49%), white blood cell count of $0.2 \times 10^9/l$ (normal 4.5–11.0), absolute neutrophil count of $0.1 \times 10^9/l$ (normal 1.8–6.8), and platelet count of $12 \times 10^9/l$ (normal 150–450). Chest x ray and urinalysis were clear. Empirical treatment with intravenous vancomycin and ceftazidime was initiated.

The next day the patient reported decreased vision in the left eye. Visual acuity in the right eye was 20/25 and light perception in the left. The anterior segments were clear. Several cotton wool spots and blot intraretinal haemorrhages were present in the right eye. In the left eye, yellow white subretinal exudate was observed detaching two thirds of the retina; the vitreous was clear. Vitreous tap was unsuccessful. Since blood cultures had grown Gram positive cocci in pairs and chains that were subsequently identified as viridans group *Streptococcus* sensitive to penicillin and vancomycin, the left eye was injected intravitreally with vancomycin 1.0 mg/0.1 ml. Despite two further intravitreal injections of vancomycin, the patient's left eye rapidly lost light perception and developed increasing vitreous haze (Fig 1). Repeat vitreous tap revealed Gram positive cocci in pairs and chains, although cultures grew no organisms.

The patient remained febrile and his mental status declined during treatment for presumed bacterial endocarditis. (He was too ill to undergo transoesophageal echocardiography.) Head computed tomogram revealed multiple brain lesions consistent with septic emboli. On day 10, the left eye was eviscerated and the indwelling catheter removed because of con-

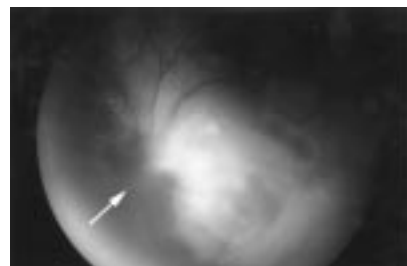

Figure 1 Fundus photograph on hospital day 4. Left eye exhibits subretinal exudative material detaching two thirds of the retina. The arrow indicates the optic disc.

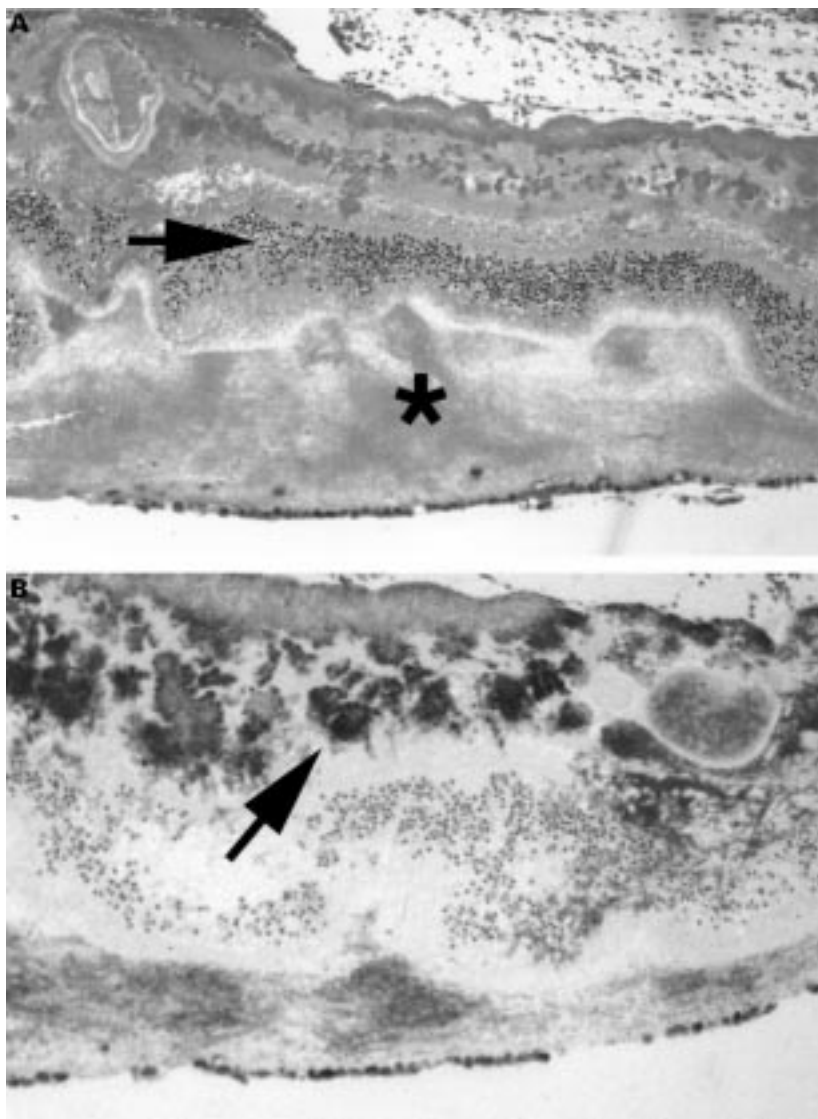


Figure 2 Histological sections of evisceration specimen. (A) Haematoxylin and eosin stain ($\times 40$) reveals coagulative necrosis of the inner retina. Arrow indicates outer nuclear layer. Asterisk indicates subretinal exudate with virtually no inflammatory cells. (B) Gram stain ($\times 40$) shows numerous Gram positive cocci in clusters and individually in the inner retina (arrow) and the subretinal space.

cern these foci might represent persistent infectious reservoirs. The patient died of sepsis on day 16. Family members declined necropsy.

Histopathological examination of the evisceration specimen revealed fragments of retina with an underlying protein exudate, coagulative necrosis of the inner retina, fibrinous occlusion of some retinal blood vessels, and numerous clumps and individual Gram positive cocci in the subretinal space and inner retina (Fig 2). Inflammatory cells were strikingly absent.

COMMENT

Viridans group *Streptococcus* (VGS) is a normal constituent of the oral flora. VGS is the leading cause of native valve endocarditis in non-injecting drug abusers and is also an increasing problem in neutropenic cancer patients.⁵ In adults undergoing chemotherapy for cancer up to 39% of bacteraemias result from VGS, with mortality rates of up to 30%.⁵ The most common source of VGS bacteraemia is the oropharynx.

Treatment guidelines for subretinal abscess are unclear. Although one of the most feared complications of vitrectomy surgery for endo-

phthalmitis is retinal break leading to retinal detachment, successful vitrectomy with internal drainage has been described.^{3,4} We did not pursue vitrectomy surgery because a causative organism was identified, the vitreous was initially clear, and the patient was moribund. In retrospect, the absence of an inflammatory cell response in the retina (Fig 2), presumably because of severe pancytopenia, suggests sterilisation of the eye by any means would have been extremely difficult if not impossible.

The clinical picture of our patient was that of subretinal abscess. The absence of inflammatory cells in the pathological specimen, however, defines the subretinal exudate as non-purulent and primarily proteinaceous in nature.

NICOLE R RIMPEL
EMMETT T CUNNINGHAM JR
EDWARD L HOWES JR
ROBERT Y KIM

Department of Ophthalmology, San Francisco General Hospital and the University of California, San Francisco, USA

Correspondence to: Dr R Y Kim, UCSF Department of Ophthalmology K301, 10 Kirkham Street, San Francisco, CA 94143-0730, USA.

Accepted for publication 1 September 1998

- 1 Weiss JN, Hutchins RK, Balogh K. Simultaneous aspergillus endophthalmitis and cytomegalovirus retinitis after kidney transplantation. *Retina* 1988;8:193-8.
- 2 Gregor RJ, Chong CA, Augsburger JJ, et al. Endogenous Nocardia asteroides subretinal abscess diagnosed by transvitreal fine needle aspiration biopsy. *Retina* 1989;9:118-21.
- 3 Webber SK, Andrews RA, Gillie RF, C et al. Subretinal Pseudomonas abscess after lung transplantation. *Br J Ophthalmol* 1995;79:861.
- 4 Yarnig SS, Hsieh CL, Chen TL. Vitrectomy for endogenous Klebsiella pneumoniae endophthalmitis with massive subretinal abscess. *Ophthalmic Surg Lasers* 1997;28:147-50.
- 5 Bochud PY, Calandra T, Francioli P. Bacteremia due to viridans streptococci in neutropenic patients: a review. *Am J Med* 1994;97:256-64.

Inferior oblique myectomy using monopolar cutting diathermy resulting in bilateral retinal scarring

EDITOR.—Modern inferior oblique surgery is considered to be a safe procedure with little chance of serious complications.^{1,2} Monopolar diathermy is known to be a potentially dangerous tool if used inappropriately or injudiciously.³ There have been cases of fires, explosions caused by igniting bowel gas during laparoscopic surgery,⁴ and patient death caused by interference with a cardiac pacemaker.⁴ Our case demonstrates once again that an inadequate understanding of equipment or its inappropriate use can cause significant injury to the patient.

CASE REPORT

A 22 year old woman presented herself to Moorfields eye casualty department with a 2 day history of seeing a blob in front of her left eye. Her acuity was 6/6 right eye and 6/12 left eye corrected with no improvement with pin-hole. Examination revealed left vitreous haemorrhage with bilateral chorioretinal scars in the temporal periphery slightly below the horizontal in each eye (Fig 1, top). The scars roughly corresponded to the possible insertion of the inferior oblique muscles. She had no

medical problems, was on no medication, but had a family history of retinal detachment. She had had bilateral inferior oblique myectomy 6 years earlier. Her acuity improved to 6/6 bilaterally when the vitreous haemorrhage had cleared 4 months later but she was left with bilateral scotomas. There was evidence of anomalous vessels in the large scar in the left eye but no leakage was seen on fluorescein angiography (Fig 1, bottom). These vessels have not been treated with laser therapy but are being observed regularly in clinic. She had normal pupillary responses to light. The surgeon who performed the inferior oblique myectomy was contacted and confirmed that it was their normal practice to use monopolar diathermy to cut the muscle during this type of surgery.

COMMENT

Monopolar diathermy works by forming an electrical current from the indifferent electrode plate (usually attached to the patient's thigh) to the forceps or blade held by the surgeon. Current flows through the body creating thermal damage in the tissues near the forceps or knife resulting in coagulation. There have been case reports of current flowing in this way causing unexpected damage proximal to the forceps particularly when operating on vascular structures in which a lot of current must flow through a small amount of tissue. This situation has occurred during circumcision operations and in some cases total ablation of the penis has resulted.⁵ Similar damage may occur during bowel surgery resulting in pedicle injury.⁶ Current flows particularly well through blood vessels which means that vascular structures are at particularly high risk of damage from this mechanism. Bipolar diathermy is generally speaking a much safer way to cauterise tissue. Current only flows between the tips of the diathermy forceps rather than through the rest of the patient. This makes collateral damage much less likely to occur.

The normal insertion of the inferior oblique muscle is oblique with the convexity upwards

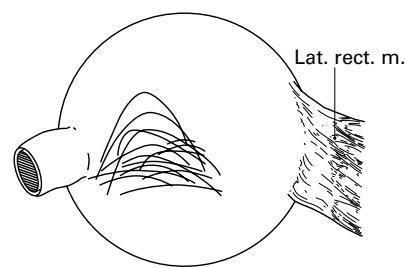


Figure 2 Sketch of the most variable insertions of the inferior oblique muscle found on examination of 100 specimens. (From Fink¹¹.)

and is predominantly below the horizontal meridian, with which it may make an angle of from 15° to 20°. The main variation in insertion is in the degree of obliquity and convexity of the curve but the insertion may often show gross irregularities such as angular serrations or dehiscences (Fig 2). The insertion is usually between 8 and 10 mm long. The macula is usually 1-2 mm posterior and 1 mm superior to the posterior tip of the inferior oblique insertion.⁷ Although at first sight our patient's scars do not seem to directly correspond to this position there are a number of possible explanations. Firstly, this patient required vertical squint surgery so it is possible that her inferior oblique muscles did not have a normal site of insertion. Another factor might be the angle of traction on the muscle when the diathermy was being applied. The forward pull on the muscle would have brought it into close contact with the globe along some of its length anteriorly and this may have resulted in the somewhat peripheral site of the scarring. Finally, there are other structures in close proximity to the muscles such as blood vessels (vortex veins), nerves, and their accompanying fibrous tissue all of which could have played a part in conducting current and causing a burn. The muscle belly where diathermy is applied has a larger cross sectional area than the insertion or place of approximation of the tendon to the globe. This results in a relatively large current flowing through a small cross sectional area which can easily result in a burn as it sometimes does in circumcision surgery.⁵

A variety of techniques are used for weakening or severing the inferior oblique muscle in the treatment of vertical gaze deviations; these include myotomy, myectomy, disinsertion, denervation, and recession.¹ Myotomy and denervation using cutting diathermy has been described¹ and in one series of 86 patients who underwent thermoelectric weakening there was no mention of any visual complications.⁸ This procedure was carried out using an "electric knife" but it is not specified whether this was a monopolar or bipolar device.

Internal ophthalmoplegia has been described as a complication of inferior oblique myectomy using what was probably bipolar cautery and the most likely cause of this was thought to be excessive stretching of the nerve to the inferior oblique with secondary trauma to the ciliary ganglion.⁹

In our case we believe that the potential of the monopolar diathermy to cause damage may have been exacerbated by stretching the inferior oblique muscle while using the cutting diathermy on it. This would have reduced the cross sectional area causing greater resistance to flow consequently generating more heat in the muscle including its site of origin which is usually in close proximity to the macula. Although difficult to prove this we have no

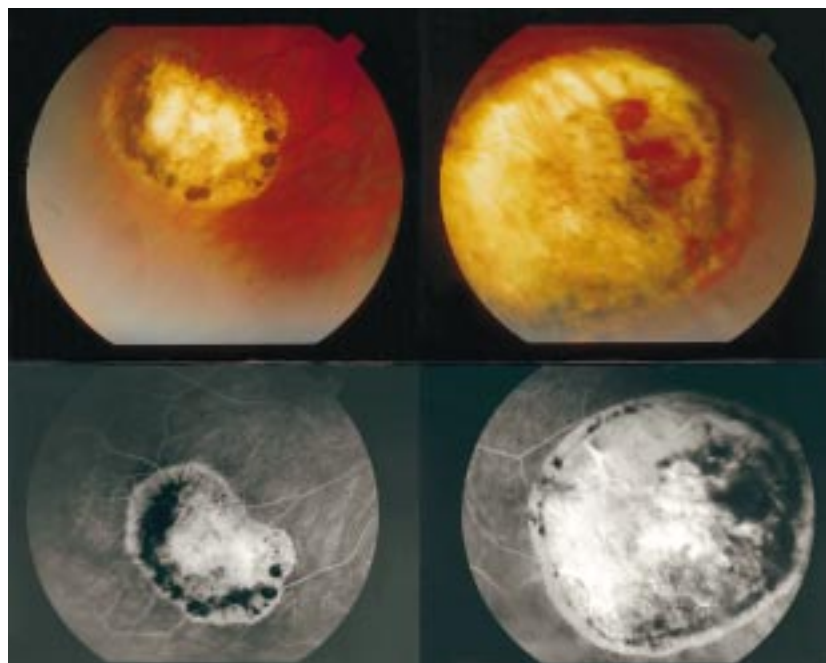


Figure 1 Top: Bilateral retinal scars on presentation. Bottom: Fluorescein angiogram demonstrating bilateral macula burns.

other explanation for the development of bilateral symmetrical chorioretinal scars in this otherwise healthy young woman.

Monopolar electrocautery has been used successfully for many years by ophthalmologists particularly in the field of oculoplastics¹⁰ and should not be abandoned. However, we believe that monopolar diathermy should not be used during inferior oblique surgery as monopolar cutting seems to offer little advantage over the use of bipolar cautery and a conventional blade and has the potential to cause significant retinal injury.

B J L BURTON
A M P HAMILTON
Moorfields Eye Hospital, City Road,
London EC1V 2PD

Accepted for publication 14 September 1998

- 1 Parks MM. Inferior oblique weakening procedures. *Int Ophthalmol Clin* 1985;25:107-17.
- 2 Edwards WC, Hess JB. Inferior oblique surgery. *Ann Ophthalmol* 1982;14:831-4.
- 3 Nduka CC, Super PA, Monson JRT, et al. Cause and prevention of electrical injuries in laparoscopy. *J Am Coll Surg* 1994;179:161-70.
- 4 Protin F, Dodinot B, Lefevre JC, et al. Interferences nefastes entre stimulation cardiaque prophylactique pre-operatoire et bistouri electrique. A propos d'une observation. *Ann Anesthesiol Fr* 1979;20:127-30.
- 5 Gearhart JP, Rock JA. Total ablation of the penis after circumcision with electrocautery: a method of management and long term follow-up. *J Urol* 1989;142:799-801.
- 6 Saye W, Miller W, Hertzman P. Electrosurgery thermal injury. *Surgical Laparoscopy and Endoscopy* 1991;1:223-8.
- 7 Fink WH. *Surgery of the oblique muscles of the eye*. St Louis: CV Mosby, 1951:97-126.
- 8 De Decker W, Kueper J. Inferior oblique weakening by marginal myotomy: thermoelectric weakening. *Ann Ophthalmol* 1973;5:605-9.
- 9 Bajart AM, Robb RM. Internal ophthalmoplegia following inferior oblique myectomy: a report of three cases. *Ophthalmology* 1979;86:1401-6.
- 10 Sherman DD, Dortzbach RK. Monopolar electrocautery dissection in ophthalmic plastic surgery. *Ophthalmic Plastic Reconstruct Surg* 1993;2:143-7.
- 11 Fink WH. *Surgery of the oblique muscles of the eye*. St Louis: CV Mosby, 1951:101.

Ultrasound biomicroscopy in juvenile xanthogranuloma of the iris

EDITOR.—Juvenile xanthogranuloma (JXG) is a rare disorder of infants and very young children affecting the ocular structures, particularly the iris.

It is characterised by spontaneous hyphaema associated with a yellowish, poorly demarcated iris tumour and increased intraocular pressure; the aetiology is unknown.¹ The ocular lesions are usually unilateral and should be differentiated from amelanotic melanoma, iris leiomyoma, haemangioma, and other iris lesions.²⁻⁴ Early diagnosis and treatment determine the final visual outcome.

The aim of the present study was to describe the use of ultrasound biomicroscopy

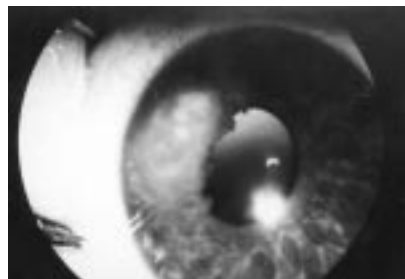


Figure 1 Juvenile xanthogranuloma of the iris. Left eye yellowish brown lesions with an irregular surface on the nasal side.

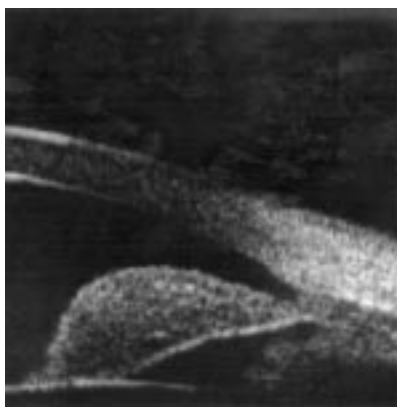


Figure 2 Ultrasonic biomicroscopy of the juvenile xanthogranuloma lesion of the iris, showing a free margin between the lesion and the angle; the ciliary body is not involved. Note the homogeneous reflectivity of the tumour mass.

(UBM) to define precisely the location of the tumour before excision and to correlate the UBM findings with the histopathological pattern.

CASE REPORT

A 2 year old girl was evaluated for an iris lesion. Past medical history showed two events of febrile convulsions at 1 year of age. Computed tomography of the brain, electroencephalography, and lumbar puncture were normal. Fixation and follow up movement were normal in both eyes. Ophthalmological examination revealed an unusual yellowish brown stromal lesion with an irregular surface in the nasal side of the left iris (Fig 1). It occupied the whole iris, from the angle to the pupillary border. Abnormal vascularisation and a small hyphaema were also noted. Except for the iris lesion, the anterior and posterior segments were completely normal. The examination of the right eye was unremarkable. Systemic evaluation revealed normal findings. On examination under anaesthesia, Tonopen tonometry revealed a pressure of 23 mm Hg, and microscopy showed a 3.4 mm × 4 mm mass located in the lower nasal quadrant between the 7 o'clock and 11 o'clock positions, with pupillary distortion. UBM was subsequently performed and a full thickness,

solid stromal lesion of the iris was observed, with a homogeneous internal reflectivity and slightly irregular surface with no surface plaque. There was no involvement beyond the iris root. Lesion thickness measured 1.2 mm (Fig 2).

Sector iridectomy was performed in order to remove the whole lesion together with clinically normal looking temporal and nasal margins.

Viscoelastic material was used to prolapse the involved iris segment out of the eye through a wide limbal incision, and the iris was excised at the root. Histopathological evaluation revealed a cellular mass occupying the entire iris stroma and consisting of numerous histiocytes, some of them containing clear cytoplasmic vacuoles. Among these cells a few lymphocytes, plasma cells, and iris melanocytes were noted. Immunohistochemical staining for CD-68, a histiocytic marker, was positive in the majority of the histiocytic cells. Immunohistochemical staining for HMB-45, a melanoma cell marker, was negative. Touton giant cells were noted among the histiocytic cells (Fig 3). According to these histopathological findings a diagnosis of juvenile xanthogranuloma was made.

COMMENT

The present study shows the importance of preoperative UBM evaluation in identifying the nature and location of any iris lesion in childhood, before surgical excision is performed.

The homogeneous cellularity of the whole mass together with the absence of significant vascular channels on histology correlated with the homogeneous reflectivity on the UBM. The slightly irregular surface of the tumour and lack of vascular channels helps to differentiate JXG from iris melanoma, which generally show more variable internal reflectivity patterns including a linear more highly reflective pattern in the superficial layer and lobulated appearance with internal space representing blood vessels.⁵

In our case, UBM was the major technique which allowed us to determine the characteristics, thickness, location, and possible spread of the lesion. By defining the precise boundaries of the lesion and ruling out involvement of the iridocorneal angle or ciliary body, UBM

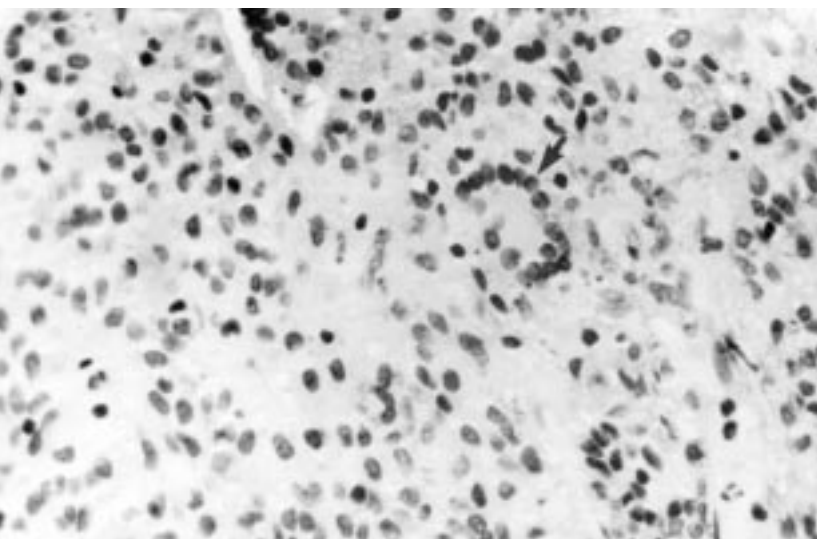


Figure 3 Cellular mass consisting of numerous histiocytes, a few lymphocytes, plasma cells, iris melanocytes, and Touton giant cells (arrow). Haematoxylin and eosin; original magnification ×120.

was found to be very helpful in planning the complete surgical excision of this iris tumour.

HENIA LICHTER
YUVAL YASSUR
DAVID BARASH
ISRAEL KREMER
MOSHE SNIR
DOV WEINBERGER

Department of Ophthalmology, Rabin Medical Center, Beilinson Campus, Petah Tiqva, and Sackler Faculty of Medicine, Tel Aviv University, Tel Aviv, Israel.

Correspondence: H Lichter, MD, Department of Ophthalmology, Rabin Medical Center, Beilinson Campus, Petah Tiqva 49100, Israel.

Accepted for publication 1 September 1998

- Zimmerman LE. Ocular lesions of juvenile xanthogranuloma nevoxanthoendothelioma. *Trans Am Acad Ophthalmol Otolaryngol* 1965;69:412-42.
- Shields JA, Eagle RC Jr, Shields CL. Iris juvenile xanthogranuloma studied by immunohistochemistry and flow cytometry. *Ophthalmic Surg Lasers* 1997;28:140-4.
- Califano L, De Luca F, Rizza G. Juvenile xanthogranuloma. Apropos of three cases. *Minerva Pediatr (Italy)* 1987;39:663-8.
- Smith ME, Sanders TW, Bresnick GH. Juvenile xanthogranuloma of the ciliary body in an adult. *Arch Ophthalmol* 1969;81:813.
- Pavlin CJ, Foster FS. *Ultrasonic biomicroscopy of the eye*. New York: Springer Verlag, 1995:98-127.

A traumatic "peripheral iridotomy" protects against pigment dispersion and glaucoma

EDITOR.—Pigment dispersion syndrome is an autosomal dominant condition which leads to pigmentary glaucoma in up to 50% of cases. Campbell¹ was the first to propose that posterior bowing of the peripheral iris with chaffing against the lens zonule was responsible for the liberation of iris pigment which recent developments in high resolution ultrasound biomicroscopy appear to bear out. Current theories suggest that the cause of this posterior iris bowing is "reverse pupil block",² in which the iris acts as a flap valve against the anterior surface of the lens allowing aqueous to pass from posterior to anterior chamber but not vice versa.

Pigment dispersion syndrome is a bilateral, symmetric disorder and unilaterality or asymmetry should prompt further investigation as to the cause.³ An unusual case of unilateral pigmentary glaucoma is presented which is the first to report the possible long term protective benefits of relieving of this "reverse pupil block".

CASE REPORT

A 39 year old man was referred after his optometrist had noted elevated intraocular pressure (IOP) in his right eye. He was myopic and had sustained a blunt injury to his left eye at the age of 8 after which the vision in that eye had been poor.

His corrected visual acuity was right eye 6/5 Snellen -1.25/-3.25x180 and left eye 6/24 Snellen -1.25/-1.50x175. IOPs at presentation were 35 mm Hg right and 20 mm Hg left. He had brown deeply pigmented irides bilaterally. His right eye showed inferocentral pigment deposition on the corneal endothelium (Krukenberg's spindle) and mid-peripheral radial iris transillumination defects. The left cornea was clear and the only iris defects visible were a 2 clock hour iridodialysis and a partially denervated, ruptured iris sphincter muscle. Both anterior chambers appeared equally deep and gonioscopy revealed a wide open angle with a posteriorly

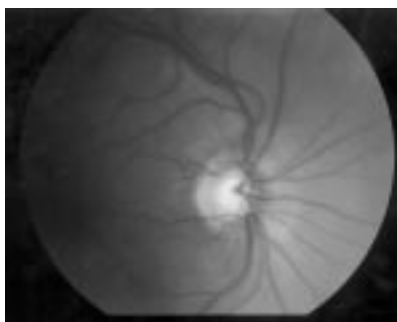


Figure 1 Optic disc, cupped.

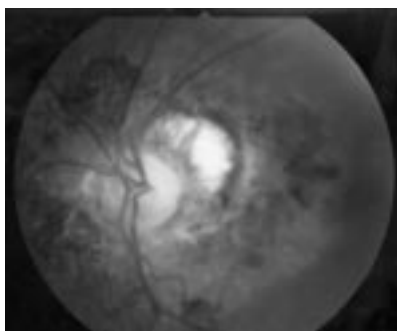


Figure 2 Optic disc, not cupped.

inserted iris root in both eyes. In the left eye, on the borders of the dialysis only, there had probably been some iris recession. Heavy circumferential trabecular pigmentation was present in the right eye but no pigment was seen on the left. The right optic disc (Fig 1) was deeply cupped (vertical C/D 0.6/7) while the left the optic disc (Fig 2) was not cupped but was slightly pale and surrounded by chorioretinal scarring. Right eye threshold visual field examination was suggestive of a superior nasal step scotoma while the left showed an inferior altitudinal defect. A diagnosis of right pigmentary glaucoma was made and he was immediately started upon levobunolol twice daily in his right eye. Subsequently he has had a laser peripheral iridotomy performed.

COMMENT

Much in the same way as conventional pupil block can be alleviated by an iridotomy (providing an alternative aqueous pathway and equalising anterior and posterior chamber IOP), it is suggested that "reverse pupil block" may also be alleviated in the same way. There is now evidence that laser peripheral iridotomy in pigment dispersion syndrome both restores a more planar iris configuration¹ and may prevent the development of ocular hypertension.⁵ However, long term studies are awaited.

This report illustrates the effect of a traumatic iridotomy occurring in childhood in an individual who was destined subsequently to develop pigment dispersion syndrome and glaucoma. It would appear that the lack of pigment dispersion and optic disc cupping in the previously damaged eye provides evidence for the long term efficacy of laser peripheral iridotomy in this condition.

GARRY N SHUTTLEWORTH
Bristol Eye Hospital, Lower Maudlin Street,
Bristol BS1 2LX

Accepted for publication 22 September 1998

- Campbell DG. Pigmentary dispersion and glaucoma. A new theory. *Arch Ophthalmol* 1979;97:1667.

- Karickhoff JR. Pigmentary dispersion syndrome and pigmentary glaucoma: a new mechanism concept, a new treatment, and a new technique. *Ophthalmic Surg* 1992;23:269-77
- Ritch R, Alward WLM. Asymmetrical pigmentary glaucoma caused by unilateral angle recession (letter). *Am J Ophthalmol* 1993;116:765-6
- Potash SD, Tello C, Liebmann JM, et al. Ultrasound biomicroscopy in pigment dispersion syndrome. *Ophthalmology* 1994;101:332-9
- Gandolfi SA, Vecchi M. Effect of a YAG laser iridotomy on intraocular pressure in pigment dispersion syndrome. *Ophthalmology* 1996;103:1693-5

Inadvertent exposure of corneal endothelium to 5-fluorouracil

EDITOR.—The use of postoperative subconjunctival 5-fluorouracil (5-FU) injection to inhibit scarring after glaucoma filtering surgery is now commonplace. Uncomplicated subconjunctival 5-FU injection is unlikely to produce endothelial toxicity, as post-injection anterior chamber drug levels remain low.¹ However, inadvertent intraocular exposure can be toxic to the cornea.² We report a case of postoperative subconjunctival 5-FU injection with accidental passage of the drug directly into the anterior chamber.

CASE REPORT

A left trabeculectomy was performed on a 79 year old white woman using peroperative 5-FU (25 mg/ml). Two days later the patient rubbed her eye and the anterior chamber became transiently flat. Over the next 4 weeks the drainage bleb encysted, and the patient received 5 mg (0.2 ml) 5-FU into the superior bulbar conjunctiva. Immediately after injection the intraocular pressure (IOP) dropped from 23 to 10 mm Hg, and air bubbles from the syringe were seen in the anterior chamber. It was clear that 5-FU had gained direct intraocular access. The anterior chamber was washed out with balanced salt solution within 30 minutes of exposure. The next day the IOP measured 15 mm Hg and the cornea was clear. Two uneventful subconjunctival injections of 5-FU (5 mg) were subsequently administered. Eleven months after her glaucoma surgery the patient underwent endocapsular cataract extraction and lens implant with one further peroperative subconjunctival 5-FU (5 mg) injection.

One month after the initial glaucoma surgery corneal specular microscopy was normal, although patient photophobia prevented detailed assessment. A second specular micrograph performed before cataract surgery revealed a central cell density of 2390 cells/mm², an average cell size of 430 μm², and a cell variation of 40%. Two years after the glaucoma drainage operation a third specular micrograph revealed a left eye central cell density of 1887 cells/mm² (right eye 2238 cells/mm²), an average cell size of 530 μm²




Figure 1 (A) Right eye, (B) left eye. Corneal specular micrographs taken 2 years after intraocular 5-FU exposure. The left eye shows some corneal polymegathism.

(right eye 447 μm^2) and cell variation of 44% (right eye 41%). Endothelial polymegathism was noted (Fig 1B). The corneal thickness measured 0.46 μm in the left eye and 0.42 μm in the right. The corrected visual acuity was 6/9 and the IOP 18 mm Hg on no therapy.

COMMENT

There are two possible mechanisms by which 5-FU may compromise cellular function. The first is inhibition of cell replication, and the second a toxic effect, either by direct drug action or an alkali effect (pH 8.9). Corneal endothelial cell toxicity has been reported in *in vitro* animal studies.³⁻⁵ However, the *in vitro* model does not allow for aqueous dilution, aqueous turnover, or aqueous pH buffer effects. In addition, corneal endothelial cells replicate in animal models, unlike their human counterparts. Direct and/or alkali toxicity is the more probable mechanism in the human cornea.

Two other cases of 5-FU gaining direct access to the anterior chamber have been reported in humans.² The authors described the use of subconjunctival 5-FU (50 mg/ml) after a bleb needling procedure. Anterior chamber washout was not performed and

severe corneal oedema developed at day 1 which resolved completely after 6 months. Increased endothelial cell pleomorphism was noted.

In our case report, the significant fall in intraocular pressure after injection suggests that the needle entered the bleb cyst, increased intracyst pressure, and enabled 5-FU to enter the anterior chamber.

The first and second specular micrograph findings indicate that the endothelium was relatively undamaged by 5-FU exposure, and the drop in cell count noted in the third micrograph is compatible with published reports of cell loss encountered after endocapsular cataract surgery. In conclusion, we did not experience clinically significant endothelial cell toxicity, presumably due to the dilution and pH buffering effects of aqueous, followed by prompt anterior chamber washout. As 5-FU is potentially toxic in the eye,² our experience suggests that care should be taken when injecting around an encysted bleb.

GURPREET S BHERMI

Glaucoma Unit, Moorfields Eye Hospital,
City Road, London

SOPHIE HOLAK
Georg-August-University in Göttingen,
Medical School, Germany

IAN E MURDOCH
Glaucoma Unit, Moorfields Eye Hospital,
City Road, London

Accepted for publication 23 October 1998

- 1 Rootman J, Tisdall J, Gudauskas G, *et al.* Intraocular penetration of subconjunctivally administered ^{14}C -fluorouracil in rabbits. *Arch Ophthalmol* 1979;97:2375-8.
- 2 Mazey BJ, Siegel MJ, Siegel LL, *et al.* Corneal endothelial toxic effect secondary to fluorouracil needle bleb revision. *Arch Ophthalmol* 1994;112:1411.
- 3 Mannis MJ, Sweet EH, Lewis AL. The effect of fluorouracil on the corneal endothelium. *Arch Ophthalmol* 1988;106:816-17.
- 4 Nuyts RM, Pels E, Greve EL. The effects of 5-fluorouracil and mitomycin C on the corneal endothelium. *Curr Eye Res* 1992;11:565-70.
- 5 Araie M, Nakano Y, Akahoshi T. Effects of subconjunctival 5-fluorouracil injections on the corneal endothelium and ciliary epithelium. *Graefes Arch Clin Exp Ophthalmol* 1990;28:573-81.

British Journal of Ophthalmology - <http://www.bjophthalmol.com>

Visitors to the world wide web can now access the *British Journal of Ophthalmology* either through the BMJ Publishing Group's home page (<http://www.bmjpub.com>) or directly by using its individual URL (<http://www.bjophthalmol.com>). There they will find the following:

- Current contents list for the journal
- Contents lists of previous issues
- Members of the editorial board
- Information for subscribers
- Instructions for authors
- Details of reprint services.
- BMJ Publishing Group home page
- British Medical Association web site
- Online books catalogue
- BMJ Publishing Group books.

A hotlink gives access to:

The web site is at a preliminary stage and there are plans to develop it into a more sophisticated site. Suggestions from visitors about features they would like to see are welcomed. They can be left via the opening page of the BMJ Publishing Group site or, alternatively, via the journal page, through "about this site".