

Confocal microscopy in the iridocorneal endothelial syndrome

Auguste G-Y Chiou, Stephen C Kaufman, Roger W Beuerman, Toshihiko Ohta, Volkan Yaylali, Herbert E Kaufman

Abstract

Aims—To report the appearances of iridocorneal endothelial (ICE) syndrome from real time, white light confocal microscopy.

Methods—Three consecutive patients, each with ICE syndrome, were examined prospectively. Corneal specular and confocal microscopic examinations were performed in all three patients. In the first patient, a penetrating keratoplasty was performed and the cornea was examined by light and scanning electron microscopy. No surgery was performed in the remaining two patients.

Results—In the first patient corneal oedema prevented endothelial specular microscopy. Confocal microscopy performed before penetrating keratoplasty successfully revealed abnormal epithelial-like endothelial cells. Histological examinations of the cornea following penetrating keratoplasty revealed the presence of multilayered endothelial cells with epithelial features (microvilli). In the remaining two patients, specular microscopy showed the presence of ICE cells with typical dark/light reversal. Confocal microscopy demonstrated groups of endothelial cells with epitheloid appearances. In all three patients, the contralateral endothelial appearance was normal by specular and confocal microscopy, except for moderate endothelial polymegathism in one patient. Epithelial-like endothelial cells were characterised by prominent nuclei on confocal microscopy.

Conclusions—The application of confocal microscopy indicates that the ICE syndrome is characterised by epitheloid changes in the endothelium. Confocal microscopy may be used to diagnose the ICE syndrome by demonstrating epithelial-like endothelial cells with hyperreflective nuclei. This technique is especially of value in cases of corneal oedema, since specular microscopy may fail to image the endothelium in such cases.

(*Br J Ophthalmol* 1999;83:697-702)

Louisiana State University Eye Center, New Orleans, LA, USA
A G-Y Chiou
S C Kaufman
R W Beuerman
T Ohta
V Yaylali
H E Kaufman

Correspondence to: Auguste G-Y Chiou, MD, Cornea and Refractive Surgery, Department of Ophthalmology, University of Lausanne, Av de France, 15, 1004 Lausanne, Switzerland.

Accepted for publication 4 December 1998

Confocal microscopy allows superior vertical and lateral resolution and image contrast, compared with conventional imaging methods, and real time in vivo examination of all layers of the cornea.³ Clinically, it has been successfully used to reveal distinguishing characteristics in Fuchs' endothelial dystrophy, various traumatic lesions, and infectious keratitis.⁴⁻¹³

Because of the optical properties of the confocal microscope, which makes it particularly suitable for endothelial examination,⁴ and since the ICE syndrome is characterised by corneal endothelial abnormality, it is likely that confocal microscopy may provide a new diagnostic approach to the ICE syndrome. We report in this study three consecutive cases of ICE syndrome. Results of confocal microscopic examination of the corneas are presented.

Materials and methods

Three patients diagnosed with the ICE syndrome were examined. All patients underwent specular microscopy using a non-contact microscope (Topcon SP 2000 P, Tokyo, Japan). In the first patient, confocal microscopy was performed using a prototype tandem scanning, white light, confocal microscope (LSU Eye Center, New Orleans, LA, USA), which had a 20×/0.60 contact objective. In the second and the third patients, our current prototype tandem scanning, white light, confocal microscope (LSU Eye Center, New Orleans, LA, USA), utilising a 24×/0.60 contact objective, was used. With both microscopes, liquefied methylcellulose was used as a coupling gel. The images were captured using a video camera (CCD 200 E, Videoscope International, Washington DC, USA) and stored on S-VHS video tapes.

CASE 1

A 46 year old white male patient with decreased vision in the left eye was referred with suspected herpes simplex virus keratitis. His family history was negative for ocular diseases. The patient had self medicated with preservative-free artificial tears in the left eye. Best corrected vision was 20/20 and 20/70 in the right and left eye, respectively. Slit lamp and funduscopic examinations of the right eye were normal. In the left eye, corneal oedema was noted along with epithelial bullae. The endothelium had a hammered silver appearance. There were no keratic precipitates and the anterior chamber was quiet. No abnormalities could be detected in the posterior segment. The intraocular pressure was 13 mm Hg in the right eye and 11 mm Hg in the left.

The iridocorneal endothelial (ICE) syndrome is a progressive, usually unilateral, and non-familial disorder with female predominance. It is characterised by corneal failure, iris destruction, and glaucoma. An abnormality of the corneal endothelium is thought to be the common aetiological basis for the different manifestations.^{1 2}

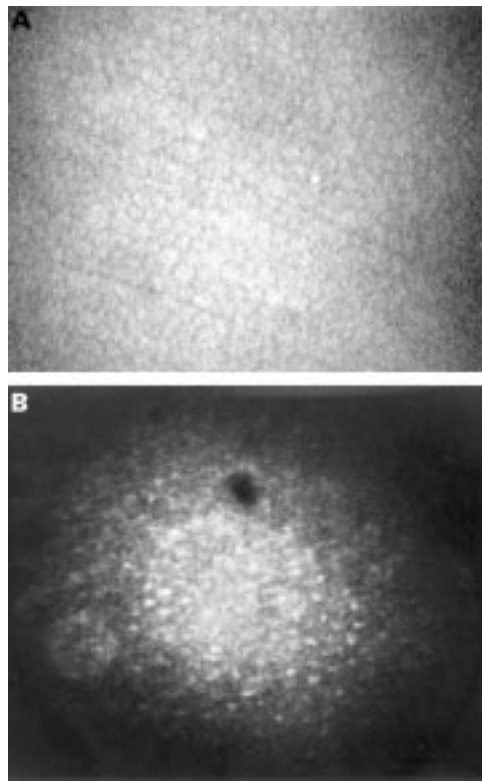


Figure 1 (A) Confocal microscopic appearance of normal endothelial cells from a normal subject. (B) Confocal microscopy (original magnification $\times 210$). Abnormal endothelial cells with well identifiable nuclei resembling the confocal microscopic appearance of corneal epithelial cells were found. The cells were relatively regular in shape and size. The dark oval image at the upper part of the picture is an artefact.

Corneal thickness measured by ultrasound pachymetry was $0.554 \mu\text{m}$ in the right eye and $0.656 \mu\text{m}$ in the left eye. Corneal endothelial specular microscopy was unremarkable in the right eye and prevented by corneal oedema in the left eye. Confocal microscopic examination of the right cornea was unremarkable. In the left eye, it readily revealed the presence of epitheloid appearing endothelial cells. Unlike in the normal cornea (Fig 1A), the abnormal

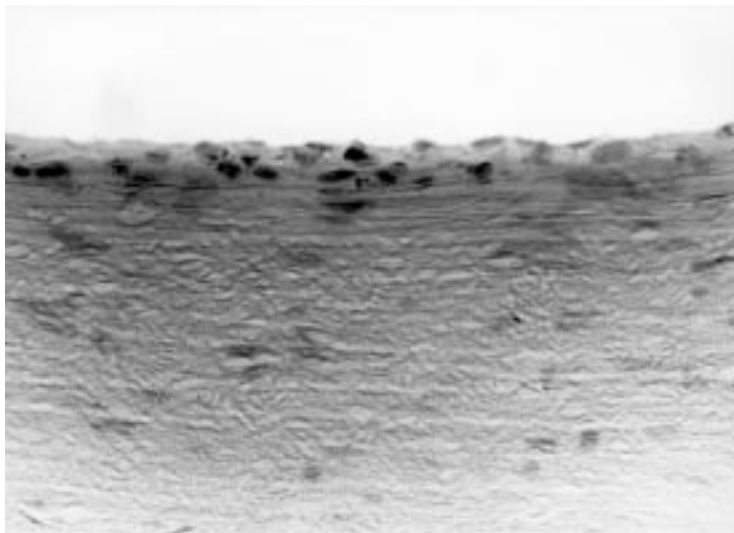


Figure 2 Light microscopy. Histological examination of the endothelium demonstrated multilayered epithelial-like cells.

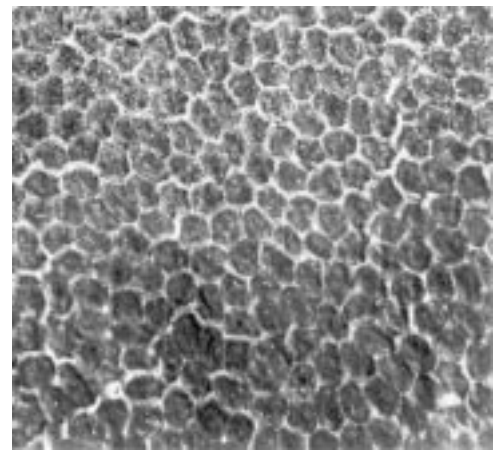


Figure 3 Scanning electron microscopy. Microvilli were found in abnormally high numbers on the surface of many endothelial cells (upper half of the photograph).

endothelial cells presented hyperreflective nuclei (Fig 1B). Their tissue organisation was found to be similar to the normal endothelium, where the cells are relatively regular in shape and size. No inflammatory cells were seen.

Because of the suspicion of herpetic disciform keratitis, the patient was treated with topical trifluorothymidine 1% and prednisolone acetate 1% four times daily in the left eye. However, corneal oedema worsened over a period of 2 months following the first visit despite the treatment. A more careful examination of the anterior segment revealed subtle iris atrophy. The combination of iris abnormality and corneal oedema pointed to the diagnosis of ICE syndrome. Chandler's syndrome, one form of the ICE syndrome characterised by corneal decompensation, was suspected and a functional penetrating keratoplasty was performed. Intraoperatively, iris atrophy was confirmed. The abnormal cornea underwent histopathological examination and endothelial cells with characteristics of epithelial cells were found. On light microscopy they appeared larger in height compared with normal endothelial cells and at some areas were multilayered (Fig 2). On scanning electron microscopy an abnormally high number of microvilli were found on the surface of abnormal cells (Fig 3).

CASE 2

A 73 year old white female patient with a history of progressive decrease of vision in the left eye was seen in the LSU Eye Center Clinic. The left eye had previously been diagnosed with Chandler's syndrome and iris abnormality. The patient underwent uncomplicated phacoemulsification and posterior chamber intraocular lens implantation in the left eye 4 years earlier. Familial and general medical history was unremarkable. Best corrected visual acuity was 20/30 in the right eye, and 20/50 in the left eye. Slit lamp examination of the right eye revealed a normal anterior segment with moderate nuclear cataract. In the left eye the endothelium had a hammered silver appearance and the cornea appeared thickened. There was a large iris hole at five o'clock. Intraocular pressures were 16 mm Hg in the

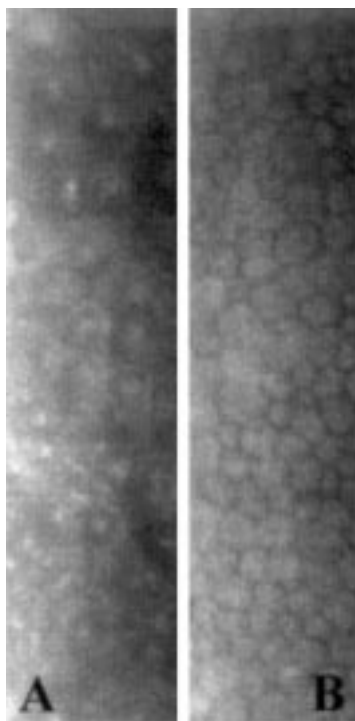


Figure 4 Specular microscopy. (A) Rounded dark cells with light borders and occasional light bodies within cell boundaries could be identified in the endothelium of the abnormal cornea. (B) In the fellow eye, the endothelium exhibited polymegathism, but no characteristics of ICE syndrome.

right eye and 18 mm Hg in the left. The remainder of the ocular examination was normal.

Measurement of the corneal thickness by ultrasound pachymetry confirmed the clinical impression of early endothelial decompensation in the left eye. The right cornea measured 550 μm versus 617 μm in the left eye. Specular microscopy of the left eye revealed the presence of rounded dark cells with light borders and occasional light bodies within cell boundaries (Fig 4A). In the right eye, specular microscopic examination showed moderate endothelial polymegathism (Fig 4B). On confocal microscopy the right eye presented moderate endothelial polymegathism. In the left eye, groups of hyperreflective epithelial-like endothelial cells with highly reflective nuclei were seen (Fig 5A). Other groups of cells had hyporeflexive cytoplasm and hyperreflective boundaries and nuclei. They resembled the confocal microscopic appearance of epithelial wing cells (Fig 5B).¹⁴ Both groups of cells conserved the regular pattern of normal endothelium. In other areas, frankly abnormal cells with hyperreflective nuclei were detected (Fig 5C). They strongly mimic the appearance of corneal surface epithelial cells,¹⁴ and cellular regularity in shape and size was lost. Small hyperreflective structures were found within and adjacent to these abnormal areas. Finally, relatively normal appearing cells adjacent to abnormal areas could be found.

CASE 3

A 53 year old nurse previously diagnosed with the ICE syndrome volunteered to participate

in the study. She had been diagnosed with unilateral glaucoma for at least 2 years and progressive iris atrophy was noted in the right eye. Uncomplicated trabeculectomy with mitomycin C application was performed 4 months

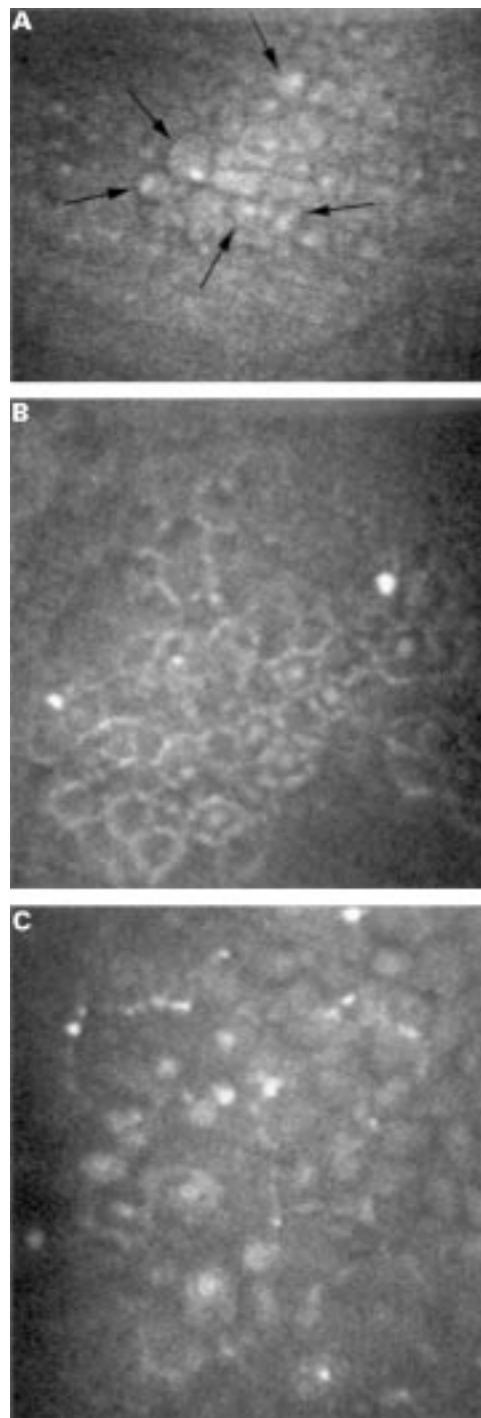


Figure 5 Confocal microscopy (original magnification $\times 210$). (A) Epithelial-like endothelial cells with well recognisable nuclei, of which some are indicated by arrows, were detected. Note the regularity of the cells. (B) Less hyperreflective cell bodies with central hyperreflective nuclei resembling the confocal microscopic appearance of epithelial wing cells were seen. The cells were relatively regular in size and shape. (C) Areas of highly abnormal cells characterised by marked epithelial-like appearance and loss of regularity in size and shape were found. Hyperreflective structures were found within and adjacent to these abnormal areas. Relatively normal appearing endothelial cells were also detected (upper right corner of the photograph).

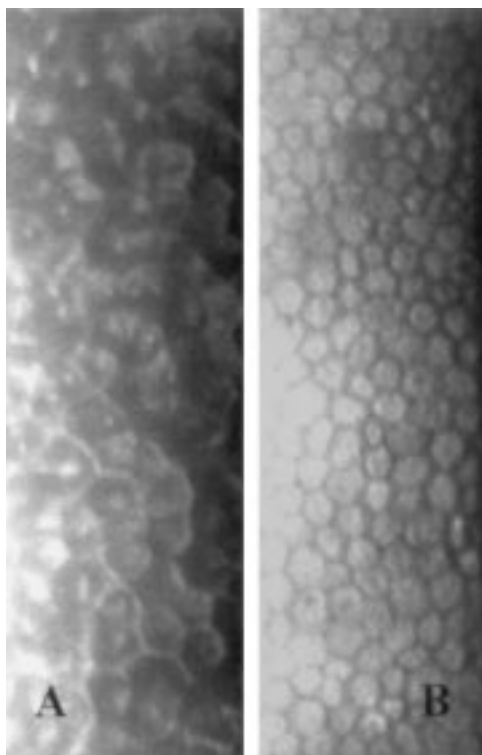


Figure 6 Specular microscopy. Endothelial cells are seen with dark/light reversal and occasional central bright reflex in the clinically abnormal eye (A), not in the normal eye (B).

earlier in the right eye. She was treated with topical fluorometholone 0.1% twice daily and diclofenac sodium 0.1% four times daily in the right eye. Her best corrected visual acuity was 20/30 in the right eye and 20/20 in the left eye. The right cornea had a well formed filtering bleb and the endothelium had a hammered silver appearance. The iridocorneal angle was open with visible trabecular meshwork for 360 degrees and visible ciliary processes for 330 degrees. The pupil was ectopic with an intact margin and the iris had a large peripheral hole inferonasally creating a pseudopupil. Slit lamp examination of the left eye was unremarkable. Intraocular pressure was 9 mm Hg in the right eye and 15 mm Hg in the left eye. No other abnormalities were found.

Corneal thickness was 521 μm in the right eye and 514 μm in the left eye. Specular microscopy showed abnormal endothelial cells with

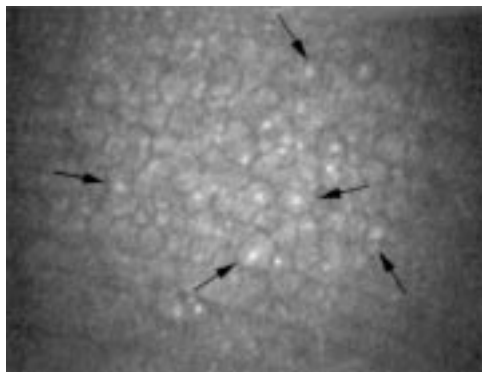


Figure 7 Confocal microscopy (original magnification $\times 210$). The arrows indicate some epithelial-like endothelial cells with nuclear hyperreflectivity.

dark light reversal and occasional central bright reflex in the right eye (Fig 6A). The endothelium of the left eye appeared normal (Fig 6B). Confocal microscopy of the endothelium revealed the presence of epithelial-like cells in the right eye (Fig 7). Nuclei could be visualised with the abnormal cell morphology. The cells were relatively regular in size and shape.

Discussion

Specular microscopy is an invaluable diagnostic tool in the ICE syndrome. Demonstration of typical endothelial changes allows confirmation of the diagnosis.¹⁵ However, in cases of corneal decompensation, as may occur in the ICE syndrome, its use may be precluded by the thickened, oedematous cornea. Advantages of confocal microscopy include high resolution imaging of the cells at all layers of the cornea. Reports of confocal microscopic findings in corneal diseases are essential in making the confocal microscope a clinically valuable diagnostic tool.

The ICE syndrome should be distinguished from posterior polymorphous dystrophy. The definite diagnosis may be made by specular microscopy. Abnormal endothelial cells with dark/light reversal, as found in patients 2 and 3, are pathognomonic of the ICE syndrome.^{15, 16}

In patient 1, specular microscopy was prevented by corneal oedema. Therefore, other diagnostic criteria had to be used. Clinical features helped to distinguish the two entities. Unlike in posterior polymorphous dystrophy, which is bilateral, the presentation of patient 1 was unilateral. Furthermore, features in posterior polymorphous dystrophy include vesicles, banding, or Descemet's membrane opacity at the level of the endothelium, while the hammered silver appearance of the endothelium found in patient 1 was compatible with the diagnosis of the ICE syndrome. It should be noted that Fuchs' endothelial dystrophy may also present a hammered silver endothelial appearance. However, histopathological examination in our case excluded its eventuality. A herpetic origin was very unlikely because of lack of keratic precipitates, iritis, and response to topical steroids.

Our study suggests that the ICE syndrome may have three "epithelioid" presentations on confocal microscopy: epithelial-like cells with regular shape and size, cells resembling the appearance of epithelial wing cells on confocal microscopy, or highly disorganised cells frankly mimicking the appearance of surface corneal epithelial cells. Hyperreflective nuclei, which are found under normal conditions in the corneal epithelium but not in the endothelium, were common to the three presentations. Findings of epithelial features correlate well with previous histopathological reports. Histologically, populations of abnormal endothelial cells, named ICE cells, are characteristic of the disorder. They were found to be morphologically and immunohistochemically similar to corneal epithelial cells.^{17, 18} The ability to differentiate epithelial from endothelial phenotype is a diagnostic characteristic that is not provided by specular microscopy.

When examined by transmission electron microscopy, human Descemet's membrane is composed of a thin non-banded layer adjacent to the stroma, an anterior banded zone composed of wide spaced collagen forming a highly ordered array, and a posterior amorphous unbanded zone.¹⁹ Diseases such as the ICE syndrome have been reported with large amounts of wide spaced collagen deposition posterior to Descemet's membrane.²⁰ However, this abnormal collagen deposition could not be identified in our patients.

It should be pointed out that, in patient 1, microvilli on the surface of endothelial cells seen by electron microscopy might represent a regenerative activity. In patient 2, it is not clear whether the previous phacoemulsification might have contributed to the changes. In our opinion this is unlikely, since long term changes following phacoemulsification usually consist of cell loss rather than endothelial metaplasia.²¹ In this patient, the exact nature of the hyperreflective structures is unknown. They do not appear to be cells of immune origin. They might represent keratin or other products secreted by the epithelioid metaplastic cells. Alternatively, they might represent cellular debris or products of cellular degeneration from the epithelial-like cells or even stressed endothelial cells. Further investigation of these materials is necessary to determine their composition and origin. Finally, endothelial polymegathism in the fellow eye in patient 2 has previously been reported in the ICE syndrome.²²

It should be noted that epithelial-like endothelial cells have also been reported in posterior polymorphous dystrophy.²³⁻²⁵ It is not clear whether confocal microscopy may allow us to differentiate epithelial-like changes in the ICE syndrome from those found in posterior polymorphous dystrophy.

Cavanagh *et al* presented a case of ICE syndrome in a 18 year old patient.²⁶ Using confocal microscopy they found epithelial-like endothelial cells, where nuclei could also be identified. They did not describe changes in Descemet's membrane. In their case, the abnormal endothelial cells were relatively regular in shape and size and still conserved tissue architecture reminiscent of normal endothelial cells, just as in patients 1 and 3 of our study. In contrast, our second patient, who was much older, also presented frankly disorganised, abnormal, and epithelial-like cells. We hypothesise that the regular epithelial-like cells, seen in younger patients, represent an early stage of the disease, where the characteristic organisation of the endothelium is still preserved. As the disease progresses, the abnormal cells may become more irregular in size, shape, and reflectivity, and more epithelioid, thereby losing the tissue characteristics of the endothelium. This theory is supported by recent data suggesting that the epithelial-like cells result from endothelial metaplasia.² It is possible that with more advanced metaplasia, the endothelial cells would undergo more epithelioid changes and lose their regular pattern. Of interest is the coexistence of

normal appearing endothelial cells and abnormal epithelial-like cells within the same cornea found in patient 2. It is compatible with the hypothesis that the abnormal cells would stem from one cell or a group of endothelial cells. These speculations correlate with previous evidence suggesting that some endothelial cells were undergoing a degenerative change while others were transforming into ICE cells.²⁷ However, this evidence needs to be validated by additional confocal microscopic observations and further studies are needed to understand the pathophysiological mechanisms leading to the endothelial changes in the ICE syndrome.

Confocal microscopy is a diagnostic tool with much potential. It may allow rapid diagnosis of the ICE syndrome by demonstrating epithelial-like endothelial cells with hyperreflective nuclei. It is especially of value in cases of Chandler's syndrome, where corneal oedema may prevent examination of the endothelium by specular microscopy.

This study was supported in part by US Public Health Service grants EY00346 (SCK), EY02580 (HEK), and EY02377 (HEK) from the National Eye Institute, National Institutes of Health, Bethesda, MD, USA; Department of the Army, Cooperative Agreement DAMD17-93-V-3013. (This does not necessarily reflect the position or the policy of the government, and no official endorsement should be inferred.) (RWB, HEK); an unrestricted departmental grant from Research to Prevent Blindness, Inc, New York City, NY, USA; Société Académique Vaudoise (AGYC), Switzerland; the Swiss National Research Foundation (AGYC), Switzerland; and Verrey Foundation (AGYC), Switzerland.

The authors do not have any commercial or proprietary interest in the products or companies cited in this article. The authors do not have any financial interest and have not received payment as consultants, reviewers, or evaluators.

- Campbell DG, Shields MB, Smith TR. The corneal endothelium and the spectrum of essential iris atrophy. *Am J Ophthalmol* 1978;**86**:317-24.
- Howell DN, Damms T, Burchette JL Jr, *et al*. Endothelial metaplasia in the iridocorneal endothelial syndrome. *Invest Ophthalmol Vis Sci* 1997;**38**:1896-901.
- Beuerman RW. Confocal microscopy: into the clinic. *Cornea* 1995;**14**:1-2.
- Kaufman SC, Beuerman RW, Kaufman HE. Diagnosis of advanced Fuchs' endothelial dystrophy with the confocal microscope. *Am J Ophthalmol* 1993;**116**:652-3.
- Chiou AGY, Cadez R, Böhnke M. Diagnosis of Dieffenbachia induced corneal injury by confocal microscopy. *Br J Ophthalmol* 1997;**81**:168-9.
- Kaufman SC, Chew SJ, Capps SC, *et al*. Confocal microscopy of corneal penetration by tarantula hairs. *Scanning* 1994;**16**:312-5.
- Cavanagh HD, McCulley JP. In vivo confocal microscopy and acanthamoeba keratitis. *Am J Ophthalmol* 1996;**121**:207-8.
- Chew SJ, Beuerman RW, Assouline M, *et al*. Early diagnosis of infectious keratitis with in vivo real time confocal microscopy. *CLAO J* 1992;**18**:197-201.
- Florakis GJ, Moazami G, Schubert H, *et al*. Scanning slit confocal microscopy of fungal keratitis. *Arch Ophthalmol* 1997;**115**:1461-3.
- Pfister DR, Cameron JD, Krachmer JH, *et al*. Confocal microscopy findings of acanthamoeba keratitis. *Am J Ophthalmol* 1996;**121**:119-28.
- Shah GK, Pfister D, Probst LE, *et al*. Diagnosis of microsporidial keratitis by confocal microscopy and the chromatope stain. *Am J Ophthalmol* 1996;**121**:89-91.
- Sutphin JE, Kantor AL, Mathers WD, *et al*. Evaluation of infectious crystalline keratitis with confocal microscopy in a case series. *Cornea* 1997;**16**:21-6.
- Winchester K, Mathers WD, Sutphin JE. Diagnosis of Aspergillus keratitis in vivo with confocal microscopy. *Cornea* 1997;**16**:27-31.
- Tomii S, Kinoshita S. Observations of human corneal epithelium by tandem scanning confocal microscope. *Scanning* 1994;**16**:305-6.
- Hirst LW, Quigley HA, Stark WJ, *et al*. Specular microscopy of iridocorneal endothelial syndrome. *Am J Ophthalmol* 1980;**89**:11-21.
- Laganowski HC, Sherrard ES, Muir MG, *et al*. Distinguishing features of the iridocorneal endothelial syndrome and posterior polymorphous dystrophy: value of endothelial specular microscopy. *Br J Ophthalmol* 1991;**75**:212-6.
- Hirst LW, Bancroft J, Yamauchi K, *et al*. Immunohistochemical pathology of the corneal endothelium in irido-

- corneal endothelial syndrome. *Invest Ophthalmol Vis Sci* 1995;**36**:820-7.
- 18 Levy SG, McCartney AC, Baghai MH, et al. Pathology of the iridocorneal endothelial syndrome. The ICE-cell. *Invest Ophthalmol Vis Sci* 1995;**36**:2592-601.
- 19 Johnson DH, Bourne WM, Campbell RJ. The ultrastructure of Descemet's membrane. I. Changes with age in normal corneas. *Arch Ophthalmol* 1982;**100**:1942-7.
- 20 Levy SG, Moss J, Sawada H, et al. The composition of wide-spaced collagen in normal and diseased Descemet's membrane. *Curr Eye Res* 1996;**15**:45-52.
- 21 Sugar A. Surgical trauma: pseudophakic and aphakic corneal edema. In: Krachmer JH, Mannis MJ, Holland EJ, eds. *Cornea*. St Louis: Mosby, 1996:1423-35.
- 22 Lucas-Glass TC, Baratz KH, Nelson LR, et al. The contralateral corneal endothelium in the iridocorneal endothelial syndrome. *Arch Ophthalmol* 1997;**115**:40-4.
- 23 Boruchoff SA, Kuwabara T. Electron microscopy of posterior polymorphous degeneration. *Am J Ophthalmol* 1971;**72**:879-87.
- 24 Richardson WP, Hettinger ME. Endothelial and epithelial-like cell formations in a case of posterior polymorphous dystrophy. *Arch Ophthalmol* 1985;**103**:1520-4.
- 25 Rodrigues MM, Sun TT, Krachmer J, et al. Epithelialization of the corneal endothelium in posterior polymorphous dystrophy. *Invest Ophthalmol Vis Sci* 1980;**19**:832-5.
- 26 Cavanagh HD, Petroll WM, Alizadeh H, et al. Clinical and diagnostic use of in vivo confocal microscopy in patients with corneal disease. *Ophthalmology* 1993;**100**:1444-54.
- 27 Lee WR, Marshall GE, Kirkness CM. Corneal endothelial cell abnormalities in an early stage of the iridocorneal endothelial syndrome. *Br J Ophthalmol* 1994;**78**:624-31.