

“Orientation teeth” in non-mechanical laser corneal trephination for penetrating keratoplasty: 2.94 μm Er:YAG *v* 193 nm ArF excimer laser

Ashley Behrens, Berthold Seitz, Michael KÜchle, Achim Langenbacher, Murat M Kus, Carmen Rummelt, Gottfried O H Naumann

Abstract

Background/claims—“Orientation teeth” at the donor trephination margin and correspondent “notches” at the host margin facilitate graft orientation and avoid “horizontal torsion” induced by asymmetric suture placement. In this study the quality and reproducibility of these structures created by non-mechanical laser corneal trephination were compared using two laser emissions.

Methods—The procedure was performed in 20 enucleated pigs’ eyes using open metal masks with eight “orientation teeth/notches” (0.3 \times 0.15 mm, base \times height), an automated globe rotation device, and either a 193 nm ArF excimer laser or a Q switched 2.94 μm Er:YAG laser. “Teeth/notches” were analysed by planimetry and scanning electron microscopy (SEM).

Results—Mean size was 0.30 (0.027) \times 0.16 (0.017) mm for “teeth” and 0.30 (0.035) \times 0.15 (0.021) mm for “notches” (excimer), and 0.31 (0.022) \times 0.16 (0.015) mm and 0.30 (0.031) \times 0.14 (0.021) mm respectively (Er:YAG). Overall, variability of notches was higher than that of teeth. By SEM, comparable cut regularity and sustained ablation profile were observed with both lasers. However, the corneal surface at the cut edge appeared slightly elevated ($\leq 35 \mu\text{m}$) in the Er:YAG group.

Conclusion—Orientation teeth/notches resembling those obtained with the excimer laser can be created using the Q switched Er:YAG laser, with potential advantages of lower costs, convenient equipment size, and solid state safety.

(Br J Ophthalmol 1999;83:1008-1012)

Department of
Ophthalmology,
University of
Erlangen-Nürnberg,
Erlangen, Germany

A Behrens
B Seitz
M KÜchle
A Langenbacher
M M Kus
C Rummelt
G O H Naumann

Correspondence to:
Berthold Seitz, University
Eye Hospital,
Schwabachanlage 6,
D-91054 Erlangen,
Germany.

Accepted for publication
16 April 1999

Excimer lasers are now successfully used as non-mechanical corneal trephines, with the advantages of reducing the “vertical tilt” commonly observed using conventional trephines, and the possibility of creating “orientation teeth” and “notches” at the cut edge.¹⁻⁴ The centration of the trephination is improved, since the precise cut location can be observed directly after placing the mask on the cornea.⁵ Virtually any shape of trephination and cut angles are feasible by changing the beam incidence angle or the mask configuration.⁶⁻⁸

These laser moulded structures may be advantageous for several reasons: (1) as a visual aid for the surgeon in the placement and orientation of the graft in its host bed; (2) the

“fitting” of the donor button in its correspondent recipient cornea is tighter, resembling a “key in a keyhole” coupling; (3) the correct placement of cardinal and secondary sutures is easily achieved; (4) “teeth” and “notches” are almost full thickness structures, and they “anchor” the donor button in its correspondent recipient bed, decreasing the “horizontal torsion” induced either by continuous suturing or with inadvertent non-radial interrupted suturing; (5) “harmonisation” of the donor and recipient topography is possible using one larger “reference tooth” to obtain a more regular postoperative surface.¹⁻⁹⁻¹¹

More than 600 post-keratoplasty procedures have been performed using this method in our department, which has become our standard trephination procedure for non-vascularised processes of the cornea. Results of a prospective randomised study have shown lower keratometric astigmatism, a higher regularity of corneal topography, and improved best corrected visual acuity up to two decimal lines after non-mechanical trephination.^{1 12 13}

In this study using porcine eye corneas, we compared the cut profile of the 193 nm excimer laser *v* the 2.94 μm Er:YAG laser to create orientation teeth in corneal donor buttons and correspondent notches in recipient beds.

Materials and methods

GLOBE PREPARATION

Twenty pig eyes were obtained from the slaughter house (respecting the ARVO statement for the use of animals in ophthalmic and vision research), and were submitted to a non-mechanical laser corneal trephination. The globes were injected with saline solution through the optic nerve with a 26 gauge cannula and placed in a metal cylinder head, part of a motorised rotation device, with a speed of one turn/minute. Intraocular pressure was maintained at 15–20 mm Hg, measured after the globes were placed in the metal cylinder by Schiotz tonometry. The eyes were divided in two groups (n=10) according to the type of laser used: group 1 for the Er:YAG laser and group 2 for the excimer laser. The procedure was performed no more than 12 hours after enucleation.

LASER EQUIPMENT

Two types of laser delivery systems were used: an ArF 193 nm excimer laser (Aesculap-Meditec MEL 60, Jena, Germany) and a Q




Figure 1 Open metal masks (detail $\times 30$). (A) Recipient mask, showing two "notches" in the internal circumference (arrows). (B) Donor mask, showing two peripheral "orientation teeth" at the external circumference (arrowheads).

switched Er:YAG 2.94 μm laser (NWL Laser Technologie, Ottenssoos, Germany). The excimer laser variables were set at 20 mJ/pulse energy, 25 Hz repetition rate, 1.5×1.5 mm spot size, and 25 ns pulse duration. The Q switched Er:YAG laser variables were set at 10 mJ/pulse energy, 2 Hz repetition rate, 0.4 mm spot size, and 1 μs pulse duration. Both laser variables were selected according to former studies of optimal response in corneal tissue.

The laser emission arms were fixed over the operating table, and both beams were positioned at 90° to the surface of the table.

TREPHINATION MASKS

Two open stainless steel masks, 0.5 mm thick, were used. Donor mask weighed 0.18 g, and was provided with eight triangular shaped orientation teeth (0.30 mm \times 0.15 mm, base \times height) located at the external circumference of 8.1 mm diameter and 3 mm diameter central aperture as an aid for centration. The recipient mask weighed 0.4 g, was provided with eight notches, of the same size and reciprocal to the donor mask, in an internal circumference of 8.0 mm diameter and a 13 mm total diameter (Fig 1).

TREPHINATION PROCEDURE

The metal masks were positioned on the cornea, and centred on the pupil. The laser aiming beam pointed towards the margin of the mask, with approximately one half spot on the mask and the other half on the cornea.

The incidence of the laser beam was parallel to the optical axis. The trephination started with the rotating movement and the emission of the laser. The procedure was stopped after approximately 7 minutes 30 seconds with the Er:YAG laser and 4 minutes 30 seconds with

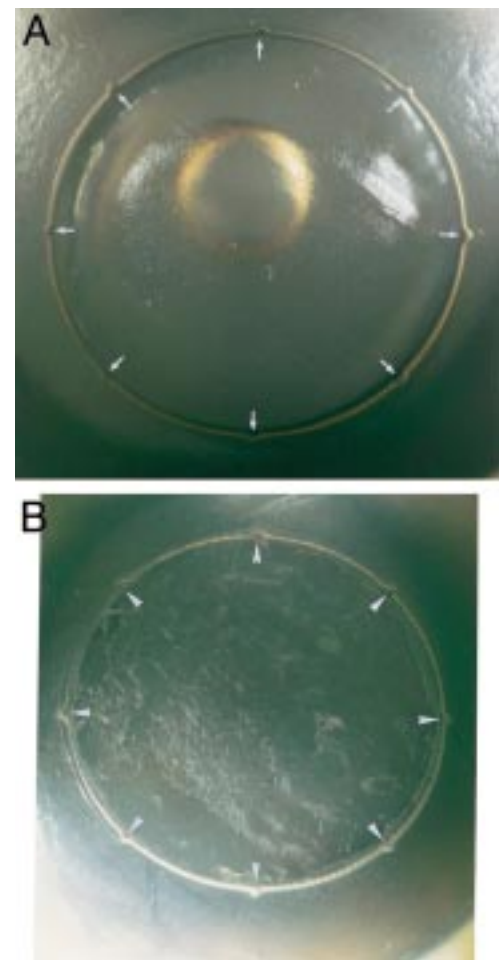


Figure 2 Cut surface in host corneas. (A) Excimer laser cut showing eight full depth "notches" (arrows) in a recipient bed ($\times 9.5$). (B) Er:YAG laser cut with eight notches (arrowheads) in a recipient bed ($\times 8$).

the excimer, since the time until perforation has been measured to be in the order of 8 minutes with the Er:YAG laser and 5 minutes with the excimer laser using these variables.¹² Perforation was intentionally avoided to obtain more accuracy in measuring the dimensions of the "teeth/notches", since the globes tend to deform and collapse once it is achieved. Therefore, donor and recipient button measurements of teeth and notches were performed in situ on the corneas.

MACROSCOPIC AND MICROSCOPIC ANALYSIS

After the procedure the eyes were fixed in 10% buffered paraformaldehyde solution for 24 hours. Macroscopic photography of each pair of teeth and notches at $\times 30$ magnification was recorded for planimetry. After fitting a triangle to the projected orientation tooth of the mask on the cornea, base and height of the triangle were measured as the base and height of the projected orientation tooth. These were the selected values for the statistical study. The same approximation was applied to the projected notches.

Four teeth and four notches of each case were selected for the analysis. The regularity of the cut was semiquantitatively assessed in three categorical levels, in ascending order of irregu-

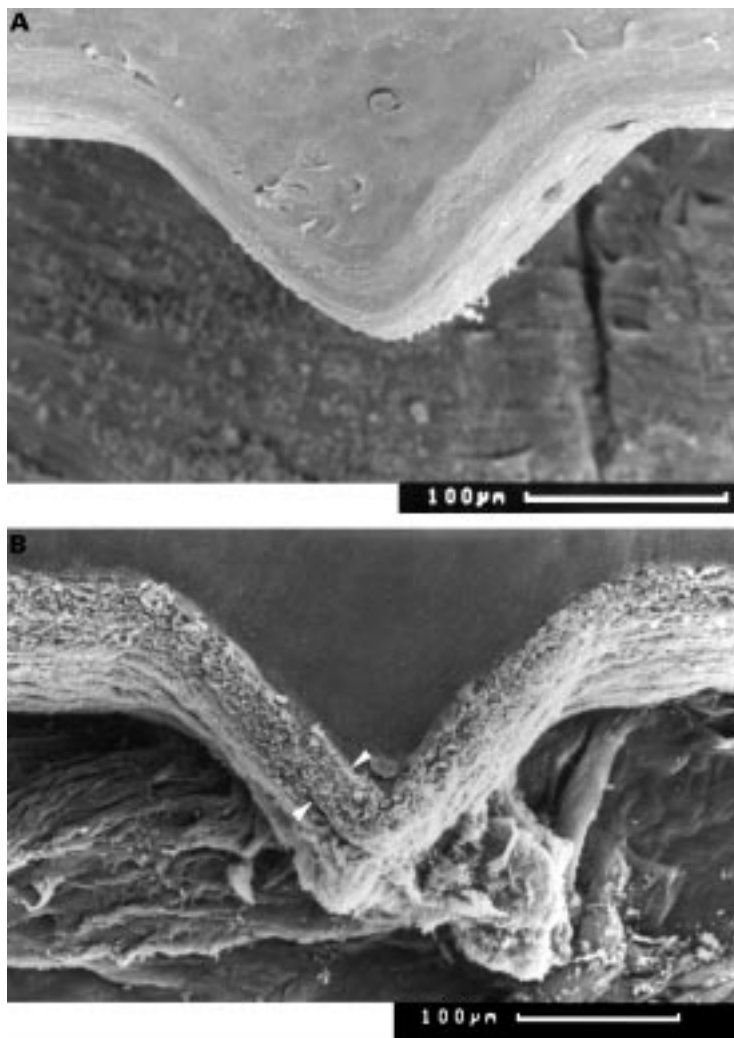


Figure 3 Scanning electron microscopy of "orientation teeth". (A) Excimer laser cut showing the triangular "orientation teeth" ($\times 160$). (B) Er:YAG cut of one orientation tooth at the margin of a donor cornea. An elevated surface of up to $35 \mu\text{m}$ can be observed (between arrowheads) ($\times 150$).

larity: I (regular cut), II (moderately regular), and III (irregular cut).

Selected cases were submitted to scanning electron microscopy (SEM) for analysis of the cut edge profile. These specimens were dehydrated in graded acetone 50%–100%, dried to critical point, sputtered with gold, and examined with a scanning electron microscope (Cam Scan, Dortmund, Germany).

STATISTICAL ANALYSIS

SPSS/PC 6.1.3 (Windows) was used. Dimensional variables were described with mean and standard deviation. Comparisons between groups or variables were performed using non-parametric tests (Mann–Whitney U test for unpaired samples, Wilcoxon test for paired samples). A p value ≤ 0.05 was considered statistically significant.

Results

No complications were observed during the procedure, although the guiding of the laser beam of the Er:YAG laser was more difficult to maintain on the margin of the mask, because its spot size was smaller.

MACROSCOPIC ANALYSIS

The groove created by the laser between the trephination edge and the rest of the cornea (recipient button in hosts and peripheral cornea in donors) was narrowed in the Er:YAG group. Consequently, a manual anterior lamellar keratectomy was performed at the residual corneas in this group to observe the cut surface details. In the excimer laser group the width of the groove was greater, therefore the keratectomy was not required (Fig 2).

In both groups of trephination the cut edges appeared macroscopically very similar. The corneal surface was regular and showed no wrinkles, such as those we have formerly observed using the Er:YAG laser in the free running mode.¹⁴ Both lasers produced teeth and notches of the same sizes. The mean dimensions of the projected "orientation tooth/notch" were $0.31 (0.027) \times 0.16 (0.017)$ mm for donors and $0.30 (0.035) \times 0.14 (0.021)$ mm for recipients in group 1, and $0.30 (0.022) \times 0.16 (0.015)$ mm for donors and $0.30 (0.031) \times 0.15 (0.021)$ mm for recipients in group 2. The difference in the size between both groups was not statistically significant. Variability of the notches in the recipient corneas was higher than of the teeth in the donor corneas. The mean width of the teeth and notches at the deepest level of ablation was maintained in both recipient and donor corneas using both lasers.

MICROSCOPIC ANALYSIS

By SEM, a regular and constant cut was observed in the two groups. However, a smoother cut at the corneal surface was seen in the excimer laser group: a well defined margin with no further alterations of tissue. In the Er:YAG laser group, a superficial elevation of up to $35 \mu\text{m}$ width along the cut margins was invariably observed (Fig 3).

In both groups the appearance of the teeth/notches was maintained through the depth of the cornea, but separation and "disarrangement" of the stromal lamella was slightly more pronounced in the corneas with the Er:YAG laser. The ablation profile appeared not to be affected by the depth of the cut using both laser systems.

The regularity was somewhat better with the excimer laser: 80% (16) of the teeth and 70% (14) of the notches were found to be in category I and 20% (four) of the teeth and 30% (six) of the notches were found to be in category II. With the Er:YAG laser, 65% (13) of teeth and 55% (11) of the notches were included in the category I and 35% (seven) of teeth and 45% (nine) of the notches were classified as category II. In no single case was the cut found to be irregular (category III). Small vertical grooves of variable width were observed in some parts of the cut surface in the Er:YAG group. These were absent in the trephination performed with the excimer laser.

Discussion

Besides the multiple factors intervening in the appearance and amount of post-keratoplasty astigmatism, the symmetry of the sutures in the

immediate postoperative period and the quality of the trephination cut for the long term “suture out” astigmatism seem to be determining factors.¹⁵⁻¹⁷ Disparities of the donor-host trephination margin (“vertical tilt”), and misalignment of the donor button in its recipient bed (“horizontal torsion”) may have important consequences in the persisting astigmatism.¹⁸⁻²¹

Using conventional mechanical trephination, corresponding points of the recipient to match the donor button when it is placed in the host bed are particularly difficult to locate, especially because of the partial collapse of the peripheral host cornea and sclera after the cornea is perforated, even if scleral fixation rings are used. Moreover, inaccurate placement of the cardinal sutures may contribute to an important circumferential mismatch, subsequent corneal distortion, and increased probability of wound leaks.^{1, 22} Orientation teeth allow the surgeon to position the donor button precisely in its recipient bed and to place the cardinal sutures in the appropriate location, even after corneal distortions due to partial collapse. Furthermore, a visual reference for the placement of the secondary sutures is easily achieved.

Former attempts to create corneal markers to avoid these difficulties have been based on staining or impression procedures that require contact with the corneal surface, potentially inducing some distortion. Likewise, the use of staining seems to offer only a transient orientation, since after repeated “washing” of the corneal surface these temporary marks tend to evanesce.²¹⁻²⁴ Orientation teeth/notches created by non-mechanical laser trephination are persistent marks that are optically moulded at the trephination margin in a non-contact fashion, therefore external forces are not applied and the possibility of corneal distortion is reduced to a minimum.

The geometric characteristics of these teeth could be modified using different masks. Inversion of the teeth/notches, changes in the triangular shape or size to create a “reference” tooth that could aim in a topography guided donor recipient “harmonisation” of the graft, are also possible.⁹⁻¹¹

The higher variability observed with notches in comparison with teeth is probably due to the higher stability of the donor disc in comparison with the recipient button, particularly after the fixation process. The differences obtained using both lasers are probably related to the spot size and the induced thermal effect. A small spot and a low repetition rate could be responsible of the “serrated” aspect observed in some parts of the cut using the Er:YAG laser, because the laser “shots” do not overlap each other. The spot size of the excimer laser is greater, and the possibility of overlapping is higher, therefore a smoother cut surface could be obtained.

The induced thermal effect of the Q switched mode Er:YAG laser (unpublished data) has been detected to be around 2–15 µm, in comparison with only 200 nm using the excimer laser.^{25, 26} This could have some

influence on the corneal shrinkage, as previously observed with the Er:YAG laser in the free running mode,²⁷ resulting in slight dimensional distortions and elevation of the trephination margin observed in the Er:YAG group. However, these changes and their repercussion in the wound healing process or in the final optical results after keratoplasty have not yet been studied in experimental animal models. Further in vivo studies are required to assess their exact role before a clinical attempt to use the Er:YAG laser is planned.

Previous studies of the effects of the free running Er:YAG laser radiation on the endothelial layer have been reported, showing no damage to endothelial cells in keratectomies up to 300 µm in depth.²⁸ Endothelial cell changes using the Q switched pulse modality in perforating incisions are currently being investigated in an animal model.

Results of this study showed no significant differences between the dimensions and shape of the teeth obtained after using a Q switched 2.94 µm Er:YAG laser compared with the 193 nm excimer laser. Both lasers performed macroscopically similar and reproducible cuts.

The possibility of using a Q switched Er:YAG laser for non-mechanical trephination has several advantages, since the characteristics of this equipment in terms of size, ease of use, acquisition maintenance costs, and solid state safety exceed by far that of excimer lasers. A place in non-mechanical trephination with orientation teeth/notches for this type of mid-infrared laser appears to be possible.

This study was supported by the Bayerische Forschungsförderung (Bavarian Research Foundation) Grant No 229/97, and the DAAD (German Academic Exchange Service), Grant No 331 4 04 001 (A Behrens).

- 1 Naumann GOH. Corneal transplantation in anterior segment diseases. The Bowman Lecture (Number 56) Part II. *Eye* 1995;9:395–421.
- 2 Lang GK, Schroeder E, Koch JW, et al. Excimer laser keratoplasty. Part 1: Basic concepts. *Ophthalmic Surg* 1989; 20:262–7.
- 3 Seitz B, Langenbucher A, Kus MM, et al. Regularity of laser keratectomy depth in nonmechanical trephination for penetrating keratoplasty. *Ophthalmic Surg Lasers* 1998;29:33–42.
- 4 Naumann GOH, Seitz B. Excimer laser 193 nm trephination with “orientation teeth” in penetrating keratoplasty. *Ophthalmology* 1992;99(Suppl 9):122.
- 5 Langenbucher A, Seitz B, Kus MM, et al. Graft decentration in penetrating keratoplasty: nonmechanical trephination with the excimer laser (193 nm) versus the motor trephine. *Ophthalmic Surg Lasers* 1998;29:106–13.
- 6 Lang GK, Koch JW, Schröder E, et al. [Configuration of corneal cuts performed with an excimer laser: an experimental study] (in German). *Fortschr Ophthalmol* 1989;86:437–42.
- 7 Lang GK, Naumann GOH, Koch JW. A new elliptical excision for corneal transplantation using an excimer laser. *Arch Ophthalmol* 1990;108:914–5.
- 8 Seitz B, Behrens A, Langenbucher A, et al. Experimental 193 nm excimer laser trephination with divergent cut angles in penetrating keratoplasty. *Cornea* 1998;17:410–6.
- 9 Seitz B, Behrens A, Langenbucher A. Corneal topography. *Curr Opin Ophthalmol* 1997;8(IV):8–24.
- 10 Seitz B, Langenbucher A, Kus MM, et al. Consideration of donor and recipient corneal topography improves graft alignment in penetrating keratoplasty. *Invest Ophthalmol Vis Sci* 1994;35(Suppl 4):1879.
- 11 Seitz B, Langenbucher A, Kus MM, et al. Harmonizing of donor and recipient corneal topography in penetrating keratoplasty: first clinical application. *Ger J Ophthalmol* 1994;3:310.
- 12 Naumann GOH, Seitz B, Lang GK, et al. [193 nm excimer laser trephination in perforating keratoplasty. Report on 70 patients] (in German). *Klin Monatsbl Augenheilkd* 1993; 203:252–61.
- 13 Seitz B, Langenbucher A, Kus MM, et al. Nonmechanical corneal trephination with the excimer laser improves outcome after penetrating keratoplasty. *Ophthalmology* 1999;106:1156–65.

- 14 Behrens A, Küchle M, Seitz B, et al. Stromal thermal effects induced by 2.94 μm Er:YAG laser corneal trephination. *Arch Ophthalmol* 1998;166:1342-8.
- 15 Filatov V, Alexandrakis G, Talamo JH, et al. Comparison of suture-in and suture-out postkeratoplasty astigmatism with single running suture or combined running and interrupted sutures. *Am J Ophthalmol* 1996;122:696-700.
- 16 Assil KK, Zarnegar SR, Schanzlin DJ. Visual outcome after penetrating keratoplasty with double continuous or combined interrupted and continuous suture wound closure. *Am J Ophthalmol* 1992;114:63-71.
- 17 Villacruz E, Rife L, Smith RE. Oval host wounds and postkeratoplasty astigmatism. *Cornea* 1987;6:181-4.
- 18 Naumann GOH. Comparison of suture-in and suture-out postkeratoplasty astigmatism with single running suture or combined running and interrupted sutures (letter). *Am J Ophthalmol* 1997;123:715-6.
- 19 Olson RJ. Corneal curvature changes associated with penetrating keratoplasty: a mathematical model. *Ophthalmic Surg* 1980;11:838-42.
- 20 Troutman RC. Astigmatic considerations in corneal graft. *Ophthalmic Surg* 1979;10:21-6.
- 21 Perlman EM. An analysis and interpretation of refractive errors after penetrating keratoplasty. *Ophthalmology* 1981;88:39-45.
- 22 Pflugfelder SC, Parel JM, Denham D, et al. A suction trephine block for marking donor corneal buttons. *Arch Ophthalmol* 1988;106:276-81.
- 23 Gilbard JP, Rothman RC, Kenyon KR. A new donor cornea marker and punch for penetrating keratoplasty. *Ophthalmic Surg* 1987;18:908-11.
- 24 Duncker GI, Nölle B. [Corneal markers for continuous keratoplasty sutures] (In German). *Klin Monatsbl Augenheilkd* 1995;207:51-2.
- 25 Marshall J, Trokel S, Rothery S, et al. A comparative study of corneal incisions induced by diamond and steel knives and two ultraviolet radiations from an excimer laser. *Br J Ophthalmol* 1986;70:482-501.
- 26 Langenbacher A, Seitz B, Kus MM, et al. Thermal effects in laser trephination of the cornea. *Graefes Arch Clin Exp Ophthalmol* 1996;234:S142-8.
- 27 Seitz B, Küchle M, Behrens A, et al. Donor and recipient shrinkage after circular nonmechanical erbium:YAG laser trephination for penetrating keratoplasty. *Ophthalmic Res* 1997;29(Suppl 1):82.
- 28 Peyman GA, Badaro RM, Khoobehi B. Corneal ablation in rabbits using an infrared (2.9- μm) erbium:YAG laser. *Ophthalmology* 1989;96:1160-70.