

## LETTERS TO THE EDITOR

### Sudden bilateral visual loss in acute myeloid leukaemia

EDITOR.—Intraocular manifestations of leukaemia are not uncommon and may be related to manifestations of the disease itself or to its complications including those of treatment. There may be direct infiltration by neoplastic cells of ocular tissue, including optic nerve, choroid, retina, iris, ciliary body, signs in the retina of associated haematological abnormalities such as anaemia, thrombocytopenia or hyperviscosity states, or retinal destruction by opportunistic infections such as that caused by herpesic viruses. In addition, occlusive retinal microvasculopathy has been reported in patients with acute leukaemia, with radiation considered to be a contributing factor in some cases.<sup>1,2</sup>

#### CASE REPORT

A 20 year old woman with a diagnosis of acute myeloid leukaemia FAB (French, American, British) classification M1, was started on BF-12 chemotherapy consisting of a combination of cytarabine, etoposide, and idarubicin given over 6 days. She had a pancytopenic form of leukaemia with haemoglobin 8.6 (g/dl), white blood count  $1.8 \times 10^9/l$ , neutrophils  $0.2 \times 10^9/l$ , platelets  $42 \times 10^9/l$ , with a hypocellular bone marrow. After 5 days of the protocol she noticed blurring of vision in both eyes; however, ocular examination by a physician revealed normal visual acuity and no obvious abnormality. Over the next 36 hours her vision deteriorated bilaterally to counting

fingers at 25 cm. Initial assessment by the local ophthalmologist showed small dot haemorrhages in the retina with a few peripheral cotton wool spots and marked posterior pole oedema. She underwent urgent computerised tomographic (CT) scan, magnetic resonance imaging (MRI), and lumbar puncture which were normal. Opportunistic infection was suspected on clinical grounds and she was started on antimicrobial therapy to cover cytomegalovirus, herpes simplex, toxoplasmosis, and fungal infection (ciprofloxacin 750 mg three times daily, teicoplanin 400 mg once daily, aciclovir 500 mg three times daily, foscarnet 3 g three times daily, sulphadiazine 1 g four times daily, amphotericin B 50 mg once daily). The vision remained poor and 6 days later she was referred for further ophthalmic assessment. Visual acuity was counting fingers in both eyes, pupils were sluggish, and there were no signs of inflammation or leukaemic infiltration. Fundal appearances were similar in each eye with the retina appearing pale, swollen, and ischaemic (Fig 1). Fluorescein angiography (Fig 2), demonstrated severe bilateral posterior pole infarction with marked retinal oedema. Prednisolone 80 mg per day was started and over the next 48 hours there was a slight increase in her peripheral vision although the large bilateral central scotomata remained. The prednisolone was tapered over the next few weeks and stopped. No further visual improvement occurred over the next few months and the patient was registered blind.

#### COMMENT

Microvascular occlusions involving both the peripheral and posterior pole retina in patients with acute leukaemia usually occur in hyperviscosity syndromes associated with very high white cell or platelet counts. Radiotherapy may be an additional risk factor for its development.

A whole spectrum of small vessel disease, ranging from mild ischaemia with scattered cotton wool spots to proliferative retinopathy<sup>1</sup> appear to be associated with acute leukaemia and its management. A state of hypercoagulability has also been reported after induction chemotherapy which may reflect the release of thromboplastic material from large numbers of destroyed leukaemic cells.<sup>3</sup> The toxic effect of chemotherapy on the microvasculature is also likely to be an important factor.<sup>4</sup> The haemolytic uraemic syndrome has been reported as a complication of intensive chemotherapy involving cytarabine as part of the protocol.<sup>5</sup> Cytarabine is also known to induce central nervous system toxicity particularly affecting the cerebellum in 7–28% of patients,<sup>3</sup> through an unknown mechanism.

This patient had a pancytopenic form of leukaemia and did not have radiotherapy as part of the treatment. A direct neurotoxic effect of the drug is unlikely as only the posterior pole has been affected with preservation of peripheral retina. A picture of toxic microangiopathy resulting from high doses of chemotherapeutic agents could explain the prodromic blurred vision with subsequent microvascular occlusion and ischaemia of the macula. Further observation of the ophthalmic problems in leukaemic patients receiving high dose cytarabine as part of their treatment, with or without associated radiotherapy is warranted.

SYLVIA BOM  
STEPHANIE YOUNG  
SUSAN LIGHTMAN  
Department of Clinical Ophthalmology,  
Institute of Ophthalmology,  
Moorfields Eye Hospital,  
City Road, London EC1V 2PD, UK

Correspondence to: Professor Lightman  
Accepted for publication 26 April 2000

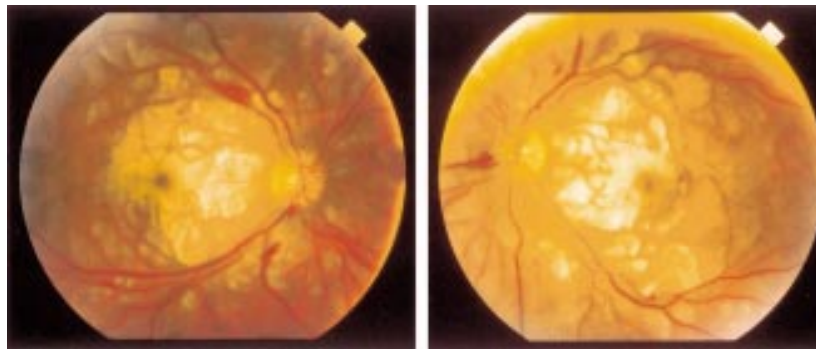


Figure 1 Occlusive vasculopathy involving the posterior pole of both eyes.

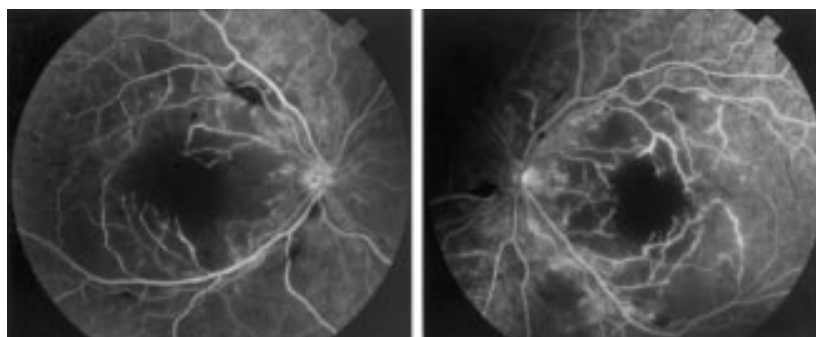


Figure 2 Fluorescein angiography showing preservation of the large arterial vessels and occlusion process of the macular capillaries.

- 1 Wiznia RA, Rose A, Levy AR. Occlusive microvascular retinopathy with optic disc and retinal neovascularization in acute lymphocytic leukaemia. *Retina* 1994;14:253–5.
- 2 Lopez PF, Sternberg P Jr, Dabbs CK, et al. Bone marrow transplant retinopathy. *Am J Ophthalmol* 1991;112:635–46.
- 3 Hiller E, Riess H, Hafter R, et al. Evaluation of hypercoagulability after remission induction chemotherapy of acute leukaemia. *Blut* 1980;41:359–66.
- 4 Herzog RH, Hines JD, Herzig GP, et al. Cerebellar toxicity with high-dose cytosine arabinoside. *J Clin Oncol* 1987;5:927–32.
- 5 Van der Lelie H, Baars JW, Rodenhuis S et al. Hemolytic uraemic syndrome after high dose chemotherapy with autologous stem cell support. *Cancer* 1995;76:2338–42.

### Serous retinal detachment caused by leukaemic choroidal infiltration during complete remission

EDITOR.—Various ocular complications in leukaemia are due to direct invasion by leukaemic cells or haematological abnormalities associated with leukaemia—for example, anaemia, thrombocytopenia, and hyperviscosity states.<sup>1,2</sup> These complications usually occur when the disease is clinically and haematologically active but rarely during complete remission. Moreover, serous retinal detachment is a less common complication, while dilated and tortuous vessels, vascular sheathing, white centred retinal haemorrhages, intraretinal haemorrhages, and cotton wool spots are often seen in the fundus. We describe an uncommon case of a young boy who showed a serous retinal detachment during the first complete remission of his acute lymphocytic leukaemia (ALL).

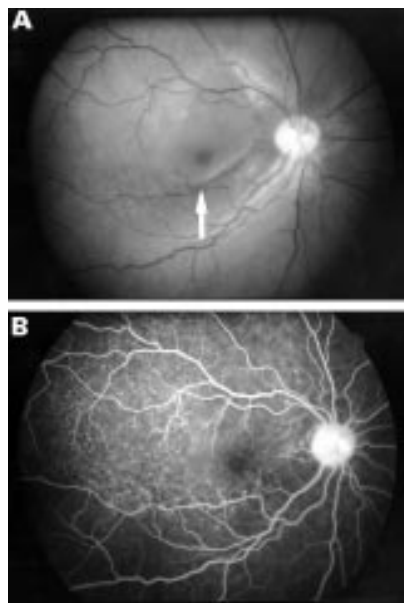


Figure 1 (A) Fundus photograph of the right eye showing serous retinal detachment in the posterior pole (arrow). (B) The corresponding fluorescein angiogram showing numerous dots of early hyperfluorescence beneath the retina.

#### CASE REPORT

A 17 year old boy presented with gradually blurring vision and metamorphopsia in his right eye. ALL had been diagnosed and treated with chemotherapy 9 months earlier. His disease was in complete remission at the time of presentation. Corrected visual acuity was 20/250 in the right eye and 20/15 in the left eye. Fundus examination of the right eye showed a serous retinal detachment involving the fovea in the posterior pole (Fig 1A). There were no retinal holes. The left eye was normal. Fluorescein angiography showed numerous hyperfluorescent dots beneath the retina and diffuse subretinal accumulation of fluorescein with time (Fig 1B). B-scan ultrasonography demonstrated diffuse leukaemic infiltration of the choroid beneath the retinal detachment. Simultaneous A-scan indicated thickening of the choroid to be 2.5 mm (Fig 2). The white blood cell count was  $4.8 \times 10^9/l$  with a normal differential but bone marrow aspiration showed 91.6% lymphoblasts. The patient received systemic chemotherapy immediately. Three weeks later, visual acuity in the right eye improved to 20/20 and the serous retinal detachment decreased markedly.

#### COMMENT

Main fundus manifestations of leukaemia are round or flame-shaped haemorrhages with a white component, intraretinal haemorrhages, and cotton wool spots, comprising what is called "leukaemic retinopathy". These retinal findings are observed commonly but serous retinal detachment is unusual in leukaemia<sup>1,3,4</sup> and even much less common during complete remission.<sup>5</sup> The serous retinal detachment observed in leukaemia is reported to be shallow in the posterior poles. Fluorescein angiography shows multifocal hyperfluorescence beneath the detachment in the early phase and diffuse subretinal accumulation of fluorescein in the late phase, which was also observed in our case. This angiographic finding is probably due to retinal pigment epithelial disturbances secondary to circulatory or metabolic changes in the underlying chorio-

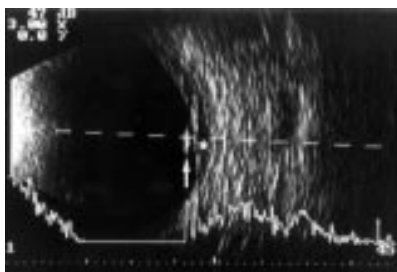


Figure 2 Ultrasonogram of the right eye showing the diffuse leukaemic infiltration of the choroid (asterisk) with serous retinal detachment (arrow).

capillaris. Stewart *et al*<sup>1</sup> postulated that leukaemic infiltration of the choroid caused decreased blood flow in the choriocapillaris, resulting in ischaemia to the overlying retinal pigment epithelium and disruption of the intercellular tight junctions.

If leukaemic choroidal involvement is evident clinically, it usually presents as a serous retinal detachment.<sup>1</sup> However, none of those reporting serous retinal detachments in leukaemia could demonstrate leukaemic infiltration of the choroid even with ultrasonography.<sup>3,4</sup> In contrast, Abramson *et al*<sup>6</sup> reported that leukaemic involvement of the choroid could easily and reliably be detected with contact ultrasonography. Although we could also detect leukaemic infiltration of the posterior choroid with ultrasonography in our case, we could not have found it if it had been much thinner. It may be difficult to detect thin diffuse choroidal infiltration even with ultrasonography, just as it is difficult to diagnose a flat melanoma or diffuse intraocular pseudotumour.<sup>1</sup>

Intraocular manifestations of leukaemia usually are not treated directly. First of all, systemic chemotherapy is attempted. When definite leukaemic infiltrates fail to respond promptly to systemic chemotherapy, ocular radiation is usually recommended.<sup>2</sup> In our case, only systemic chemotherapy was administered but the serous retinal detachment was resolved promptly and the visual acuity in the affected eye improved to 20/20. This case suggested that systemic chemotherapy alone could preserve visual acuity if performed early.

As the rate of remission induction in leukaemic patients increases, ophthalmic examination is becoming more important during remission. Serous retinal detachment caused by leukaemia clinically may mimic a simple central serous chorioretinopathy. Ophthalmologists should bear this in mind in leukaemic patients even in apparent remission.

KAZUAKI MIYAMOTO  
SATOSHI KASHII  
YOSHIHITO HONDA

Department of Ophthalmology and Visual Sciences,  
Kyoto University Graduate School of Medicine,  
Kyoto, Japan

Correspondence to: Kazuaki Miyamoto, MD, Department of Ophthalmology, Kobe City General Hospital, 4-6 Minatojima-Nakamachi, Chuo-ku, Kobe 650-0046, Japan

kazuaki@kuhp.kyoto-u.ac.jp

Accepted for publication 26 April 2000

- 1 Kincaid MC, Green WR. Ocular and orbital involvement in leukemia. *Surv Ophthalmol* 1983;27:211-32.
- 2 Schachat AP, Dhaliwal RS. Leukemias and lymphomas. In: Ryan SJ, ed. *Retina*. 2nd ed. St Louis: CV Mosby, 1994:873-90.
- 3 Tang RA, Vila-Coro AA, Wall S, *et al*. Case report. Acute leukemia presenting as a retinal pigment epithelium detachment. *Arch Ophthalmol* 1988;106:21-2.

- 4 Stewart MW, Gitter KA, Cohen G. Acute leukemia presenting as a unilateral exudative retinal detachment. *Retina* 1989;9:110-4.
- 5 Primack JD, Smith ME, Tychsens L. Retinal detachment in a child as the first sign of leukemic relapse: histopathology, MRI findings, treatment, and tumor-free follow up. *J Pediatr Ophthalmol Strabismus* 1995;32:253-6.
- 6 Abramson DH, Jereb B, Wollner N, *et al*. Leukemic ophthalmopathy detected by ultrasound. *J Pediatr Ophthalmol Strabismus* 1983;20:92-7.

#### Diplopia, ptosis, and hepatitis as presenting signs and symptoms of giant cell arteritis

EDITOR.—Giant cell arteritis (GCA) presents either as localised or systemic vasculitis and is found typically in individuals older than 50 years and is often associated with polymyalgia. GCA involves most frequently the temporal artery and may be bilateral. Other affected vessels include aorta, carotid, vertebral, ophthalmic and, rarely, coronary arteries. Headache, jaw claudication, and scalp tenderness are frequent complaints. Anterior arteritic ischaemic optic neuropathy is the best known, most common, and severe neuro-ophthalmic manifestation. We describe the case of a patient with third and sixth cranial nerve palsy, as well as suspected liver involvement as presenting signs in GCA.

#### CASE REPORT

A 69 year old female patient was referred for examination of ptosis in the right eye and diplopia. The past medical history was unremarkable. One month before admission the patient had suffered from severe headache, loss of appetite, and weight loss. Two weeks later the patient noticed a droopy right eyelid and started to experience double vision.

On examination visual acuity was full in both eyes and the optic discs were normal. Both pupils were equal and reactive. The visual fields were intact. There was ptosis, slight esotropia, and a deficiency in elevation, downgaze, and abduction of the right eye (Fig 1).

Based on these findings the diagnosis of a partial external oculomotor and abducens palsy was made.

Laboratory testing was remarkable for an elevated erythrocyte sedimentation rate (ESR), 75 mm in the first hour, and C reactive protein (CRP) 42 mg/l. The red and white blood cell counts were normal as well as autoimmune antibody titres. Serological antibody titres for herpes virus, cytomegalovirus, Epstein-Barr virus, *Borrelia burgdorferi*, and hepatitis virus types A, B, and C were normal. Liver enzymes were elevated: AST (GOT) 72 IU/l, ALAT (LPT) 121 IU/l, alkaline phosphatase 195 IU/l, gamma GT 235 IU/l. Cerebrospinal fluid revealed normal opening pressure, cell count, glucose, and protein concentration. Except for dysfunction of the ocular motility in the right eye, the neurological examination was normal. Magnetic resonance imaging of the brain (MRI) and a chest x ray were unremarkable. Ultrasound and computed tomography of the abdomen were normal. Histological examination of a fine needle liver biopsy displayed small areas of necrotic changes and low grade lobular inflammation that fitted the morphological diagnosis of non-specific hepatitis (Fig 2A). Colour Doppler imaging (CDI), using a 5-10 MHz broad band linear array transducer, was performed in search of temporal arteritis and reported to be normal. Temporal artery biopsy was therefore performed and therapy

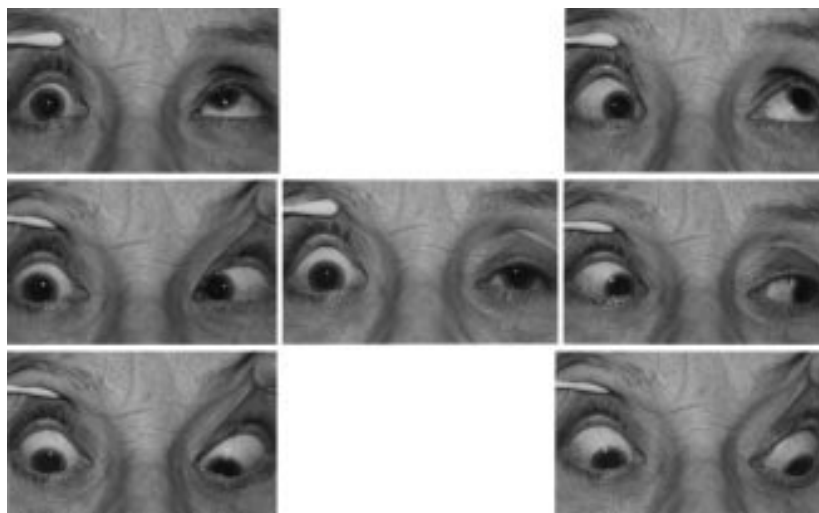

Figure 1 Pretreatment extraocular movements demonstrating partial right oculomotor and abducens palsy. Both pupils are pharmacologically dilated.

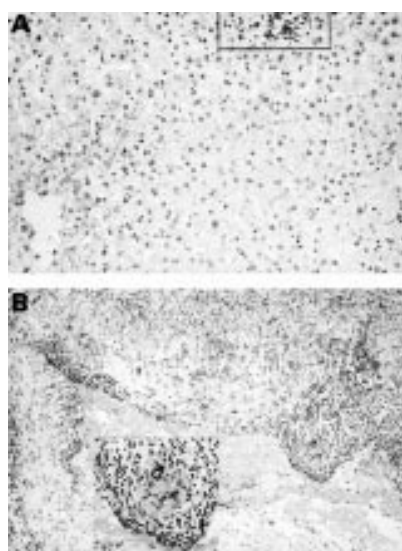


Figure 2 (A) A small solitary leucocytic infiltrate (top margin) was found in a liver biopsy specimen (periodic acid Schiff,  $\times 240$ ). (B) Low power view of a temporal artery. Both intima and media are overrun by a dense inflammatory infiltrate resulting in disruption of the internal elastic lamina; an intimal giant cell lesion is seen in the inset. (Haematoxylin and eosin;  $\times 120$ , inset  $\times 240$ )

with intravenous methylprednisolone (250 mg twice a day) was started immediately. Microscopic examination of the biopsy specimen revealed florid giant cell arteritis (Fig 2B).

Within 3 weeks the oculomotor dysfunction improved rapidly along with normalisation of the ESR, CRP, and all liver factors.

#### COMMENT

Involvement of cranial nerves, such as abducens and oculomotor nerve, leading to diplopia is a known complication of CGA. Diplopia, however, can occur as well without a distinct pattern of cranial nerve involvement.<sup>1-3</sup> Primary affection of the eye muscles and/or cranial nerves has been discussed as pathophysiological mechanisms for ophthalmoplegia. Liver involvement has frequently been reported in patients with GCA and polymyalgia rheumatica and is usually reflected by raised serological liver enzymes.<sup>4-6</sup> In our case, a minute solitary infil-

trate was found in the fine needle liver biopsy specimen; although non-specific, it is consistent with systemic manifestation of GCA, and the return to normal serological parameters of liver function upon steroid medication provides a further argument of this view.

The diagnosis of CGA is based on the history, the clinical picture, and the temporal artery biopsy. Schmidt *et al* suggested that patients with typical clinical signs of GCA and a clear halo on CDI might be treated with steroids without performing a biopsy.<sup>7</sup> In our patient with biopsy proved giant cell arteritis, however, CDI was normal. Although CDI has a high specificity, the sensitivity is still not satisfactory, indicating that for the diagnosis of temporal arteritis histology is still the gold standard. Based on our experience with this patient we would like to emphasise that new onset of ophthalmoplegia can be the first presenting sign of GCA, leading the patient to consult a doctor. We should therefore add GCA to the differential diagnosis in patients with oculomotor and sixth nerve palsies especially when systemic involvement, such as hepatitis, is present.

H E KILLER

Department of Neuroophthalmology,  
Kantonsspital Aarau, CH-5001 Aarau, Switzerland

D J HOLTZ

Division of Angiology

H J KAISER

University Eye Clinic, Basel, Switzerland

R H LAENG

Department of Pathology,  
Kantonsspital Aarau, Switzerland

Correspondence to: Dr Killer

Accepted for publication 26 April 2000

- Ghanchi FD, Dutton GN. Current concepts in giant cell (temporal) arteritis. *Surv Ophthalmol* 1997;42:99-123.
- Hayreh SS, Podhajsky PA, Zimmerman B. Ocular manifestations of giant cell arteritis. *Am J Ophthalmol* 1998;125:509-20.
- Keltner JL. Giant-cell arteritis. *Ophthalmology* 1982;89:1101-10.
- Ilan Y, Ben-Chetrit E. Liver involvement in giant cell arteritis. *Clin Rheumatol* 1993;12:219-22.
- Glick EN. Raised serum-alkaline-phosphatase levels in polymyalgia rheumatica. *Lancet* 1972; 2:328.
- Kyle V, Wraight EP, Hazelman BL. Liver scan abnormalities in polymyalgia rheumatica/giant cell arteritis. *Clin Rheumatol* 1991;10:249-97.
- Schmidt WA, Kraft HE, Vorpahl K. Color duplex ultrasonography in the diagnosis of temporal arteritis. *N Engl J Med* 1997;337:1336-42.

#### Observations on time course changes of the cherry red spot in a patient with Tay-Sachs disease

EDITOR,—Tay-Sachs disease is characterised by lesions in the central nervous systems due to the precipitation of GM<sub>2</sub> trihexosylceramide in neurocytes.<sup>1</sup> Its onset at around 6 months after birth is manifested by mental and emotional retardation together with hypomyotonia and hyperacusis as its typical signs. Subsequently, the patient tends to develop convulsions insidiously and usually dies at 2-4 years of age. A cherry red spot and optic nerve atrophy are the characteristic ophthalmic signs in this disease.

This report deals with observations of a patient with Tay-Sachs disease whose ophthalmic signs were monitored from birth to his death at the age of 5 years 8 months. During this period, a cherry red spot developed and then diminished in both eyes.

#### CASE REPORT

The subject was a boy who was born weighing 1600 g at a gestational age of 36 weeks. Two weeks after birth, ophthalmoscopy disclosed a favourable stretch of retinal blood vessels to the peripheral area without any abnormality of the optic disc and macula in both eyes. Following pursuit movement was observed 5 months after birth. Mental and emotional retardations were manifested beginning at 6 months of age which were precipitated with the onset of afebrile tonic convulsions at the age of 1 year 1 month. Following the convulsions, funduscopy revealed chalk-white macular areas with a cherry red spot in the centre of both eyes. Optic atrophy was present in the left eye and mild paleness in the right eye. Nystagmus with no light fixation was present.

Quantitative analysis of plasma cells and cultured skin fibroblasts revealed a deficiency of  $\beta$  hexosaminidase A enzyme. Immunoelectron microscopy of a biopsy specimen from the rectum disclosed lamellar inclusion body positive for anti-GM<sub>2</sub> antibody, whereby a diagnosis of Tay-Sachs disease was made.

At the age of 1 year 6 months, no alterations were observed in the cherry red spot in both eyes and the optic nerve atrophy in the left eye. However, optic nerve atrophy was now quite evident in the right eye. Thereafter, there were no funduscopic changes as evidenced in the fundus photograph at the age of 2 years 10 months (Fig 1). At the age of 3 years 4 months, however, ophthalmoscopy revealed that the turbidity in the opaque lesions surrounding the cherry red spot in the retina had decreased slightly. The fundus photograph at the age of 5 years 8 months demonstrates a further reduction in the retinal opacity (Fig 2). The patient died at the age of 5 years 8 months.

#### COMMENT

The pathogenesis of Tay-Sachs disease is attributable to the accumulation of GM<sub>2</sub> trihexosylceramide secondary to defects of  $\beta$  hexosaminidase A enzyme. GM<sub>2</sub> trihexosylceramide accumulates predominantly in the retinal ganglion cells whereby retina becomes turbid with a milky-white coloration. The pattern of the coloration is in conformity with the density of the ganglion cells. Strong opacity is observed in the macula area which is characterised by the multilayered ganglion cells, and the opacity is not found in the foveal pit that is devoid of ganglion cells. Eventually, a cherry

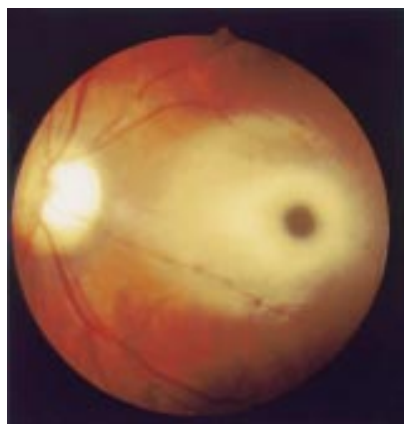


Figure 1 The fundus photograph of the left eye at the age of 2 years 10 months. This shows the cherry red spot and the optic nerve atrophy.

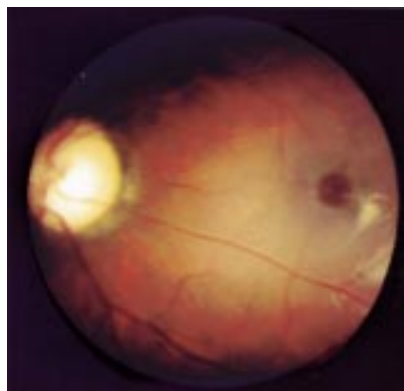


Figure 2 The fundus photograph of the left eye at the age of 5 years 8 months. This shows the reduction in the retinal opacity surrounding the cherry red spot.

red spot develops. In our patient, the macular opacity, in all likelihood, was induced by the accumulation of GM<sub>2</sub> trihexosylceramide in ganglion cells that then decreased over time. It has been reported from cerebral biopsy findings at various phases of this disease that there is a ballooning of the neurons with vacuolisation in the cytoplasm with progression of the disease process.<sup>2</sup> Eventually, there is a disappearance of the neurons resulting in gliosis.

The retina is an extension of the central nervous system, and ganglioside fractions parallel those of the brain.<sup>3,5</sup> The lipids stored in the ganglion cells of the retina have similar histochemical reactivity in the retina as in the brain. Accordingly, it is postulated that, as with the cerebral neurons, hypertrophy is also observed in the retinal ganglion cells, followed by their death and disappearance over time. Finally, there is proliferation of glia cells. These progressive changes probably account for the alleviation of retinal opacity and the loss of the cherry red spot in our patient.

M NAKAYA-ONISHI  
A SUZUKI  
N OKAMOTO  
M FUKUDA

Department of Ophthalmology,  
NTT West Osaka Hospital, 2-6-40 Karasugatsuji,  
Tenmouji-ku, Osaka-shi, Osaka 543-0042, Japan  
Accepted for publication 26 April 2000

1 Okada S, O'Brien JS. Tay Sachs disease: generalized absence of a beta-D-N-acetylhexosaminidase component. *Science* 1969; 165:698-700.

- 2 Korey SR, Terry RD. Studies in Tay-Sachs disease. I: B Clinical and pathologic descriptions. *J Neuropath Exp Neurol* 1963;22:10-7.
- 3 Handa S, Burton RM. Lipids of retina: I. Analysis of gangliosides in beef retina by thin layer chromatography. *Lipids* 1968;4:205-8.
- 4 Cogan DG, Kuwabara T. Histochemistry of the retina in Tay-Sachs disease. *Arch Ophthalmol* 1959;61:414-22.
- 5 Cogan DG, Kuwabara T. The sphingolipidoses and the eye. *Arch Ophthalmol* 1968;79:437-51.

#### Effects of homozygous apolipoprotein A-1 deficiency on the cornea

EDITOR,—Apolipoprotein A-1 (Apo A-1) plays a central part in the metabolism of high density lipoproteins (HDL).<sup>1</sup> Apo A-1 and apolipoprotein A-2 (Apo A-2) make up 80-90% of the protein content of HDL. The characteristics of this deficiency are low levels of HDL serum and Apo A-1, normal levels of triglycerides serum and high levels of LDL serum and total cholesterol.<sup>1-4</sup> HDL concentration is inversely correlated with a risk of coronary heart disease (CHD).<sup>5</sup> However, there is disagreement about the importance of normal Apo A-1 and HDL serum levels in preventing atherosclerosis.<sup>6</sup> Signs of advanced atherosclerosis and early coronary heart disease were only found in some patients with Apo A-1 deficiency,<sup>3,5</sup> and did not appear in other patients.<sup>4,6</sup> Thus, in addition to low Apo A-1 levels, other cardiovascular risk factors must be present to cause premature atherosclerosis.<sup>5,7</sup> Retinopathy, neuropathy, and corneal opacity are associated with this deficiency.<sup>8,9</sup> Our report describes the corneal condition of a 37 year-old Sri Lankan woman with homozygous Apo A-1 deficiency.

#### CASE REPORT

A 37 year old Sri Lankan woman presented complaining of intermittent red eyes. The patient's vision was good and there were no abnormalities in her past general health. She reported having an unusual bluish appearance in her eyes since the age of 15 and reported that her two sisters had a similar corneal appearance, though neither of her brothers or parents were affected (Fig 1). Her parents' marriage was non-consanguineous. On examination her uncorrected visual acuity was 6/5 in both eyes. Both corneas had a dense arcus extending for 360° of the peripheral cornea. The bilateral corneal stromal opacity was slightly denser anteriorly than posteriorly (Fig 2). Corneal thickness was normal. The left eye was mildly injected. Intraocular pressure was normal (15-16 mm Hg) in both eyes throughout the follow up. Dilated fundus examination revealed a normal posterior pole. Specular microscopy, pachymetry, and photography were conducted. Specular microscopy revealed cell counts of 2776/2562 cells/mm right eye and 2826/2456 cells/mm left eye in two successive measurements. Episcleritis with no coincidental systemic disease was provisionally diagnosed. No abnormality was detected on examination of the chest, heart, lungs, neck, and tonsils.

Blood pressure was 120/70. Fasting blood samples were taken for lipids, plasma protein, thyroid function, immunoglobulins, VDRL, FBC, ESR, and IEPG. The patient was treated in both eyes with topical prednisolone sodium phosphate 0.5% four times daily and dexamethasone phosphate 0.1% twice daily. After 1 week the episcleritis disappeared. Blood results showed increased total cholesterol (7.79 mmol/l, normal 3.0-5.5), LDL (5.05 mmol/l, normal 1.7-3.5), and total pro-

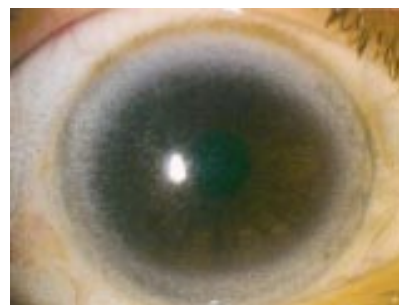


Figure 1 Right eye. Corneal appearance on presentation.



Figure 2 Left eye. Slit lamp appearance: showing increased corneal deposits.

tein (81 g/l, normal 59-78). Normal triglycerides (1.8 mmol/l, normal 0.2-2.0) and apolipoprotein B (1.51 g/l, normal 0.70-1.60) levels were recorded, with decreased HDL cholesterol (0.14 mmol/l, normal 0.83-1.87) and apolipoprotein A-1 (0.15 g/l, normal 1.10-2.00). Serum albumin (45 g/l, normal 37-46) and bilirubin (7 µmol/l, normal 3-18) were within normal range. Immunological serum specimens were negative for all of the above mentioned factors including ANA. Blood TSH level was normal (0.7 µm/l, normal 0.1-3.8). Protein electrophoresis showed increased total protein (87 g/l, normal 63-80), increased α<sub>2</sub> globulin (11 g/l, normal 2-9) with a low α<sub>1</sub> (1.8 g/l, normal 2-4). Blood count was WBC 9.43 × 10<sup>9</sup> g/l (3-10), Hb 12.3 g/dl (11.5-16.5), PLT 375 × 10<sup>9</sup> g/l (150-400) with neutrophil 6.6 × 10<sup>9</sup> g/l (2.0-7.5), lymphocytes 3.3 × 10<sup>9</sup> g/l (0.8-4.0), monocytes 0.6 × 10<sup>9</sup> g/l (0.0-1.0), and eosinophils 0.5 × 10<sup>9</sup> g/l (0.0-0.5). ESR was high (38 mm in the first hour, normal 0-30). A diagnosis of severe homozygous lipoprotein A-1 deficiency syndrome was confirmed. There was no corneal change throughout the 18 months of follow up.

#### COMMENT

The differential diagnosis of our patient's bilateral corneal stromal opacity with advanced arcus senilis included Tangier disease, fish eye disease, Schnyder central crystalline dystrophy, and apolipoprotein A-1 deficiency. Schnyder central crystalline dystrophy is characterised by elevated serum cholesterol. A disc-shaped pattern of cholesterol crystals deposits are located in the centre of the cornea at the level of Bowman's layer and the anterior part of the stroma. Our patient had bilateral diffuse stromal involvement. Tangier disease is characterised by low levels of HDL, apolipoprotein A-1 and LDL, mild hypertriglyceridaemia and cholesterol ester deposition in the tonsils (orange tonsils), liver (hepatomegaly), spleen (splenomegaly), lymph nodes (lymphadenopathy), Schwann cells (peripheral neuropathy), and bone marrow.<sup>10</sup> The low

levels of only HDL and apolipoprotein A-1 in our case enabled us to reject the diagnosis of Tangier disease. Fish eye disease is characterised by low serum levels of HDL and total cholesterol, mild hypertriglyceridaemia, and deficiency of both apolipoprotein A-1 and apolipoprotein A-2.<sup>11</sup> Although our patient's blood level of HDL and apolipoprotein A-1 were both low, the blood level of cholesterol was high and the triglycerides and apolipoprotein A-2 were normal. These findings are uncharacteristic of fish eye disease. Apolipoprotein A-1 deficiency is an autosomal recessive disease. The corneal clouding is due to cholesterol deposition and is affected by the severity of the apolipoprotein A-1 deficiency. The corneal lipid deposits are less dense at the centre and resemble small hazy white dots. In the periphery the denser deposition resembles arcus senilis. Apo A-1 deficiency was confirmed by serum analysis measures, which in our patient was 0.15 g/l (normal 1.1–2.0). Genetic analysis showed that the patient has the homozygous form of apolipoprotein A-1 deficiency. Her high LDL level (6.0 mmol/l normal 1.7–3.5) will need to be lowered with medication in order to prevent future atherosclerosis and coronary heart disease. Although there is no effective treatment for the cornea, an accurate diagnosis is essential in order to treat high LDL and total cholesterol levels and reduce the risk of renal failure and coronary heart disease.

Y DOMNIZ  
G L SUTTON  
M A LAWLESS  
C M ROGERS  
K McCLELLAN  
P CLIFTON-BLIGH  
SUE K WEBBER

The Eye Institute, Sydney, Australia

Correspondence to: Dr Y Domniz, The Eye Institute, Level 3, 270 Victoria Avenue, Chatswood, 2067, Sydney, Australia  
ydomniz@theeyeinstitute.com.au  
Accepted for publication 19 April 2000

- Matsunaga A, Sasaki J, Han H, *et al.* Compound heterozygosity for an apolipoprotein A1 gene promoter mutation and a structural nonsense mutation with apolipoprotein A1 deficiency. *Arterioscler Thromb Vasc Biol* 1999;19:348–55.
- Tilly-Kiesi M, Packard CJ, Kahri J, *et al.* In vivo metabolism of apo A-1 and apoA-2 in subjects with apo A-1 (Lys 107→0) associated with reduced HDL cholesterol and Lp (A1 w A2) deficiency. *Atherosclerosis* 1997;128:213–22.
- Ng DS, Vezina C, Wolever TS, *et al.* Apolipoprotein A-1 deficiency. Biochemical and metabolic characteristics. *Arterioscler Thromb Vasc Biol* 1995;12:2157–64.
- Takata K, Saku K, Ohta T, *et al.* A new case of apo A-1 deficiency showing codon 8 nonsense mutation of the apo A-1 gene without evidence of coronary heart disease. *Arterioscler Thromb Vasc Biol* 1995;11:1866–74.
- Miccoli R, Bertolotto A, Navalesi R, *et al.* Compound heterozygosity for a structural apolipoprotein A-1 variant, apo A-1 (L141R)pisa, and apolipoprotein A-1 null allele in patients with absence of HDL cholesterol, corneal opacifications, and coronary heart disease. *Circulation* 1996;94:1622–8.
- Romling R, Von Eckardstein A, Funke H, *et al.* A nonsense mutation in the apolipoprotein A-1 gene is associated with high-density lipoprotein deficiency and periorbital xanthelasma. *Arterioscler Thromb* 1994;120:1915–22.
- Li H, Reddick RL, Maeda N. Lack of apoA-1 is not associated with increased susceptibility to atherosclerosis in mice. *Arterioscler Thromb* 1993;12:1814–21.
- Huang W, Sasaki J, Matsunaga HA, *et al.* Novel homozygous missense mutation in the apo A-1 gene with apo A-1 deficiency. *Arterioscler Thromb Vasc Biol* 1998;18:389–96.
- Ng DS, O'Connor PW, Mortimer CB, *et al.* Case report: retinopathy and Neuropathy associated with complete apolipoprotein A-1 deficiency. *Am J Med Sci* 1996;312:30–3.

- Serfsty-Lacroisniere C, Civeira F, Lanzberg A, *et al.* Homozygous Tangier disease and cardiovascular disease. *Atherosclerosis* 1994;107:85–98.
- Clerc M, Dumon MF, Sess D, *et al.* A fish eye disease familial condition with massive corneal opacities and hypoalphalipoproteinaemia: clinical, biochemical and genetic features. *Eur J Clin Invest* 1991;21:616–24.

### Acquired capillary haemangioma of the eyelid in an adult treated with cutting diathermy

EDITOR,—Capillary haemangiomas usually present within the first weeks or months of life. Less commonly they can present at birth. To our knowledge only one other report exists of the occurrence of acquired capillary haemangioma of the eyelid in an adult.<sup>1</sup> Our case is the first reported acquired capillary haemangioma to be treated with cutting diathermy.

#### CASE REPORT

A 40 year old man was referred to the oculoplastics clinic for evaluation of a left upper eyelid mass. The lesion first appeared 9 months earlier and had gradually increased in size. The patient was otherwise fit and well—in particular, there was no history of other cutaneous lesions or antecedent trauma.

On examination the visual acuities were 6/6 unaided bilaterally. Examination of the adnexa revealed a dusky red pedunculated mass of the left upper eyelid and a mechanical ptosis (Fig 1). Telangiectatic vessels were noted above the lesion. Clinically the appearance was consistent with a capillary haemangioma. The remainder of the ophthalmic and orbital examination was normal. Excision of the lesion was performed with the Ellman cutting diathermy. Haemostasis was maintained throughout the procedure. The wound was sutured with interrupted 6-0 Prolene.

Histopathological examination of the 1 × 0.7 × 0.6 cm pedunculated nodular mass revealed numerous capillary lumina lined by endothelial cells. No cellular atypia or mitotic figures were noted (Fig 2).

The patient was assessed 2 weeks postoperatively. The wound had healed and the sutures were removed. The previously noted telangiectatic vessels were now not clinically evident. There has been no recurrence of the lesion after 6 months of follow up.

#### COMMENT

Capillary haemangiomas are the most common congenital vascular tumours of the periorbital region.<sup>2</sup> The majority of capillary haemangiomas appear over the first weeks or months of life. The natural history of the lesion is that of increasing size to 1 year of age and then gradual regression during the next 4–5 years. Intralesional corticosteroid injection

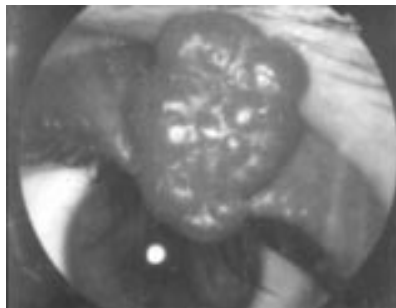


Figure 1 Pedunculated red mass of left upper eyelid.

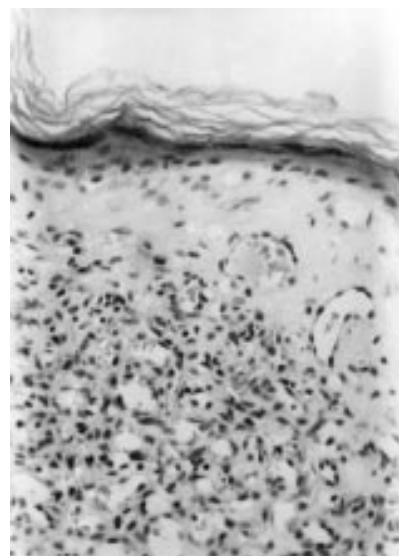


Figure 2 Low power histological section of mass stained with haematoxylin and eosin.

is the current treatment of choice. Other treatment methods employed include excisional biopsy and carbon dioxide laser.

Acquired capillary haemangioma of the eyelid in an adult is a very rare occurrence and has been reported only once in the literature.<sup>1</sup> Our diagnosis was made after exclusion of other similar presenting lesions. The differential diagnosis would include Kaposi's sarcoma, cavernous haemangioma, angiosarcoma, varix, acquired tufted angioma, and intravascular papillary endothelial hyperplasia.

Our choice of treatment proved to be very successful. The lesion was removed in its entirety and the postoperative cosmetic result was excellent. The technique was easy to perform for two reasons; firstly, the Ellman cutting diathermy allowed cutting precision and haemostasis was maintained throughout the procedure. The size of the capillary haemangioma and its location in this case made it essential to incise around the edge of the lesion accurately and therefore avoid the necessity for skin grafting. The Ellman cutting diathermy was particularly well suited to this purpose. We would recommend this method for the treatment of similar lesions.

SUZANNE BRANNAN  
TRISTAN Q REUSER  
JOHN CROCKER

Birmingham Heartlands and Solihull Hospital,  
Department of Ophthalmology, Birmingham

Correspondence to: Dr Brannan  
Accepted for publication 18 April 2000

- Murphy BA, Dawood GS, Margo CE. Acquired capillary haemangioma of the eyelid in a adult. *Am J Ophthalmol* 1997;124:403–4.
- Haik GR, Jakobiec FA, Ellsworth RM, *et al.* Capillary hemangioma of the lids and orbit: an analysis of the clinical features and therapeutic results in 101 cases. *Ophthalmology* 1979;86:760–92.

### Idiopathic sclerosing inflammation of the orbit: a new finding of calcification

EDITOR,—Idiopathic sclerosing inflammation of the orbit (ISIO) is a rare but well described condition.<sup>1–4</sup> There is controversy as to whether it is a condition at one end of the spectrum of non-specific orbital inflammatory syndrome (pseudotumour)<sup>2,5,6</sup> or whether it is

a disease entity in its own right.<sup>1</sup> Its aetiology is not known, although its association with systemic disease and multifocal fibrosclerotic conditions such as Reidel's thyroiditis, retroperitoneal fibrosis, mediastinal fibrosis, and idiopathic pachymeningitis suggests an immunological mechanism.<sup>2-5,7</sup> An autosomal recessive inheritance is suggested by the pedigree of two offspring of a consanguineous marriage, who developed multifocal fibrosclerosis.<sup>8</sup> Diagnosis is complicated by a wide variety of clinical features ranging from mild grittiness to a painful, fixed, blind eye.<sup>9</sup> Often there are no features of active inflammation, and there may be aggressive local destruction of bone with invasion of adjacent structures including brain, meninges, and sinuses.<sup>4,6</sup> Reliable differentiation from lymphoma is only possible with immunohistochemical studies. Management is difficult because of poor response to both steroids and radiotherapy.<sup>4,7</sup> Kennerdell recommends early, aggressive treatment with surgery, steroids, radiotherapy, or a combination.<sup>10</sup> Results of the use of systemic chemotherapeutic agents such as azathioprine and cyclophosphamide, in addition to the above modalities, have been reported by Rootman *et al.*<sup>1</sup>

#### CASE REPORT

A 75 year old woman with bilateral proptosis, marked photophobia, and severe ocular discomfort was referred to the ophthalmology service for an orbital biopsy. She was being investigated for an IgM paraproteinaemia, and the proptosis combined with a haematological disorder suggested orbital lymphoma. There was a history of hypertension and, at presentation, she also had a lower respiratory tract infection.

She had a history of dry eyes, treated with hypromellose eye drops. On examination proptosis measured 23 mm on the right and 21 mm on the left. She had marked restriction of extraocular movement in all directions of gaze in both eyes (Fig 1). Visual acuity with pinhole was 6/9-1 right and 6/12+3 left. There was no relative afferent pupillary defect. Lacrimal glands were not palpable and the globes were tender. Palpebral apertures were 6 mm right and 7 mm left. Levator function was moderate (11 mm) in both eyes. Skin creases were absent bilaterally. The right lower lid was retracted 3 mm with entropion. There was no lid lag or lagophthalmos. The globes were resistant to ballotment. Slit lamp examination revealed bilateral chemosis, asymmetric sectoral vascular pannus containing telangiectatic lumps at the limbus, and extensive punctate corneal epithelial erosions. It was not possible to evert the upper lids. Fundal examination revealed pale optic discs and posterior pole drusen. There was no head or neck lymphadenopathy.

One mm computed tomography with coronal and sagittal reconstructions revealed a bilateral orbital homogeneous infiltrate of soft tissue density, extending preseptally. Calcification was seen bilaterally in the region of the lacrimal fossae and in the central orbit (Fig 2).

Under general anaesthetic, six biopsies were taken from the right lacrimal gland and the left limbal conjunctival mass. Intraoperative forced duction testing was positive in all directions. Histopathology showed monomorphic lymphoid aggregates and fibrous tissue foci entrapping small nerves, consistent with sclerosing lymphoma (Fig 3). The differential diagnosis was of sclerosing inflammation. Immunohistochemistry differentiated be-

tween these two entities, and the final diagnosis was confirmed to be idiopathic sclerosing inflammation of the orbit. Postoperatively, a short course of topical steroids was given for scleritis localised to a biopsy site. The histopathological changes showed minimal active inflammatory changes, and the disease process was so far advanced that anti-inflammatory treatment was not considered helpful in this patient. Symptomatic relief was provided with topical lubricants.

#### COMMENT

Calcification of the orbit has not previously been described in idiopathic sclerosing inflammation of the orbit. The presence of calcification would be consistent with lymphoma, and idiopathic sclerosing inflammation of the orbit may be missed on histopathological examination if the diagnosis is not considered. This case demonstrates the difficulties associated with the diagnosis of idiopathic sclerosing inflammation of the

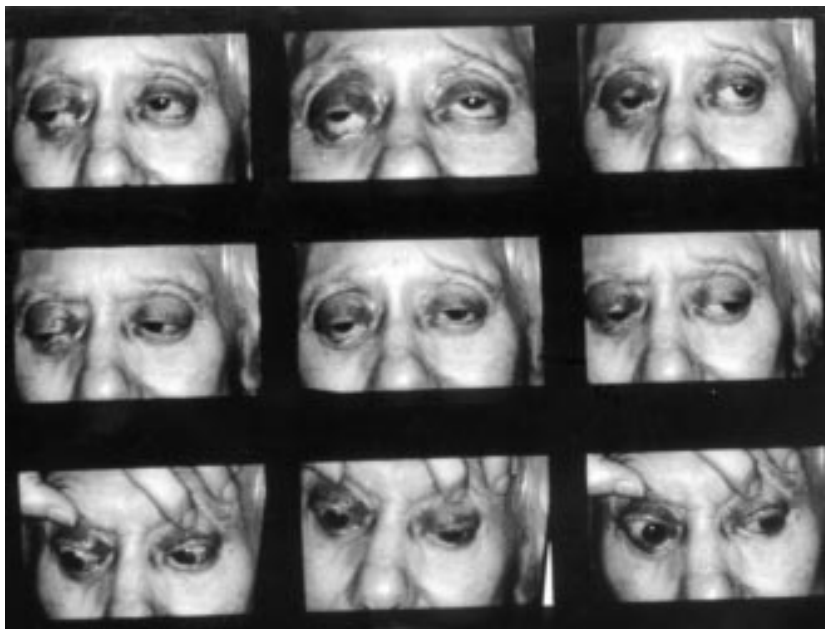

Figure 1 Restriction of ocular movement in nine positions of gaze.

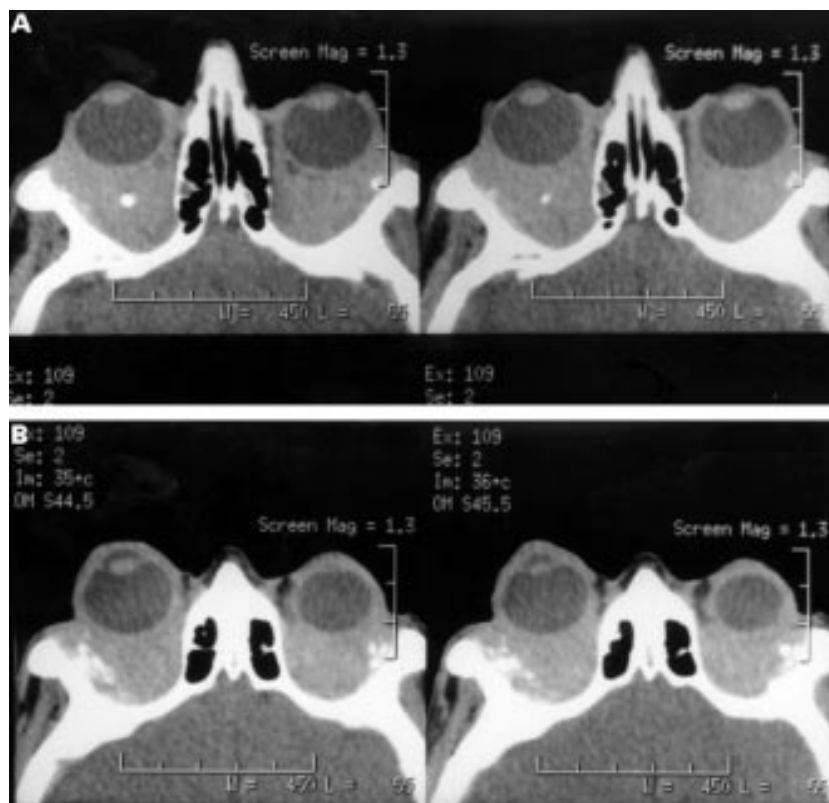


Figure 2 Computed tomography showing (A) calcification in the centre of the right orbit, and (B) bilateral calcification in the lacrimal fossae.

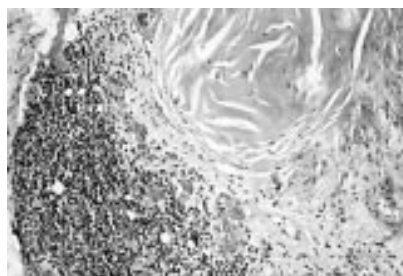


Figure 3 A haematoxylin and eosin stained biopsy sample showing a dense fibrous nodule typical of idiopathic sclerosing inflammation, which is associated with a mass of chronic inflammatory cells, predominantly lymphocytes.

orbit. It also demonstrates and confirms orbital calcification as part of the disease process, and we recommend that idiopathic sclerosing inflammation should be considered in the differential diagnosis of calcification within the orbit.

R ZAKIR  
R M MANNERS  
D ELLISON  
S BARKER

Southampton Eye Unit, Southampton General Hospital, Tremona Road, Southampton SO16 6YD

M CRICK  
Department Ophthalmology, Royal Victoria Hospital, Bournemouth, Hants, BH4 9DG

Correspondence to: Dr Zakir, Department of Ophthalmology, King's College Hospital, Denmark Hill, London SE5 9RS

Accepted for publication 26 April 2000

- 1 Rootman J, McCarthy M, White V, *et al.* Idiopathic sclerosing inflammation of the orbit—a distinct clinicopathologic entity. *Ophthalmology* 1994;101:570–83.
- 2 Aylward GW, Sullivan TJ, Garner A, *et al.* Orbital involvement in multifocal fibrosclerosis. *Br J Ophthalmol* 1995;79:246–9.
- 3 Albert DM, Jakobiec FA. Noninfectious orbital inflammations and vasculitis. In: *Principles and practice of ophthalmology*. Philadelphia: Saunders, 1994:1923–42.
- 4 Berger JR, Snodgrass S, Glaser J, *et al.* Multifocal fibrosclerosis with hypertrophic intracranial pachymeningitis. *Neurology* 1989;39:1345–9.
- 5 Levine MR, Kaye L, Mair S, *et al.* Multifocal fibrosclerosis. *Arch Ophthalmol* 1993;111:841–3.
- 6 Weissler MC, Miller E, Fortune MA. Sclerosing orbital pseudotumour: a unique clinicopathologic entity. *Ann Otol Rhinol Laryngol* 1989;98:496–501.
- 7 Richards AB, Skalka HB, Roberts FJ, *et al.* Pseudotumour of the orbit and retroperitoneal fibrosis. *Arch Ophthalmol* 1980;98:1617–20.
- 8 Comings DE, Skubi KB, Van Eyes J, *et al.* Familial multifocal fibrosclerosis. *Ann Intern Med* 1967;66:884–92.
- 9 Abramovitz JN, Kasdon DL, Sutula F, *et al.* Sclerosing orbital pseudotumour. *Neurosurgery* 1983;12:463–8.
- 10 Kennerdell JS. The management of sclerosing non-specific orbital inflammation. *Ophthalmic Surg* 1991;22(9):512–518.

#### Therapy of subhyaloidal haemorrhage by intravitreal application of rtPA and SF<sub>6</sub> gas

EDITOR.—Subhyaloidal haemorrhage in the premacular space may cause a sudden loss of central vision in eyes, where macular function was good before the incidence. It can be caused by different disorders such as vitreoretinal traction of different origins, trauma, Valsalva retinopathy, or occur spontaneously—for example, following partial detachment of the posterior hyaloid membrane. Different therapeutic approaches have been adopted for treatment of this situation. Spontaneous resorption of the haemorrhage can be awaited, which may be limited by the

frequently slow course of resolution. Nd:YAG laser photodisruption of the posterior hyaloid membrane has been described to achieve distribution of the haemorrhage in the vitreous, which resulted in accelerated clearing and visual improvement.<sup>1</sup> Pars plana vitrectomy can be performed for complete surgical separation of the posterior hyaloid membrane and removal of the whole haemorrhage.

We report on a case of acute premacular subhyaloidal haemorrhage, which was treated successfully by subsequent injection of recombinant tissue plasminogen activator (rtPA) and sulphur hexafluoride gas (SF<sub>6</sub>).

#### CASE REPORT

A 55 year old healthy woman (apart from medically controlled arterial hypertension) presented with a 1 day history of acute decrease of central vision to 20/200 in her right eye. Visual acuity in the left eye was 20/20, and there was no history of other or previous ocular disorders. Funduscopy revealed a subhyaloidal haemorrhage in the right eye which extended between the temporal vascular arcades (Fig 1). A small retinal area with intraretinal haemorrhages, retinal oedema, and epiretinal fibrovascular proliferation following occlusion of a small venous branch above the temporal superior arcade could be identified as the origin of the haemorrhage. Scatter laser photocoagulation was performed in the area of venous occlusion immediately. After 2 days, the surgical procedure was performed similar to the pneumatic displacement therapy of subretinal haemorrhages: after peribulbar anaesthesia, ocular pressure was applied twice for 10 minutes to reduce intraocular pressure. Then, 25 µg of rtPA (Actilyse, Boehringer-Ingelheim, Germany) were injected in the central vitreous cavity via pars plana. Following another two courses of ocular pressure, 0.3 ml of SF<sub>6</sub> were injected in the vitreous cavity after 30 minutes. For further reduction of intraocular pressure, a limbal paracentesis was carried out and aqueous humour was released.

On the first postoperative day, detachment of the superior half of the posterior hyaloid membrane could be observed with diffuse intravitreal blood, and visual acuity had increased to 20/25. After 2 weeks, the fundus image was almost clear and the patient experienced no further visual impairment. During a 4 month follow up, visual acuity returned to 20/20. No increase in intraocular pressure was noted during the whole follow up period. At 4 months, funduscopy showed regular findings except for the small area of venous occlusion (Fig 2), the crystalline lens showed no increase in opacification compared with the preoperative findings and to the other eye.

#### COMMENT

In many cases, subhyaloidal premacular haemorrhage demands therapeutic intervention. Although the finding theoretically can be observed and spontaneous resorption of the haemorrhage can be awaited, this procedure may not be accepted by the patient because of the possible slow course of resolution. Additionally, adequate treatment of the underlying cause of haemorrhage may be delayed with potential risks for further damage to ocular structures. To induce distribution of the premacular blood in the vitreous cavity and consequently accelerate clearing, Nd:YAG laser photodisruption of the posterior hyaloid membrane has been described.<sup>1</sup> However, this form of treatment may result in damage to the

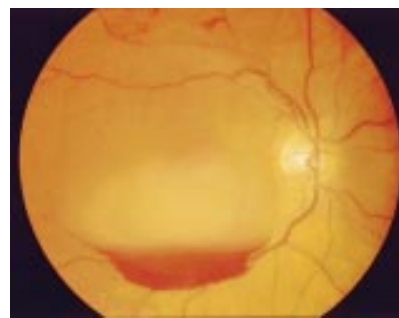


Figure 1 Premacular subhyaloidal haemorrhage in front of the posterior pole, area of venous branch occlusion with epiretinal fibrovascular proliferation above the temporal superior arcade; visual acuity 20/200.

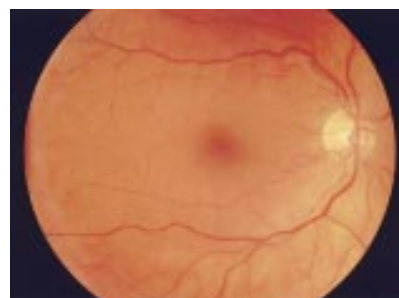

Figure 2 Four months' follow up: except for small area of venous occlusion regular fundus photograph; visual acuity 20/20.

underlying retinal tissue, especially in cases of thin subhyaloidal blood layers, of increased vitreous opacification, and of reduced patient compliance. Certainly, visual function can almost instantly be restored by pars plana vitrectomy with surgical separation of the posterior hyaloid membrane and evacuation of all blood. However, vitrectomy—even though a routine procedure—has numerous risks and side effects. The progression of lens nuclear sclerosis even after uneventful vitrectomy is a well known complication, which occurs in almost all cases. Intraoperative retinal breaks and postoperative proliferative vitreoretinopathy may result in retinal detachment and severe loss of visual function. The intravitreal injection of rtPA and SF<sub>6</sub> gas has recently been reported by different authors to induce pneumatic displacement of subretinal haemorrhage in cases of age related macular degeneration.<sup>2,3</sup> A significant reduction of central scotoma size with this comparably minimally invasive procedure has been pointed out, especially considering the minor side effects compared with the potential complications after vitrectomy with subretinal surgery.

To our knowledge this is the first report on the application of this surgical technique for the indication of central subhyaloidal haemorrhage. The intravitreal injection of fibrinolytic agents such as urokinase to induce resolution of vitreous haemorrhage of different origins has already been described in the previtrectomy era<sup>4</sup> and has been investigated experimentally.<sup>5</sup> More recently, induction of posterior vitreous separation by injection of rtPA has been shown both experimentally<sup>6</sup> and clinically.<sup>7</sup> Plasmin formed from vitreal plasminogen by rtPA breaks up extracellular matrix proteins of the hyaloid membrane, thus inducing separation. Additionally, these breaks may allow blood to pass the membrane even before further detachment, as we were able to see in our case, where diffuse distribution of blood in the vitreous cavity had already

occurred 30 minutes after injection of rtPA. Vitreous separation and further distribution of blood is then promoted by the injected gas bubble, which constantly rolls across the posterior pole if prone positioning is maintained by the patient in the early postoperative period.

The low risk profile of the procedure has been pointed out for its use in subretinal haemorrhage.<sup>2,3</sup> Retinal break formation after intravitreal gas injection is a well known complication. Therefore, before gas injection a thorough examination of the peripheral retina should be carried out to detect any pre-existing breaks or degenerations. The relatively small gas volume injected to achieve coverage of the posterior pole for this indication should further lower the risk of secondary break formation. Compared with vitrectomy, cataract formation or progression does not occur after intravitreal injection of fluid or gas as we know from retinal detachment surgery.

This case demonstrates the effective treatment of a dense central subhyaloidal haemorrhage by the injection of rtPA and SF<sub>6</sub>. The minimally invasive procedure resulted in restoration of useful visual function within a day after surgery and in recovery to full visual acuity within 2 weeks. No side effects could be attributed to the procedure compared with the potential risks of vitrectomy.

KLAUS SCHMITZ  
BERNHARD KREUTZER  
STEPHANIE HITZER

WOLFGANG BEHRENS-BAUMANN  
Eye Department, Otto-von-Guericke-University,  
Leipziger Strasse 44, D-39120 Magdeburg, Germany

Correspondence to: Dr Klaus Schmitz  
Accepted for publication 26 April 2000

- Gabel VP, Birngruber R, Gunther-Koszka H, et al. Nd:YAG laser photodisruption of hemorrhagic detachment of the internal limiting membrane. *Am J Ophthalmol* 1989;107:566-8.
- Hesse L, Schmidt J, Kroll P. Management of acute submacular hemorrhage using recombinant tissue plasminogen activator and gas. *Graefes Arch Clin Exp Ophthalmol* 1999;237:273-7.
- Meier P, Zeumer C, Jochmann C, et al. Management of submacular hemorrhage by tissue plasminogen activator and SF<sub>6</sub> gas injection. *Ophthalmologie* 1999;96:643-7.
- Williamson J, Forrester JV. Treatment of vitreous haemorrhage with urokinase. *Lancet* 1973;i:888.
- Forrester JV, Edgar W, Prentice CRM, et al. The effect of fibrinolytic inhibition in the resolution of experimental vitreous hemorrhage. *Am J Ophthalmol* 1977;84:810-14.
- Hesse L, Kroll P. Enzymatically induced posterior vitreous detachment in proliferative diabetic retinopathy. *Klin Monatsbl Augenheilkd* 1999;214:84-9.
- Verstraeten TC, Chapman C, Hartzer M, et al. Pharmacologic induction of posterior vitreous detachment in the rabbit. *Arch Ophthalmol* 1993;111:849-54.

### Sebaceous gland carcinoma of the eyelid and palpebral conjunctiva in a patient with Muir-Torre syndrome

EDITOR.—Sebaceous carcinoma (SC) of the eyelid and palpebral conjunctiva is rare.<sup>1</sup> We present a patient with this entity and Muir-Torre syndrome (MTS).<sup>2,3</sup> MTS is characterised by the concurrent or sequential documentation of at least a single sebaceous gland tumour (adenoma, epithelioma, or carcinoma), with or without keratoacanthomas, and a minimum of one internal malignancy. A recent review revealed that 163 cases fulfilling the diagnostic criteria for MTS have been reported since 1913, with 318 internal malignancies.<sup>4,6</sup> Colorectal (47%) and uro-

genital (21%) malignancies predominate, and nearly half the patients have two or more internal cancers. Our case is remarkable and was previously reported 7 years ago for presenting the highest number of malignancies described in this syndrome (eleven) and a prolonged survival of 26 years.<sup>7</sup>

#### CASE REPORT

A 62 year old man came to our clinic with a diagnosis of MTS.<sup>7</sup> In 1972 he had undergone a right hemicolectomy for undifferentiated Dukes' B adenocarcinoma. In 1978 segmental right ureterectomy was performed for transitional cell carcinoma (T1 No Mo). In 1983 a sebaceous epithelioma had been resected from the left thigh. Between 1986 and 1987 four urological operations were performed for low grade tumours: partial excision of the right renal pelvis, a segmental left ureterectomy and two transurethral resections at the right ureteric meatus. In 1987 a radical right nephroureterectomy, was performed for invasive carcinoma (T3a No Mo). In 1989 he was diagnosed with rectal carcinoma and an abdominoperineal resection was performed (Dukes' B adenocarcinoma plus adenomatous polyp); 16 months later, a colonoscopy showed metachronous carcinoma and a total colectomy was performed with end ileostomy for adenocarcinoma in a tubulovillous adenoma. In 1998 new skin lesions appeared on the face, and the patient was referred to our clinic because of spontaneous bleeding of the left upper lid. Physical examination disclosed a whitish, gelatinous, and vascularised papillomatous lesion on the tarsal conjunctiva located on the inner part of the left upper eyelid. It protruded as the eyelid was turned up, did not affect the free edge and was 0.5 cm long, with a base width of 0.2 cm (Fig 1). The patient also presented with more than 40 facial lesions (face and neck), each about 0.4 cm wide, and which had appeared in the previous year; they were rounded, well delimited, and adherent to deep tissues. One of them was located in the mid part of the upper left eyelid, and did not affect the free edge. Both eyelid tumours were resected by excisional biopsy. The genetic study showed mutations in the hMSH2 gene (mut exon 14 msh2; del at 2239; codon 747).

#### COMMENT

MTS is a rare autosomal dominant disorder characterised by the association of sebaceous gland tumours with internal malignancies. This syndrome is now considered a subtype of the more common hereditary non-polyposis colorectal cancer syndrome (HNPCC).<sup>8</sup> This last condition has been ascribed to mutations in four mismatched repair genes and similar mutations, mostly located in the hMSH2 gene, are now being described in some MTS

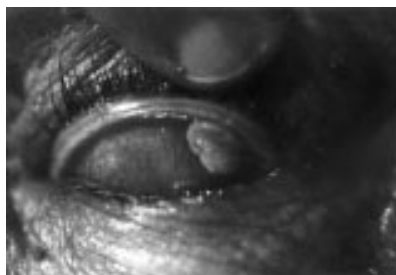

Figure 1 Polypoid mass located in the temporal aspect of the tarsal conjunctiva without free edge affection.

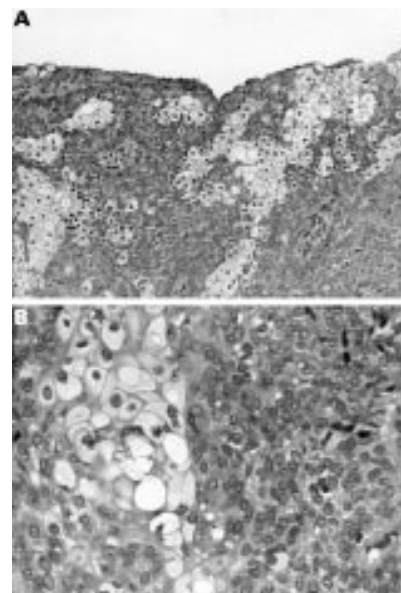


Figure 2 (A) The tumour was composed of lobules or sheets of cells separated by a fibrovascular stroma. Focally the lesion showed a pagetoid spread of neoplastic cells through the metaplastic conjunctiva (haematoxylin and eosin  $\times 100$ ). (B) Neoplastic cells showed variable sebaceous differentiation, with finely vacuolated or foamy cytoplasm. Nuclei were large, with prominent nucleoli. Scattered mitosis were present (haematoxylin and eosin  $\times 400$ ).

patients.<sup>9</sup> The genetic study showed mutations in the hMSH2 gene in our patient. This case reveals the indolent course of multiple neoplasm in patients with MTS and the prolonged survival that is possible after surgical treatment.

The skin lesions may be the first sign in 41% of these patients, and in some cases the cutaneous tumours may precede the appearance of the internal disease by as many as 25 years,<sup>4</sup> although more often they follow the diagnosis of at least the first visceral malignancy.<sup>10</sup> Our case presented a sebaceous epithelioma in the left thigh in 1983, 11 years after the first malignancy and did not present SC on the eyelid, face, and palpebral conjunctiva until 1998, 15 years later.

The mean age for the appearance of the skin tumours is 53 years (range 27-90 years) and the mean age for detection of the initial visceral neoplasm is 50 years; our case was diagnosed at ages 36 and 47 years old. The male:female ratio is 2:1.

Sebaceous carcinomas of the eyelid comprise 1-5.5% of all malignancies in this anatomic location and have been noted for their frequent metastatic potential. In contrast, extraocular sebaceous carcinoma is exceedingly rare, with fewer than 100 reported cases; metastatic spread is infrequent.<sup>10</sup> We have found only one case of differentiated sebaceous carcinoma from the palpebral conjunctiva, which was described as uncommon.<sup>1</sup> Therefore, this would be the second case reported at this location. There are 37 MTS patients with documented sebaceous gland carcinomas.

Histopathological diagnosis in our case was SC well differentiated in the lesion of the skin and SC moderately differentiated in the conjunctival lesion (Fig 2).

The treatment of sebaceous neoplasm is surgical excision. Complete removal of the tumour virtually eliminates the chance of recurrence in extraocular locations. Lesions of



the eyelid may have metastatic recurrence even with adequate initial excision.<sup>4</sup>

Patients with an MTS associated cutaneous lesion should have a complete evaluation for gastrointestinal or genitourinary cancers. Although the penetrance of this disease is variable, its autosomal dominant inheritance suggests that relatives should be screened for sebaceous gland tumours and internal malignancy and followed on a regular basis.<sup>4</sup>

ENRIQUE MENCÍA-GUTIÉRREZ  
ESPERANZA GUTIÉRREZ-DÍAZ

Department of Ophthalmology, 12 de Octubre Hospital  
and Complutense University, Madrid, Spain

ANGEL SANTOS-BRIZ  
SANTIAGO MADERO-GARCÍA

Department of Pathology

Correspondence to: Dr Enrique Mencia-Gutiérrez,  
Cedro, 23 E-28250 Torrelozanes, Madrid, Spain  
emencia@hdoc.insalud.es

Accepted for publication 26 April 2000

- Miyagawa M, Hayasaka S, Nagaoka S, *et al.* Sebaceous gland carcinoma of the eyelid presenting as a conjunctival papilloma. *Ophthalmologica* 1994;208:46–8.
- Muir EG, Bell AJY, Barlow KA. Multiple primary carcinomata of the colon, duodenum, and larynx associated with keratoacanthoma of the face. *Br J Surg* 1967;54:191–5.
- Torre D. Multiple sebaceous tumors. *Arch Dermatol* 1968;98:549–51.
- Cohen PR, Kohn SR, Kurzrock R. Association of sebaceous gland tumours and internal malignancy: the Muir-Torre syndrome. *Am J Med* 1991;90:606–13.
- Hartig C, Stielor W, Stadler R. Muir-Torre syndrome. Diagnostic criteria and review of the literature. *Hautarzt* 1995;46:107–13.
- Serleth HJ, Kiskken WA. A Muir-Torre syndrome family. *The American Surgeon* 1998;64:365–9.
- Cruz Vigo F, Pardo R, Saenz D, *et al.* Muir-Torre syndrome with multiple neoplasia. *Br J Surg* 1992;79:1161.
- Kruse R, Rütten A, Lanberti Ch. Muir-Torre phenotype has a frequency of DNA mismatch-repair-gene mutations similar to that in hereditary nonpolyposis colorectal cancer families defined by the Amsterdam criteria. *Am J Hum Genet* 1998;63:63–70.
- Suspiro A, Fidalgo P, Cravo M, *et al.* The Muir-Torre syndrome: a rare variant of hereditary nonpolyposis colorectal cancer associated with hMSH2 mutation. *Am J Gastroenterol* 1998;93:1572–4.
- Schwartz RA, Torre DP. The Muir-Torre syndrome: a 25-year retrospect. *J Am Acad Dermatol* 1995;33:90–104.

#### Ophthalmic features of primary oxalosis after combined liver/kidney transplantation

**EDITOR.**—Primary oxalosis is a rare autosomal recessive inborn error of glyoxylate metabolism in which two different enzyme defects lead to increased serum oxalate levels resulting in calcium oxalate crystal deposition in various tissues including the eyes, kidney, myocardium, brain, synovia, skin, and peripheral vessels.<sup>1,2</sup> This contributes to urolithiasis and end stage renal failure.

Ocular features of oxalosis have characteristically included the crystalline retinopathy (flecked retina), black geographic maculopathy, and optic atrophy.<sup>1–8</sup> We report two additional cases of primary oxalosis who underwent combined liver/renal transplantation at 1 year of age, but who initially did not manifest crystalline retinopathy or optic atrophy but developed poor vision despite successful transplantation.

#### CASE REPORTS

##### Case 1

An 18 month old female was initially evaluated before her simultaneous kidney/liver transplant. She was undergoing peritoneal

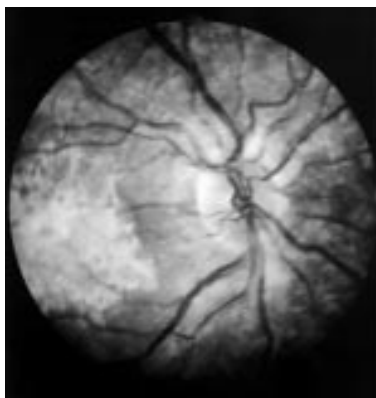


Figure 1 Case 1. Visual acuity right eye 5/140, left eye 5/140. Fundus: normal healthy disc with diffuse subretinal fibrosis. No black ring. No peripheral crystals.

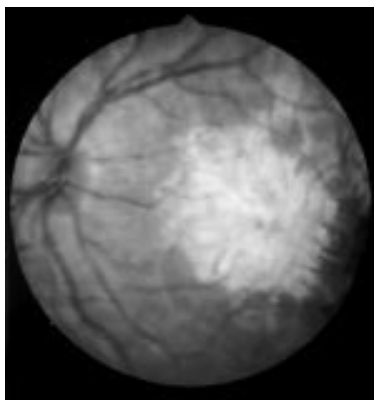


Figure 2 Case 1. Macula demonstrating "white geographic maculopathy" without crystals.

dialysis for her end stage renal disease secondary to biopsy confirmed primary oxalosis, diagnosed at age 6 months.

Visual acuity was CSM in each eye. She had no pupillary abnormalities. Extraocular motility was normal and she was orthophoric. Her anterior segment was entirely unremarkable without any evidence of conjunctival, corneal, or lenticular opacities (Figs 1–3).

Funduscopically she demonstrated striking pigmentary changes symmetrically throughout both eyes. Her optic nerves appeared healthy without optic atrophy. Her vessels were not attenuated. Her foveal area had increased pigment clumping but without exudate or discrete crystals. She had diffuse RPE changes throughout her periphery.

She underwent combined renal/liver transplantation at 18 months of age and subsequently had annual ophthalmological examinations. On her most recent evaluation at age 6, visual acuity was 5/140 in each eye with a cycloplegic refraction of  $-4.00$  sphere in each eye. Her anterior segments remained unremarkable without any lenticular opacities. Funduscopically she remained without any evidence of optic atrophy. She demonstrated profound retinal pigment epithelium (RPE) changes diffusely with extensive bilateral symmetrical submacular fibrosis. She did not have any peripheral crystalline retinopathy. There was no significant arteriolar attenuation.

##### Case 2

This young male was the product of a second pregnancy to a non-consanguineous 22 year old mother and 44 year old father. It was a full term uncomplicated pregnancy with a birth

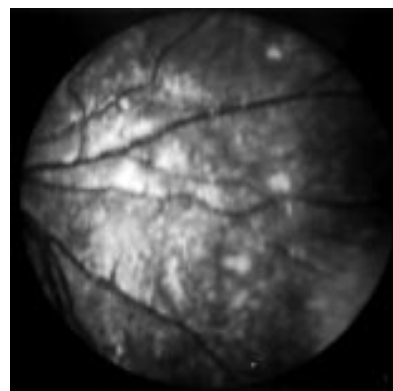


Figure 3 Case 1. Periphery: diffuse RPE changes without crystals or arteriolar attenuation

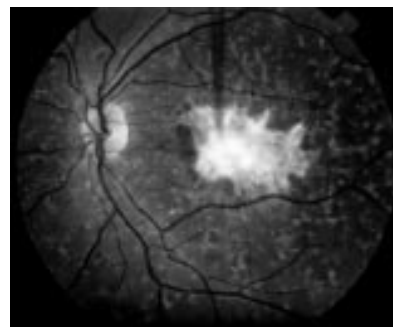


Figure 4 Case 2. Visual acuity left eye: 20/100. Demonstrates subretinal fibrosis with surrounding RPE pigment and diffuse peripheral RPE changes without any crystals. No optic atrophy.

weight of 9 lb. He did well until 4 months of age when he presented with presumed viral gastroenteritis which subsequently proved to be primary oxalosis (PH 1) after a confirmatory renal biopsy. He was maintained on peritoneal dialysis for end stage renal disease. He underwent a simultaneous kidney/liver transplant at 15 months of age. He has done well systemically for three subsequent years without any signs of rejection.

At 4½ years of age he was noted to have decreased vision in the left eye on a school screening. Neither the child nor parent had noted any ocular problems. He had not previously undergone patching, spectacle correction, or ocular surgery. At age 4½ years his visual acuity was 20/30 right eye and 20/100 left eye at distance. Near vision was 20/20 and 20/80 respectively. He had no altered head position. Ocular movements and motility were normal and he was orthophoric. He had no nystagmus. Pupillary testing was normal without evidence of a pupillary defect. Anterior segment evaluation was unremarkable, specifically without any conjunctival, corneal, or lenticular opacities. Cycloplegic refraction:  $+1.00$  sphere right eye and  $+1.50$  sphere left eye.

Funduscopically he had no evidence of optic atrophy. He had evidence of bilateral symmetrical subretinal fibrous changes within both macula with surrounding RPE pigmentation (Fig 4). He had marked pigmentary changes with pigment clumping in the periphery decreasing with increased distance from the macula. There were no crystals evident in either eye. There was no significant arteriolar attenuation. After intensive patching of his right eye, follow up visual acuity at age 6 was 20/20 right eye and 20/100 left eye.

## COMMENT

Two children underwent combined liver/kidney transplantation at 15 and 18 months of age for primary oxalosis (PH 1). Profound alteration of the retinal pigment epithelium was evident before transplantation. There was no progression of retinopathy after transplantation. The most recent visual acuity was 5/140 in each eye of the first patient and 20/20 and 20/100 in the second patient. No strabismus was noted. The prominent feature in both children was the bilateral symmetrical submacular RPE changes with extensive fibrosis ("white geographic maculopathy"). Neither child demonstrated any peripheral crystalline retinopathy or optic atrophy.

Primary hyperoxaluria type 1 (PH 1) is caused by a deficiency of the hepatic peroxisomal enzyme alanine: glyoxylate aminotransferase (AGT).<sup>9</sup> This enzyme is encoded by the AGXT gene on chromosome 2q37.3.<sup>10</sup> In the absence of AGT glyoxylate is not adequately converted to less toxic metabolites and instead is metabolised to oxalate and glycolate. AGT has pyridoxal phosphate as its cofactor. In the majority of patients the disease results from the lack of a functional gene product but in one third of the patients there is a misrouting of the enzyme to the mitochondria instead of the peroxisomes.

Primary hyperoxaluria type 2 (PH 2) is due to the deficiency of the enzyme D-glycerate dehydrogenase/glyoxylate reductase. The biochemical criteria for diagnosis include hyperoxaluria and L-glyceric aciduria.

Oxalosis has classically been included in the differential diagnosis of crystalline retinopathy. This differential includes Bietti's crystalline dystrophy and cystinosis, though both of these also manifest corneal crystals. Additionally, talc and canthaxanthine retinopathy should be included as well as methoxyflurane toxicity and tamoxifen retinopathy. Intraretinal crystals have also been described in advanced stages of hyperornithaemia, gyrate atrophy, and Sjogren-Larsson syndrome.

These children represent the product of treatment of the underlying metabolic problems by liver/kidney transplantation for the most severe form of infantile primary hyperoxalosis. Despite early intervention, these children still developed white geographic maculopathy and poor vision. Previously, 15 ocular cases have been reported in the English literature citing the typical funduscopic picture of crystalline retinopathy, black geographic ringlet maculopathy, and optic atrophy.<sup>3-8</sup> Those previous reports indicated the maculopathy caused only mild, if any, visual impairment, whereas the worst vision was in those patients with optic atrophy.<sup>6</sup> Unlike the previous reports, in our children their maculopathy was associated with poor vision in all but one eye, despite combined liver/kidney transplantation at an early age. It may be that our patients were younger and with a more severe disease. We postulate that the visual decrement is a result of subfoveal fibrosis. The one eye with good vision shows less subretinal fibrosis than the fellow eye with poor vision.

Successful hepatorenal transplantation has been followed by progressive and ultimately complete mobilisation of the oxalate deposits with resolution of the manifestations of systemic oxalosis including cardiomyopathy, cardiac dysrhythmias, and osteodystrophy. It may be that if there was not significant foveal involvement or optic nerve damage before transplantation these children could have an excellent visual outcome. Given that these two

patients underwent liver/renal transplantation by age 18 months old and yet have poor vision, it is imperative that treatment be initiated at the earliest possible stage.

The patients described above represent early involvement of retinal oxalosis with infantile PH 1, yet neither child demonstrated any crystals. It is important for the ophthalmologist to be cognizant of the "non-crystalline" retinopathy which is the result of calcium oxalate deposition and subsequent RPE reaction.

As more children will be diagnosed appropriately with newer molecular testing and with the increased success of combined liver and kidney transplantation, the ophthalmologist will be more involved with these patients and must be aware of the wide spectrum of ocular manifestations of oxalosis.

D M ALCORN

Stanford University School of Medicine, Department of Ophthalmology and Pediatrics, Stanford, CA 94305, USA

D R FREDRICK

University of California-San Francisco, Department of Ophthalmology, San Francisco, CA 94120, USA

Correspondence to: Dr Deborah Alcorn, Stanford University School of Medicine, Department of Ophthalmology, 300 Pasteur Drive, Suite No A157, Stanford, CA 94305-5308, USA

dalcorn@leland.Stanford.edu

Accepted for publication 27 April 2000

- Danpure CJ, Purdue PE. Primary hyperoxaluria. In: Scriver CR, Beaudet AL, Sly WS, Valle D, eds. *The metabolic basis of inherited disease*. 7th ed. New York: McGraw-Hill, 1994: Ch 75:2385-424.
- Watts RW. The clinical spectrum of the primary hyperoxalurias and their treatment. *J Nephrol* 1998;11(Suppl 1):4-7.
- Fielder AR, Garner A, Chambers TL. Ophthalmic manifestations of primary oxalosis. *Br J Ophthalmol* 1980;64:782-8.
- Mansell MA. Primary hyperoxaluria type 2. *Nephrol Dial Transplant* 1995;10(Suppl 8):58-60.
- Meredith TA, Wright JD, Gammon A, et al. Primary hereditary oxalosis retinopathy. *Arch Ophthalmol* 1983;101:78-80.
- Small KW, Letson R, Scheinman. Ocular findings in primary hyperoxaluria. *Arch Ophthalmol* 1990;108:89-93.
- Traboulsi EI, El-Baba F, Barakat Ay, et al. The retinopathy of primary hyperoxaluria. *Retina* 1985;5:151-3.
- Zak TA, Buncic R. Primary hereditary oxalosis retinopathy. *Arch Ophthalmol* 1983;101:78-80.
- Von Schnakenburg C, Rumsby G. Primary hyperoxaluria type 1: a cluster of new mutations in exon 7 of the AGXT gene. *J Med Genet* 1997;34:489-92.
- Purdue PE, Lumb MJ, Fox M, et al. Characterization and chromosomal mapping of a genomic clone encoding human alanine: glyoxylate aminotransferase. *Genomics* 1991;10:34-42.

### Retinal telangiectasis and angioid streaks

EDITOR,—As the name implies, angioid streaks may resemble blood vessels.<sup>1</sup> Initially described by Doyne in 1889 as a case presentation to the Ophthalmological Society of the United Kingdom, there was consensus that these streaks were vascular in nature, and thus aptly named. It remained for Kofler in 1916 to correctly delineate the level of the streaks at Bruch's membrane.<sup>2</sup> Choroidal neovascularisation (CNV) has been reported as a complication of angioid streaks to occur in 70% to 86% of cases.<sup>3</sup> Retinal telangiectasis, however, has never been described in association with angioid streaks.

## CASE REPORT

A 66 year old white woman presented with gradual visual loss in her right eye for 2 months. Her best corrected visual acuity was right eye 20/40 and left eye 20/20. Slit lamp biomicroscopy of the anterior segment was normal. Fundus examination showed macular oedema in the right eye and prominent peripapillary atrophy with irregularly radiating streaks in the left eye (Fig 1). Fluorescein angiography disclosed bilateral peripapillary angioid streaks and juxtafoveolar retinal telangiectasis in the right eye. There was no evidence of CNV (Fig 2).

## COMMENT

The development of CNV is a common finding in angioid streaks. Histopathological studies demonstrated linear breaks in Bruch's membrane in addition to extensive calcification. These cracks in Bruch's membrane may be bridged by a thin hypopigmented layer of retinal pigment epithelium, thus predisposing to the ingrowth of fibrovascular tissue from the choroid into the subpigment epithelial space in at least three out of four patients, usually occurring during the third to fifth decade of life.<sup>2,3</sup>

Despite the age of 66 years, the patient presented here did not show any evidence of CNV or related scarring. However, mild peripapillary streaks were present in both eyes. It has been reported previously that streaks with this appearance are not associated with fundus abnormalities or macular lesions typically observed in patients with pseudoxanthoma elasticum, such as reticular pigmentary changes or peau d'orange appearance.<sup>1</sup> Regarding the different clinical appearance and the benign course, these mild peripapillary streaks were considered a separate entity and have also been termed senile atrophic lines or pseudostreaks.<sup>4</sup> Characteristically, in senile streaks, peripapillary helicoidal choroidal atrophy is often much more prominent than the streaks themselves (Figs 1 and 2).

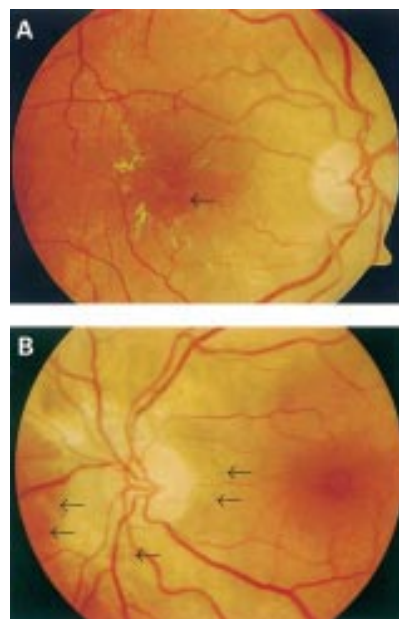


Figure 1 Fundus photographic view of the right eye (A) shows macular oedema and biomicroscopically visible telangiectasis (arrow). In the left eye, prominent peripapillary atrophy and mild irregularly radiating streaks (arrows) are present (B).

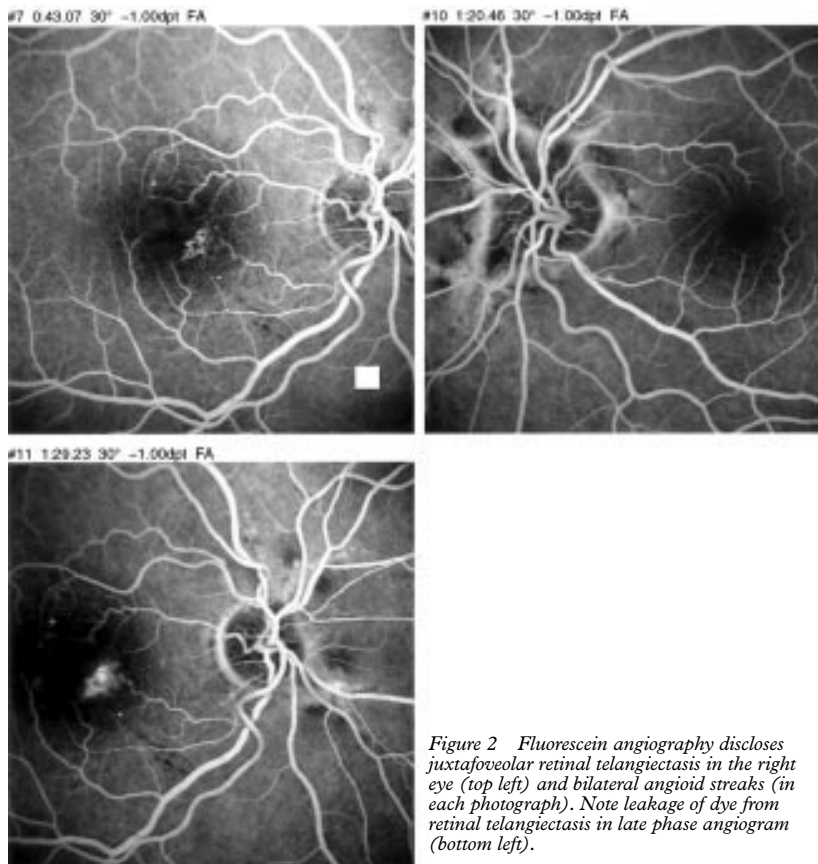


Figure 2 Fluorescein angiography discloses juxtafoveal retinal telangiectasis in the right eye (top left) and bilateral angioid streaks (in each photograph). Note leakage of dye from retinal telangiectasis in late phase angiogram (bottom left).

The macular oedema of this 66 year old woman, however, resulted from leakage of juxtafoveal retinal telangiectasis. A classification of idiopathic juxtafoveal retinal telangiectasis was proposed by Gass and coworkers in 1982, and updated in 1993.<sup>5</sup> According to the biomicroscopic and fluorescein angiographic findings, three distinct groups of patients at risk were categorised—unilateral, non-familial, biomicroscopically visible telangiectasis with intraretinal exudation; bilateral, occult telangiectasis with minimal exudation and superficial retinal crystalline deposits; bilateral, biomicroscopically visible telangiectasis with minimal exudation and capillary occlusion, associated with systemic disease.<sup>5</sup>

The aetiology of angioid streaks as well as of retinal telangiectasis remains unknown. Although hundreds of eyes with angioid streaks have been observed clinically and some of them have been studied histopathologically, the reason for calcification and for the development of cracks of Bruch's membrane remained unclear. Abnormal calcification of elastic tissue, a component of Bruch's membrane, is seen in other parts of the body in pseudoxanthoma elasticum and in Paget's disease. These two entities are the most common systemic association with angioid streaks, occurring in up to 50%. Sickle cell haemoglobinopathy and haemolytic anaemia are much less frequent.<sup>2</sup>

In Gass's studies, only bilateral, biomicroscopically visible telangiectasis was associated with systemic disease. These eyes were characterised not by exudation, but by capillary obstruction and occlusion "similar to that seen in some patients with sickle cell retinopathy". All of these patients had systemic disease which was probably related to telangiectasis such as abnormalities of the

cardiovascular or central nervous system.<sup>5</sup> As sickle cell haemoglobinopathy is the only known systemic disease associated with both retinal telangiectasis and angioid streaks, bilateral telangiectasis and angioid streaks may theoretically present together.

In our case, unilateral juxtafoveal telangiectasis caused macular oedema. There was no evidence of systemic disease or vascular occlusion. Therefore, regarding the various histopathological features and systemic diseases associated with angioid streaks and retinal telangiectasis, we assume that both clinical entities occurred in a coincidental way. It is important to note, however, that retinal telangiectasis can occur in an eye with angioid streaks, and it should not be confused with CNV. In elderly patients beyond the sixth decade of life, there is a senile form of angioid streaks which is unlikely to cause CNV, but may be associated with retinal telangiectasis.

ARND GANDORFER  
MICHAEL ULBIG  
MARTIN BECHMANN  
STEPHAN FRÖHLICH  
ANSELM KAMPIK

Department of Ophthalmology, Ludwig Maximilians University, Munich, Germany

Correspondence to: Dr A Gandorfer, Ludwig Maximilians Universität, Mathildenstrasse 8, 80336 München, Germany

arn.d.gandorfer@ak-i.med.uni-muenchen.de  
Accepted for publication 3 May 2000

- Shields JA, Federman JL, Tomer TL, *et al*. Angioid streaks. I. Ophthalmoscopic variations and diagnostic problems. *Br J Ophthalmol* 1975;59:257-66.
- Clarkson JG, Altman RD. Angioid streaks. *Surv Ophthalmol* 1982;26:235-46.
- Lim JJ, Bressler NM, Marsh MJ, *et al*. Laser treatment of choroidal neovascularization in patients with angioid streaks. *Am J Ophthalmol* 1993;116:414-23.

- Quaranta M, Cohen SY, Krott R, *et al*. Indocyanine green videoangiography of angioid streaks. *Am J Ophthalmol* 1995;119:136-42.
- Gass JD, Blodi BA. Idiopathic juxtafoveal retinal telangiectasis. Update of classification and follow-up study. *Ophthalmology* 1993;100:1536-46.

#### Sclerosing lipid granuloma of the medial canthus 30 years after dacryocystitis

EDITOR.—Lipid granuloma of the lid and anterior orbit can occur in various conditions.<sup>1-6</sup> We present a 33 year old woman with an indurated inflammatory swelling at the medial canthus 30 years after a dacryocystitis on the same side. Histologically the lesion was identical to those that have been described as a reaction to paraffin from displaced ointments.<sup>7</sup> The lipid in our case, however, was analysed as a mixture of triglycerides corresponding to a substance that was previously used as a contrast material for dacryocystography. To our knowledge, this is the longest time span reported to date between the application of a lipid based material and the development of a lipogranulomatous reaction.

#### CASE REPORT

A 33 year old white woman presented with a painless red swelling of the medial left lower lid (Fig 1A) that had been present for several weeks. There was an obstruction of both lower and upper canaliculus and also mild oedema of the upper lid. On palpation, the swelling presented as a remarkably firm subcutaneous mass extending deep into the medial canthal area. Otherwise, all ocular findings were normal. The patient's previous ocular history was unremarkable apart from a left sided refractory dacryocystitis at age 3 that had been investigated and treated at another university eye department. The parents had documented the lesion photographically but unfortunately the chart was no longer available. Ultrasonography of the suspicious area revealed a dense homogeneous infiltration within the subcutaneous tissue while on computed tomograph scan no definite tumour was seen. With the presumed diagnosis of dacryocystitis, topical and systemic antibiotics were given but no improvement was noted. A full clinical examination including extensive laboratory investigations did not reveal any evidence of an underlying systemic disease or immunoregulatory abnormalities. Eventually a diagnostic biopsy revealing firm yellowish tissue (Fig 1B) was performed mainly to rule out lymphoma or a metastasis.

Histopathology showed muscle and fibrous tissue with numerous lipid vacuoles of different sizes (Fig 1C), surrounded by multinucleate giant cells and a dense inflammatory cell infiltrate. These were features consistent with the so called paraffin granuloma that has been described after endonasal sinus surgery and after injection of ointment into the lacrimal drainage system.<sup>7</sup> It was decided to surgically remove as much of the tumour as possible which proved difficult because it extended around the medial canthus up into the upper lid and back into the orbit temporally. However, wound healing was without any complications, and the cosmetic result was excellent. On repeat probing, the canaliculus was now patent, and no recurrence was seen up to 2 years after the surgery.

In contrast with our histopathological expectations, a biochemical analysis of the excised tissue using infrared, mass, and nuclear magnetic resonance spectroscopy

showed the extracted lipid to be an accumulation of triglyceride esters which mostly consisted of oleate and to a lesser degree of palmitate and stearate (2.5 mg versus 0.16 mg in non-affected control tissue).

#### COMMENT

This patient presented with a lipid-rich lesion similar to the so called paraffin granuloma which represents an inflammatory reaction to exogenous lipid.<sup>7</sup> Usually, exogenous lipid gets access into the tissue in the form of ointments used in or in close vicinity to the eye.<sup>7,8</sup> In contrast with paraffin, however, the triglyceride esters that were analysed in our patient are not usually present in ophthalmic ointments. Triglycerides are rather a constituent of naturally occurring lipids and can be expected—for example, in fat necrosis after trauma. Our patient did not exhibit any features of a pre-existing lipomatous lesion such as, for example, a lipodermoid; moreover, there was no history of trauma or mechanical irritation. Thus, the most likely explanation for the pres-

ence of a lipogranuloma remains a “complication” from the treatment of her dacryocystitis 30 years ago. Various lipid based substances have been used for rinsing of, and instillation into, the canaliculus or lacrimal sac. These ointments, however, are usually also based on paraffin or Vaseline.<sup>5-9</sup> Other lipid based materials have been employed as contrast material for viewing the lacrimal passage. One of the substances that has been commonly used for contrast dacryocystography is Lipiodol<sup>10</sup>, an iodised poppy seed oil which is a characteristic mixture of glyceric esters of various fatty acids including mainly oleic, linoleic, linolenic, palmitic, and stearic acid (information from Byk Gulden, Konstanz). Thus, the lipid composition of Lipiodol corresponds remarkably well to the mixture that was analysed in our specimen. The iodine present in the original substance can be expected to have been removed and transferred to the thyroid, and, with endogenous fat and ointments exhibiting somewhat different components, there is convincing evidence that Lipiodol can indeed be regarded as the initiating agent.

Similar problems after instillation of other lipid based substances into the lacrimal drainage system<sup>5-9</sup> and one case of a granulomatous inflammation initiated by the application of a lipid based contrast medium to the orbit<sup>3</sup> have been reported but the time between the original “insult” and the development of an inflammatory reaction was always much shorter. This suggests that, in our case, a minor injury to the canaliculus or lacrimal sac might have occurred, allowing only a very small amount of lipid based material to reach the surrounding tissues and cause a self propagating inflammatory process. As triglycerides are much more similar to human body fat than paraffin, one could speculate that this might further help to explain the unusually long time lapse between the primary application and the clinically relevant granulomatous reaction seen in our patient.

We are very grateful to Dr S Moss, Novartis, Switzerland, for performing the biochemical analysis.

KARIN U LOEFFLER  
FRANK M JAKOBS  
PETER ROGGENKAEMPER  
Department of Ophthalmology, University of Bonn,  
Germany

Correspondence to: Dr Karin U Loeffler, Department of Ophthalmology, University of Bonn, Sigmund-Freud-Strasse 25, D-53105, Bonn, Germany  
karinloeffler@uni-bonn.de  
Accepted for publication 8 May 2000

- Boynnton JR, Searl SS, Heimer JL, *et al*. Eyelid oleogranulomas caused by petroleum jelly injection. *Arch Ophthalmol* 1988;106:550-1.
- Cornblath WT, Dotan SA, Trobe JD, *et al*. Varied clinical spectrum of necrobiotic xanthogranuloma. *Ophthalmology* 1992;99:103-7.
- Eifrig DE. Lipid granuloma of the orbit. *Arch Ophthalmol* 1968;79:163-5.
- Hanssens M, Poelman J. Sclerosing lipogranuloma of the orbit. *Bull Soc Belge Ophthalmol* 1988; 227:35-46.
- Crehange JR, Arouette J, Mouly R, *et al*. Vaseline palpebraux apres injections medicamenteuses dans les voies lacrymales. *Bull Soc Ophthalmol Fr* 1970;70:1202-6.
- Newcomer VD, Graham JH, Schaffert RR, *et al*. Sclerosing lipogranuloma resulting from exogenous lipids. *Arch Dermatol* 1956;73:361-72.
- Witschel H, Geiger K. Paraffin induced sclerosing lipogranuloma of eyelids and anterior orbit following andonasal sinus surgery. *Br J Ophthalmol* 1994;78:61-5.
- Moolchandani J, Kazim M, Farber M, *et al*. Eyelid lipid granuloma following topical ointment application. *Ophthalmic Plast Reconstr Surg* 1990;6:133-5.

- Struck HG, Tost F. Die “Tränenwegsplombe”—Indikation und Risiken. *Aktuelle Augenheilkd* 1992;17:153-6.
- Kassel EE, Schatz CJ. Lacrimal apparatus. In: Som PM, Curtis HA, eds. *Head and neck imaging*. 3rd ed. St Louis: Mosby, 1995:1129-83.

#### Treatment of subhyaloid haemorrhage with intravitreal tissue plasminogen activator and C<sub>2</sub>F<sub>6</sub> gas injection

EDITOR,— Subhyaloid haemorrhage can be caused by a variety of retinal disorders, such as age related macular degeneration, proliferative diabetic retinopathy, Valsalva retinopathy, macroaneurysm, and trauma. Nd:YAG laser membranotomy has been used for the rapid clearing of premacular haemorrhage, but complications such as retinal or choroidal haemorrhage and retinal hole formation were reported with the use of Nd:YAG laser. If the patient has cataract or media opacity, effective and precise laser delivery would be difficult.<sup>1</sup>

Hassan *et al* reported that intravitreal tissue plasminogen activator (tPA) and C<sub>2</sub>F<sub>6</sub> injection effectively displaced the subretinal haemorrhage.<sup>2</sup> Furthermore, it has been recently reported that intravitreal tPA and SF<sub>6</sub> promote the clearing of premacular subhyaloid haemorrhages in shaken and battered baby syndrome.<sup>3</sup>

We treated a patient with subhyaloid haemorrhage by intravitreal tPA and C<sub>2</sub>F<sub>6</sub> injection without any complications. YAG laser membranotomy failed because the patient's pterygium and cataract hindered proper contact lens application and caused laser beam scattering.

#### CASE REPORT

A 75 year old female patient visited our clinic because of sudden visual loss in her right eye 45 days earlier. Visual acuity was counting fingers at 20 cm in the right eye and 20/100 in the left. There were pterygia in both eyes, and her lenses showed cortical opacity. On fundus examination, a round dark red haemorrhage with a convex surface covering the right macula was noted (Fig 1). There was a fluid level in the upper part of haemorrhage and its preretinal location was confirmed by fluorescein angiography. There was neither posterior vitreous detachment nor a hole in the posterior hyaloid. Indocyanine angiography showed an arterial macroaneurysm in the superotemporal vascular arcade in the right eye.

Since the subhyaloid haemorrhage was thick, we first tried Nd:YAG laser membranotomy. However, this failed because her pterygium hindered proper contact lens application, and YAG laser was not able to be precisely focused on the anterior surface of the

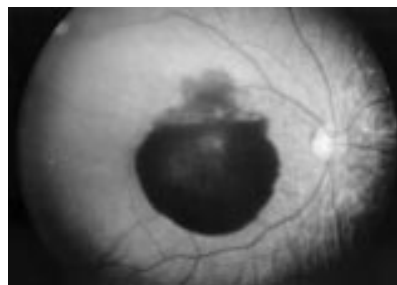


Figure 1 Fundus photograph of the right eye shows a dark subhyaloid haemorrhage centred at the fovea. The fluid level in the upper part of the haemorrhage suggests subhyaloid space location. Lens opacity makes the fundus hazily visualised.

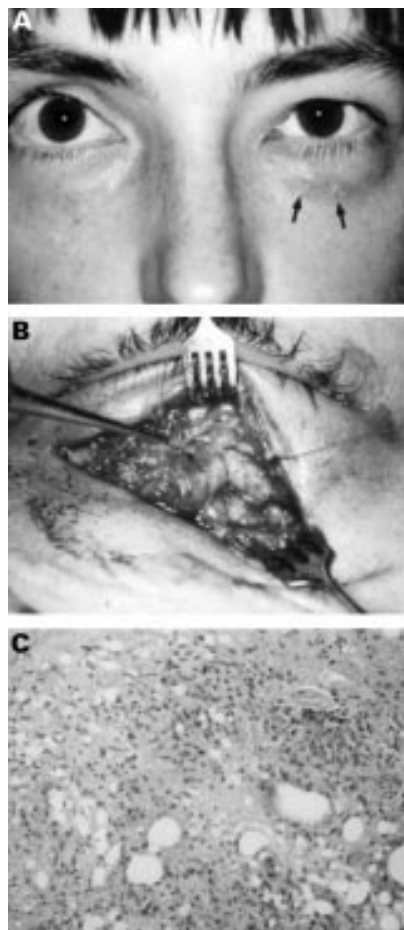


Figure 1 (A) Clinical appearance at first presentation, showing a red subcutaneous swelling (indicated by arrows) in the left medial canthus extending into the lower lid. The left upper eyelid also appears somewhat oedematous. (B) Intraoperative appearance of the lesion, revealing yellowish lipid-like tissue of firm consistency. Note that the tumour is infiltrating the surrounding tissues without evidence of a capsule or pseudocapsule. (C) Histology shows connective tissue with numerous lipid vacuoles of different sizes that are mostly surrounded by multinucleate giant cells. Note also the dense chronic inflammatory cell infiltrate. No genuine orbital fat is seen in this section. (Paraffin section, haematoxylin and eosin, x170).

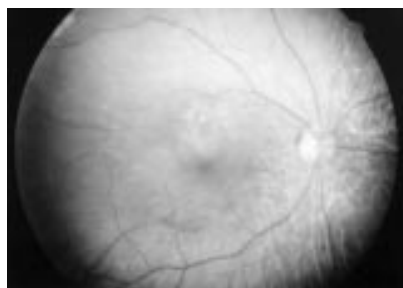


Figure 2 Fundus photograph of right eye 2 months after treatment. The subhyaloid haemorrhage has completely cleared.

subhyaloid membrane owing to the poorly applied contact lens and cataract. Therefore, we decided to perform intravitreal tPA and  $C_3F_8$  injection under topical anaesthesia. Twenty minutes after injecting intravitreal 0.1 ml of 25  $\mu$ g/0.1 ml tPA (total dose of 25  $\mu$ g), 0.5 ml of 100%  $C_3F_8$  was injected into the vitreous cavity. A paracentesis was done to decrease the intraocular pressure. The patient was told to maintain the face down position for 2 weeks. Three days after the injection, the subhyaloid haemorrhage was displaced by the gas bubble out of the macular region. The haemorrhage slowly decreased in size over 2 weeks, and then markedly decreased. After 2 months, the subhyaloid haemorrhage had completely cleared (Fig 2). Her vision in the right eye increased to 20/70 on her last visit.

#### COMMENT

Although the subhyaloid haemorrhage was somewhat old and very thick, it was rapidly displaced out of the macular region within 3 days. We suggest that tPA worked to lyse the blood clot. The vision of 20/70 may be attributed to cataract and retinal damage caused by the subhyaloid haemorrhage.

Tissue plasminogen activator and  $C_3F_8$  injection seems to be an alternative way to clear the subhyaloid haemorrhage especially when the patient has media opacity or when there is a problem with contact lens application for laser.<sup>4 5</sup>

HYOUNG J KOH  
SOON H KIM  
SUNG C LEE  
OH W KWON

Institute of Vision Research,  
Department of Ophthalmology,  
Yonsei University College of Medicine,  
Seoul, Korea

Correspondence to: Hyoung J Koh MD, Institute of Vision Research, Department of Ophthalmology, Yonsei University College of Medicine, 134 Shinchon-dong, Sodaemun-gu, Seoul, Korea, 120-752

hjkoh@yumc.yonsei.ac.kr

Accepted for publication 8 May 2000

- Gabel VP, Bringruber R, Gunther-Koszuka H, et al. Nd:YAG laser photodisruption of hemorrhagic detachment of the internal limiting membrane. *Am J Ophthalmol* 1989;107:33-7.
- Hassan AS, Johnson MW, Schneiderman TE, et al. Management of submacular hemorrhage with intravitreal tissue plasminogen activator injection and pneumatic displacement. *Ophthalmology* 1999;106:1900-6.
- Conway MD, Peyman GA, Recasens M. Intravitreal tPA and SF<sub>6</sub> promote clearing of premacular subhyaloid hemorrhages in shaken and battered baby syndrome. *Ophthalmic Surg Lasers* 1999;30:435-41.
- Adel B, Israel A, Friedman Z. Dense subhyaloid hemorrhage or subinternal limiting membrane hemorrhage in the macula treated by Nd:YAG laser. *Arch Ophthalmol* 1998;116:1542-3.

- Iijima H, Satoh S, Tsukahara S. Nd:YAG laser photodisruption for preretinal hemorrhage due to retinal macroaneurysm. *Retina* 1998;18:430-4.

#### Blunt trauma in Best's vitelliform macular dystrophy

EDITOR,—Recently, the association of Best's vitelliform macular dystrophy (BVMD) with mutations in chromosome 11 has been reported, and candidate genes that may be affected by these mutations have been identified.<sup>1 2</sup> However, the role of these genes in retinal and retinal pigment epithelium (RPE) function is not clear. In addition, factors that determine the progression of the vitelliform foveal lesion leading to impairment of visual acuity in patients with BVMD are not understood. We present a case in which blunt trauma was associated with deterioration of visual acuity and macular scar formation in a patient with BVMD.

#### CASE REPORT

A 14 year old male presented to our clinic after being hit in his right eye by a fist 40 days earlier. He complained of reduced visual acuity

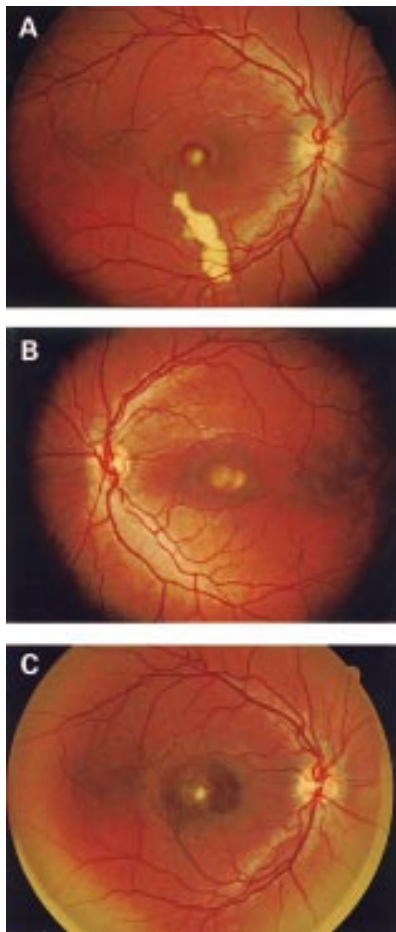


Figure 1 Colour fundus photographs of a patient with Best's vitelliform macular dystrophy. On initial examination (40 days after blunt trauma), the right eye had a foveal scar with remnants of perifoveal haemorrhage, and subretinal yellowish material (A). The left eye showed a typical vitelliform lesion (B). One month later, the remnants of haemorrhage and the yellowish subretinal material had been absorbed, and mild RPE changes were noted in this area in the right eye. The other findings remained unchanged (C).

in this eye since the trauma. He had a history of good and equal visual acuity in both eyes until the trauma occurred, and ocular and systemic history were unremarkable. He was the fourth son among eight children (two males and six females), and the patient was unaware of any significant ocular diseases in his family. Other family members were not available for our examination.

Best corrected visual acuity was 6/24 and 6/7.5 in the right and left eye respectively. Anterior segments and intraocular pressures were normal. Funduscopy of the right eye revealed a foveal scar with remnants of subretinal haemorrhage around the fovea. Yellowish subretinal material was seen extending centrally from the lower temporal arcade. In this area, two parallel pigmented lines that may represent choroidal ruptures were noted (Fig 1A). The left eye showed a vitelliform foveal lesion (Fig 1B). The optic disc and peripheral retina were normal in both eyes.

ISCEV standard electro-oculography (EOG) and electroretinography (ERG) were performed. The EOG showed severely reduced light peak to dark trough ratios of 120% and 100% in the right and left eye, respectively (lower limit of normal 180%). The full field photopic cone ERG response, as well as the scotopic rod and mixed cone-rod responses, were normal. The patient could not discriminate the colours on the Farnsworth D-15 test in his right eye, while the left eye showed a deuteranopic defect.

On the basis of these findings, we diagnosed blunt trauma that resulted in subretinal haemorrhage and foveal scar formation in a patient with BVMD. On follow up examination 1 month later, the visual acuity remained unchanged. However, the haemorrhage surrounding the foveal scar as well as the yellowish subretinal material in the posterior pole of the right eye had absorbed, and mild RPE changes were noted (Fig 1C). Fluorescein angiography at this time showed staining of the foveal scar in the right eye with hypofluorescence in the area corresponding to the absorbed subretinal material (Fig 2).

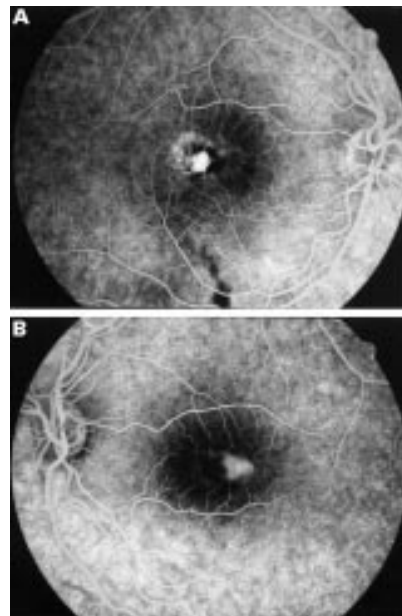


Figure 2 Fluorescein angiography in BVMD approximately 2½ months after trauma to the right eye, taken on the same day as Figure 1C. Late staining of the foveal scar with hypofluorescence in the area corresponding to the absorbed subretinal material is seen in the right eye (A). Late staining of the vitelliform foveal lesion is noted in the left eye (B).

presence in the area where the subretinal material was previously present (Fig 2A). In the left eye, early hypofluorescence and late staining of the foveal vitelliform lesion were seen (Fig 2B).

#### COMMENT

Submacular haemorrhage has been previously reported in several cases of BVMD during the natural course of the disease.<sup>3</sup> In addition, Benson *et al* reported in 1975 a single case of a child with BVMD who had blunt trauma complicated by rupture of the vitelliform lesion, subretinal haemorrhage, scarring of the fovea, and severe reduction of visual acuity.<sup>4</sup> In an attempt to explain the occurrence of such haemorrhages in BVMD, it was suggested that a metabolic abnormality causes the retinal pigment epithelium and Bruch's membrane in these patients to be especially vulnerable to rupture, with resultant subretinal bleeding from the choriocapillaris.<sup>5</sup> Interestingly, one of the recently identified candidate genes for BVMD is indeed expressed in the RPE.<sup>2</sup>

Our patient had the typical clinical and electrophysiological findings of BVMD. His visual acuity deteriorated in one eye after he suffered blunt trauma that resulted in damage to the retinal pigment epithelium and Bruch's membrane, as evidenced by subretinal bleeding and scarring of the fovea. The yellowish subretinal material that was later absorbed may also represent remnants of dehaemoglobinised subretinal haemorrhage (the patient was first examined 40 days after the trauma). Alternatively, this yellowish material may have originated from the vitelliform lesion ruptured by the trauma. The visual acuity deteriorated following this rupture with formation of a fibrous foveal scar.

The present case and the case reported by Benson *et al* demonstrate that the consequences of blunt trauma in BVMD can be devastating. Vitelliform lesion disruption, haemorrhage and, perhaps, choroidal ruptures can occur, with loss of central visual acuity that may have otherwise persisted for many years. Therefore, it is important to warn patients with BVMD about their vulnerability to trauma and furthermore, as Benson has indicated,<sup>4</sup> patients should be advised to use

protective eyewear, at least when participating in sports or other high impact activities.

ITAY CHOWERS  
EHUD ZAMIR  
EYAL BANIN  
MOHAMMED ABDULRAZIK  
YITZCHAK HEMO

Department of Ophthalmology, Hadassah University Hospital and Hebrew University Hadassah Medical School, Jerusalem, Israel

Correspondence to: Dr Itay Chowers, Department of Ophthalmology, Hadassah University Hospital, PO Box 12000, Jerusalem 91120, Israel  
chowers@md2.huji.ac.il

Accepted for publication 23 June 2000

- 1 Petrukhin K, Koisti MJ, Bakall B, *et al*. Identification of the gene responsible for Best macular dystrophy. *Nat Genet* 1998;19:241-7.
- 2 Marquardt A, Stohr H, Passmore LA, *et al*. Mutations in a novel gene, VMD2, encoding a protein of unknown properties cause juvenile-onset vitelliform macular dystrophy (Best's disease). *Hum Mol Genet* 1998;7:1517-25.
- 3 Braley A. Dystrophy of the macula. *Am J Ophthalmol* 1966;61:1-24.
- 4 Benson WE, Kolker AE, Enoch JM, *et al*. Best's vitelliform macular dystrophy. *Am J Ophthalmol* 1975;79:59-66.
- 5 Deutman A. *The hereditary dystrophies of the posterior pole of the eye*. Springfield, IL: Charles C Thomas, 1971:198.

#### Epidermoid carcinoma arising in an ocular leishmania lesion

EDITOR.—American tegumentary leishmaniasis is an endemic disease occurring in Latin America, especially in Brazil.<sup>1</sup> The agent is the protozoan *Leishmania*, transmitted by sand flies. *Leishmania v braziliensis* causes the mucocutaneous form of the disease, in which systemic dissemination to mucous membranes follows the primary ulcerative skin lesion.

We report a patient with nasal and conjunctival mucous leishmaniasis who developed an epidermoid carcinoma in the orbit.

#### CASE REPORT

A 58 year old man presented with a painless conjunctival mass of 2 months' duration. He reported nasal and mouth wounds and nasal flattening for 3 years and had a depressed scar

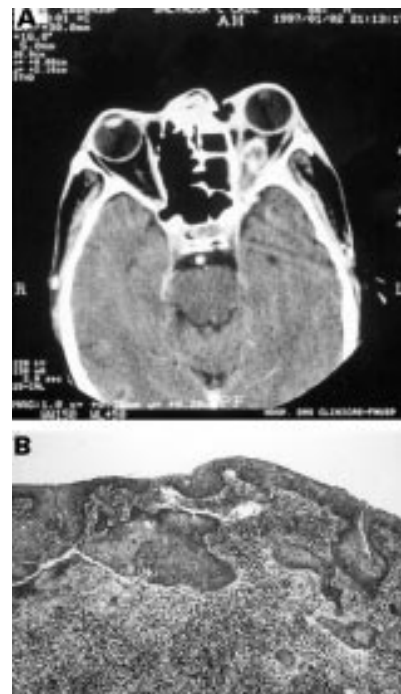


Figure 2 Computed tomography axial scan: the tumour has invaded the left orbital intraconal space, resulting in grade III proptosis (A). Histological section of the left maxillary sinus mucous membranes shows blocks of anaplastic cells invading the lamina propria. (haematoxylin and eosin,  $\times 250$ ) (B).

in his right leg caused by an ulcer that developed 6 years before. He had been treated with N-methyl glucamine antimoniate 2 years before and underwent nasal reconstruction 1 year later. The patient had been a smoker and an alcoholic for 30 years and lived in an endemic region for tegumentary leishmaniasis.

Slit lamp examination revealed a lower left conjunctival nodule of 3 $\times$ 1 cm (Fig 1A) and ipsilateral dacryocystitis. The remainder of the ocular examination was normal. Leishmanin skin test and serology were positive. Biopsies of the conjunctival, mouth, and nasal lesions showed a chronic inflammatory process rich in plasmacytes and an immunohistochemical test was positive for *Leishmania* (Fig 1C). Dacryocystography disclosed left lacrimal duct stenosis and skin fistulisation, left maxillary sinus opacification, and nasal septum destruction. The patient was treated with intravenous amphotericin B (total dose 2500 mg), with reduction of the conjunctival lesion (Fig 1B). Immunohistochemistry in a new biopsy was negative.

The patient was lost to follow up for 2 years, when he showed up with left proptosis and destruction of the internal ocular commissure (Fig 1D). Computed tomography revealed a solid mass eroding the walls of the left maxillary sinus, zygomatic arch, and orbital floor (Fig 2A). A biopsy of the maxillary tumour disclosed epidermoid carcinoma (Fig 2B). The patient underwent left maxillectomy and orbit exenteration. One year after surgery, the patient presented with partial dehiscence of the frontal flap, a local biopsy showing carcinoma recurrence. Face magnetic resonance did not show signs of tumour. The patient did not return to the hospital.

#### COMMENT

The upper airway is the most affected site in mucocutaneous leishmaniasis (MCL), and

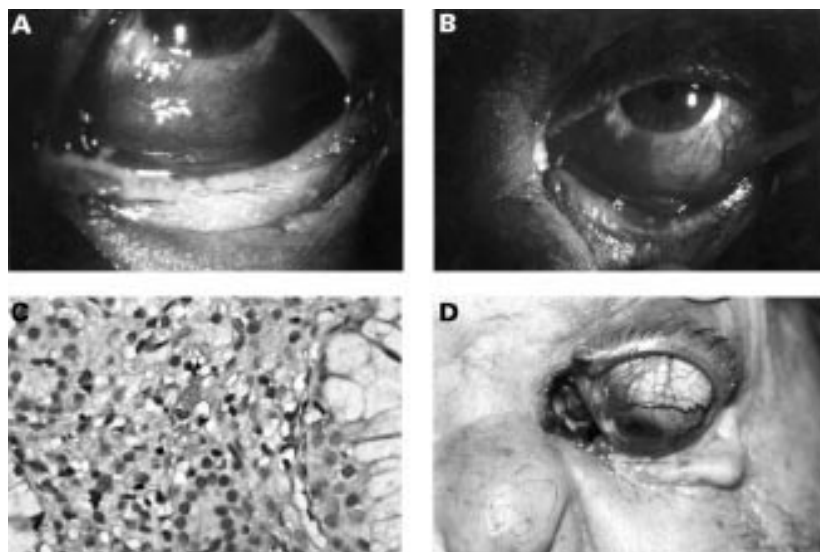


Figure 1 Bulbar erythematous conjunctival nodule with indefinite limits and lacrimal discharge before (A) and after treatment (B). Histopathological section of the conjunctival lesion with leishmania antigens within macrophage (immunoperoxidase technique,  $\times 1000$ ) (C). Proptosis and necrosis of the left internal ocular commissure 2 years after the initial lesion (D).

extensive destruction of nasal mucous membranes and cartilage, invasion of the face sinuses, oral cavity, larynx, and pharynx may occur. Diagnosis is confirmed by the demonstration of intracellular leishmania amastigotes in Giemsa stained slit skin smears, although the parasite may be difficult to find in chronic lesions. Immunohistochemistry for leishmania antigens is an important diagnostic tool. Histopathological analysis discloses features ranging from inflammatory infiltration of mononuclear cells and neutrophils to a granulomatous reaction.<sup>2</sup> Pentavalent antimony is the drug of choice for the treatment of all types of leishmaniasis. In resistant cases, amphotericin B or pentamidine isothionate is indicated.

Cutaneous leishmaniasis of the eyelid is the most common ophthalmological finding in oriental and occidental tegumentary leishmaniasis,<sup>3</sup> and conjunctival involvement may appear as an associated<sup>4</sup> or isolated finding.<sup>5</sup> Other ocular features in MCL include interstitial keratitis,<sup>6</sup> iridocyclitis,<sup>7</sup> and chronic dacryocystitis.<sup>8</sup>

In the case reported here, the malignant tumour may have been present in the initial

condition, but the diagnosis of MCL and the favourable response to treatment meant that a more extensive search for an additional diagnosis was not carried out. The development of a neoplasm at the site of a previous dermal scar is a well recognised phenomenon. Basal cell carcinomas have been reported to arise from a previous cutaneous leishmaniasis lesion.<sup>9,10</sup> To our knowledge, this is the first case of development of a squamous cell carcinoma from a previous mucous leishmania lesion with major involvement of the eye.

SUZANA MATAYOSHI  
CHRISTIANE BADDINI-CARAMELLI  
MAURO GOLDBAUM  
LEDA MINE TAKEI  
MICHEL HONDA  
NEWTON KARA-JOSÉ

*Department of Ophthalmology of the University of São Paulo School of Medicine, São Paulo, Brazil*

Correspondence to: Dr Suzana Matayoshi, R Bergamota, 470 CEP: 05468-000, São Paulo, Brazil  
smillie@usp.br

Accepted for publication 26 May 2000

1 Grimaldi G Jr, Tesh RB, McMahon-Pratt D. A review of the geographic distribution and epide-

miology of leishmaniasis in the New World. *Am J Trop Med Hyg* 1989;41:687-725.

- 2 Sotto MN, Yamashiro-Kanashiro EH, Matta VLR, et al. Cutaneous leishmaniasis of the New World: diagnostic immunopathology and antigen pathways in skin and mucosa *Acta Tropica* 1989;46:121-30.
- 3 Oliveira-Neto MP, Martins VJ, Mattos MS, et al. South American cutaneous leishmaniasis of the eyelids. *Ophthalmology* 2000;107:169-72.
- 4 Sodaify M, Aminlari A, Resaei H. Ophthalmic leishmaniasis. *Clin Exp Dermatol* 1981;6:485-8.
- 5 Abdel-Hameed A, Hassan MEA, Abdalla KM, et al. Two cases of ocular leishmaniasis. *Trop Geogr Med* 1990;9:1-3.
- 6 Roizenblatt J. Interstitial keratitis caused by american leishmaniasis. *Am J Ophthalmol* 1979;87:175-9.
- 7 Ferrari TCA, Guedes ACM, Oréfice F, et al. Isolation of Leishmania sp from aqueous humor of a patient with cutaneous disseminated leishmaniasis and bilateral iridocyclitis. *Rev Inst Med Trop* 1990;32:296-8.
- 8 Machado NR, Machado JGC, Moura PA. Sobre um caso de leishmaniose ocular. *Rev Br Oftalmol* 1958;5:5-20.
- 9 Suster S, Ronnen M. Basal cell carcinoma arising in a leishmania scar. *Int J Dermatol* 1988;27:175-6.
- 10 Morsy TA, Mangoud AM, al-Seghayer SM. Cutaneous leishmaniasis and basal cell carcinoma in a patient from Al Baha, Saudi Arabia. *J Egypt Soc Parasitol* 1992;22:167-70.

#### Video Report ([www.bjophthalmol.com](http://www.bjophthalmol.com))

Capsule staining and mature cataracts: a comparison of indocyanine green and trypan blue dyes. *D F Chang*