

# Changes in ocular surface caused by antiglaucomatous eyedrops: prospective, randomised study for the comparison of 0.5% timolol *v* 0.12% unoprostone

Jun Shimazaki, Kazuomi Hanada, Yukiko Yagi, Junkichi Yamagami, Misaki Ishioka, Shigeto Shimmura, Kazuo Tsubota

## Abstract

**Aim**—To study changes induced in ocular surface epithelia and the tear film by antiglaucomatous eyedrops. A  $\beta$  blocker (0.5% timolol) and a novel prostaglandin  $F_{2a}$  metabolite related drug (0.12% unoprostone) were examined in a prospective, randomised fashion.

**Methods**—40 patients were randomly assigned to use either 0.5% timolol (timolol group) or 0.12% unoprostone eyedrops (unoprostone group) twice a day for 24 weeks. In addition to routine ocular examinations, corneal epithelial integrity (vital staining tests, tear film break up time (BUT), anterior fluorometry, specular microscopy) and tear function (Schirmer's test, cotton thread test, tear clearance test (TCT)) were examined before and after the treatment.

**Results**—Both eyedrops caused significant reduction in intraocular pressure from the baseline levels. No significant changes were noted in corneal integrity in both groups, except a decrease in BUT at 20 weeks in the timolol group. The timolol group demonstrated significant decreases in Schirmer's test, tear clearance test, and tear function index (Schirmer's test value multiplied by clearance test); however, no such changes were noted in the unoprostone group.

**Conclusion**—While unoprostone eyedrops caused no adverse effects on the corneal epithelial integrity and tear function, timolol caused significant impairments in tear production and turnover.

(Br J Ophthalmol 2000;84:1250-1254)

The past 10 years has witnessed the development of a number of antiglaucomatous eyedrops such as  $\beta$  blockers,  $\alpha$  adrenergic stimulants, carbonic anhydrase inhibitors, and prostaglandin analogues. While these new drugs expanded the choice of treatment, they also increased risks of drug related complications. Since antiglaucomatous eyedrops are used for a long period of time, chronic side effects are a major concern. Among these side effects, ocular surface disorders are relatively common, which are caused by either the drug itself or by preservatives.<sup>1-3</sup> This complication has recently attracted attention in Japan, especially since a prostaglandin F metabolite

related drug, unoprostone, was introduced.<sup>4-7</sup> The incidence of corneal complications is reported to be up to 12.9% of patients using unoprostone eyedrops.<sup>8-11</sup> It is not clear, however, if unoprostone is truly responsible for the complication because many of these patients had been using other antiglaucomatous eyedrops—namely,  $\beta$  blockers. It has been reported that  $\beta$  blockers alter corneal sensitivity and ocular surface epithelia.<sup>12-15</sup> Therefore, it is not clear whether or not the ocular surface complications in glaucoma patients are attributed to the use of unoprostone,  $\beta$  blockers, or the combination of both. We conducted a randomised, prospective comparative study on the changes in ocular surface epithelia and tear functions in patients who used either unoprostone or timolol eyedrops.

## Subjects and methods

### PATIENTS

Forty patients with primary open angle glaucoma (n=8), normal tension glaucoma (n=6), or ocular hypertension (n=26) were enrolled in this open labelled, randomised prospective study. Patients with autoimmune disease, contact lens use, history of using any antiglaucomatous eyedrops, and patients who were frequent users of eyedrops other than artificial tears were excluded from the study. This study followed the tenets of the Declaration of Helsinki. After explaining the aim of the study, informed consent was obtained from all patients. There were 11 men and 29 women, with a mean age of 60.6 (SD 13.2) years. The demographic profile of the patients is shown in Table 1. Patients were randomly assigned to use either 0.5% timolol (Timoptol, Banyu Pharmaceutical Co, Tokyo, Japan: timolol group) or 0.12% isopropyl unoprostone (Rescula, Fujisawa Pharmaceutical Co, Osaka, Japan: unoprostone group) using an envelope method. Both eyedrops contained benzalkonium chloride (BAK) as a preservative, with a concentration of 0.005% in timolol and 0.01% in unoprostone. These patients were instructed to use the eyedrops twice a day in both eyes. Only one eye of a subject with a higher Schirmer's test value was analysed in order to reduce influence caused by desiccation. Four eyes in both the unoprostone and timolol groups had diabetes mellitus, under good hyperglycaemic control.

Department of  
Ophthalmology, Tokyo  
Dental College, Chiba,  
Japan  
J Shimazaki  
K Hanada  
M Ishioka  
S Shimmura  
K Tsubota

Department of  
Ophthalmology,  
University of Tokyo  
School of Medicine  
J Yamagami

Correspondence: Dr Jun Shimazaki, Department of Ophthalmology, Tokyo Dental College, 5-11-13 Sugano, Ichikawa-shi, Chiba, 272-8513, Japan  
jun@eyebank.or.jp

Accepted for publication  
16 May 2000

Table 1 Demographic profile of the subjects

	Timolol (n=20)	Unoprostone (n=20)
Age (mean (SD))	61.9 (12.7)	59.3 (13.9)
Sex (M:F)	6:14	5:15
Diseases		
POAG	4	4
NTG	2	4
OH	14	12
Associated disorders		
DM	4	4
Hypertension	2	1
Dry eye	1	3
Macular degeneration	1	0
Pre IOP (mean (SD))	20.8 (4.14)	20.8 (4.69)
Pre VA (mean)	1.07	1.02
C/D ratio (mean (SD))	0.48 (0.19)	0.52 (0.17)

OH = ocular hypertension; IOP = intraocular pressure; VA = corrected visual acuity; C/D = cup to disc ratio.

Table 2 Study protocol

Examinations	Weeks						
	0	4	8	12	16	20	24
Visual acuity	X			X			X
Intraocular pressure	X	X	X	X	X	X	X
C/D ratio	X						X
Visual field	X						X
Cotton thread test	X			X			X
Schirmer's test	X			X			X
Tear clearance test	X			X			X
Fluorescein score	X			X			X
Rose bengal score	X			X			X
Specular microscopy	X			X			X
Anterior fluorometry	X			X			X

X indicates the timing when the examinations are performed.

EXAMINATIONS

After routine ophthalmic examinations including visual acuity, intraocular pressure, fundus examination, and Goldmann perimetry various ocular surface and tear function tests were performed according to the protocol shown in Table 2. For vital staining, 2 µl of preservative-free 1% sodium fluorescein and 1% rose bengal solution were instilled, and staining of the corneal and conjunctival epithelium was evaluated semiquantitatively.<sup>16,17</sup> Tear film break up time (BUT) was measured after the vital staining tests, and the average of three measurements was used as a representative value. Schirmer's test was performed 5 minutes after the instillation of 1% sodium fluorescein. The dilution of the fluorescein colour on the paper strip was evaluated semiquantitatively for the tear clearance test (TCT), and the logarithm of the value was calculated.<sup>18</sup> Tear function index (TFI), which is a more sensitive measure of tear function than Schirmer's test, was calculated by multiplying log TCT by the Schirmer's test value.<sup>19</sup> The cotton thread test was performed to evaluate the volume of tears in the conjunctival cul de sac.<sup>20</sup> Dry eye was defined as eyes having both positive vital staining (fluorescein score ≥1 or rose bengal score ≥3) and decreased tear function (either Schirmer's value ≤5 mm, cotton thread test value ≤10 mm, or BUT ≤5 seconds).

For the evaluation of morphology and barrier function of the corneal epithelium, specular microscopy and anterior fluorometry were performed. In specular microscopy, the central corneal epithelium was photographed using a wide field specular microscope (CSP-580, Konan Co, Hyogo, Japan) with a special-

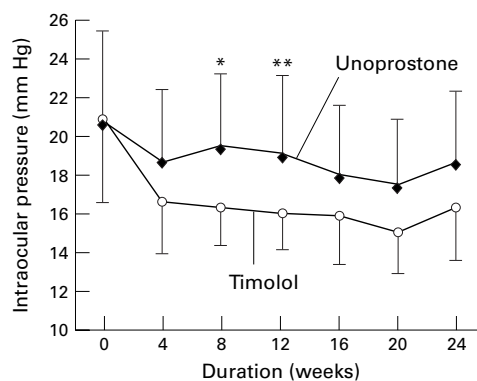


Figure 1 Changes in intraocular pressure in the unoprostone and timolol groups. \*p=0.0086, \*\*p=0.014 between the unoprostone and timolol groups.

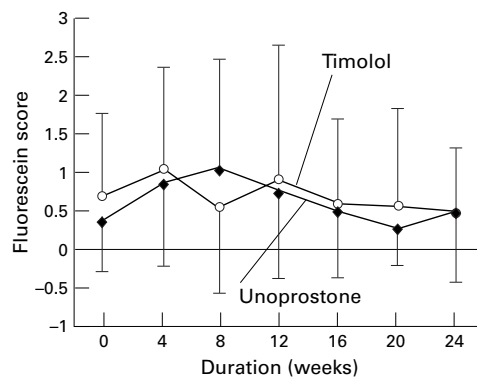


Figure 2 Changes in fluorescein scores in the timolol and unoprostone groups.

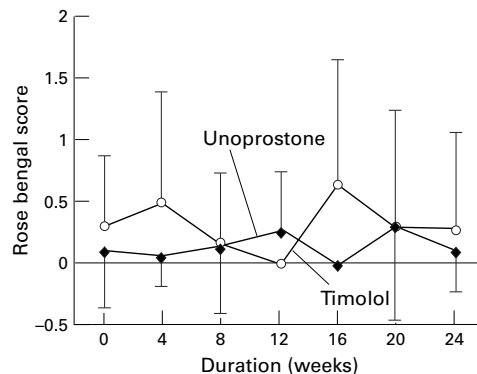


Figure 3 Changes in rose bengal scores in the timolol and unoprostone groups.

ised contact lens to photograph the epithelium (SM Lens, Rainbow Contact Ltd, Tokyo, Japan).<sup>21,22</sup> The presence of elongated superficial epithelial cells (a long axis/short axis ratio >2), and increases in the exposed cell area, calculated using a cell analysis system (Cell Analysis System Version 3.2, Sun Contact Lens Co, Kyoto, Japan), were used as parameters of epithelial cell changes. The barrier function of the corneal epithelium was examined using fluorophotometry (Anterior Fluorometer, FL-500, Kowa Co, Tokyo, Japan) by a method described previously.<sup>23</sup> Briefly, a fluorophotometer coupled with a biomicroscope was used to measure fluorescence in the corneal stroma 20 minutes after instillation of 1% preservative-free sodium fluorescein, followed by gentle washing with BSS-plus (Alcon,

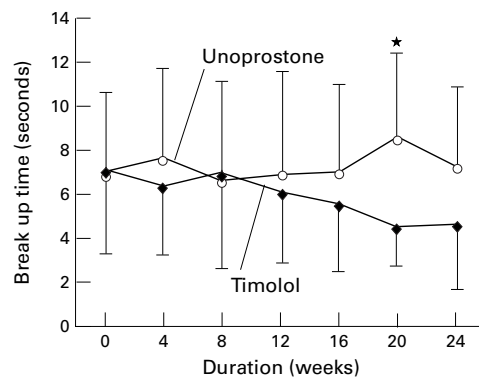


Figure 4 Changes in BUT in the unoprostone and timolol groups. \* $p = 0.0087$  between the timolol and unoprostone groups.

Fort Worth, TX, USA). The mean fluorescent intensity before the instillation of fluorescein was recorded as background fluorescence. The background fluorescence intensity was subtracted from the average of 10 fluorescein uptake counts, and the value was converted into the corresponding fluorescein concentration. After the above examinations on the ocular surface epithelial and tear function were performed, intraocular pressure was re-examined and either timolol or unoprostone was started.

#### STATISTICAL ANALYSIS

Data were presented as the mean (SD). Between group differences in age, BUT, Schirmer's test, and cotton thread test were

Table 3 Changes in corneal epithelial area, barrier function, and tear function tests

	Weeks	Timolol	Unoprostone	p Value
Corneal epithelial area ( $\mu\text{m}^2$ )	0	710.5 (189.0)	757.7 (171.2)	0.45
	12	725.4 (177.5)	814.3 (152.9)	0.19
	24	670.4 (120.0)	785.3 (175.4)	0.093
Fluorescein uptake (ng/ml)	0	152.6 (178.8)	53.6 (41.9)	0.025
	12	117.6 (85.9)	83.7 (93.4)	0.29
	24	143.5 (140.8)	71.0 (52.2)	0.10
Cotton thread test (mm/15 s)	0	25.3 (9.1)	21.9 (8.1)	0.22
	12	22.4 (8.1)	26.6 (8.0)	0.19
	24	22.5 (9.7)	27.0 (7.8)	0.22
Schirmer's test (mm/5 min)	0	12.5 (8.4)	16.4 (11.1)	0.22
	12	9.50 (4.3)	17.1 (11.4)	0.031
	24	7.82 (3.0)	16.1 (9.7)	0.011
Tear clearance test (log2)	0	2.95 (1.05)	3.45 (1.47)	0.22
	12	2.57 (1.45)	3.57 (1.40)	0.075
	24	2.18 (1.33)	3.92 (1.66)	0.010
Tear function index	0	40.9 (39.5)	61.4 (57.6)	0.20
	12	24.1 (18.0)	66.4 (61.1)	0.025
	24	17.3 (15.1)	67.5 (55.5)	0.0073

Table 4 Changes in corneal epithelial area, barrier function, and tear function tests in eyes with diabetes mellitus and dry eye

	Weeks	Timolol		Unoprostone	
		DM/DE (+)	DM/DE (-)	DM/DE (+)	DM/DE (-)
BUT (s)	0	6.80 (2.4)	7.33 (4.4)	5.71 (2.6)	7.77 (3.9)
	12	6.25 (1.0)	6.09 (3.8)	5.50 (3.3)	7.56 (5.2)
	24	5.00 (1.0)	4.50 (3.4)	8.20 (5.2)	6.78 (2.7)
Schirmer's test (mm/5 min)	0	13.8 (5.3)	12.1 (9.4)	13.9 (10.2)	17.7 (11.6)
	12	10.8 (5.6)	9.00 (3.9)	13.2 (12.4)	19.3 (10.9)
	24	10.0 (2.0)	7.00 (2.9)	15.2 (11.9)	16.6 (9.0)
Tear clearance test (log2)	0	2.20 (0.8)	3.20 (1.0)	3.71 (1.9)	3.25 (1.5)
	12	1.00 (0.8)	3.20 (1.1)*	4.00 (1.6)†	3.33 (1.3)
	24	1.67 (2.08)	2.38 (1.1)	4.60 (1.7)	3.64 (1.6)
Tear function index	0	31.6 (18.5)	43.9 (44.5)	56.1 (70.6)	59.1 (49.5)
	12	10.3 (8.2)	29.6 (18.0)	65.4 (82.4)	56.7 (48.6)
	24	16.0 (21.2)	17.8 (14.0)	81.0 (78.6)	53.9 (38.2)

\* $p=0.0044$ , † $p=0.011$ , compared with the value of the DM/DE (+) in the timolol group. BUT = tear film break up time; DM = diabetes mellitus; DE = dry eye.

evaluated using the non-paired Student's  $t$  test. Differences between pretreatment and post-treatment values were evaluated using the paired Student's  $t$  test. Mann-Whitney's rank test was used to evaluate differences in staining scores, tear clearance, and tear function index.

#### Results

Five and four patients in the timolol and unoprostone group, respectively, did not complete the study protocol, and only available data were used in this study. One patient in the unoprostone group complained of foreign body sensation, and another patient in the same group noticed decrease in vision. There were no other patients reporting marked changes in subjective symptoms which may have been related to the use of the eyedrops.

#### CHANGES IN VISUAL ACUITY, INTRAOCULAR PRESSURE, OPTIC DISC, AND VISUAL FIELD

No significant changes were found in the corrected visual acuity, cup to disc ratio, and visual fields before and after treatment in either the timolol or unoprostone groups. Both groups demonstrated a significant reduction of intraocular pressure after treatment, although more reduction was observed in the timolol than the unoprostone group (Fig 1).

#### CHANGES IN VITAL STAINING AND BUT

Fluorescein and rose bengal scores did not change significantly throughout the observation period in either timolol or unoprostone groups. No differences were noted in vital staining tests between the timolol and unoprostone groups (Figs 2 and 3). Although the mean BUT values did not change significantly in either groups compared with the pretreatment values, BUT gradually decreased in the timolol group, and became significantly shorter by the 20th week compared with the unoprostone group (Fig 4).

#### CHANGES IN MORPHOLOGY AND BARRIER FUNCTION OF THE CORNEAL EPITHELIUM

Changes in the mean epithelial area and fluorescein uptake value in the unoprostone and timolol groups are demonstrated in Table 3. No elongated corneal epithelial cells were noted in either the unoprostone or timolol groups, before or after the treatment. The mean epithelial area also showed no significant changes in both groups. Although the fluorescein uptake value was significantly higher in the unoprostone than the timolol group before the treatment, no differences were noted after treatment.

#### CHANGES IN TEAR FUNCTION TESTS

The cotton thread test did not show significant changes in either timolol or unoprostone groups. The Schirmer's test value gradually decreased in the timolol group but not in the unoprostone group. The difference between the two groups was statistically significant at 12 and 24 weeks (Table 3). Both TCT and TFI gradually decreased in the timolol group compared with the unoprostone group, suggesting tear turnover rate had decreased in the former group.

INFLUENCE OF DIABETES MELLITUS AND DRY EYE  
Eight and four eyes had diabetes mellitus and dry eye, respectively before treatment. In order to examine the influence of these pre-existing disorders, eyes with these abnormalities were analysed separately. It was demonstrated that changes in tear function (Schirmer's test, TCT, and TFI) and BUT were noted in the timolol group irrespective of the presence of either diabetes mellitus or dry eye (Table 4).

### Discussion

PGF analogue eyedrops have a unique pressure reducing mechanism—that is, by increasing the uveoscleral outflow.<sup>4-7 24-26</sup> The first commercially available PGF<sub>2α</sub> eyedrops in Japan, isopropyl unoprostone, was introduced to the market in 1996. While the response of the market has been favourable in general, some reports indicated that the drug might increase the incidence of ocular surface complications. Tachibana and associates reported that 38 out of 294 eyes (12.9%) developed corneal epithelial disorders following the use of unoprostone.<sup>11</sup> They reported that it took more than 4 weeks for epithelialisation in 14 eyes (36.8%) after cessation of unoprostone eyedrops.<sup>11</sup> However, most of the reported cases had been using other antiglaucomatous drugs,<sup>8-11</sup> and there are no well controlled prospective studies regarding the effects of unoprostone on ocular surface and tears.

The results of the present study demonstrated two important findings. One is that unoprostone eyedrops did not cause adverse effects on either ocular surface or tear function in most of the eyes examined. Specular microscopy and anterior fluorometry of the corneal epithelium are very sensitive measures of changes in morphology and function of the corneal epithelium, respectively. These methods have been shown to detect subclinical abnormalities caused by dry eyes syndrome, contact lens wear, diabetes, and corneal surgeries.<sup>21-23 27-31</sup> Therefore, the results of the present study indicated that unoprostone eyedrops alone do not cause ocular surface changes at least in normal eyes. This finding seems to contradict previous clinical reports. The difference is probably caused by different study design—that is, most of the previous studies were conducted retrospectively, and included eyes that had used other antiglaucomatous eyedrops.<sup>8-11</sup> For example, Most eyes (36 out of 38 eyes) having corneal abnormalities reported by Tachibana and associates had been using other antiglaucomatous eyedrops.<sup>11</sup>

Changes in corneal epithelial barrier function caused by unoprostone and timolol have been also studied by Komuro and associates.<sup>30</sup> They reported that neither timolol nor unoprostone alone caused impairment of epithelial barrier function. However, eyes that had both timolol and unoprostone eyedrops showed significantly increased fluorescein uptake (decreased barrier function). Toshino and associates recently demonstrated that unoprostone inhibits the proliferation of cultured human corneal epithelial cells. They postulated that a combination of impaired epithelial barrier

function induced by β blocker eyedrops and cytotoxic effects of unoprostone eyedrops contributes to epithelial problems.<sup>31</sup>

Another important finding of the present study was that timolol, the most commonly prescribed antiglaucoma eyedrops, caused significant adverse effects on tear function. Adverse effects of β blocker eyedrops on the ocular surface have been described previously. It has been shown that β blocker eyedrops inhibited proliferation of corneal epithelial cells.<sup>15 32</sup> Clinical studies indicated that β blocker eyedrops caused a decrease in corneal sensitivity, goblet cell density, and tear production.<sup>3 12 13</sup> In the present study, we performed extensive examinations on both ocular surface epithelia and tear functions. As a result, timolol was shown to cause decreases in both tear production (decrease in Schirmer's test value) and tear turnover (decrease in TCT). TFI is an integrated parameter of both production and clearance of tears,<sup>19</sup> and the values were significantly decreased by the use of timolol. Although we did not examine corneal sensitivity, it is conceivable that decreased corneal and conjunctival sensitivity resulted in a decreased blink rate, and a decrease in the tear turnover. These changes in tear function increase both concentration and exposure time of drugs and preservatives. It is reasonable to consider that eyes that had been using β blockers had decreased tear production and tear turnover, and an additional use of unoprostone caused ocular surface changes.

We anticipated that eyes with predisposing factors in ocular surface abnormalities such as dry eye or diabetes mellitus may cause changes in ocular surface epithelia more readily. However, we did not find any significant differences in tear function between eyes with and without such predisposition. This may be due to the small sample size, or the fact that only eyes with dry eye or diabetes mellitus with mild symptoms were included in this study.

In conclusion, we found that a new PGF metabolite related antiglaucoma eyedrop, isopropyl unoprostone, does not cause adverse effects on either ocular surface epithelia or tear function. In contrast, timolol eyedrops caused a significant reduction in tear production and turnover. Pretreatment evaluation of tear function is necessary when timolol eyedrops are used.

The authors do not have any proprietary interest in the products mentioned.

- 1 Wilson FM. Adverse external ocular effects of topical ophthalmic medications. *Surv Ophthalmol* 1979;24:57-88.
- 2 Sherwood MB, Grierson J, Millar L, et al. Long-term morphologic effects of antiglaucomatous drugs on the conjunctiva and Tenon's capsule in glaucoma patients. *Ophthalmology* 1989;96:327-35.
- 3 Herreras JM, Pastor JC, Calonge M, et al. Ocular surface alteration after long-term treatment with an antiglaucomatous drug. *Ophthalmology* 1992;99:1082-8.
- 4 Haria M, Spencer CM. Unoprostone (isopropyl unoprostone). *Drug Aging* 1996;9:213-8.
- 5 Yamamoto T, Kitazawa Y, Azuma I, et al. Clinical evaluation of UF-021. *Surv Ophthalmol (Suppl)* 1997;41:S99-103.
- 6 Sakurai M, Araie M, Oshika T, et al. Effects of topical application of UF-021, a novel prostaglandin-related compound, on aqueous humor dynamics in rabbit. *Jpn J Ophthalmol* 1993;27:252-8.
- 7 Azuma I, Masuda K, Kitazawa Y, et al. Double-masked comparative study of UF-021 and timolol ophthalmic

- solutions in patients with primary open-angle glaucoma of ocular hypertension. *Jpn J Ophthalmol* 1993;37:514-25.
- 8 Sakamoto Y, Iwasaki N, Maeda N, et al. Corneal epithelial lesion induced by prostaglandin F2 $\alpha$  ophthalmic solution. *Rinsho Ganka (Jpn J Clin Ophthalmol)* 1995;49:1845-8.
  - 9 Kokawa N, Yokoi N, Matsumoto Y, et al. Seven cases of severe ocular surface disorders following topical antiglaucoma agents. *Rinsho Ganka (Jpn J Clin Ophthalmol)* 1996;50:1105-8.
  - 10 Sakata N, Tagawa Y, Matsuda A, et al. Five cases of corneal epithelial complication induced by antiglaucomatous (PGF2 $\alpha$ ) eye drops. *Ganki (Folia Ophthalmol Jpn)* 1997;48:757-60.
  - 11 Tachibana N, Kimura T, Ishii R, et al. Epithelial keratitis induced by new medicine for glaucoma therapy: prostaglandin F2 $\alpha$  derivative—*isopropyl unoprostone*. *Atarashii Ganka (Journal of the Eye)* 1996;13:1097-101.
  - 12 Van Buskirk EM. Adverse reactions from timolol administration. *Ophthalmology* 1980;87:447-50.
  - 13 Weissman SS, Asbell PA. Effects of topical timolol (0.5%) and betaxolol (0.5%) on corneal sensitivity. *Br J Ophthalmol* 1990;74:409-12.
  - 14 Kùppens EVMJ, Stolwijk TR, van Best JA. Topical timolol, corneal epithelial permeability and autofluorescence in glaucoma by fluorophotometry. *Graefes Arch Clin Exp Ophthalmol* 1994;32:221-4.
  - 15 Reidy JJ, Zarzour J, Thompson HW, et al. Effect of topical  $\beta$ -blockers on corneal epithelial wound healing in the rabbit. *Br J Ophthalmol* 1994;78:377-80.
  - 16 Toda I, Tsubota K. Practical double vital staining for ocular surface evaluation. *Cornea* 1993;12:366-7.
  - 17 Van Bijsterveld OP. Diagnostic tests in the sicca syndrome. *Arch Ophthalmol* 1969;82:10-4.
  - 18 Ono M, Tsubota K, Yoshino K, et al. Tear fluid clearance test. *Rinsho Ganka (Jpn J Clin Ophthalmol)* 1991;45:1143-7.
  - 19 Xu KP, Yagi Y, Toda I, et al. Tear function index; a new measure of dry eye. *Arch Ophthalmol* 1995;113:84-8.
  - 20 Sakamoto R, Bennett ES, Henry VA, et al. The phenol red thread test: a cross-cultural study. *Invest Ophthalmol Vis Sci* 1993;34:3510-4.
  - 21 Tsubota K. In vivo observation of the corneal epithelium. *Scanning* 1994;16:295-9.
  - 22 Tsubota K, Yamada M, Naoi S. Specular microscopic observation of human corneal epithelial abnormalities. *Ophthalmology* 1991;98:184-91.
  - 23 Yokoi N, Kinoshita S. Clinical evaluation of corneal epithelial barrier function with the slit-lamp fluorophotometer. *Cornea* 1995;14:485-9.
  - 24 Toris CB, Camras CB, Yablonski ME. Effects of PhXA41, a new prostaglandin F2 $\alpha$  analog, on aqueous humor dynamics in human eyes. *Ophthalmology* 1993;100:1297-304.
  - 25 Camras CB. Mechanism of the prostaglandin-induced reduction of intraocular pressure in humans. *Adv Prostaglandin Thromboxane Leukotriene Res* 1995;23:519-25.
  - 26 Mishima HK, Kiuchi Y, Takamatsu M, et al. Circadian intraocular pressure management with latanoprost: diurnal and nocturnal intraocular pressure reduction and increased uveoscleral outflow. *Surv Ophthalmol* 1997;41:S139-44.
  - 27 Tsubota K, Yamada M. Corneal epithelial changes induced by disposable contact lens wear. *Ophthalmology* 1992;99:1193-6.
  - 28 Tsubota K, Chiba K, Shimazaki J. Corneal epithelium in diabetic patients. *Cornea* 1991; 10:156-60.
  - 29 Shimazaki J, Fujishima H, Yagi Y, et al. Effects of diclofenac eye drops on corneal epithelial structure and function after small-incision cataract surgery. *Ophthalmology* 1996;103:50-7.
  - 30 Komuro A, Yokoi N, Matsumoto Y, et al. Effect of topical instillation of prostaglandin F2 $\alpha$  on the barrier function of corneal epithelium. *Rinsho Ganka (Jpn J Clin Ophthalmol)* 1996;50:1109-11.
  - 31 Toshino A, Okamoto S, Shimamura I, et al. The mechanism of corneal epithelial disorder induced by prostaglandin F2 $\alpha$  isopropyl unoprostone. *Nichigan Kaishi (J Jpn Ophthalmol Soc)* 1998;102:101-5.
  - 32 Trope GE, Liu GS, Basu PK. Toxic effects of topically administered Betagen, Betoptic, and Timoptic on regenerating corneal epithelium. *J Ocular Pharmacol*. 1988;4:359-66.