

LETTERS TO THE EDITOR

Endophthalmitis following globe perforation with a hypodermic needle

EDITOR.—Exogenous endophthalmitis is a common complication of intraocular foreign bodies (IOFBs).¹ It commonly occurs in association with a non-metallic foreign body and often results in profound visual loss.² Early diagnosis and treatment with intravitreal antibiotics are essential in its treatment.³ We describe an unusual case of exogenous endophthalmitis caused by a heroin filled needle, the patient rapidly losing vision despite active intervention.

CASE REPORT

A 24 year old remand prisoner presented to the casualty department with a vague 2 day history of visual loss in his right eye. He had been stabbed in the eye 2 days previously with a hypodermic needle, which had recently been used for heroin injections.

The patient had a visual acuity of hand movement vision in the affected eye, which was inflamed and had a fibrinoid uveitis. A 3 mm hypopyon was present but a puncture wound was not visible. No fundus view was present. A high reflectivity shadow was seen in the vitreous on B scan ultrasonography (Fig 1A) and an intraocular hypodermic needle was confirmed on plain x ray (Fig 1B).

The patient underwent a vitreous biopsy and intravitreal ceftazidime 2 mg/0.1 ml, vancomycin 2 mg/ml, and amphotericin B 0.005 mg/ml. The following day, a three port pars plana vitrectomy was performed. Postoperatively, the retina was observed to be detached with two giant retinal tears, one temporally and one nasally. Widespread periphlebitis and retinal necrosis was noted (Fig 2). The broken hypodermic needle was recovered and removed through a corneal incision. Retinal

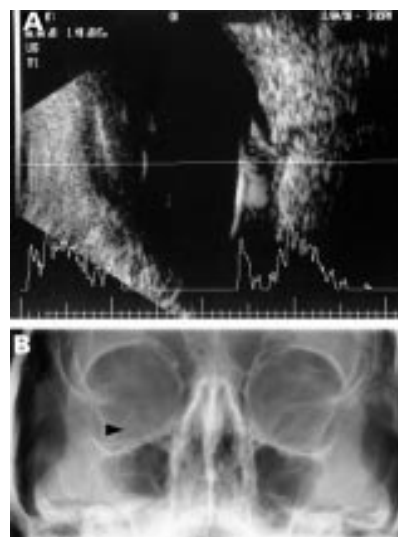


Figure 1 (A) Ultrasound of the right eye showing a linear reflection in vitreous. (B) A plain x ray showing the intraocular hypodermic needle.

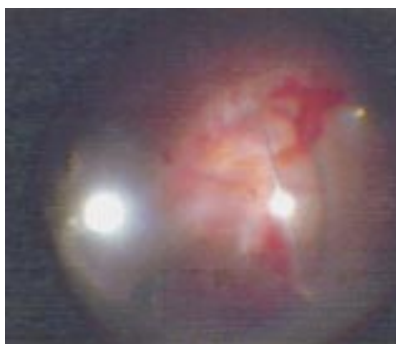


Figure 2 Showing the needle within vitreous, areas of retinal necrosis, and periphlebitis.

detachment repair was undertaken with heavy liquids, silicone oil, and endolaser photocoagulation. Postoperatively, he was treated with intravenous ciprofloxacin 750 mg twice daily, chloramphenicol eyedrops 1/2 hourly, atropine eyedrops 1% twice daily, Pred Forte eyedrops (Allergan) 1/2 hourly, and 40 mg prednisolone orally.

The endophthalmitis settled slowly postoperatively, the retina remained flat but vision was reduced to perception of light. The vitreous biopsy grew *Streptococcus oralis* which was sensitive to chloramphenicol.

COMMENT

Penetrating eye injuries predominantly occur in young males, and are a common cause of monocular visual loss.⁴ Endophthalmitis occurs in around 15% of patients with intraocular foreign bodies, the commonest organisms being *Staphylococcus epidermidis* (23.4%) and mixed organisms (17.3%). The visual prognosis is particularly poor with concurrent infection, 82.3% of patients having no perception of light.

The timing of surgery remains contentious. Many authors recommend vitrectomy within 14 days of presentation, particularly if there is retinal detachment. The advantage of intervening before proliferative vitreoretinopathy has develops usually outweighs the universal risk of intraoperative haemorrhage in a recently traumatised globe. In our case endophthalmitis and sight loss developed as a result of *Streptococcus oralis* contaminated hypodermic needle, which is an uncommon intraocular pathogen.

A unique factor of this case was the marked retinal necrosis, which was presumed to be due to heroin toxicity. The delay in presentation and co-toxicity of heroin significantly worsened the prognosis for this patient.

POORNIMA RAI
RICHARD NEWSOM
KAMIAR MIRESKANDARI
DOMINIC MCHUGH
King's College Hospital, London

Correspondence to: Miss P A Rai, Department of Ophthalmology, King's College Hospital, Denmark Hill, London SE5 9RS
rai@poornima.demon.co.uk

Accepted for publication 27 January 2000

- Mieler WF, Ellis MK, William DF, *et al*. Retained intraocular foreign bodies and endophthalmitis. *Ophthalmology* 1990;97:1532–8.
- Chiquet C, Zech JC, Gain P, *et al*. Visual outcome and prognosis factors after magnetic extraction of posterior segment foreign bodies in 40 cases. *Br J Ophthalmol* 1998;82:801–6.
- Seal DV, Kirkness CM, Criteria for intravitreal antibiotics during surgical removal of intraocular foreign bodies *Eye* 1992;6:465–8.

- Dannenber AL, Parver LM, Fowler CJ. Penetrating eye injuries related to assault: the national eye trauma registry. *Arch Ophthalmol* 1992;110:849–52.
- Duch-Samper AM, Menezes JL, Hurtad-Sarrio M. Endophthalmitis following penetrating injuries. *Acta Ophthalmol Scand* 1997;75:104–6.

Intranasal passage of dacryoliths

EDITOR.—Causes of tearing fall into two broad categories—hypersecretion and lacrimal drainage insufficiency. We present two patients in whom chronic intermittent epiphora resolved after the passage of putty-like casts of the nasolacrimal duct and sac.

CASE 1

A 33 year old man was referred to the Dartmouth-Hitchcock Medical Center with an 8 year history of intermittent right sided tearing. Several previous irrigations of his right lacrimal drainage system had temporarily settled the symptoms.

On examination, the patient exhibited tearing of the right eye and marked pain, tenderness, and erythema at the right medial canthus. During lacrimal irrigation through the right lower canaliculus, a mass of material entered the patient's throat. The material was a cast of putty-like consistency in the shape of the nasal lacrimal sac and duct (Fig 1A). There was immediate relief of both pain and watering. The cast grew sparse *Aspergillus* species. The patient declined further investigation or treatment, but continues to have intermittent recurrences of symptoms.

CASE 2

A 35 year old woman was referred to Moorfields Eye Hospital with a 13 year history of intermittent epiphora associated with pain at the left inner canthus. On several occasions, after spontaneous passage of material into her throat, she would note complete resolution of her symptoms. The patient retained one such specimen (Fig 1B) which was a putty-like cast of the nasolacrimal duct.

Ocular examination was entirely normal, fluorescein dye clearance was fast on both sides, and both lacrimal drainage systems were freely patent to irrigation. Dacryocystography (Fig 2) was normal, with no retention of oily contrast on the erect film to suggest an abnormality of drainage at the nasal end of the nasolacrimal duct.¹ The patient declined further intervention and has been asymptomatic for 2 years.

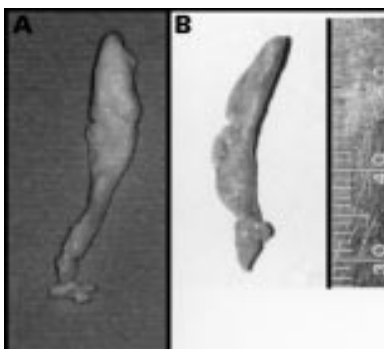


Figure 1 (A) Case 1. Putty-like cast passed with lacrimal irrigation. (B) Case 2. Putty-like cast passed spontaneously.

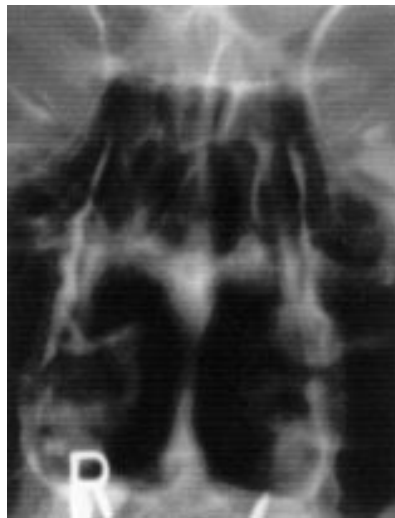


Figure 2 Dacryocystogram showing normal nasolacrimal drainage system.

COMMENT

Most patients with chronic tearing have drainage insufficiency caused by abnormalities anywhere along the outflow pathway: punctal disorders, canalicular or lacrimal pump deficiencies, lacrimal sac or duct abnormalities, or intranasal pathology.² Our cases show that dacryoliths, or putty-like casts, originating in the nasolacrimal system may cause intermittent epiphora and dacryocystitis, and that the casts can be passed relatively readily or spontaneously.

A similar case of a patient with 14 years of intermittent epiphora, relieved by the passage of a dacryolith, has been described,³ and the author suggested that such casts may comprise an extremely slow aggregation of cellular debris. Our two cases presented similar histories and presented for diagnosis in the fourth decade of life—dacryolithiasis being commoner in the young.⁴

The aetiology of dacryoliths is unclear, although they largely comprise protein and cellular debris. Fungus, yeast, and eyelashes have been described as possible niduses.^{4,5} The specimen from case 1 grew *Aspergillus*, which may have served as a nidus. Local stagnation or turbulent flow might allow a coalescence of debris within the lacrimal drainage system with formation of a cast.⁵ A dilated lacrimal sac or a diverticulum might predispose to such stagnation. However, case 2, with normal dacryocystography, would suggest that an anatomical abnormality of the lacrimal drainage system is not a necessary requirement for the formation of a dacryolith.

WILLIAM J ROSEN

Dartmouth Medical School, Hanover, NH, USA

GEOFFREY E ROSE

Moorfields Eye Hospital, London, England

Correspondence to:

William J Rosen, MD, Section of Ophthalmology, Dartmouth-Hitchcock Medical Center, One Medical Center Drive, Lebanon, NH 03756, USA
william.j.rosen@hitchcock.org

Accepted for publication 3 February 2000

1 Wearne MJ, Pitts J, Frank J, *et al.* Comparison of dacryocystography and lacrimal scintigraphy in the diagnosis of functional nasolacrimal duct obstruction. *Br J Ophthalmol* 1999;83:1032-5.

2 Tanenbaum M. Lacrimal drainage system disorders: diagnosis and treatment. In: McCord CD, Tanenbaum M, Nunnery WR, eds. *Oculoplastic surgery*. 3rd ed. New York: Raven Press, 1995:341-78

3 Kaye-Wilson LG. Spontaneous passage of a dacryolith. *Br J Ophthalmol* 1991;75:564.

4 Orhan M, Onceri M, Orhan D, *et al.* Lacrimal sac dacryolith: a study with atomic absorption spectrophotometry and scanning electron microscopy. *Eur J Ophthalmol* 1996;6:478-80.

5 Barratz KH, Bartley GB, Campbell RJ, *et al.* An eyelash nidus for dacryoliths of the lacrimal excretory and secretory systems. *Am J Ophthalmol* 1991;111:624-7.

Treatment of recurrent giant iris cyst with intracyst administration of mitomycin C

EDITOR,—Iris cysts may be primary—that is, developmental in nature, or secondary following surgery or penetrating trauma. In the latter case, the condition is due to implantation of epithelial cells from the ocular surface, and thus these lesions are also referred to as epithelial implantation cysts.¹ We report the successful treatment of a post-traumatic, recurrent, giant iris cyst by needle aspiration combined with intracyst administration of dilute mitomycin C.

CASE REPORT

A 32 year old woman was referred with the complaint of decreased vision as a result of a recurrent giant iris cyst in the left eye. She had a vague history of penetrating trauma involving a piece of glass at the age of 8. Laser cystotomy had been performed at other institutions 7 and 4 years before presentation at our hospital; however, recurrence of the cyst occurred soon each time. On our initial examination, the visual acuity was 20/15 right eye and 20/200 left eye. Slit lamp biomicroscopy revealed a full thickness corneal scar and a large iris cyst centred in the inferonasal quadrant, extending over the central visual axis and occupying roughly 60% of the anterior chamber (Fig 1A). The anterior surface of the cyst appeared to be in contact with the posterior cornea although the overlying cornea was clear and compact. The intraocular pressure was normal. After pupillary dilatation the cyst was noted to still be blocking the visual axis, with lens opacification in the inferotemporal quadrant observed. The fundus was unremarkable. Ultrasound biomicroscopy (UBM) revealed that the cyst also extended posteriorly to a substantial degree (Fig 1B). Endothelial cell density (ECD) at the central cornea was 2720 cells/mm² right eye and 1600 cells/mm² left eye.

Given the history of recurrence following previous attempts at laser treatment of the cyst, a surgical procedure was performed. The cyst was pierced directly using a 30 gauge needle through the peripheral cornea at 1 o'clock. After approximately 0.3 ml of clear fluid was aspirated, the cyst was reduced to roughly one fifth of its original size, and the anterior surface of the cyst was observed to separate from the posterior cornea. Next, 0.3 ml of 10⁻³ mg/ml mitomycin C (2 mg in 2000 ml of balanced salt solution) was injected into the cyst and left for 5 minutes, after which most of the fluid in the cyst was aspirated. This was followed by injection and aspiration of 0.3 ml of balanced salt solution, repeated three times, in order to wash out any residual mitomycin C. No complications were observed during the procedure. The intraocular pressure (IOP) rose transiently to 22 mm Hg and mild anterior chamber fibrin was noted on the first postoperative day, although these symptoms resolved quickly with topical corticosteroids. At 18 months postoperatively, the visual acuity in the left eye was 20/30, with no recurrence of the cyst by slit lamp or ultrasound biomicroscopy (Fig 2A, B). The IOP

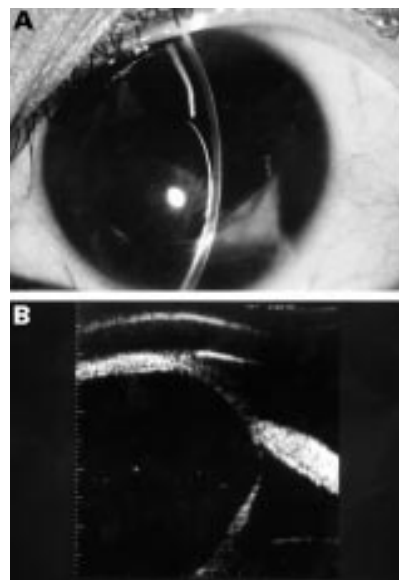


Figure 1 (A) A full thickness corneal scar and a large iris cyst centred in the inferonasal quadrant were noted at presentation. (B) Ultrasound biomicroscopy showed that the cyst extended significantly into the posterior chamber, pushing against the lens.

was normal and there was no evidence of epithelial downgrowth. At this time, the ECD was 1538 cells/mm² in the left eye, representing a decrease of only 4%. No other toxicity related to the intracameral use of mitomycin C was detected by clinical examination, electroretinography, colour testing, contrast sensitivity testing, and Humphrey automated perimetry.

COMMENT

Photocoagulation of iris implantation cysts can induce a rise in IOP believed to be due to clogging of the trabecular meshwork by released viscous contents of the cyst.² Moreover, since the original structure and function of the epithelial lining of the cyst remains fundamentally unchanged, recurrence after

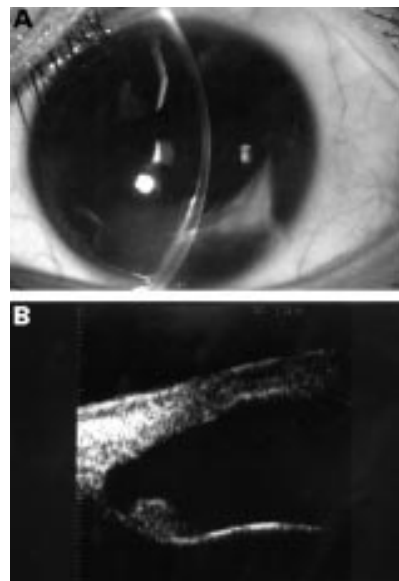


Figure 2 (A) Eighteen months postoperatively, no cystic structure was observed in the anterior chamber. (B) UBM revealed shrinkage of the cyst to a small mass on the anterior surface of the iris.

photocoagulation is common.² Total surgical excision may be performed, although the cyst can be adherent to the posterior surface of the cornea and excessive surgical manipulation may induce epithelial downgrowth. Simple transcorneal needle drainage is much less invasive and has the advantage of little cyst fluid entering the anterior chamber; however, it too is associated with recurrence.¹

In this case report, we have demonstrated that needle drainage combined with intracyst administration of dilute mitomycin C may be an effective and safe alternative to other treatment modalities. Mitomycin C is a DNA cross linking antineoplastic agent used at doses of 0.2–0.5 mg/ml on exposed Tenon's capsule and sclera in glaucoma filtering surgery, and at somewhat lower doses in surgery for recurrent pterygium, in the attempt to inhibit fibroblast proliferation.³ Toxicity associated with such use can include conjunctival irritation, tearing, and superficial punctate keratopathy. The dose of mitomycin C we used was the same as the dose shown to inhibit proliferation of retinal pigment epithelial cells.⁴ We speculate that mitomycin C, applied transiently to the lining of the cyst, caused permanent damage to the epithelial and goblet cells which secrete cyst fluid, resulting in regression of the cyst. Although implantation iris cysts represent a relatively rare condition, larger numbers of cases would be necessary to confirm the efficacy and safety of this novel treatment.

KIYOTOMI KAWAGUCHI
SHUJI YAMAMOTO
YASUNOBU NAGAE
ANNABELLE A OKADA
NAOKI IWASAKI
YASUO TANO

Department of Ophthalmology, Osaka University
Graduate School of Medicine E7, 2-2 Yamadaoka,
Suita 565-0871, Japan

Correspondence to: Dr Yamamoto

Accepted for publication 24 February 2000

- Eiferman RA, Rodrigues MM. Squamous epithelial implantation cyst of the iris. *Ophthalmology* 1981;88:1281–5.
- Tsukamoto H, Nakano K, Mishima H, et al. Six cases of iris cyst. *Nihon Ganka Kiyo [Folia Ophthalmologica Japonica]* 1990;41:1195–201.
- Singh G, Wilson MR, Foster CS. Mitomycin eye drops as treatment for pterygium. *Ophthalmology* 1998;95:813–20.
- Del Priore LV, Kaplan HJ, Hornbeck R, et al. Retinal pigment epithelial debridement as a model for the pathogenesis and treatment of macular degeneration. *Am J Ophthalmol* 1996;122:629–43.

Scleritis as a presenting feature of Takayasu's disease

EDITOR.—Takayasu's (pulseless) disease is a chronic inflammatory arteriopathy of unknown aetiology and was first described in 1908 by an ophthalmologist, Takayasu.¹ Although he described some retinal features of the disease he did not discuss the absence of any arterial pulses. It occurs more commonly in young oriental women and affects the aorta and/or its major branches giving rise to end organ hypoperfusion.² The major complications attributed to the disease include Takayasu's retinopathy, secondary hypertension, aortic regurgitation, and arterial aneurysms. The ophthalmological complications are generally late manifestations of the disease and include ischaemia of the retina, choroid, and anterior segment.³ We describe a patient with Takayasu's disease who presented with scleritis of her left eye.

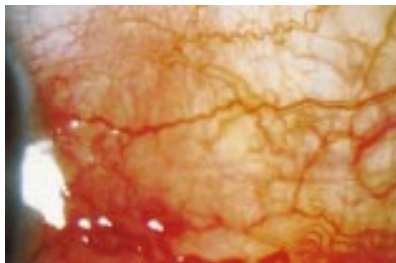


Figure 1 Anterior scleritis as a presenting feature of Takayasu's disease.

CASE REPORT

A 39 year old Asian woman presented to Moorfields Eye Hospital casualty department with a red, painful left eye and was diagnosed as having anterior scleritis (Fig 1). Her visual acuities were 6/5 right and left and intraocular pressures were normal. There was no retinal vasculitis and no history of any previous ocular problems. She had been investigated eighteen months earlier for left intermittent arm pain with claudication and had been diagnosed as having left subclavian artery occlusion. She was a non-smoker and no underlying cause for the arterial disease had been identified at that time. Investigations following the diagnosis of scleritis included a raised erythrocyte sedimentation rate at 72 mm in the first hour, microcytic anaemia, and raised PEG immune complexes at 24.8. Antinuclear antibodies (ANA) and antineutrophilic cytoplasmic antibodies (ANCA) were negative. Clinical examination revealed absent pulses in the radial, ulnar, and brachial arteries of her left arm with carotid and subclavian bruits. The right arm blood pressure (BP) measured 100/60 and the leg BP was 180/100. An arch aortogram (Fig 2) showed complete occlusion of the left common carotid and subclavian arteries and a tight stenosis of the proximal right subclavian artery with a mild stenosis of the right carotid artery. An echocardiogram showed mild mitral valve regurgitation. A diagnosis of Takayasu's disease made, and the patient was started on oral cyclophosphamide (2 mg/kg/day), prednisolone (60 mg daily), and amlodipine to treat the hypertension (the leg BP was taken as the true BP reading). Her scleritis rapidly resolved with this regimen, and she subsequently underwent successful reconstructive arterial surgery.

COMMENT

Takayasu's disease has an incidence of 2.6 per million per year with a female to male ratio of 9:1.⁴ Although more commonly affecting orientals it has been described in all races⁵ and classically presents in the second to fourth decades of

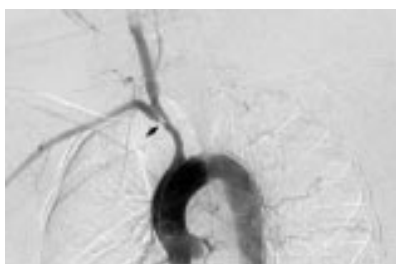


Figure 2 Arch aortogram demonstrating complete occlusion of the left subclavian and left common carotid arteries, with extensive collateral circulation formation. There is tight focal stenosis of the proximal right subclavian artery (arrow) but minimal right common carotid and vertebral artery involvement.

life. Scleritis is a feature of many of the vasculitides^{6,7} but has not previously been described as a presenting feature of Takayasu's disease. There have been reports of patients with Takayasu's disease and scleritis who were later diagnosed as having Wegener's granulomatosis.^{8,9} These patients were reported to have raised ANCA titres, however, which is rare in Takayasu's disease.^{10–12} The ANCA titre was negative in the patient we describe. This case alerts us to the possibility of Takayasu's disease presenting as a more acute inflammatory ocular picture before any signs of the chronic ischaemic changes in the eye can be found.

RAJNI JAIN

ALEXANDER IONIDES

CARLOS PAVESIO

Moorfields Eye Hospital, City Road, London
EC1V 2PD

ANDREW RUSSELL

DORIAN HASKARD

Hammersmith Hospital, 150 Du Cane Road,
Shepherd's Bush, London W12 0HS

Correspondence to: Miss R Jain, Western Eye Hospital, Marylebone Road, London NW1
rajni@jain1000.freemove.co.uk

Accepted for publication 24 February 2000

- Takayasu M. A case with peculiar changes of the central retinal vessels. *Acta Soc Ophthalm Jpn* 1908;12:55.
- Ishikawa K. Takayasu's disease. In: Weatherall DJ, Ledingham JGG, Warrell DA, eds. *Oxford textbook of medicine*. 2nd ed. Oxford: Oxford Medical, 1987;13:193–6.
- Lewis JR, Glaser JS, Schatz NJ, et al. Pulseless (Takayasu) disease with ophthalmic manifestations. *J Clin Neuro-Ophthalmol* 1993;13:242–9.
- Bleck TP. Takayasu's disease. In: Toole JF, ed. *Handbook of clinical neurology*. Vol 11. Chicago: Elsevier, 1989:335–40.
- Hall S, Barr W, Lie JT, et al. Takayasu's arteritis: a study of 32 North American patients. *Medicine* 1985;94:89.
- Hakin KN, Watson PG. Systemic associations of scleritis. *Int Ophthalmol Clin* 1991;31:111–29.
- Akova YA, Jabbar NS, Foster CS. Ocular presentation of polyarteritis nodosa. Clinical course and management with steroid and cytotoxic therapy. *Ophthalmology* 1993;100:1775–81.
- Jolly SS, Bronstein S, Jordan DR, et al. Scleritis in a patient with limited Wegener's granulomatosis and Takayasu's disease. *Can J Ophthalmol* 1995;30:371–3.
- Yamasaki S, Eguchi K, Kawabe Y, et al. Wegener's granulomatosis overlapped with Takayasu arteritis. *Clin Rheum* 1996;15:303–6.
- Shwartz-Eywill M, Breitbart A, Csernok E, et al. Treatment modalities and ANCA in Takayasu's arteritis. In: Gross WL, ed. *ANCA-associated vasculitides: immunological and clinical aspects*. New York: Plenum Press, 1993:497–501.
- Niles JL. Value of tests for antineutrophilic cytoplasmic autoantibodies in the diagnosis and treatment of vasculitis. *Curr Opin Rheumatol* 1993;5:18–24.
- Soukiasian SH, Foster SC, Niles JL, et al. Diagnostic value of antineutrophilic cytoplasmic antibodies in scleritis associated with Wegener's granulomatosis. *Ophthalmology* 1992;99:125–32.

Acute visual loss by an Onodi cell

EDITOR.—In the literature Onodi cells occur in 3.4–51% of people.^{1,2} The paranasal sinus "Anatomic terminology group" defines the Onodi cell as the most posterior ethmoid cell which pneumatizes laterally and superiorly to the sphenoid and is intimately associated with the optic nerve. Using this definition the incidence of Onodi cells is 8–14%.^{3–5}

The occurrence of optic neuropathy caused by a pathological process in an Onodi cell is explained by the close relation to the optic nerve, because it often runs within the small cavity of the Onodi cell.⁶

Orbital inflammation associated with paranasal sinusitis is a well known cause of optic neuropathy,⁷ but an isolated mucocoele of an Onodi cell causing optic neuropathy is rare.^{8,9}

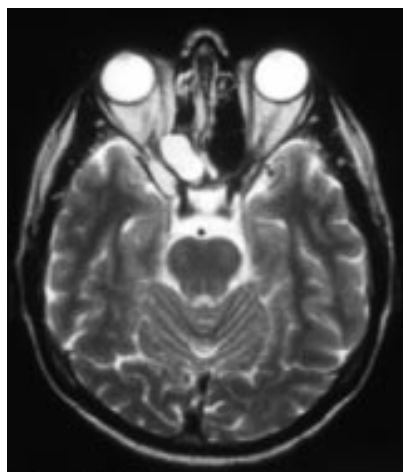


Figure 1 Axial T2 weighted magnetic resonance image of the orbit showing a kidney bean-shaped mass of 1 × 2 cm and high signal intensity in the right orbital apex.

We report a case of acute visual loss caused by an isolated mucocoele of an Onodi cell.

CASE REPORT

A 41 year old man was referred to our outpatient department in February 1998 with acute visual deterioration in the right eye and a central scotoma. He complained about having visual impairment for the past 2 weeks and "black dots" in his central visual field. His medical and family history were unremarkable.

Examination disclosed a visual acuity of hand movements on the right and 20/20 on the left. A swinging flashlight test revealed an afferent pupillary defect on the right. Slit lamp biomicroscopy and direct and indirect ophthalmoscopy were normal on both sides. Goldmann perimetry showed a central scotoma of 20° on the right and no pathological findings on the left. The clinical otorhinolaryngological status was unremarkable. Magnetic resonance imaging (MRI) showed a kidney bean-shaped mass of 1 × 2 cm and high signal intensity in the T2 weighted images in the right orbital apex, which compressed the optic nerve superomedially (Figs 1 and 2).

Optic neuropathy caused by an isolated mucocoele in an Onodi cell was diagnosed. The patient underwent endoscopic microsurgical sinus surgery. Intraoperatively the diagnosis was confirmed. Nine days after surgery the

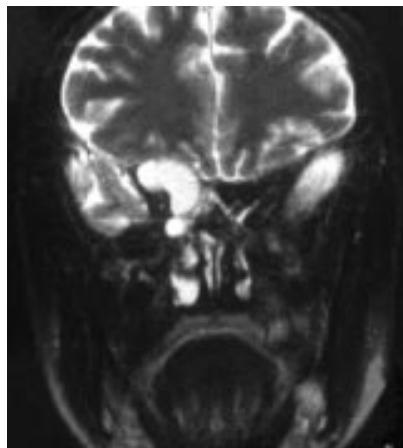


Figure 2 Coronal T2 weighted magnetic resonance image of the orbit showing a mass which compressed the optic nerve superomedially.

patient's visual acuity recovered to 20/30 and the initial central scotoma was reduced to a small paracentral scotoma.

Three months later the patient presented again with a recurrence of the mucocoele, but without changes in visual acuity and visual field in comparison with the last examination. Surgery was repeated and showed a blockage in the former surgical field causing the relapse of the mucocoele. Three weeks after the second intervention visual acuity improved to 20/20 and only a very small paracentral scotoma was detected. One year after the second operation the visual acuity is stable and the paracentral scotoma has disappeared.

COMMENT

The importance of the most posterior localized ethmoidal cell and its close relation to the optic nerve where first described by Adolf Onodi (1857–1920), professor of laryngology, University of Budapest, Hungary in 1904.¹⁰

Most authors have found an incidence of 8–14%.^{3–6} Onodi cells are mainly pneumatized laterally. Its location is usually superior and lateral to the sphenoid sinus.

ENT surgeons who perform endonasal sinus surgery, especially, should know about the anatomical variation. There is the substantial risk of injury to the optic nerve and even more, to the internal carotid artery, which is in close anatomical relation to the Onodi cell.²

Optic neuropathy is a well known complication of paranasal sinusitis and mucocoeles,⁷ but there are only few cases in literature which describe an isolated mucocoele in an Onodi cell as the cause of optic neuropathy.^{8,9} The mechanism of retrobulbar optic neuropathy is a mechanical compression of the optic nerve, because it often runs within the small cavity of the Onodi cell.⁵

Axial and coronal MRIs are of great value in detecting those lesions in the orbital apex.^{8,9} Coronal computed tomography is helpful in the differential diagnosis of an osseous origin and preoperative evaluation.^{2,3,8,9}

In our patient we saw that an immediate decompression of the optic nerve led to considerable improvement of visual acuity and field, even in a case of drastic functional impairment. A close interdisciplinary cooperation with other medical specialties such as ENT and neuroradiology is essential for adequate diagnosis and treatment.

In patients with retrobulbar optic neuropathy an isolated Onodi cell mucocoele should be considered in the differential diagnosis.

T KLINK

Department of Ophthalmology,
Julius-Maximilians-University, Würzburg, Germany

J PAHNKE
F HOPPE

Department of Otorhinolaryngology,
Julius-Maximilians-University, Würzburg, Germany

W LIEB

Department of Ophthalmology,
Julius-Maximilians-University, Würzburg, Germany

Correspondence to: Dr T Klink, Universitäts-Augenklinik Würzburg, Josef-Schneiderstrasse 11, D-97080 Würzburg, Germany

Accepted for publication 24 February 2000

- Dixon FW. A comparative study of the sphenoid sinus: A study of 1,600 skulls. *Ann Otol Rhinol Laryngol* 1937;46:687–98.
- Kainz J, Stammberger H. Danger areas of the posterior rhinobasis. *Acta Otolaryngol* 1992;112:852–61.
- Weinberger DG, Anand VK, Al-Rawi M, et al. Surgical anatomy and variations of the Onodi cell. *Am J Rhinol* 1996;10:365–70.

- Jones NS, Strobl A, Holland I. A study of the CT findings in 100 patients with rhinosinusitis and 100 controls. *Clin Otolaryngol* 1997;22:47–51.
- Stammberger HR, Kennedy DW. Paranasal sinuses: anatomic terminology and nomenclature. *Ann Otol Rhinol Laryngol* 1995;104(Suppl 167):7–16.
- Lang J. Paranasal Sinuses. In: Lang J, ed. *Clinical anatomy of the nose, nasal cavity and paranasal sinuses*. New York: Thieme, 1989:88–9.
- Chawla HS, Goodwin JA, Ticho BH, et al. Orbital and sinus inflammation with secondary optic neuropathy. *Ann Ophthalmol* 1991;23:231–3.
- Ogata Y, Okinaka Y, Takahashi M. Optic neuropathy caused by an isolated mucocoele in an Onodi cell. *ORL J Otorhinolaryngol Relat Spec* 1998;60:349–52.
- Lim CC, Dillon WP, McDermott MW. Mucocoele involving the anterior clinoid process: MR and CT findings. *Am J Neuroradiol* 1999;20:287–90.
- Onodi A. Die Sehstörungen und Erblindung nasalen Ursprunges, bedingt durch Erkrankungen der hinteren Nebenhöhlen. *Z Augenheilkd* 1904;12:23–46.

Spontaneous arteriovenous malformation of the orbit

EDITOR,—Arteriovenous malformations (AVMs) and fistulas are rare in the orbit and generally have been associated with previous trauma. Of the 627 orbital tumours reported by Wright,¹ only three were arteriovenous malformations. We report the clinical and pathological findings in a patient with an apparent spontaneous malformation.

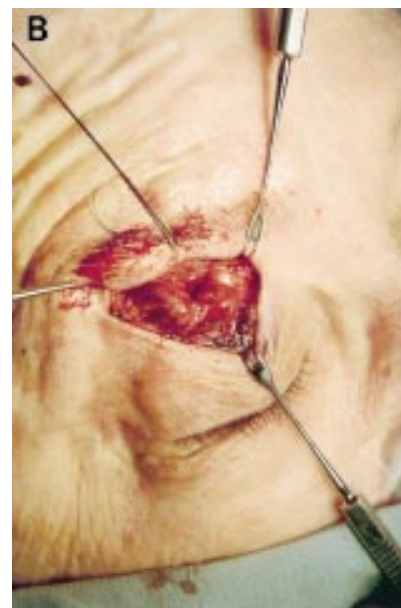
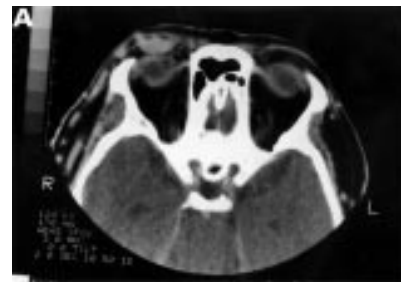
Figure 1 (A) Computed tomographic scan shows a soft tissue homogeneous mass in the right upper eyelid, 2.5 × 1 cm in size, retroseptal, anteriorly placed, separate from lacrimal gland and eyeball, and without any extension in the orbit or cranium. (B) Surgical exposure of arteriovenous malformation via anterior approach shows large sausage-shaped, thick walled, pulsating lesion with several tributaries.

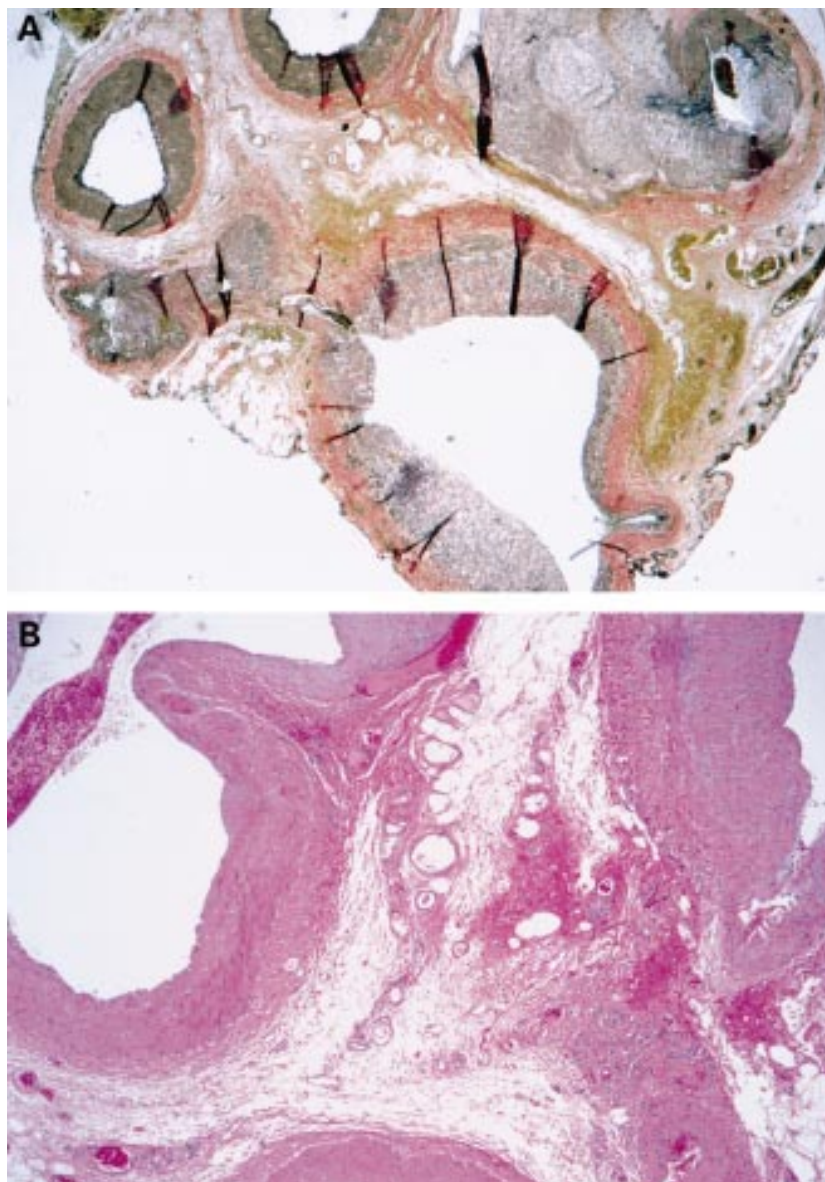


Figure 2 (A) Congeneries of arteries and veins in arteriovenous malformation (elastic tissue stain, original magnification $\times 25$). (B) Arteriovenous malformation (haematoxylin and eosin stain, original magnification $\times 50$).

CASE REPORT

A 74 year old white woman presented with a 2 month history of painless, progressive swelling of the right upper eyelid with no antecedent history of inflammation, trauma, or surgery. Ocular examination revealed visual acuity 20/30 in both eyes and an elastic, partially compressible, movable, pulsating tumour of 2.5×1 cm in size, located superiorly in the right upper eyelid, with a thrill over the lesion but no bruit and no accentuation on Valsalva. The remainder of the ophthalmic examination was unremarkable. Computed tomography (Fig 1A) showed a localised, homogeneous retroseptal mass. Because of the extremely anterior location of the lesion, further investigation with MRI/MRA or with selective angiography was not undertaken. During surgery (Fig 1B), a pulsating lesion was found with several tributaries. Each tributary was ligated and excised individually. The pulsations after excision of the temporal aspect of the tumour suggested a nasal origin, apparently arising from the

medial palpebral branches of the ophthalmic artery. Pathology (Fig 2) showed a typical AVM.

COMMENT

AVM is the least common of the various orbital and periorbital vascular tumours.¹ AVM consists of a communication between artery and veins with no interposed capillary bed. Pathologically, this communication is lined with endothelium and has characteristics of both arteries and veins.^{2,3} Many of these will have a palpable thrill even if a bruit is not present.^{2,3} Currently, a complete surgical excision of the AVM remains the most successful therapy.^{2,4} In this case, the surgical excision of the tumour through an anterior approach produced excellent cosmetic and functional results. Deeper orbital AVMs can haemorrhage severely without careful control of the feeder vessels.⁵ To our knowledge, this is the first reported case of a spontaneous

orbital AVM presenting as a pulsatile tumour of the eyelid.

RICHARD J HESSE
VINOD K JINDAL
NILS MUNGAN

Department of Ophthalmology, Ochsner Clinic and
Alton Ochsner Medical Foundation, New Orleans, LA
70121, USA

JOHN C SCHARFENBERG
Department of Pathology

LUIS BERNHARD
Department of Ophthalmology

Correspondence to: Dr Richard J Hesse, Department of Ophthalmology, Ochsner Clinic, 1514 Jefferson Highway, New Orleans, LA 70121, USA
rhesse.csspo.css@ochsner.org
Accepted for publication 15 February 2000

- 1 Wright JE. Orbital vascular anomalies. *Trans Am Acad Ophthalmol Otolaryngol* 1974;78:606-16.
- 2 Flanagan JC. Vascular problems of the orbit. *Ophthalmology* 1979;86:896-913.
- 3 Holt JE, Holt GR, Thornton WR. Traumatic arteriovenous malformation of the eyelid. *Ophthalmic Surg* 1980;11:771-7.
- 4 Busin M, Graefe C, Koch J. Arteriovenous fistula presenting as a tumor of the upper eyelid. *Ophthalmic Surg* 1994;25:471-3.
- 5 Rootman J, Stewart B, Goldberg RA. *Orbital surgery: a conceptual approach*. Philadelphia: Lippincott-Raven, 1995:53-7, 270.

Perceptual distortion around homonymous scotomas is not restricted to defects located in the right hemifield

EDITOR,—In the February 1999 issue of the *BJO*, we reported that subjects presenting with a right homonymous paracentral scotoma experienced “filling in” of field defects and, as a result did not perceive their scotoma.¹ Moreover, the subjects described in our study noted that, after a few seconds of steady fixation, a perceptual distortion occurred in areas surrounding the defect, as if images bordering the scotoma were pulled toward the centre of the defect. We suggested that this phenomenon was due to a process of plasticity in the visual cortex.

In the same issue Dr Neil R Miller published a most interesting editorial devoted to our study, in which he raised a number of questions regarding the perceptual phenomena described.² In particular, he wondered whether distortion occurred with homonymous field defects on both sides of the visual space or only with right sided defects. A recent clinical observation has allowed us to clarify this issue. We therefore believe that it deserves to be briefly reported.

CASE REPORT

A 20 year old, right handed woman underwent occipital transtentorial excision of a right pineal cyst that caused triventricular hydrocephalus. The surgical procedure resulted in a small localised alteration in the right calcarine cortex, which was demonstrated on magnetic resonance imaging (MRI). The occipital abnormality clearly appeared on T2 post-contrast images as a small stroke localised in the middle calcarine cortex. The visual cortex alteration induced a small absolute scotoma, located paramedially in the left homonymous visual field. The scotoma was about two degrees in width and in height, and was centred 7 degrees below the horizontal meridian. Using a white on black Amsler grid, the patient was unable to note any defect, confirming that filling-in occurred in this patient. The scotoma was absolute when tested at 1 metre distance from the tangent screen, using a 10 W/1000 stimulus. However,

the patient perceived no gap in the visual field. When she was asked to fixate steadily the nose of her examiner, who was facing her from a distance of 60 cm, she volunteered after about 8 seconds that her examiner's right shoulder appeared to be slightly contracted, and about 5 or 6 cm lower, and some 4 cm narrower, than the left shoulder. The homonymous scotoma was then delineated using a laser pointer, and was found to overlie the examiner's axillary area.

COMMENT

Our patient presented with a minute lesion in the right calcarine cortex, a common sequela of an occipital transtentorial approach to the pineal area.³ As a result, she was found to have a small left homonymous scotoma. Neuro-ophthalmological evaluation corroborated our previous findings that homonymous defects are "filled in", and that images surrounding the defects are perceptually displaced towards the scotoma. This report answers one of the questions asked by Miller—namely, whether this perceptual phenomenon is restricted to scotomas located in the right homonymous field. We found that spatial distortion also occurred with defects located in the left homonymous field. The homonymous scotoma was re-delineated using a laser pointer, and was found to overlie the examiner's axillary area. This finding has practical and theoretical implications.

Occurrence of a spatial distortion following alteration on either right or left homonymous visual field does not imply that the characters of changes in spatial perception are identical in both conditions. Indeed, specialisation of right and left cerebral hemispheres has been demonstrated in human normal subjects—for example, using functional magnetic resonance imaging (fMRI).⁴ In that fMRI study, it was shown that a stronger activation occurs in the left than in the right angular gyrus with categorical tasks (that is, when asking to judge whether a dot was presented above or below a horizontal line), whereas stronger activation occurred initially on the right than on the left angular gyrus in a coordinate task (that is, when subjects were asked to judge whether or not the distance between a dot and a bar was within a reference distance). In addition, the authors showed that, in the later task, the involvement of the right angular gyrus decreased with practice, while that of the left angular gyrus increased. Thus, obviously, although both hemispheres are involved in spatial function, there is theoretical evidence suggesting that some degree of hemispheric specialisation can be found in the process involved in visual perception of space. Within the frame of our clinical observation, however, these experimental data had no evident clinical implications.

This study was supported by the Swiss National Fund for Scientific Research, grants nos 3200-040780.94, 3200-0409594.96, and by the Aetas Foundation and the Sir Jules Thorn Foundation.

AVINOAM B SAFRAN
Ophthalmology Clinic, Department of Clinical
Neuroscience and Dermatology, Geneva University
Hospitals, Geneva, Switzerland

BENEDICT RILLIET
N DE TRIBOLET
Neurosurgery Clinic

THEODOR LANDIS
Neurology Clinic

Correspondence to: Professor Avinoam B Safran,
Ophthalmology Clinic, Department of Clinical Neuro-
science and Dermatology, Geneva University Hos-
pitals, 1211 Geneva 14, Switzerland

Accepted for publication 24 February 2000

- 1 Safran AB, Achard O, Duret F, *et al.* The "thin man" phenomenon: a sign of cortical plasticity following inferior homonymous paracentral scotomas. *Br J Ophthalmol* 1999;**83**:137–42.
- 2 Miller NR. The "thin man" phenomenon: imperfect filling-in of visual space. *Br J Ophthalmol* 1999;**83**:131–3.
- 3 Nazzaro JM, Shults WT, Neuwelt EA. Neuro-ophthalmological function of patients with pineal region tumors approached transtentorially in the semisitting position. *J Neurosurg* 1992;**76**:746–51.
- 4 Baciau M, Koenig O, Vernier MP, *et al.* Categorical and coordinate spatial relation: fMRI evidence for hemispheric specialization. *NeuroReport* 1999;**10**:1373–8.