

LETTERS TO THE EDITOR

Spontaneous closure of a macular hole secondary to an accidental laser injury

EDITOR.—Early surgical intervention has been reported to achieve closure of laser induced macular holes.^{1,2} We report a case of spontaneous closure of a laser induced macular hole indicating that surgery should not be undertaken before a reasonable period of observation.

CASE REPORT

A 24 year old physics postgraduate student accidentally sustained an injury to his right eye while aligning an 806 nm titanium-sapphire laser. The laser parameters were pulse energy 2 mJ, pulse duration 100 femtoseconds, and repetition rate 10 Hz. The duration of exposure was limited by his blink reflex. He noted immediate impairment of central vision in this eye.

When examined by an ophthalmologist 2 days later, visual acuity was 6/18 in the right eye. Amsler testing demonstrated an absolute paracentral scotoma which was 1.5° in diameter and abutted fixation. A full thickness macular hole was present with loss of both neurosensory retina and retinal pigment epithelium (RPE). The hole was approximately 150 µm in diameter and located at the

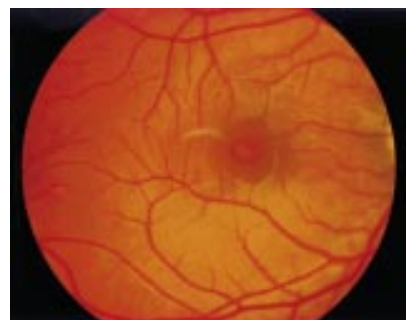

Figure 1 Posterior pole at 4 weeks after injury. There is a full thickness macular hole with a surrounding cuff of subretinal fluid and associated retinal elevation. Visual acuity was 6/18 with an absolute scotoma in the nasal paracentral region.

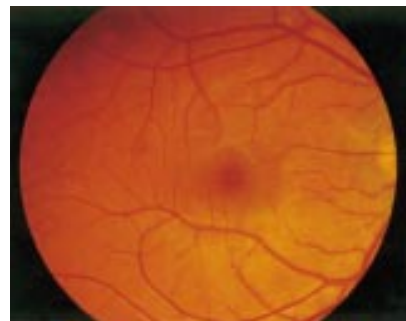

Figure 2 Posterior pole at 12 weeks after injury. The macular hole is closed with good apposition of the surrounding neurosensory retina to the RPE. There is residual RPE depigmentation at the site of the laser injury. Visual acuity was 6/6 with a relative scotoma in the nasal paracentral region.

temporal margin of the foveola. There was no associated retinal oedema or haemorrhage. Fluorescein angiography showed a hyperfluorescent transmission defect.

At 4 weeks after injury, a cuff of subretinal fluid had developed around the macular hole (Fig 1). Visual acuity remained 6/18, but the size of the scotoma had correspondingly increased. The option of surgical intervention was considered, but a conservative approach was chosen at this stage.

The patient noticed a gradual improvement in his vision approximately 4 weeks later. At 12 weeks after injury, his visual acuity was 6/6. Amsler testing now demonstrated a relative paracentral scotoma which was 0.5° in diameter and located 1° from fixation. The macular hole was closed with residual RPE depigmentation at the site of the laser injury (Fig 2). There was no posterior vitreous detachment. No further changes occurred during 6 months of follow up.

COMMENT

The mechanism of macular hole formation following accidental exposure to a Q switched laser is photomechanical tissue disruption (rather than photocoagulation).³ The natural history of these laser induced macular holes remains uncertain because this type of injury is uncommon. In a series of five cases, spontaneous closure was only observed in one eye which occurred at 3 weeks after injury.⁴ Two other cases of non-resolving laser induced macular holes have also been reported.^{5,6}

This case report confirms that laser induced macular holes can close spontaneously with visual improvement. Furthermore, this event may be delayed for 8–12 weeks following the injury. The occurrence of spontaneous closure could possibly be influenced by macular hole size. The diameter of macular holes that have spontaneously resolved was 150 µm in this case and 180 µm in the previous report.⁴ While non-resolving macular holes have generally been larger (250–500 µm in diameter^{4,5}), a 75 µm macular hole has been observed to enlarge without spontaneous closure.⁴ Spontaneous closure of small traumatic macular holes (0.1 disc diameter) has also been reported at 3–4 months after the injury.⁷

There have been two recent reports of laser induced macular holes being successfully treated by early surgical intervention, performed at 3 weeks¹ and 6 weeks² after injury, respectively. In both cases, the macular hole was 300 µm in diameter. Surgery comprised pars plana vitrectomy, removal of the posterior cortical vitreous, and gas tamponade followed by face down posturing. Additional procedures comprised stripping of an early epiretinal membrane¹ and adjuvant therapy with autologous thrombocyte concentrate.² The rationale for surgical treatment was relief of tangential traction on the edges of the hole and reattachment of the retina by gas tamponade, as for idiopathic macular holes.⁸

It is, however, important to recognise that laser induced macular holes can resolve spontaneously. Internal limiting membrane changes induced by laser injuries are capable of spontaneous regression, as demonstrated by reports of significant macular pucker improving spontaneously.^{6,9} Reparative events within the neurosensory retina and RPE may also influence macular hole closure, comprising fibroglial and retinal pigment epithelial hyperplasia.¹⁰ Surgical intervention for laser induced macular holes should therefore not be considered before a reasonable period of observation.

Sources of funding: None
Proprietary or financial interests: None

DOUGLAS K NEWMAN
DECLAN W FLANAGAN

Department of Ophthalmology, Addenbrooke's Hospital,
Cambridge, UK

Correspondence to: Dr D K Newman, Department of Ophthalmology, Clinic 3 (Box 41), Addenbrooke's Hospital, Hills Road, Cambridge CB2 2QQ, UK

Accepted for publication 6 March 2000

- Ciulla TA, Topping TM. Surgical treatment of a macular hole secondary to accidental laser burn. *Arch Ophthalmol* 1997;115:929–30.
- Potthöfer S, Foerster MH. Vitrectomy and autologous thrombocyte adhesion of an accidental macular hole caused by Nd:YAG laser. *Br J Ophthalmol* 1997;81:803–4.
- Marshall J. Structural aspects of laser-induced damage and their functional implications. *Health Phys* 1989;56:617–24.
- Thach AB, Lopez PF, Snady-McCoy LC, et al. Accidental Nd:YAG laser injuries to the macula. *Am J Ophthalmol* 1995;119:767–73.
- Boldrey EE, Little HL, Flocks M, et al. Retinal injury due to industrial laser burns. *Ophthalmology* 1981;88:101–7.
- Goldberg MF, Young RS, Read J, et al. Macular hole caused by a 589-nanometer dye laser operating for 10 nanoseconds. *Retina* 1983;3:40–4.
- Kusaka S, Fujikado T, Ikeda T, et al. Spontaneous disappearance of traumatic macular holes in young patients. *Am J Ophthalmol* 1997;123:837–9.
- Kelly NE, Wendel RT. Vitreous surgery for idiopathic macular holes. *Arch Ophthalmol* 1991;109:654–9.
- Modarres-Zadeh M, Parvaresh MM, Pourbabak S, et al. Accidental parafoveal laser burn from a standard military ruby range finder. *Retina* 1995;15:356–8.
- Guyer DR, Green WR, de Bustros S, et al. Histopathologic features of idiopathic macular holes and cysts. *Ophthalmology* 1990;97:1045–51.

Failure of transpupillary thermotherapy (TTT) for choroidal melanoma: two cases with histopathological correlation

EDITOR.—We are concerned about the widespread use of transpupillary thermotherapy (TTT). Two patients referred for evaluation after TTT failed to destroy their tumours underwent ophthalmic oncology evaluations, were diagnosed as having recurrent choroidal melanoma, and opted for enucleation as definitive treatment. Clinical history and examination revealed evidence of a TTT laser effect with partial chorioretinal attenuation and temporary reductions in tumour height. Histopathology revealed attenuation of the retina and choroid above viable appearing melanoma. Despite temporary reductions in tumour height, resistant and/or untreated choroidal melanoma at the deep margins grew, resulting in TTT failure.

CASE REPORTS

Case 1

A 47 year old man developed a small (8 × 7 × 1.9 mm) macular choroidal melanoma. Before TTT, the tumour's posterior margin was 2.25 mm from the foveola and the patient's visual acuity was 20/20 left eye (with metamorphopsia).

Three months after TTT, the apical tumour height decreased to 1.1 mm but the posterior margin remained elevated and was "heavily" retreated. Three months later a third TTT was administered, resulting in "no visible tumour". At 30 months a crescent of pigmentation was noted along the posterior margin of the TTT scar (Fig 1) and treated immediately with a fourth and ultimately with a fifth TTT (3 months later).

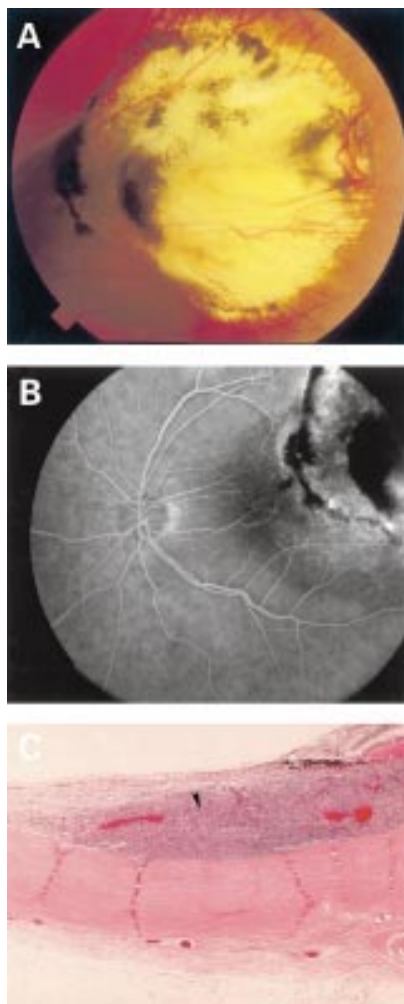


Figure 1 (A) Patient 1. A colour fundus photograph reveals a large chorioretinal scar with an arc of pigmented tumour along its posterior margin consistent with recurrent melanoma. Residual pigment can also be found within the treatment area. (B) Fluorescein angiography of the posterior TTT margin reveals mottled tumour fluorescence next to the treated margin before an area of arcuate fluorescein blockage as the tumour fans out posteriorly towards the optic nerve. (C) Histopathological evaluation revealed a layer of viable malignant melanoma (arrow) beneath laser attenuated retina (haematoxylin and eosin $\times 40$).

Three years after his initial TTT he presented to the New York Eye Cancer Centre with 20/200 vision left eye, and a marginal recurrence of his choroidal melanoma (Fig 1A). Fluorescein angiography revealed blood flow within the treated zone and recurrent tumour at the posterior margin (Fig 1B). Ultrasonography revealed a dome-shaped choroidal tumour with low internal reflectivity (2 mm in height). After a detailed discussion of observation, radiation, TTT, and enucleation he chose to undergo enucleation. Histopathology revealed viable appearing choroidal melanoma beneath laser attenuated retina (Fig 1C).

Case 2

A 73 year old woman with a (12 \times 10 \times 6.2 mm) choroidal melanoma, 20/63 vision, cataract, and glaucoma was given one session of TTT. "Ocular pain" and a "secondary membrane" over the tumour precluded further treatment. She sought intermittent evaluations with several physicians over 3.5 years. A

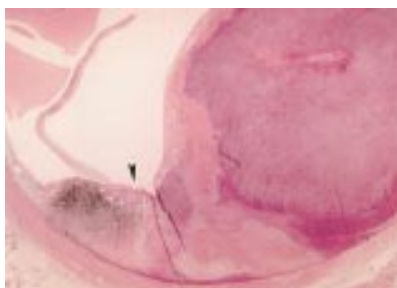


Figure 2 Patient 2. Histopathological evaluation revealed tumour necrosis in the path of TTT as evidenced by attenuated retina (arrow). Again, a basal layer of intact choroidal melanoma can be seen at the tumour base and within the zone of treatment (arrow). The tumour mass is largely recurrence into the temporal quadrants.

series of ultrasound tumour height measurements were extrapolated from her records (6.2, TTT, 2.2, 3.4, 4.4, and 6.7)

She presented with a moderate afferent pupillary defect, a visual acuity of 20/250 (left eye), and a recurrent choroidal melanoma (6.7 mm in apical height). Histopathology again revealed a localised region of atrophic retina above a relatively fibrotic and pigmented tumour. This deep margin contained viable epithelioid melanoma cells extending to the recurrent temporal mass (Fig 2).

COMMENT

Transpupillary thermotherapy involves aiming a large (for example, 2.5 mm) spot size diode laser at posterior choroidal melanomas to completely cover the tumour surface and a circumferential (1 mm) safety margin. Power is increased until the 1 minute applications produce a light, white retinal "burn." TTT is not consistent with clinical hyperthermia where tumour temperatures are measured and radiation is typically added.²

Korver and colleagues introduced the use of TTT for choroidal melanoma.³ Their histopathological evaluations demonstrated variable depths of TTT penetration.³ In order to address the possibility of untreated deep tumour, Oosterhuis advocates a "sandwich technique" adding plaque radiotherapy to treat the tumour's base.³ Shields and Capone have advocated the use of TTT alone.^{6,7}

Clinical and histopathological studies suggest that laser (xenon, argon, or krypton) photocoagulation of choroidal melanoma is relatively ineffective.^{8,9} Laser treated melanomas typically demonstrate residual tumour which can grow over time. Radiation therapy also results in a tumour residua, but irradiated melanoma is considered sterilised (incapable of growth or metastasis).¹⁰ Surgeons also define successful TTT as cessation of growth or shrinkage, but like other forms of laser photocoagulation, there is no reason to believe that residual heat treated tumour has been sterilised.¹

Radiation has offered mean 5 year local control rates of 92.8%.¹⁰ TTT has thus far demonstrated similar control rates of 93%, but only with a mean 16 months' follow up after treatment of small melanomas, and 94% after a mean 14 months (medium sized tumours).^{6,7}

The ability of TTT to preserve vision has been poor. Because of aiming considerations, the perfect tumours for TTT are small, posterior, and melanotic. Case selection makes them relatively close to the optic nerve and/or fovea. This may be why TTT has resulted in a loss of vision in 43% of patients with small

melanomas and 41% in Shields' series.^{6,7} TTT induced scotomas are typical. Traction maculopathy, haemorrhages, and optic nerve damage are common. Though these findings can also occur after ophthalmic radiotherapy they are rarely immediate.¹⁰

We present two cases where TTT resulted in inadequate treatment, leaving the ominous finding of malignant tissue at the tumours base adjacent to scleral emissary vessels. We feel that TTT should be scientifically compared with standard treatments before it is presented as standard therapy.

Supported (in part) by The EyeCare Foundation, Inc, New York City (<http://www.eyecarefoundation.org>).

PAUL T FINGER
ANDREW C LIPKA
JEFFREY L LIPKOWITZ
MARK JOFE

STEVEN A MCCORMICK

The New York Eye Cancer Centre, New York City, The Departments of Ophthalmology and Laboratory Medicine, The New York Eye and Ear Infirmary, New York City, and The Department of Ophthalmology, The New York University School of Medicine, New York City, New York, USA

Correspondence to: Paul T Finger, MD, FACS, Director, The New York Eye Cancer Centre, 5th Floor, 115 East 61st Street, New York, NY 10021, USA

pfinger@eyecancer.com

Accepted for publication 13 April 2000

- Hall E. *Hyperthermia. Radiobiology for the radiologist*. 4th ed. 16 Vol. Philadelphia: JB Lippincott, 1994:257-88.
- Finger PT. Microwave thermoradiotherapy for uveal melanoma: results of a 10-year study. *Ophthalmology* 1997;104:1794-803.
- Journee-de Korver JG, Oosterhuis JA, Kakebeke-Kemme HM, et al. Transpupillary thermotherapy (TTT) by infrared irradiation of choroidal melanoma. *Doc Ophthalmol* 1992;82:185-91.
- Journee-de Korver JG, Oosterhuis JA, de Wolff-Rouendaal D, et al. Histopathological findings in human choroidal melanomas after transpupillary thermotherapy. *Br J Ophthalmol* 1997;81:234-9.
- Oosterhuis JA, Journee-de Korver HG, Keunen JE. Transpupillary thermotherapy: results in 50 patients with choroidal melanoma (see comments). *Arch Ophthalmol* 1998;116:157-62.
- Shields CL, Shields JA, Cater J, et al. Transpupillary thermotherapy for choroidal melanoma: tumor control and visual results in 100 consecutive cases. *Ophthalmology* 1998;105:581-90.
- Godfrey DG, Waldron RG, Capone A. Transpupillary thermotherapy for small choroidal melanoma. *Am J Ophthalmol* 1999;128:88-93.
- Brancato R, Menchini U, Pece A. Enucleation after argon laser photocoagulation for choroidal melanoma. *Ann Ophthalmol* 1988;20:296-8.
- Cernak A. Treatment of choroidal melanoma using photocoagulation. *Cesk Ophthalmol* 1991;47:363-6.
- Finger PT. Radiation therapy for choroidal melanoma. *Surv Ophthalmol* 1997;42:215-32.

Unusual presentation of diffuse melanoma of the iris

EDITOR.—Diffuse melanoma of the iris is an unusual variant of anterior uveal melanoma. It is usually characterised by diffuse, circumferential neoplastic involvement of the iris, chamber angle and, sometimes, ciliary body.² Patients usually present with ipsilateral raised intraocular pressure and heterochromia. There is often a delay in both the diagnosis and treatment of these tumours owing to their atypical presentation.² A tendency for ciliary body involvement and extraocular extension may account for their generally poor prognosis.

We present an unusual case with diffuse melanoma of the iris diagnosed by high frequency ultrasonography and fine needle aspiration biopsy.

CASE REPORT

A 79 year old man with unilateral glaucoma on the left eye developed pain, red eye, and heterochromia during his follow up. He had an ocular history of glaucoma surgery (Baerveldt implant) 1 year before presentation, and recent cataract surgery on the left eye.

Because of uncontrolled glaucoma, heterochromia, and diffuse yellow-white deposits throughout the anterior chamber, cornea, with vitreous cells on left eye, he was referred for ophthalmic oncology evaluation. The examination of right eye was found to be normal. On examination of the left eye, he was noted to have a best corrected visual acuity of 20/250 and intraocular pressures of 46 mm Hg. Slit lamp examination of the left eye revealed yellow-white keratic precipitates on the cornea and 4+ cells in the anterior chamber (Fig 1A and B). The iris was significant for clumps of similarly coloured debris and neovascularisation (Fig 1A and B). Ophthalmoscopy revealed vitreous cells and the retina appeared normal. A transillumination defect (3 × 3 mm) was observed between 5 and 6 o'clock inferiorly in the pars plana.

High frequency ultrasonography revealed deposits on the corneal endothelium, diffuse iris thickening, and a nodular thickening on the inferior quadrant of the ciliary body (Fig 1C). The diagnosis of the diffuse melanoma of iris was made by transcorneal fine needle biopsy of the anterior segment debris.

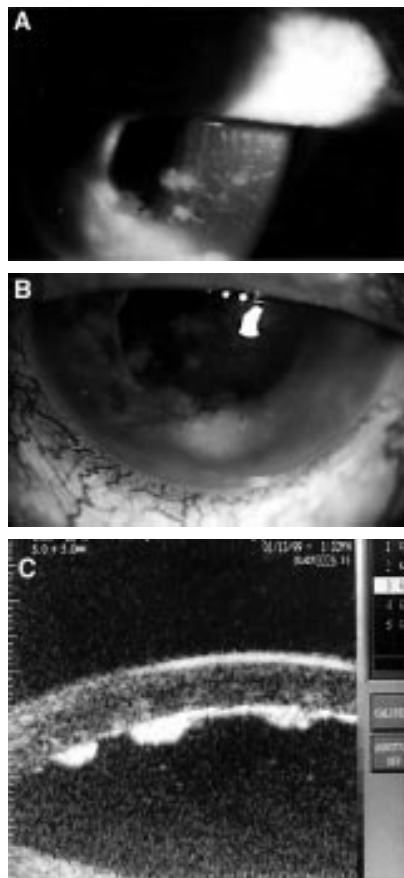


Figure 1 Slit lamp examination of the left eye revealed yellow-white keratic precipitates on the cornea, 4+ cells in the anterior chamber (A); clumps of similarly coloured debris on iris with neovascularisation (B). On high frequency ultrasonography, deposits on the corneal endothelium, diffuse iris thickening, and a nodular thickening on the inferior quadrants of the ciliary body were observed (C).

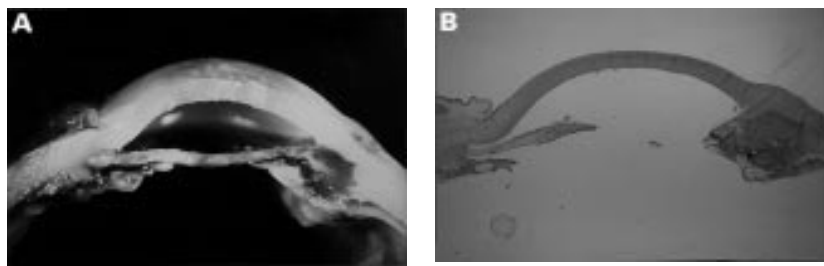


Figure 2 Gross photograph of the eye showing diffuse involvement of iris with epithelioid tumour cells and small, amelanotic malignant melanoma of the inferior ciliary body (A). Tumour cells involved the chamber angle (B) (haematoxylin and eosin, ×10).

After a negative metastatic survey, the patient underwent enucleation with 50 Gy of postoperative radiation therapy. Histopathological evaluation of the enucleated eye confirmed the tumour to be a malignant melanoma with a diffuse involvement of the iris stroma (Fig 2A and B). Cytology revealed epithelioid malignant melanoma cells. Special stains of the harvested material was S100 positive (Fig 3A and B).

COMMENT

Diffuse melanoma of the iris is a rare entity among anterior uveal tumours.¹ Classically, it

is described as involvement of anterior uveal tissues in a complete ring, but it is used for any melanoma involving more than 6 clock hours of anterior uvea circumferentially.² Jakobiec and associates reported that 13 of 183 (7%) patients with iris melanoma had diffuse melanoma; however, Jensen and associates reported 10 of 80 (12.5%) iris melanoma cases were diffuse melanoma.^{1,3}

The ipsilateral glaucoma and heterochromia are the cardinal signs in this disease.⁴ The mechanism of glaucoma includes pigment dispersion, tumour invasion of the angle, angle closure, and iris and angle neovascularisation.⁴

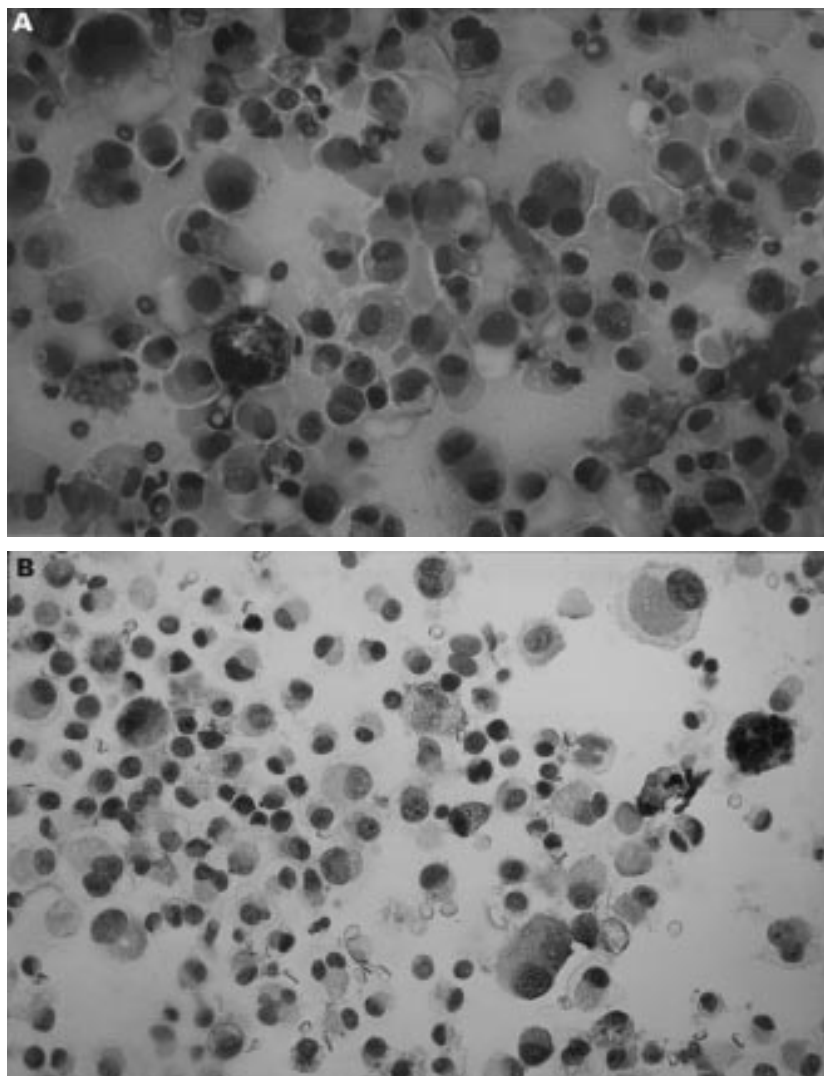


Figure 3 Large epithelioid, discohesive, pleomorphic cells with granular cytoplasm and oval nuclei. Some cells contain melanin and have prominent nucleoli (A) (haematoxylin and eosin, ×100). Positive dark staining characteristic of neural crest derived cells is noted in most of the cells (B) (S-100 stain, ×100).

The clinicians often pay more attention to the secondary glaucoma than to the heterochromia. So, there is usually a delay in diagnosis and often a history of previous glaucoma surgery in these patients.

Conventional B scan ultrasonography is not so helpful for anterior uveal tumours. Ultrasound biomicroscopy offers a better diagnostic method to evaluate the lesions of iris, chamber angle, and ciliary body.⁵ Transillumination is another useful test to assess the ciliary body involvement, although transillumination defects have been variably reported, ranging from 4% to 87% of patients with diffuse uveal melanoma.⁶ The other diagnostic tool is fine needle aspiration biopsy with an accuracy rate of 90% in diagnosis and a low risk of tumour seeding.⁴

Although our patient had a history of glaucoma and heterochromia, this case had an atypical presentation with diffuse tumour seeding in the anterior chamber and vitreous (a clinical picture similar to endophthalmitis). Clearly ultrasonographic biomicroscopy and fine needle aspiration biopsy were invaluable for the diagnosis and management of this case.

Enucleation is commonly performed for diffuse melanomas. But, despite surgery the prognosis for survival of these patients is typically worse than patients with nodular uveal melanomas of equivalent thickness. This may be due to the greater likelihood of epithelioid cells, a higher rate of extrascleral extension, and/or their delays in diagnosis.⁷ Our patient is still alive with no evidence of metastasis and recurrence after 1 year.

HAKAN DEMIRCI
PAUL T FINGER

New York Ophthalmic Oncology Center, New York City
and the Department of Ophthalmology, New York Eye
and Ear Infirmary, New York, USA

RUBINA COCKER
STEVEN A MCCORMICK

Department of Pathology and Laboratory Medicine,
New York Eye and Ear Infirmary, New York, USA

Correspondence to: Paul T Finger, The New York
Eye Cancer Centre, 5th Floor, 115 East 61st Street,
New York, NY10021, USA

pfinger@eyecancer.com

Accepted for publication 13 April 2000

- Jakobiec FA, Silbert G. Are most iris melanomas really nevi. *Arch Ophthalmol* 1981;99:2117-32.
- Lee V, Cree IA, Hungerford JL. Ring melanoma—a rare cause of refractory glaucoma. *Br J Ophthalmol* 1999;83:194-8.
- Jensen OA. Malignant melanoma of the iris. A 25-year analysis of Danish cases. *Eur J Ophthalmol* 1993;3:181-8.
- Char DH, Crawford BJ, Gonzales J, et al. Iris melanoma with increased intraocular pressure. Differentiation of focal solitary tumors from diffuse or multiple tumors. *Arch Ophthalmol* 1989;107:548-51.
- Katz NR, Finger PT, McCormick SA, et al. Ultrasound biomicroscopy in the management of malignant melanoma of the iris. *Arch Ophthalmol* 1995;113:1462-3.
- Font RL, Spaulding AG, Zimmerman LE. Diffuse malignant melanoma of the uveal tract. A clinicopathologic report of 54 cases. *Trans Am Acad Ophthalmol Otolaryngol* 1968;72:877.

Promoter mutations of myocilin gene in Japanese patients with open angle glaucoma including normal tension glaucoma

EDITOR.—Mutations causing primary open angle glaucoma (POAG) have been identified in the chromosome 1 open angle glaucoma gene (GLC1A), which encodes a 57 kD protein known as myocilin (MYOC).¹⁻⁴ A number of mutations of the MYOC gene that are associated with glaucoma have been reported in

Table 1 Mutations of the promoter region

Mutation		Patient group No (%)	Control group No (%)	
-83 G→A (GT)n	n=13/13	9/30 (30)	14/36 (39)	
		13/30 (43)	22/33 (67)	
		13/15	7/33 (21)	
		15/15	4/30 (13)	
		11/11	0/30 (0)	
-153 T→C	1st survey	5/30 (17)	3*/38 (7.9)	
	2nd survey	11/53 (21)	3/63 (4.8)	(p<0.01)
			(age matched)	
	sum	16/83 (19)	6/101 (5.9)	(p<0.01)

The maximal intraocular pressure in these patients was 35 mm Hg, and most intraocular pressures were between 15 and 30 mm Hg.

*Three controls with the -153 C mutation later underwent ophthalmological examination of the optic disc and glaucomatous visual field defects. Two had a diagnosis of evident glaucoma and the third (a 22 year old man) was a glaucoma suspect.

different ethnic groups.¹⁻³ The mutations occur in 2-4% of POAG patients, but mostly in the exons. Although five different such alleles have been identified among Japanese patients,^{5,6} they are rare and a promoter region has not received much attention. We conducted a study using the same methods^{1,2} in Japanese patients with POAG and normal tension glaucoma (NTG) who had a family history of the disease in first and second degree relatives (n=30, 53), and in control subjects (n=38, 63) who had no ophthalmological conditions.

The results of this screening for the Japanese patients with POAG disclosed no exon mutations. The introns at the exon/intron boundaries had no abnormalities. However, three abnormalities were found in the promoter region (Table 1). One was a polymorphism at -83 G→A (83 base pairs upstream from initiation codon), which had been reported previously in Westerners,^{1-3,5,7} and another was a new mutation of (GT) repeats at -339 to -314, which also seemed polymorphic. The last promoter mutation (-153 T→C) is newly observed, and was found in a substantial number of our patients. However, no significant difference was found in the first survey (Table 1).

The -153 T→C creates tandem repeats of [CAGCCCCAC]. The CACCC motif, transcription regulator in β -like globin genes, bridges the two repeats [5'CAGCCCCAC]C[CAGCC(T→C)CAC]. Thus, this mutation seems to affect the expression of the myocilin gene. These results caused us to extend the examination in a second survey for the -153 T→C to other patients with POAG and NTG (n=53) and to new age matched control subjects (n=63). The result showed a significant difference between the patients and the control group (p<0.01, Fisher's exact probability). The age matched second survey provided results similar to those of the first survey. Even when we combine the results of both, the difference was also evident (Table 1). No homozygosity for the -153 C was detected.

Therefore, the -153 C mutation is very likely to be disease related. The mutation comprises nearly 20% of patients with POAG and NTG, but only 4.8% of the control subjects. An incidence as high as this has not been observed in any POAG related mutant reported previously.^{1-3,5-8} In fact, three control subjects carrying the -153C in the original survey were examined ophthalmologically, and to our surprise, two of them had POAG. These carriers in the control group, despite the absence of ophthalmological complaints, may have an insidious development of glaucoma.

Our preliminary study suggested that the promoter activity is different between the -153 T and C alleles, and it depends on the linkage with the number of GT dinucleotide repeats, about 160 nucleotides upstream from this mutation.

This -153 C allele may be found exclusively in Japanese patients and may be the major mutation associated with POAG and NTG in Japanese people. Clinical phenotypes differ among ethnic groups,⁸⁻¹⁰ which may be explained genetically.

The patent licence number of the glaucoma detection kit is 500223497.

This work was supported by a general research programme (C2-10671645) from the Ministry of Education, Science and Culture, Japan (Dr Suzuki) and New Frontier Project 2000, Japan (Dr Suzuki). We wish to thank Lynda Charters of Medical International for editing this manuscript.

RYO SUZUKI

Department of Ophthalmology, Glaucoma Service,
Yamaguchi University School of Medicine,
755-8505, Japan

YUKIO HATTORI
KOZUE OKANO

Yamaguchi University School of Health Sciences

Correspondence to: Dr Ryo Suzuki

suzuki@po.cc.yamaguchi-u.ac.jp

Accepted for publication 13 April 2000

- Alward WLM, Fingert JH, Coote MA, et al. Clinical features associated with mutations in the chromosome 1 open-angle glaucoma gene (GLC1A). *N Engl J Med* 1998;338:1022-7.
- Stone EM, Fingert JH, Alward WLM, et al. Identification of a gene that causes primary open angle glaucoma. *Science* 1997;275:668-70.
- Rozsa FW, Shimizu S, Lichiter PR, et al. GLC1A mutations point to regions of potential functional importance on the TIGR/MYOC protein. *Mol Vis* 1998;4:20.
- Kubota R, Kudoh J, Mashima Y, et al. Genomic organization of the human myocilin gene (MYOC) responsible for primary open angle glaucoma (GLC1A). *Biochem Biophys Res Commun* 1998;242:396-400.
- Fingert JH, Heon E, Liebmann JM, et al. Analysis of myocilin mutation in 1703 glaucoma patients from five different populations. *Hum Mol Genet* 1999;8:899-905.
- Suzuki Y, Shirato S, Taniguchi F, et al. Mutations in the TIGR gene in familial primary open-angle glaucoma in Japan. *Am J Hum Genet* 1997;61:1202-4.
- Polansky JR, Nguyen TD. The TIGR gene, pathogenic mechanisms, and other recent advances in glaucoma genetics. *Curr Opin Ophthalmol* 1998;9:15-23.
- Wolfs RCW, Klaver CC, Ramrattan RS, et al. Genetic risk of primary open-angle glaucoma. Population-based familial aggregation study. *Arch Ophthalmol* 1998;116:1640-5.
- Miller R. Genetics of glaucoma and family studies. *Trans Ophthalmol Soc UK* 1978;98:290-2.
- Poinosawmy D, Nagasubramanian S, Warmald R, et al. Glaucoma and race. *Lancet* 1989;1:1134.

Keratoconus associated with chromosome 13 ring abnormality

EDITOR.—We wish to report a patient with a ring abnormality of chromosome 13 who developed keratoconus. As far as we are aware such an association has not previously been reported. This case may provide some further insight into the presumed genetic basis of keratoconus.

CASE REPORT

A 19 year old woman was referred by her optometrist because of impaired distance vision present for several months which could not be satisfactorily corrected with spectacles. There was no history of familial ocular problems. The patient did not suffer from atopy.

Unaided visions were: right 6/9 part, left 6/24. The optimal spectacle correction and visual acuities were: right +1.00/−1.00 × 90 = 6/7.5, left +1.50/−3.00 × 110 = 6/18. With a pinhole the visual acuities improved to: right 6/5 part, left 6/6. The retinoscopy reflex in the left eye showed an “oil droplet” appearance with distortions, and slit lamp assessment of this eye revealed a definite corneal cone. Conventional keratometry measurements were: right 7.08 mm × 123/7.05 mm × 33 (47.62/47.87D), left 6.99 mm × 150/6.67 mm × 60 (48.25/50.62D). Videokeratography (TMS) demonstrated corneal topographies typical of keratoconus, more marked on the left side, with the cone apices inferior to the corneal centre. The condition was managed by the fitting of rigid gas permeable contact lenses.

The patient was born at full term weighing 2.2 kg. There was delay in achieving her early childhood developmental milestones and, as a result, chromosomal investigations were performed at the age of 8 years. These revealed a chromosome 13 ring abnormality (46,XX,r(13)). She showed mild learning difficulties, particularly of her reading and writing skills. She has, however, remained within mainstream education. During childhood she suffered from persistent middle ear infections and required a hearing aid. Puberty was delayed with menarche occurring at age 15 years 2 months. At the age of 19 years, she has a height on the 9th centile, weight on the 75th centile, and occipitofrontal circumference on the 10th centile. She has mild dysmorphic features of epicanthic folds, depressed nasal bridge, and overfolded helices. She also has underdevelopment of the right breast and a hypoplastic toe nail on the right fifth toe.

Further cytogenetic analysis in 1999 demonstrated that the long arm subtelomeres are absent from the ring. The karyotype is, therefore, 46,XX,r(13),(p11q34).ish r(13)(p11q34)(85A10-).

COMMENT

A number of cases of ring 13 have been reported with the same breakpoints of p11 and q34.¹ While microcephaly, mild dysmorphism, mental retardation, and foot anomalies have been described, there have been no reports of an association with keratoconus.

The aetiology of keratoconus remains unclear. The thinning of the corneal stroma and the resulting ectasia are presumed to be due to an abnormality of the corneal collagen or extracellular matrix. Although many cases occur sporadically, twin and family studies suggest that there is, at least in part, a genetic basis to the condition.² Candidate genes

include those that code for the components of collagen. In the case described above, the ring (13) has occurred following a deletion of the end of the long (q) arm of the chromosome. The association with keratoconus raises the possibility that a deleted gene may have a role in the maintenance of corneal integrity. It is interesting that the genes COL4A1 and COL4A2 which code for the $\alpha 1$ and $\alpha 2$ chains, respectively, of collagen IV are located on the long arm of chromosome 13 (13q33-q34).³

C J HEAVEN

Royal Albert Edward Infirmary, Wigan WN1 2NN

F LALLOO

E MCHALE

St Mary's Hospital, Manchester M13 0FH, UK

Correspondence to: Mr Heaven

Accepted for publication 18 April 2000

- 1 Brandt CA, Hertz JM, Petersen MB, V *et al*. Ring chromosome 13: lack of distinct syndromes based on different breakpoints on 13q. *J Med Genet* 1992;29:704–8.
- 2 Rabinowitz YS. Keratoconus (major review). *Surv Ophthalmol* 1998;42:297–319.
- 3 Boyd CD, Toth-Fejel S, Gadi IK, *et al*. The genes coding for human pro alpha-1(IV) collagen are both located at the end of the long arm of chromosome 13. *Am J Hum Genet* 1988;42:309–14.

Vitamin A deficiency in coeliac disease

EDITOR.—Vitamin A deficiency is a major cause of ocular morbidity especially in underdeveloped countries. In the West sporadic cases have been reported usually associated with malabsorption syndromes, small intestinal bypass surgery, or abnormal metabolism. We report a case of an ophthalmological diagnosis of vitamin A deficiency secondary to coeliac disease. To our knowledge keratomalacia in association with coeliac disease has not been described previously.

CASE REPORT

A 64 year old man presented with a 6 week history of sudden progressive redness of his right eye associated with blurring of vision. His left eye was asymptomatic and he had no ocular history of note. He had a history of diet controlled coeliac disease proved by jejunal biopsy. Several weeks earlier he had complained of persistent diarrhoea despite adherence to his gluten-free diet.

On examination visual acuity was counting fingers on the right and 6/6 on the left. The left eye was normal except for multiple fluorescein staining scattered fine superficial punctate erosions. The right eye was diffusely injected and the cornea showed filamentary changes with multiple underlying punctate staining epithelial defects. There were no other pathological features.

A provisional diagnosis of filamentary keratitis was made and he was treated with topical acetylcysteine to the right eye and topical lubricants to the left eye. Two weeks later he reported a marked deterioration in symptoms. Visual acuity remained unchanged. Corneal examination revealed a large central full thickness epithelial defect. Regular topical lubricants were applied and a botulinum toxin injection was administered. Full physical examination at this stage revealed a thin man but no other relevant findings.

After 1 week there was complete failure of re-epithelialisation (Fig 1). The suspicion of a keratomalacia secondary to vitamin A deficiency was raised and an intramuscular injection of 100 000 units of vitamin A was immediately administered. Subsequent serum

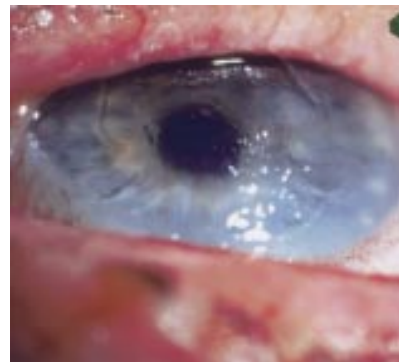


Figure 1 Photograph of right cornea showing significant epithelial erosion ($\times 15$ magnification).

vitamin A levels were 13 (normal 330–1100). Six days later there was a dramatic symptomatic improvement. Visual acuity had improved to 6/18. The cornea was almost completely healed with only a few areas of superficial epithelial deficit remaining. The patient was referred back to the gastroenterologists who investigated his continuing malabsorptive symptoms and administered standard dietary supplementation including regular vitamin A injections.

Ophthalmology review occurred 1 month later when full corneal healing was noted. The visual acuity had improved to 6/12 and since then he has had no further ocular problems.

COMMENT

Vitamin A deficiency and xerophthalmia are generally considered to be problems of developing countries. Vitamin A (retinol) is obtained from the diet and is required in the cornea for maintenance of epithelial surface integrity and immune competence. It is also required for normal retinal function.

Although dietary insufficiency is the leading cause of vitamin A deficiency in the developing world, liver disease and chronic malabsorption are the foremost aetiological factors in the West.¹ Xerophthalmia secondary to avitaminosis A has been described extensively in the literature related to a wide variety of disorders such as cystic fibrosis,² primary sclerosing cholangitis,³ primary biliary cirrhosis,³ gross dietary malnutrition associated with chronic alcoholism^{4,5} or autism,^{6,7} and iatrogenically after small bowel resections and jejunioileal bypass surgery.⁸ Treatment consists of remedying the underlying vitamin deficiency with supplementation via the oral or intramuscular route, each of which have been demonstrated to be equally efficacious.⁹

In our case we made the diagnosis of hypovitaminosis A from the corneal pathology and rapid healing was seen once vitamin A supplementation was instituted. Although rare, the ophthalmologist must be alert to the potential causes of severe vitamin A deficiency and consider this diagnosis in unexplained keratomalacia, since early intervention will significantly minimise morbidity and prevent long term sequelae.

AMAR ALWITRY

Department of Ophthalmology, Derbyshire Royal Infirmary, Derby, UK

Accepted for publication 18 April 2000

- 1 Sommer A. Vitamin A deficiency and xerophthalmia. *Arch Ophthalmol* 1990;108:343–4.
- 2 Logan Brooks H, Driebe WT, Schemmer GG. Xerophthalmia and cystic fibrosis. *Arch Ophthalmol* 1990;108:354–7

- 3 Watson NJ, Hutchinson CH, Atta HR. Vitamin A deficiency and xerophthalmia in the United Kingdom. *BMJ* 1995;310:1050-1.
- 4 Macsai MS, Agarwal S, Gamponia E. Bilateral corneal ulcers in primary vitamin A deficiency. *Cornea* 1998;17:227-9.
- 5 Reisin I, Reisin LH, Aviel E. Corneal melting in a chronic alcoholic contact lens wearer. *CLAO J* 1996;22:146-7.
- 6 Clark JH, Rhoden DK, Turner DS. Symptomatic vitamin A and D deficiencies in an eight-year-old with autism. *J Enteral Parent Nutr* 1993;17:284-6.
- 7 Cohen EJ. Vitamin A deficiency and xerophthalmia in an autistic child. *Arch Ophthalmol* 1998;116:392-3.
- 8 Tripathi RC, Tripathi BJ, Raja SC, et al. Iatrogenic ocular complications in patients after jejunoileal bypass surgery. *Int Surg* 1993;78:68-72.
- 9 Sommer A, Tarwotjo I, Djunaedi E, et al. Oral versus intramuscular vitamin A in the treatment of xerophthalmia. *Lancet* 1980;1:557-9.

Choroidal neovascular membrane presenting as a complication of pre-eclampsia in a patient with the antiphospholipid syndrome

EDITOR.—Pre-eclampsia is characterised by hypertension, proteinuria, and generalised body oedema, which occurs during the third trimester of pregnancy. Ophthalmological changes related to pre-eclampsia include involvement of retinal or choroidal vasculature, with the presence of cotton wool spots, haemorrhages and serous retinal detachment.¹ The antiphospholipid syndrome is characterised by the triad of arterial or venous thrombosis, recurrent abortions, and thrombocytopenia.

Choroidal neovascular membrane (CNV) is a complication which occurs in many ocular diseases including age related macular degeneration, myopic degeneration, and presumed ocular histoplasmosis syndrome (POHS). It occurs as a degenerative process (type I) or secondary to damage in the choriocapillaris-Bruch's membrane-retinal pigmented epithelium (RPE) complex (type II).

We report a case of choroidal neovascular membrane as a complication of pre-eclampsia and the antiphospholipid syndrome.

CASE REPORT

A 35 year old woman was referred for ophthalmological examination with distortion of vision in her left eye. She noticed this in her left eye vision 2 weeks before an episode of pre-eclampsia which led to a stillbirth at 26 weeks of pregnancy. One week before her ophthalmic presentation she was diagnosed as having the antiphospholipid syndrome, and treated with aspirin 75 mg a day.

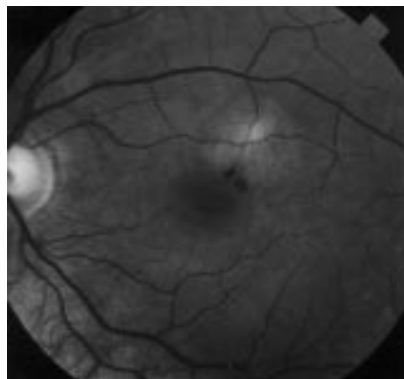


Figure 1 A one disc diameter lesion with subretinal fluid and haemorrhage in the macula region.

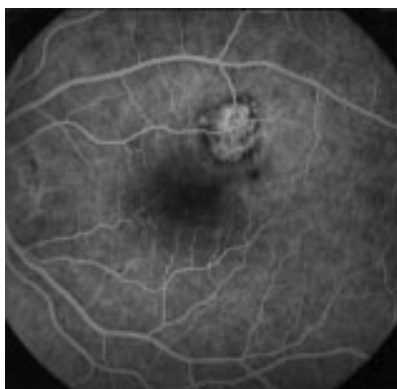

Figure 2 Late phase angiogram revealing a choroidal neovascular membrane.

She had corrected visual acuity of 6/5 in both eyes, with normal anterior segments and intraocular pressure of 20 mm Hg in the right eye and 22 mm Hg in the left. She had no changes in the right fundus and the left fundus revealed a subretinal lesion surrounded by fluid (Fig 1). The clinical appearance of the lesion was consistent with the diagnosis of choroidal neovascular membrane (CNV) which was confirmed by fluorescein angiography (Fig 2). The patient had good vision and no symptoms, therefore treatment was considered unnecessary.

One month later she returned and her left visual acuity had deteriorated to 6/6 and she also complained of distortion and diplopia. The decision to proceed with laser photocoagulation was made as the CNV had enlarged both clinically and on fluorescein angiography.

One month after treatment she was maintaining visual acuity of 6/5 on the right eye and 6/6 in the left eye. Her fundus examination disclose resolution of the subretinal membrane with a well demarcated scar in the left eye.

COMMENT

Ocular changes in pre-eclampsia are well known although they are unusual.¹ When they occur they are usually secondary to high blood pressure levels. The pathogenesis of the serous retinal detachment is not well understood. Hayreh *et al* suggested that serous retinal detachment in pre-eclampsia was caused by choroidal ischaemia secondary to accelerated hypertension.² The incidence of serous retinal detachment is approximately 1% for severe pre-eclampsia and 10% for eclamptic patients.³

Lesions in the RPE and outer retina have also been described. Saito and Tano⁴ demonstrated 47 eyes with RPE changes, which were mainly located in the macular region. These lesions corresponded to areas of delayed choroidal filling seen by fluorescein angiography. Some authors suggested that the macular region is more vulnerable to ischaemic disorders.

Changes in the blood viscosity, increased levels of vasoactive hormones, significant increases in blood volume and cardiac output may lead to damage of choriocapillaris and RPE. Rhee *et al* reported three cases in which CNV was diagnosed during pregnancy. The authors concluded that changes in the RPE during pregnancy could lead to choroidal neovascular membrane formation.⁵

The presence of antiphospholipid antibody is associated with choroidal disturbance in more than 30% of the patients with ocular changes.⁶ Our patient had two risk factors for choroidal ischaemia: pre-eclampsia and antiphospholipid antibodies. We believe that this association led to damage to choriocapillaris-Bruch's membrane-RPE complex and secondary choroidal neovascular membrane formation.

ANDRÉ L L CURI
ANDREW JACKS
CARLOS PAVESIO
Moorfields Eye Hospital

Correspondence to: Carlos Pavesio, Moorfields Eye Hospital, City Road, London EC1V 2PD
Accepted for publication 18 April 2000

- 1 Jaffe G, Schatz H. Ocular manifestation of preeclampsia. *Am J Ophthalmol* 1987;103:309-15.
- 2 Hayreh SS, Servais GE, Virdi PS. Fundus lesions in malignant hypertension. *Ophthalmology* 1986;93:1383-400.
- 3 Sunness JP. Pregnancy and retinal disease. In: Ryan SJ, ed. *Retina*. Vol 2. St Louis: CV Mosby, 1994:1393-403.
- 4 Saito Y, Tano Y. Retinal pigment epithelial lesions associated with choroidal ischemia in preeclampsia. *Retina* 1998;18:103-7.
- 5 Rhee P, Dev S, Mieler W. The development of choroidal neovascularization in pregnancy. *Retina* 1999;19:520-4.
- 6 Leo-Kottler B, Klein R, Berg PA, et al. Ocular symptoms in association with antiphospholipid antibodies. *Graefes Arch Clin Exp Ophthalmol* 1998;236:658-68.

Usefulness of three dimensional ultrasonography for invisible fundus

EDITOR.—We describe the new technology of three dimensional ultrasonic imaging^{1,2} to evaluate invisible fundus. There were two previous reports on clinical applications of three dimensional ultrasonography.^{3,4} However, these reports solely described the results of three dimensional ultrasonography to evaluate the extension of a choroidal melanoma. We report here on the first clinical application of three dimensional ultrasonography for invisible fundus.

CASE REPORT

In 1990, a 44 year old man, diagnosed with Behçet's disease was referred to our hospital for a cataract. A phacoemulsification operation was performed for the cataract in the right eye, which resulted in a corrected visual acuity of 20/20. However, he developed severe

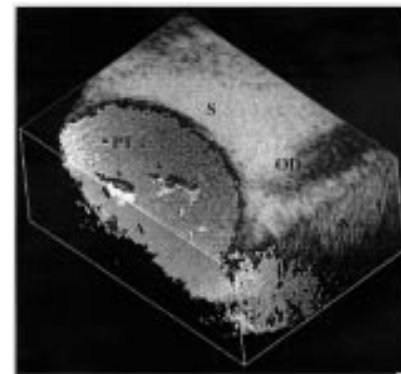


Figure 1 By observing from superior side, we could diagnose the absence of adhesion of the proliferative tissue to the retina. S = superior side, N = nasal side, A = anterior side; OD = optic disc, PT = proliferative tissue.




Figure 2 By observing from the nasal side, we could also diagnose the absence of adhesion of the proliferative tissue to the retina. S = superior side, N = nasal side, A = anterior side, PT = proliferative tissue.

postoperative inflammation. Elschning's pearl type emerged 6 months after cataract surgery, requiring posterior capsulotomy by YAG laser. In 1994, band keratopathy appeared and progressed gradually as a result of chronic uveitis of Behçet's disease. By November 1999, although his corrected visual acuity was still 10/20, ophthalmoscopic evaluation of the vitreous body and the fundus became impossible because of band keratopathy and severe after cataract. Because of the chronic uveitis, this patient could not receive a penetrating keratoplasty operation or excimer laser treatment for band keratopathy. Thus, three dimensional ultrasonography was performed using a 3D i-Scan ultrasonography system^{1,2} (Ophthalmic Technologies Inc, Downsview, Ontario, Canada) to measure the degree of vitreous opacification and to detect the presence of proliferative tissues in the vitreous body. As shown in Figures 1 and 2, we could diagnose the absence of adhesion of the proliferative tissue to the retina by observing from both superior side and nasal side. Because this examination excluded the possibility of retinal traction by proliferative tissues and retinal detachment, only periodic check ups have been conducted.

COMMENT

Two dimensional ultrasonography has traditionally been used to examine retinal or vitreous diseases with invisible fundus. Three dimensional ultrasonography has an advantage over two dimensional ultrasonography in that cross sections of the eye can be observed and the size of the space occupied by the lesion can be measured. Two dimensional ultrasonography, however, is superior to three dimensional ultrasonography for observing the dynamic changes of the membranous tissue associated with eye movement. We report here of a case in which two dimensional ultrasonography could not detect the adhesion of the proliferative tissue to the retina. This case was successfully examined by three dimensional ultrasonography. By observing many cross sections, we could diagnose the absence of adhesion of the proliferative tissue to the retina. Three dimensional ultrasonography was essential in determining the therapeutic approach for this patient. Further improvement of the technique using three dimensional ultrasonography may

expand the possible application of this technique to patients with other invisible fundus as well.

KAZUKO ENDO

Division of Ophthalmology, Tokyo University Branch Hospital, Tokyo, Japan

SATOSHI KATO

HARUMI FUKUSHIMA

KENJI INOUE

JIRO NUMAGA

HIDETOSHI KAWASHIMA

Division of Ophthalmology, Tokyo University Branch Hospital, Tokyo, Japan

Correspondence to: Satoshi Kato, MD, Division of Ophthalmology, Tokyo University Branch Hospital, 3-28-6 Mejirodai, Bunkyo-ku Tokyo, 112-8688 Japan
katou-s@ka2.so-net.ne.jp

Accepted for publication 18 April 2000

- 1 Cusumaro A, Coleman DJ, Silverman RH, *et al.* Three-dimensional ultrasonography imaging. *Ophthalmology* 1998;105:300-6.
- 2 Coleman DJ, Silverman RH, Daly SM, *et al.* Advances in ophthalmic ultrasound. *Radiol Clin N Am* 1998;36:1073-82.
- 3 Finger RT, Romero JM, Rosen RB, *et al.* Three-dimensional ultrasonography of choroidal melanoma. *Arch Ophthalmol* 1998;116:305-12.
- 4 Romero JM, Finger PT, Iezzi R, *et al.* Three-dimensional ultrasonography of choroidal melanoma: extrascleral extension. *Am J Ophthalmol* 1998;126:842-4.

Late complications after pterygium excision with high dose mitomycin C instillation

EDITOR,—To prevent recurrence of pterygia after excision, instillation of 0.04% mitomycin C has been used in Japan and northern America. However, early (less than 14 months) development of serious complications including scleral ulceration has been reported.¹⁻³ Fujitani *et al* have reported that corneal perforation developed 33 months after therapy. In the present study we report on late complications of mitomycin C treatment.

CASE REPORT

Four patients were included in this study (Table 1). All patients underwent pterygium excision and postoperative topical instillation of 0.04% mitomycin C four times a day for 2-3 weeks. The patients complained of ocular pain or irritation 18-25 years after treatment. Scleral ulceration with calcified plaque was found. After plaques were removed, uveal tissue bulged, and scleral patch grafts were successfully performed.

Table 1 Characteristics of patients

Characteristics	Patient			
	1	2	3	4
Sex	F	M	F	M
Eye	R	L	L	L
Age at pterygium excision (years)	60	50	53	40
Mitomycin C, 0.04%	+	+	+	+
four times a day duration (weeks)	2	3	2	3
Age at ocular irritation or pain (years)	78	68	77	65
Duration between mitomycin C and complaint (years)	18	18	24	25
Visual acuity at complaint	20/20	20/25	20/200	20/20
Scleral ulceration	+	+	+	+
Calcified plaque	+	+	+	+
Bacterial culture	-	-	-	-
Rheumatoid factor	-	-	-	-
Bulging uveal tissue after removal of plaque	+	+	+	+
Scleral patch graft	+	+	+	+
Further therapy			PE	
Follow up (years)	5	1	0.5	0.5
Visual acuity at last visit	20/20	20/25	20/20	20/20
Good outcome	+	+	+	+

+ = yes; - = negative; PE = phacoemulsification of cataract and intraocular lens implantation.

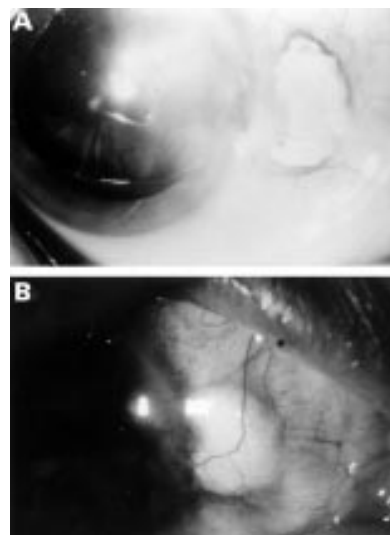


Figure 1 Case 1. Preoperatively, a rough surfaced hard plaque is seen at the nasal side of the right eye. The conjunctival epithelium is defective, and the sclera is thin at the site of the plaque (A). Postoperatively, the conjunctiva covers the graft in the right eye (B).

Case 1

A 78 year old woman complained of ocular irritation in the right eye in January 1995. The patient had undergone excision of pterygium in the right eye, and topical instillation of 0.04% mitomycin C four times a day for 2 weeks was administered in 1977 at another eye clinic. Our examination disclosed a visual acuity of right eye 20/20 with correction. Her intraocular pressures were 12 mm Hg in both eyes. A rough surfaced whitish hard plaque, 6 × 4 mm, was seen at the nasal side of the right eye (Fig 1A). The conjunctival epithelium was defective and the sclera was thin at the site of the plaque. Wheel-like lenticular opacities were seen bilaterally. Both eyes appeared normal otherwise. Bacterial culture from a scraping sample of the plaque was negative. Laboratory test results including rheumatoid factor were negative or within normal range. On 2 February 1995 the patient underwent excision of the plaque. After the plaque (which was firmly adherent to the underlying sclera) was excised the uveal tissue bulged. A patch graft, 7 × 5 mm, of full thickness sclera, was obtained from an eyebank eye and preserved in 99% ethanol at -20°C

rinsed in 0.9% NaCl solution just before use, and secured with 10-0 nylon sutures. Conjunctiva was pulled down over the graft and was sutured with 8-0 polyglactin. The removed plaque stained with alizarin red, suggesting calcification. Thereafter, the patient had no complaints of irritation. Five years later the patient had good visual acuity in both eyes. The scleral graft was covered with conjunctiva in the right eye (Fig 1B).

COMMENT

In our patients, ocular irritation, or pain associated with scleral ulceration with calcified plaque occurred more than 10 years after treatment. To our knowledge, calcified plaque development after simple excision of pterygium is rare. Scleral ulceration with calcified plaque in our patients was quite similar to that reported by Fujitani *et al.*⁴ It is possible that scleral lesions in our patients may be second-

ary to the topical use of 0.04% mitomycin C. To avoid complications, mitomycin C at a lower concentration should be applied for a shorter period of time, as previously described.⁵ Recently, mitomycin C has been used as adjunct in trabeculectomy. Eyes treated with mitomycin should be carefully observed for longer than 20 years. We believed that scleral ulceration with calcified plaque following topical mitomycin C instillation could be treated with scleral patch grafting.

SEIJI HAYASAKA
YOSHIO IWASA
YASUNORI NAGAKI
CHI HARU KADOI
MASAYUKI MATSUMOTO
YORIKO HAYASAKA

Department of Ophthalmology, Toyama Medical and
Pharmaceutical University, Toyama, Japan

Correspondence to: Dr Seiji Hayasaka, Department of Ophthalmology, Toyama Medical and Pharmaceutical University, 2630 Sugitani, Toyama, 930-0194 Japan

ophthal@ms.toyama-mpu.ac.jp

Accepted for publication 18 April 2000

- 1 Yamanouchi U, Takaku I, Tsuda N, *et al.* Scleromalacia presumably due to mitomycin C instillation after pterygium excision. *Jpn J Clin Ophthalmol (Rigan)* 1979;33:139-44.
- 2 Dunn JP, Seamone CD, Ostler HB, *et al.* Development of scleral ulceration and calcification after pterygium excision and mitomycin therapy. *Am J Ophthalmol* 1991;112:343-4.
- 3 Rubinfeld RS, Pfister RS, Stein RM, *et al.* Serious complications of topical mitomycin C after pterygium surgery. *Ophthalmology* 1992;99:1647-54.
- 4 Fujitani A, Hayasaka S, Shibuya Y, *et al.* Corneal scleral ulceration and corneal perforation after pterygium excision and topical mitomycin C therapy. *Ophthalmologica* 1993;207:162-4.
- 5 Hayasaka S, Noda S, Yamamoto Y, *et al.* Postoperative instillation of low-dose mitomycin C in the treatment of primary pterygia. *Am J Ophthalmol* 1988;106:715-18.

Contributors please note:

Communications from **all countries except the UK and Republic of Ireland** should be sent to Professor C Hoyt, Editor, *British Journal of Ophthalmology*, University of California, Department of Ophthalmology, 10 Kirkham Street, K 301, San Francisco, CA 94143-0730, USA (tel: 001 415 502-6871; fax: 001 415 514-1521).

Manuscripts from the **UK and the Republic of Ireland** should be sent to Professor Andrew Dick, UK Editor, *British Journal of Ophthalmology*, Division of Ophthalmology, University of Bristol, Lower Maudlin Street, Bristol BS1 2LX (tel: +44 (0) 0117 929-4496; fax: +44 (0) 117 929-4607).