

## LETTERS TO THE EDITOR

### Waardenburg syndrome type 2 in a Turkish family: implications for the importance of the pattern of fundus pigmentation

EDITOR.—Waardenburg syndrome (WS) is a typical auditory pigmentary syndrome with affected individuals showing varying combinations of sensorineural hearing loss, patchy abnormal pigmentation of the eyes, hair and skin, and various defects of neural crest derived tissues.<sup>1-3</sup>

This syndrome is both clinically and genetically heterogeneous and is clinically classified into four types.<sup>3</sup> Mutations of the *PAX3* gene have been identified in WS type 1 and 3, while those of either the *endothelin B receptor* gene, the *endothelin-3* gene or the *sox10* gene have been identified in WS type 4.<sup>4-6</sup> WS type 2 is a heterogeneous group, with about 10% of cases caused by mutations in *MITF*. But *MITF* mutations are obviously not the major cause of WS type 2 and for most cases the genetic basis is as yet unknown.

The diagnostic criteria for WS type 2 proposed by Liu *et al*<sup>1</sup> include, in addition to congenital sensorineural hearing loss and pigmentary disturbances of the hair, pigmentary disturbances of the iris but not of the fundus.

In the two affected boys of the Turkish family presented here, the pattern of fundus pigmentation was one of the most striking clinical features, with dense hyperpigmented areas next to hypopigmented areas. We want to emphasise the importance of a thorough observation of the clinical phenotype and especially of the pattern of fundus pigmentation in WS type 2.

#### CASE REPORT

A Turkish family presented with two of three sons showing clinical symptoms of WS type 2. Firstly, the 5 year old boy, the youngest of three children of a non-consanguineous couple, was referred for ophthalmological evaluation because of constant esotropia in the left eye. The child has worn hearing aids since the age of 16 months; the first reliable audiogram at age 3 years showed profound sensorineural hearing loss which had not changed over the past years. Best corrected visual acuity was right eye 20/20 and left eye 20/400. Cycloplegic refraction showed anisohypermetropia (right eye +2.5D and left eye +4.5D). He had bilateral dark brown irides and strabismus convergens in the left eye (Fig 1, top). The pattern of fundus pigmentation was of a distinctly abnormal type in both eyes. Areas of hypopigmentation on the posterior pole as well as nasally passed over to areas with pigmentary mottling and spots of hyperpigmentation temporally in the right eye. In the left eye, these areas of hyperpigmentation were more extensive in the peripapillary region, nasally, and in the whole fundus periphery, respectively (Fig 1, centre). Audiometry showed profound bilateral sensorineural hearing loss (Fig 1, bottom).

As the parents also reported congenital deafness in the second son with "two different

coloured eyes," we asked them to bring the other family members for examination. The second son, a 7 year old boy, showed complete iris heterochromia with a dark brown iris right and a brilliant blue iris left (Fig 2, top). Cycloplegic refraction revealed an anisohypermetropia (right eye +0.5D and left eye +5.5D), best corrected visual acuity was 20/20 right eye and 20/200 left eye. Severe fundus pigmentary disturbances were found in the left (blue) eye, with extensive albinoid areas nasally and on the posterior pole, whereas the temporal region showed a homogeneous area of dense hyperpigmentation. In the right (dark brown) eye, the pigmentary disturbances were less extensive with a hyperpigmented peripapillary ring and pigmentary mottling especially in the nasal

region (Fig 2, centre). Conventional audiological examinations showed bilateral sensorineural hearing loss with moderate impairment on the right and total deafness on the left side (Fig 2, bottom).

Ophthalmological and audiological evaluations made of the father, the eldest brother, and a son of the father's first marriage were within normal limits. The mother showed pigmentary mottling in the periphery of the fundus only. No other associated abnormalities (such as hair or skin hypopigmentation, medial eyebrow flare, broad and high nasal root, hypoplasia of alae nasi, or premature greying of hair) were found among the family members. To calculate the W index, a biometric index for dystopia canthorum, we used dystopia indices for WS as reported by Arias,<sup>7</sup>

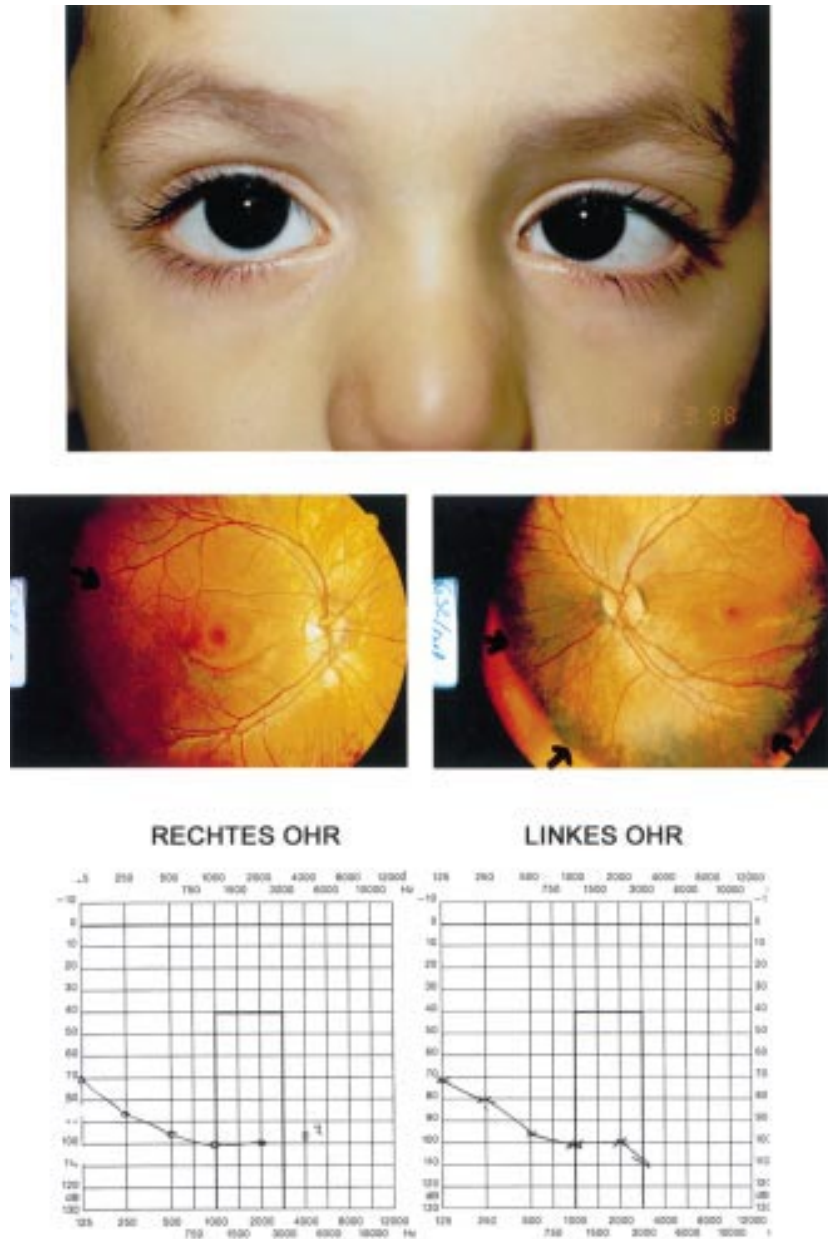
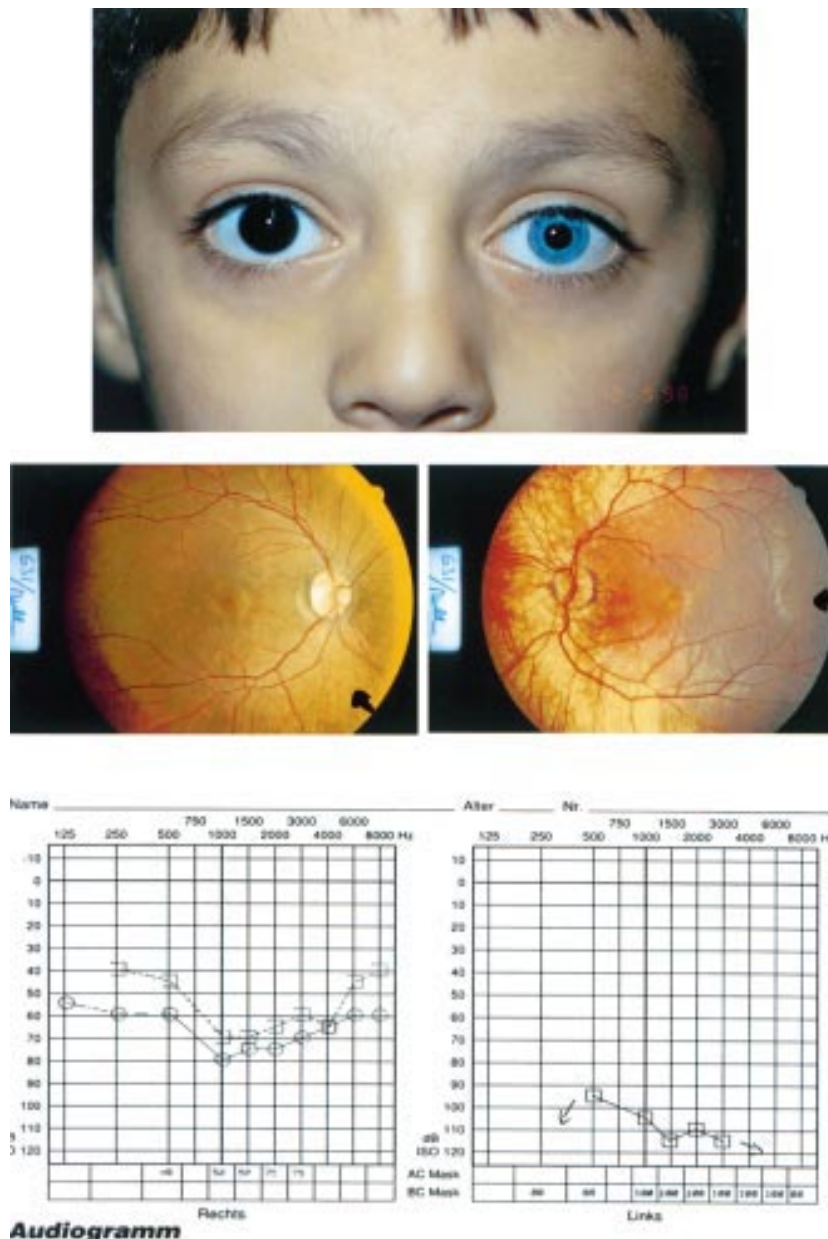


Figure 1 (Top) The 5 year old boy (III-5) with bilateral dark brown irides; corneal reflexes demonstrate left esotropia; there is no evidence of dystopia canthorum. (Centre) Left: right fundus with an area of hypopigmentation on the posterior pole as well as nasally; pigmentary mottling and spots of hyperpigmentation in the temporal periphery (arrow); (right) left fundus, albinoid in type with spots of hyperpigmentation nasally and around the whole fundus periphery (arrows). (Bottom) Audiogram: profound bilateral sensorineural hearing loss.



**Figure 2** (Top) The 7 year old boy (III-4) with heterochromia irides (note the brilliant blue iris colour left); there is no evidence of dystopia canthorum. (Centre) Left: right fundus with pigmentation mottling especially nasally (arrow); right: left fundus albinoid in type nasally and between optic disc and macula; in the temporal region there is a homogeneous dense hyperpigmentation (arrow). (Bottom) Audiogram: bilateral sensorineural hearing loss with moderate impairment in the right ear and total deafness in the left ear.

based upon the inner canthal, interpupillary, and outer canthal distances. The W index for this family was 1.45, indicating that none of the individuals had dystopia canthorum. This was consistent with the clinical picture of WS type 2.

The genomic DNA samples, tested for mutations in the *PAX3* and *MITF* genes as described elsewhere,<sup>4</sup> showed no abnormally migrating bands.

#### COMMENT

Given the classic symptoms of WS type 2 expressed in this Turkish family, we had the opportunity to make some interesting observations on the clinical findings in this syndrome.

In the genomic DNA samples of this family no abnormally migrating bands in the *MITF* gene or the *PAX 3* gene were seen. Only about

10% of patients who fulfil the diagnostic criteria for WS type 2 have an *MITF* mutation and for most cases the genetic basis is as yet unknown.<sup>4-6,8</sup> Dominantly inherited examples of auditory pigmentary syndromes with patchy depigmentation of the skin, hair, eyes or the stria vascularis of the cochlea are usually labelled as Waardenburg syndromes.<sup>1,3</sup> Expression of clinical findings is extremely variable<sup>1,2</sup> and the evaluation of a correct history of pedigree was difficult in this family because of the fact that most of the other family members were living in the Turkey. However, the fundal pigmentary changes of the mother were distinct enough to mark her as affected.

Complete heterochromia irides and especially the brilliant sapphire-blue eye colour have been noted rarely in non-Waardenburg people.<sup>5</sup> Slit lamp examination of the left iris

of the second son showed a thick iris of a brilliant blue colour without any hypoplastic structures or transillumination defects. It is generally assumed that in WS type 2 only the mesodermal component of the iris is involved owing to a lack of melanocytes in the mesodermal part of the iris.

Congenital deafness is clinically the most serious symptom. WS type 2 individuals were found to have a greater incidence of deafness, more severe and more often bilateral forms of deafness.<sup>2</sup> Hearing impairment can be explained by a lack of melanocytes in the stria vascularis of the cochlea. These two affected boys showed bilateral sensorineural hearing loss. Interestingly, we found that the audiological results are paralleled by the pattern of fundus pigmentation. While the youngest boy with bilateral brown irides and marked bilateral pigmentary abnormalities of the fundus had profound bilateral hearing loss (Fig 1), the 7 year old boy with heterochromia irides showed different degrees in the severity of fundus anomalies and hearing loss: the moderate degree of hearing loss of the right ear correlated with mild irregularities of pigmentation of the homolateral fundus, total deafness left correlated with severe homolateral fundus pigmentary disturbances and the brilliant blue iris (Fig 2).

The pattern of fundus pigmentation is not considered as part of diagnostic criteria for WS type 2.<sup>1</sup> However, in our family, abnormalities in fundus pigmentation seem to constitute an integral part of this syndrome. Fundi in patients with WS were described as "patchy hypopigmentation," "pigmentary mottling," or "albinoid in type" in most cases.<sup>9,10</sup> Only Goldberg<sup>9</sup> reported "blond next to hyperpigmented areas" in a black boy. In the two affected boys, dense hyperpigmented areas next to marked hypopigmented areas were one of the most impressive clinical findings. This picture seems to be the result of a localised accumulation of pigmented melanocytes which were handicapped in their determined homogeneous distribution.

In conclusion, we have presented a Turkish WS type 2 family in which no mutations of the *MITF* gene could be found. The affected family members showed a conspicuous fundus picture with ipsilateral connections between iris, fundus, and perhaps, inner ear pigmentation. Therefore, one might suggest, that the clinical signs in WS type 2 could be a consequence of a failure in distribution of pigmented melanocytes in their final location. The genetic basis, as yet unknown for most cases of WS type 2, might be found in a very late step of the pigmentation pathway.

ANDREA MÜLLNER-EIDENBÖCK  
ELISABETH MOSER

Department of Ophthalmology, University Hospital of  
Vienna, Austria

HERWIG FRISCH

Department of Paediatrics, University Hospital of  
Vienna, Austria

ANDREW P READ

University Department of Medical Genetics, St Mary's  
Hospital, Manchester M 13 0JH, UK

Correspondence to: Andrea Müllner-Eidenböck, MD, Department of Ophthalmology, University of Vienna Medical School, Allgemeines Krankenhaus, A-1090 Vienna, Waehringier Guertel 18-20, Austria  
andrea.muellner-eidenboeck@akh-wien.ac.at  
Accepted for publication 20 April 2001

1 Liu XZ, Newton VE, Read AP. Waardenburg syndrome type 2: phenotypic features and diagnostic aspects. *Am J Med Genet* 1995;55:95-100.

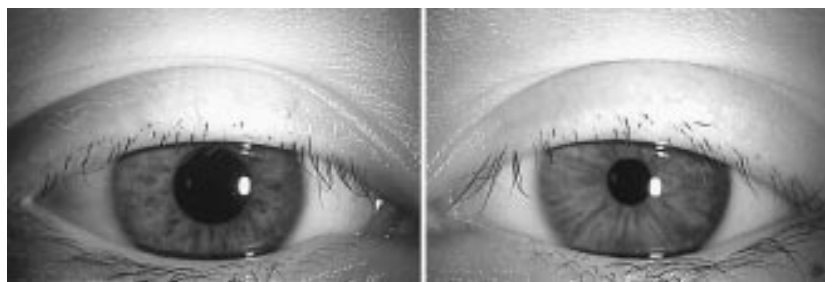


Figure 1 Scarce central eyelashes on both upper eyelids.

- Reynolds JE, Meyer JM, Landa B, *et al.* Analysis of variability of clinical manifestations in WS. *Am J Med Genet* 1995;57:540–7.
- Read AP, Newton VE. Waardenburg syndrome. *J Med Genet* 1997;34:656–65.
- Tassabehji M, Newton VE, Liu XZ, *et al.* The mutational spectrum in Waardenburg syndrome. *Hum Mol Genet* 1995;4:2131–7.
- Tachibana M. A cascade of genes related to Waardenburg syndrome. *J Invest Dermatol Symp Proc* 1999;4:126–9.
- Lalwani A, Attaie A, Randolph F, *et al.* Mutation in the MITF gene causing WS type II in a three-generation Indian family. *Am J Med Genet* 1998;80:406–9.
- Arias S, Mota M. Apparent non-penetrance for dystopia in WS type I, with some hints on the diagnosis of dystopia canthorum. *J Genet Hum* 1978;26:103–31.
- Tassabehji M, Newton VE, Read AP. Waardenburg syndrome type 2 caused by mutations in the human microphthalmia (MITF) gene. *Nat Genet* 1994;8:251–5.
- Goldberg MF. Waardenburg's syndrome with fundus and other anomalies. *Arch Ophthalmol* 1966;76:797–810.
- Delleman JW, Hageman MJ. Ophthalmological findings in 34 patients with Waardenburg syndrome. *J Pediatr Ophthalmol Strabismus* 1978;15:341–5.

### Trichotillomania

EDITOR.—Trichotillomania is the inability to resist the urge to pull out body hair. We present a case of this rare condition.

#### CASE REPORT

A 12 year old boy was referred to the eye clinic with complaints of dropping of eyelashes of both upper eyelids. He was seen by his optician before the referral. Lid hygiene, propamidine isethionate eye ointment 0.15% (Brolene), and sodium cromoglycate eye drops 2% (Opticrom) were tried but with no benefit. The mother reports that his eyelashes grew while they were abroad on a holiday for a fortnight and then fell off once they returned from their holiday!

When seen in the eye clinic his visual acuities were 6/5 bilaterally. He had no significant ocular history, was generally fit and well, and was taking no regular medications. His parents did not express any concerns regarding his health or his behaviour. On examination, the eyelashes of both upper eyelids were scarce centrally. The few lashes, which were seen, had pointed and not cut ends. On either side the lashes were normal. There was no evidence of inflammation or disease of the lid margins and the rest of the ocular examination was normal. There was no evidence of loss of eyebrow or scalp hair. He is being considered for psychiatric evaluation.

#### COMMENT

Trichotillomania is characterised by an irresistible urge to pull one's hair. Any body hair may be targeted. Scalp and eyelashes are most commonly affected. Onset is generally in childhood or adolescence, and a chronic course is typical. Depression and anxiety frequently accompany

this disorder. An increased incidence of comorbid obsessive-compulsive disorder (OCD) has been noted.<sup>1</sup> The estimated lifetime prevalence is 1.5% for male and 3.4% for female college students.<sup>2</sup> In very young patients, a more equal sex ratio is observed. On the whole, women show 5–10 times higher prevalence rates than men.<sup>2</sup> The majority of the sufferers disguise their hair loss very well. Because of the secrecy and shame about their behaviour, many remain silent sufferers and treatment is often delayed. It is a chronic mental illness that imposes severe limitations on the patient's social, emotional, and occupational adjustment. The pathophysiology of trichotillomania is not well understood. Treatment options include: medications such as serotonin reuptake inhibitors with or without haloperidol,<sup>1</sup> paroxetine,<sup>3</sup> clomipramine,<sup>4</sup> pimoziide,<sup>2</sup> risperidone in serotonin reuptake inhibitor refractory trichotillomania,<sup>5</sup> venlafaxine<sup>6</sup>; behaviour therapy habit reversal training<sup>2,4</sup> and hypnotherapy.<sup>1</sup>

Trichotillomania has been infrequently reported in the ophthalmic literature. Management can be difficult. Many of these patients are aware of their behaviour, but are unable to curtail it. Others may conceal or deny their habit. Psychiatric counselling may be of benefit if patients are willing to undergo it.

B B PATIL  
T C DOWD  
North Riding Infirmary, Newport Road, Middlesbrough  
TS1 5JE, UK

Correspondence to: B B Patil  
bheemapatil@hotmail.com

Accepted for publication 5 February 2001



Figure 1 (Left) Slit lamp photograph of the right cornea. Stromal oedema with brush-like stromal vascularisation (arrows). (Right) Slit lamp photograph of the right cornea, using a narrow slit beam. Dense deposition of golden brown granules is seen in the inferior corneal stroma superior to the limbus. Arrows indicate epithelium (long arrow) and endothelium (short arrow).

- Christenson GA, Crow SJ. The characterization of treatment of trichotillomania. *J Clin Psychiatry* 1996;57(suppl 8):42–7; discussions 48–9.
- Ko SM. Under diagnosed psychiatric syndrome: trichotillomania. *Ann Acad Med Singapore* 1999; 28:279–81.
- Block C, West SA, Baharoglu B. Paroxetine treatment of trichotillomania in an adolescent. *J Child Adol Psychopharmacol* 1998;8:69–71.
- Tynes LL, Winstead DK. Behavioural aspects of trichotillomania. *J La State Soc* 1992;144:459–63.
- Epperson CN, Fasula D, Wasylink S, *et al.* Risperidone addition in serotonin reuptake inhibitor-resistant trichotillomania: three cases. *J Child Adol Psychopharmacol* 1999;9:43–9.
- Ninan PT, Knight B, Kirk L, *et al.* A controlled trial of venlafaxine in trichotillomania: interim phase I results. *Psychopharmacol Bull* 1994;34: 221–4.

### Gold induced interstitial keratitis

EDITOR.—A 60 year old woman presented with intense, bilateral ocular irritation and photophobia. She had a history of rheumatoid arthritis and was under treatment with prednisone, azathioprine, sulindac, plaquenil, and intramuscular injections of gold sodium thiomaleate (50 mg once weekly). She had received a total of 7.4 g of gold over the past 3 years. Examination revealed an extremely photophobic patient with a visual acuity of 20/20 in both eyes. The conjunctivas were mildly injected, with bilateral perilimbal chemosis. The peripheral cornea showed 360° stromal oedema. Mid-stromal vessels were seen entering the oedematous stroma from the limbus (Fig 1 (left)). The rest of the examination was unremarkable. The patient was diagnosed with rheumatoid marginal keratitis, and therapy was started with hourly application of topical prednisolone acetate. Over the next 2 months her symptoms gradually resolved, as did most of her inflammatory findings. However, granular, golden brown pigmented deposits appeared in the corneal stroma in the same peripheral, ring-like distribution as the now resolved stromal keratitis (Fig 1 (right)). A diagnosis of gold keratopathy was made, and the patient was referred for rheumatological consultation. A systemic evaluation did not reveal signs of gold toxicity. Gold therapy was discontinued. Over the next 6 months, the stromal deposits partially cleared, and topical prednisolone was gradually tapered off. A milder episode of photophobia and irritation

then occurred, with stromal oedema in the same distribution. This was controlled by reinstitution of topical prednisolone therapy. One year after onset, the patient continues to use topical prednisolone once a day and is asymptomatic. There is no stromal inflammation, but fine golden granules are still evident.

#### COMMENT

Two variants of gold induced keratopathy (corneal chrysiasis) have been described.<sup>1</sup> The more common variant manifests as asymptomatic deposition of fine brown or purple granules in the central posterior corneal stroma, sparing the periphery. Other patterns include peripheral deposition with extension towards the central cornea, superficial and deep axial deposition.<sup>2</sup> Corneal stromal granule deposition correlates with duration and dosage of therapy and occurs in most, if not all patients after a cumulative dose of 1 g has been reached.<sup>1,2</sup> Corneal gold deposition by itself is not considered an indication to discontinue gold therapy.<sup>2</sup>

The second variant of keratopathy is rare, presenting with inflammatory symptoms and signs. Examination reveals marginal interstitial keratitis that may ulcerate, with white, subepithelial limbal infiltration and deep, brush-like stromal vascularisation.<sup>1,3</sup> Crescent-shaped marginal ulcers, 2–3 mm in length may be present. This variant is presumed to be an idiosyncratic reaction.<sup>1,3</sup> It may be unilateral or bilateral, and is considered an indication to stop gold therapy.<sup>1</sup> The underlying pathogenic mechanism, as well as the possible associations with other systemic gold toxicity, is unknown. However, it is notable that the keratitis in our case was responsive to topical corticosteroids and recurred after their withdrawal. A similar response has been reported in systemic manifestations of gold toxicity.<sup>4,5</sup>

The diagnosis of gold keratopathy should be considered in patients with rheumatoid arthritis who present with marginal keratitis. Assessment of possible systemic toxicity is warranted and cessation of therapy should be considered in such cases. Patients should be continuously followed, since stromal inflammation may recur even after cessation of gold therapy.

Supported in part by National Institute of Health core grant EY03040 and by an unrestricted grant from Research to Prevent Blindness, New York, USA. Dr Zamir is the recipient of an American Physician fellowship, Boston, MA. Dr Read is the recipient of an American Ophthalmological Society/Herman Knapp Testimonial Fund fellowship, Cleveland, OH, USA.

EHUD ZAMIR  
RUSSELL W READ  
JOHN C AFFELDT

Doheny Eye Institute, Keck School of Medicine of the  
University of Southern California, Los Angeles,  
California, USA

DHARMARAJAN RAMASWAMY  
Department of Rheumatology

NARSING A RAO  
Doheny Eye Institute

Correspondence to: Narsing A Rao, MD, Doheny Eye Institute, Keck School of Medicine, University of Southern California, 1450 San Pablo Street, DVRC 211, Los Angeles, CA 90033, USA

nrao@hsc.usc.edu

Accepted for publication 18 April 2001

1 Arffa RC. Drugs and metals. In: Arffa RC, ed. *Grayson's diseases of the cornea*. 3rd ed. St Louis: Mosby-Year Book, 1991:617–31.

- McCormick SA, DiBartolomeo AG, Raju VK, et al. Ocular chrysiasis. *Ophthalmology* 1985;92:1432–5.
- Smith JL. Ocular complications of rheumatic fever and rheumatoid arthritis. *Am J Ophthalmol* 1957;43:575–82.
- Schapira D, Nahir M, Scharf Y. Pulmonary injury induced by gold salts treatment. *Med Interne* 1985;23:259–63.
- Hansen RM, Varma RR, Hanson GA. Gold induced hepatitis and pure red cell aplasia. Complete recovery after corticosteroid and N-acetylcysteine therapy. *J Rheumatol* 1991;18:1251–3.

#### Osteosarcoma with metastasis to orbit

EDITOR,—Osteosarcoma is the most common primary malignant tumour of the bone. More than 90% of patients with this disease die with pulmonary metastases. Metastatic disease to the orbit from sarcomas is rare.<sup>1</sup> An English language computer Medline search (from January 1966 to December 2000) for osteosarcoma metastatic to the orbit did not reveal any previous report. We describe perhaps the first case of osteosarcoma metastasising to the orbit.

#### CASE REPORT

An 8 year old boy was referred from a district hospital for a swelling over the proximal right leg of 5 months' duration. Lower extremity radiography showed a metaphyseal lesion in the proximal tibia with bone destruction and new bone formation. A clinical and radiological diagnosis of osteosarcoma was made. A plain chest radiograph did not reveal any abnormality. Histopathological examination of the tumour confirmed the diagnosis of osteosarcoma. An above knee amputation of the right leg was performed.

One month later, the child developed protrusion of the right eye (Fig 1). An ophthalmic examination confirmed proptosis

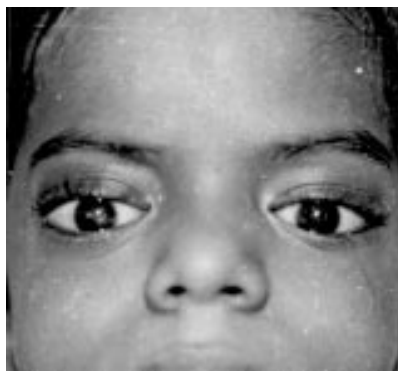

Figure 1 Clinical photograph showing proptosis of right eye.

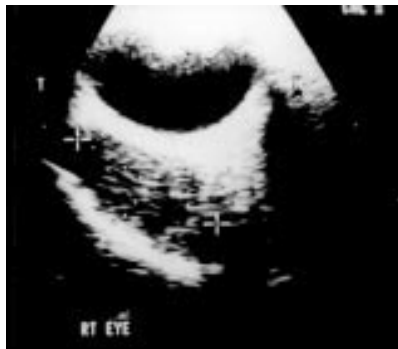

Figure 2 Ultrasound showing retrobulbar mass.

of the right eye. Vision, fundus, and eye movements were normal in both eyes. Ultrasound examination of the eye revealed a 12 mm × 18 mm lobulated, nodular, hypodense retrobulbar shadow on the temporal side, displacing the optic nerve medially. An area of necrosis was seen in the mass, but no calcification was present (Fig 2). Computed tomography of the orbit confirmed the findings of ultrasonography, demonstrating a soft tissue density mass in the right orbit displacing the eyeball. Fine needle aspiration cytology from the mass showed malignant spindle cells. A diagnosis of osteosarcoma with metastasis to right orbit was made. The patient was offered palliative chemotherapy but refused further treatment and was discharged from the hospital.

#### COMMENT

Osteosarcoma is the most common primary malignant tumour of bone. Most cases occur in children, adolescents, and young adults with a male predominance. The classic site of occurrence is the medulla of the metaphysis of the long bones, particularly the distal femur, proximal tibia, and proximal humerus. Metastases of osteosarcoma typically involve the lungs. Recent studies indicate, however, that the incidence of non-pulmonary metastases is increasing.<sup>2</sup>

Orbital metastases from malignant neoplasms are rare and can originate from anywhere in the body.<sup>3</sup> In adults, the primary tumour is almost always a carcinoma, with breast and lung accounting for the vast majority of orbital metastases, followed in frequency by genitourinary and gastrointestinal primaries. In children with orbital metastases the primary tumours in descending order of frequency are neuroblastoma, Ewing's sarcoma, and Wilm's tumour.<sup>4</sup> Jain *et al*<sup>5</sup> found leukaemia and neuroblastoma as the commonest tumours producing orbital metastases. The two populations studied in these reports differed geographically (United States and India respectively). These tumours tend to involve the orbits and spare the globes in contradistinction to metastatic disease in adults.<sup>4</sup> Metastatic osteosarcoma to the eye is very rare. Newman and DiLoreto<sup>6</sup> reported a single case metastatic to the eyelids. Spaulding and Woodfin<sup>7</sup> and Lees<sup>8</sup> have reported single cases of osteosarcoma metastatic to the choroid. The lung was not involved as a metastatic site in our patient. The spread of tumour to the orbit, sparing the lung, may have possibly been through the Batson's paravertebral system. Physicians should be aware that non-pulmonary metastases of osteogenic sarcoma may exist at unusual sites.

A MISRA  
Department of Ophthalmology, King George's Medical  
College, Lucknow - 226003, India

S MISRA  
A CHATURVEDI  
Department of Surgical Oncology

P K SRIVASTAVA  
Department of Radiotherapy

Correspondence to: Dr Sanjeev Misra, 122, Faizabad Road, Lucknow-226007, UP, India  
misralko@satyam.net.in

Accepted for publication 17 May 2001

- Peyster RG, Shapiro MD, Haik B. Orbital metastasis: role of magnetic resonance imaging and computed tomography. *Radiol Clin North Am* 1987;25:647–62.
- Giuliano AE, Feig S, Eilber FR. Changing metastatic patterns of osteosarcoma. *Cancer* 1984;54:2160–4.
- Char DH, Miller T, Kroll S. Orbital metastases: diagnosis and course. *Br J Ophthalmol* 1997;81:386–90.

- Jakobiec FA, Rootman J, Jones IS. Secondary and metastatic tumors of the orbit. In: Duane TD, Jaeger EA, eds. *Clinical ophthalmology*. Philadelphia: JB Lippincott; 1982:1-67.
- Jain IS, Dinesh K, Mohan K. Ocular and orbital metastasis from systemic malignancies. *Indian J Ophthalmol* 1987;35:437-41.
- Newman NM, DiLoreto DA. Metastasis of primary osteogenic sarcoma to the eyelid. *Am J Ophthalmol* 1987;104:659-60.
- Spaulding AG, Woodfin MC Jr. Osteogenic sarcoma metastatic to the choroid. *Arch Ophthalmol* 1968;80:84-6.
- Lees V. A case of metastatic osteosarcoma in the choroid. *Br J Ophthalmol* 1947;31:713-16.

### An unusual cause of oscillopsia

EDITOR,—Chronic maxillary atelectasis (CMA),<sup>1</sup> also known as silent sinus syndrome (SSS)<sup>2</sup> describes the same condition. Typically, the patient presents with acute enophthalmos and hypoglobus in the absence of previous trauma or surgery. Past sinus disease may be present and computed tomograph (CT) scans demonstrate ipsilateral sinus contraction, orbital floor resorption, and thinning with inferior prolapse into the maxillary sinus. We present a patient who noted oscillopsia while jogging 1 year after being diagnosed with SSS.

#### CASE REPORT

A 26 year old woman was referred with a 6 month history of painless gradual sinking of the left eye (Fig 1). She had suffered two episodes of mild sinusitis, one at the age of 12 and one at a year before presentation. Visual acuity was 6/6 in each eye and there was no evidence of optic neuropathy. There was 4 mm of left relative enophthalmos, no manifest deviation, and full extraocular movements. The height of the palpebral aperture was 1 mm less on the left. Orbital CT scans showed a unilaterally opaque maxillary antrum and ethmoid sinus, a collapsed infundibulum, an imploding medial wall, and a concave demineralised orbital floor (Fig 2). Eighteen months after becoming symptomatic, the patient spontaneously remarked that she had vertical oscillopsia while jogging.

#### COMMENT

Oscillopsia is an illusion that the world is in motion; we believe that this is the first report

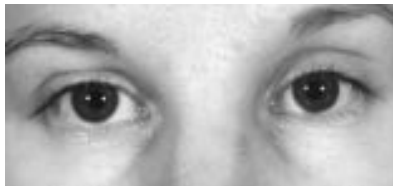

Figure 1 There is left hypoglobus, enophthalmos (indicated by the deeper upper lid sulcus) and a narrower left palpebral aperture.

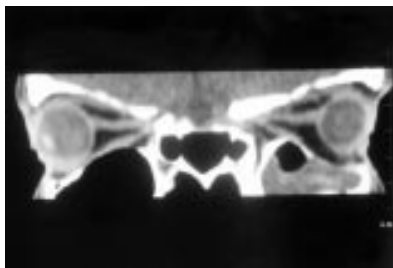


Figure 2 Unwrapped orbital CT scan demonstrates an opaque left maxillary antrum and inferior bowing of the orbital floor.

in a patient with SSS. It occurs most frequently with disorders of the vestibular system, cerebellum, or brainstem. Our patient had no associated neurological signs or symptoms, and a normal head CT scan. A mechanical cause of oscillopsia caused by an instability of fixation is a rare but well documented finding.<sup>3</sup>

In our patient we postulate that the oscillopsia during jogging arises from inadequate globe support caused by demineralisation and downward displacement of the orbital floor and Lockwood's ligament, while the levator palpebrae superioris and Whitnall's ligament remain in their normal position. Patients with SSS may also develop vertical diplopia,<sup>4</sup> lid retraction,<sup>5</sup> lagophthalmos,<sup>6</sup> or blurred vision.<sup>7</sup>

Spontaneous enophthalmos unrelated to trauma, surgery, local malignancy, or systemic disease is uncommon. The presence of diplopia may suggest an underlying neuro-ophthalmic disorder; however, hypoglobus and enophthalmos point to the orbital/maxillary area as the primary site of pathology.

HADI J ZAMBARAKJI  
GEOFFREY E ROSE  
Orbital Clinic, Moorfields Eye Hospital, City Road,  
London EC1V 2PD, UK

Correspondence to: Mr G E Rose  
Accepted for publication 6 June 2001

- Montgomery WW. Mucocoele of the maxillary sinus causing enophthalmos. *Eye Ear Nose Throat Mon* 1964;43:41-3.
- Soparkar CN, Patrinely JR, Cuaycong MJ, et al. The silent sinus syndrome. A cause of spontaneous enophthalmos. *Ophthalmology* 1994;101:772-8.
- Knight RT SJJ, Nakada T. A case of voluntary visual illusions of movement. *Arch Neurol* 1984;41:95-6.
- Durig J, Borruat FX, Jaques B. Silent sinus syndrome: an unusual cause of vertical diplopia. *Klin Monatsb Augenheilkd* 1998;212:397-9.
- Bartley GB. The differential diagnosis and classification of eyelid retraction. *Ophthalmology* 1996;103:168-76.
- Rubin PAD RS. Functional indications for enophthalmos repair. *Ophthalmic Plast Reconstruct Surg* 1999;14:284-92.
- Wan MK, Francis IC, Carter PR, et al. The spectrum of presentation of silent sinus syndrome. *J Neuro-Ophthalmol* 2000;20:207-12.

### Cytogenetic analysis in ocular lymphoma

EDITOR,—A 56 year old man was referred to the ocular oncology service with complaints of pain, redness, and blurring of vision in his left eye for the previous 2 months. He had no significant past ocular history. He was a known hypertensive with no known allergies.

On examination his visual acuity was 6/18 in the right eye and 6/6 in the left eye. There was 2 mm of relative exophthalmos on the right side. A pink subconjunctival patch was noticed in the superior quadrant (Fig 1). He had a shallow anterior chamber. Gonioscopy showed that anterior bowing of the iris closed 270 degrees of the angle. A YAG iridotomy was performed and pupils dilated for fundus evaluation. Funduscopy showed extensive peripheral elevation of the ciliary body and pars plana, which appeared to extend subretinally to the disc with an overlying retinal detachment in places (Fig 2) Ultrasound biomicroscopy along with B scan of the globe confirmed diffuse infiltration of the ciliary body and choroid (Fig 3A). Diffuse extension of this abnormal tissue behind the globe was also evident. The left eye was normal. A working diagnosis of benign reactive lymphoid hyperplasia was made and an incisional biopsy

planned. The patient was subsequently admitted for an incisional biopsy and investigations to rule out systemic disease. No systemic evidence of lymphoma was found, however. Histopathology confirmed the diagnosis of well differentiated B cell lymphoma (diffuse large cell lymphoma (REAL classification)<sup>1</sup>) (Fig 4).

A cytogenetic analysis was also performed as detailed previously.<sup>2,3</sup> Only a partial analysis was possible, but from analysis of 12 divisions the karyotype was determined to be: 2 cells, 46 XY; 10 cells, 43-46 X-Y, add (1)(q?) [10], add (6)(q?) [10], -10 [10], -14 [10], +2mar [5].

The patient was subsequently started on 30 mg of prednisolone and was referred to the radiotherapy department where he received 30 Gy in 15 sessions over a 3 week period. Follow up at 4 months and further 3 months following the radiotherapy showed resolution

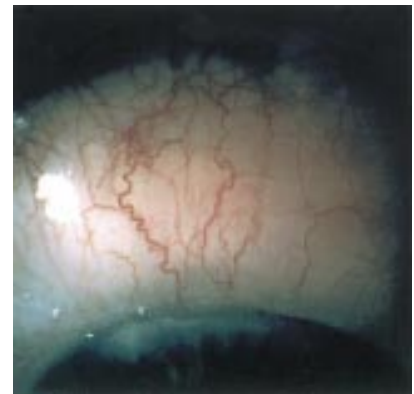


Figure 1 Photograph showing the conjunctival lesion at presentation.

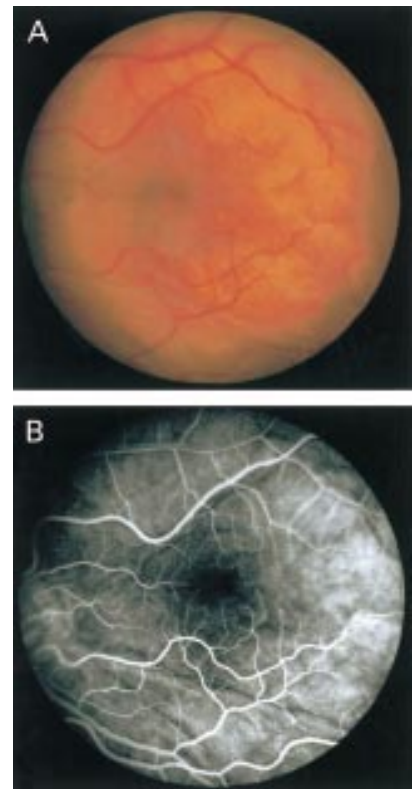


Figure 2 (A) Colour fundus photograph showing the posterior extension of the lesion. (B) Fundus fluorescein angiography showing multiple areas of hyperfluorescence.

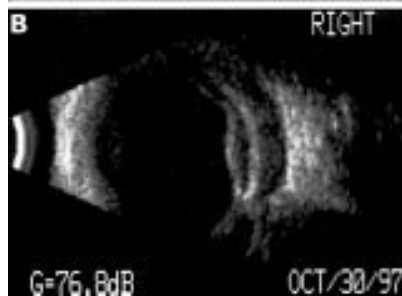
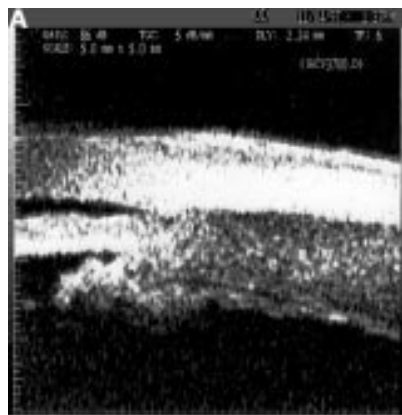


Figure 3 (A) Ultrasound biomicroscopy showing infiltration of the ciliary body and choroid. (B) Ocular B scan ultrasonography showing the posterior extension.

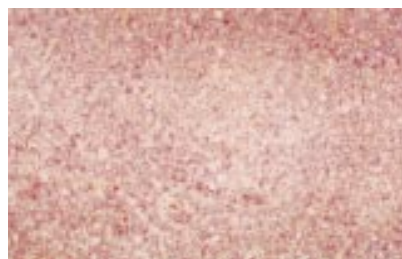

Figure 4 Histological section of the lesion confirming the lesion to be a well differentiated B cell lymphoma.

of the mass. The patient has since been asymptomatic.

#### COMMENT

Characteristic cytogenetic abnormalities are known to be associated with certain types of lymphoma.<sup>4,5</sup> In addition to classic translocation of chromosome 8 and 14 in Burkitt's lymphoma, other chromosome rearrangements are related to subsets of lymphoma.<sup>5</sup> To our knowledge this is the first report of chromosome abnormalities in ocular lymphoma. We observed abnormalities frequently associated with non-Hodgkin's lymphoma (NHL), including rearrangements of chromosome 1 and 6, which are found in both B and T cell NHL, as is a loss of the Y chromosome.<sup>6</sup> Trisomy of chromosome 12 was also observed in this ocular lymphoma, and has been linked with small lymphocytic or diffuse large cell B NHL,<sup>5</sup> and from a study of diffuse large cell lymphomas of stomach, chromosome 12 was again found to be the most consistent abnormality.<sup>4</sup> Although its too early to identify which abnormalities are specifically related to the development of this eye lymphoma, it is apparent that certain alterations are characteristic of lymphoma in

general, suggesting that similarities exist between development of ocular and other lymphomas.

S PRASAD

Department of Ophthalmology and Orthoptics,  
University of Sheffield, Royal Hallamshire Hospital,  
Sheffield S10 2JF, UK

P PURI

Department of Ophthalmology, Royal Hallamshire  
Hospital

K SISLEY

Department of Ophthalmology and Orthoptics,  
University of Sheffield

A PARSONS

I G RENNIE

Department of Ophthalmology and Orthoptics,  
University of Sheffield

Correspondence to: Mr S Prasad

Accepted for publication 4 February 2001

- Harris NL, Jaffe ES, Stein H, *et al.* A revised European-American classification of lymphoid neoplasms: a proposal from the International Lymphoma study group. Comment in: *Blood* 1994;84:1359-60; comment in *Blood* 1995; 85:857-60; comment in *Blood* 1995;85:1972-4.
- Sisley K, Rennie IG, Parsons MA, *et al.* Abnormalities of chromosome 3 and 8 in posterior uveal melanoma correlate with prognosis. *Genes Chromosom Cancer* 1997;19:22-8.
- Sisley K, Brand C, Parsons MA, *et al.* Cytogenetics of iris melanomas: disparity with other uveal tract melanomas. *Cancer Genet Cytogenet* 1998; 101:128-33.
- Chan WY, Wong N, Chan ABW, *et al.* Consistent copy number gain in chromosome 12 in primary diffuse large cell lymphomas of the stomach. *Am J Pathol* 1998;152:11-16.
- Donner LR. Cytogenetics of lymphoma: a brief review of its theoretical and practical significance. *Cancer Genet Cytogenet* 1997;94:20-6.
- Heim S, Mitelman F. Malignant lymphoma. In: Heim, Mitelman, eds. *Cancer Cytogenetics*. New York: Wiley Liss.

#### Grotesque bilateral eyelid swelling as a symptom of Munchausen's syndrome

EDITOR,—Eyelid swelling can be diffuse or solid, acute or chronic, isolated or part of a syndrome. The differential diagnosis of solid, chronic, and isolated eyelid swelling comprises tumours of multiple origin. We report a case of eyelid swelling which was caused by automutilation as part of Munchausen's syndrome.

#### CASE REPORT

A 44 year old white woman presented with bilateral lower eyelid swelling that had been present for 6 months, which made reading impossible (Fig 1). In the past she had undergone several paranasal sinus operations and 3 years earlier she had been treated for a preseptal orbital cellulitis and pansinusitis. For the past 4 years she had been bedridden because of fibromyalgia.

The swellings measured 7 × 5 × 2 cm and felt solid on palpation. Complete ocular, internal,

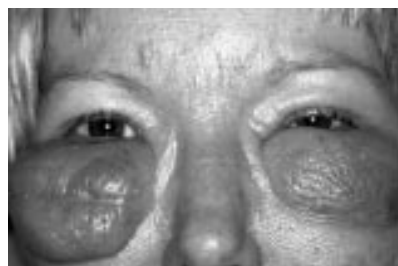

Figure 1 The patient presented with bilateral lower eyelid swelling.

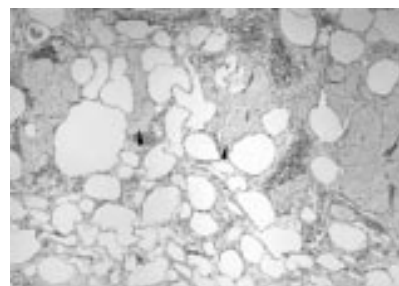


Figure 2 Histology of the upper lids showed densely packed empty spaces.

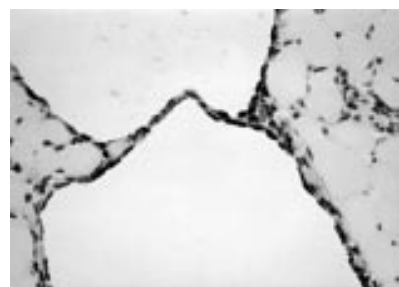


Figure 3 At high magnification the empty spaces reveal a lining of macrophages.

otolaryngological, dermatological, parasitological, and psychological examination revealed no clues for the diagnosis. The swellings were surgically removed to the level of the orbital septum, the defects being covered with full thickness skin grafts. Histological examination showed chronic lymphoedema with lymphangiectasia, inflammation, and striking eosinophilia, but no conclusive diagnosis could be made at this time. During uneventful healing of the lower lids, the patient developed bilateral upper eyelid swelling. These swellings were removed as well and replaced by split skin grafts. Histology of the upper lids showed densely packed empty spaces, which almost obscured pre-existent structures such as the orbicularis muscle (Fig 2). In between a patchy infiltrate of lymphocytes, neutrophils, eosinophils, and many macrophages was seen. At high magnification (Fig 3), the empty spaces revealed a lining of macrophages as was demonstrated by positivity for the CD 68 antibody, a reaction pattern highly suggestive of a factitious process. The diagnosis of Munchausen's syndrome was made.

#### COMMENT

The patient was confronted with these results and admitted having pin-pricked herself after putting fatty ointments on her eyelids. She thought this would help the "blisters" to disappear more rapidly. After an emotional conversation, she was able to get up and walk for the first time in 4 years. The repeated psychiatric evaluation resulted in a diagnosis of a factitious disorder with physical signs superimposed on a somatisation disorder. The complaints seemed to have a function in the maintenance of the balance of power in the matrimonial relationship. The patient refused psychiatric treatment.

Factitious disorders, such as the Munchausen's syndrome, are under the patient's voluntary control and are intended to get or maintain the role of patient.<sup>1-3</sup> Self inflicted enucleation and corneal perforation are described ophthalmological representatives of these disorders and easy to recognise.<sup>4-6</sup> The above described swellings are a less common

and more difficult to prove example of an ocular factitious disorder, although the patient's medical history might make the doctor suspicious. In summary, self-inflicted disorders must be considered as a cause of eyelid swelling.

MAARTEN PH MOURITS  
INNA V SASIM

Department of Ophthalmology, University Medical  
Center Utrecht, Netherlands

SEBASTIAAN C J VAN DER PUTTE  
Department of Pathology

Correspondence to: Dr Maarten Ph Mourits, Orbital Unit, Department of Ophthalmology, University Medical Center Utrecht, POBox 85500, 3508 GA Utrecht, Netherlands  
M.P.Mourits@oogh.azu.nl  
Accepted for publication 16 April 2001

- 1 Shafer N, Shafer R. Factitious disorders including Munchausen's syndrome. *NY State J Med* 1980;80:594.
- 2 Rosenberg PN, Krohel GB, Webb RM, et al. Ocular Munchausen's syndrome. *Ophthalmology* 1986;93:1120-3.
- 3 Numata-Watanabe K, Hayasaka S, Kadoi C, et al. Decreased visual acuity and diplopia in a patient with Munchausen syndrome. *Ophthalmologica* 1998;212:337-8.
- 4 Duke-Elder S, MacFaul PA. Self-inflicted injuries. In: Duke-Elder S, ed. *System of Ophthalmology*. London: Henry Kimpton 1972;14,part 1:58.
- 5 Palmowski A, Heinz G, Ruprecht KW. Self-inflicted injuries of the eye: differential diagnosis of self-inflicted lacerating corneal injury. *Klin Monatsbl Augenheilkd* 1994;204:30-2.
- 6 Heinz P, Bodanowitz S, Hesse L. Keratitis punctata superficialis caused by self-injury. *Klin Monatsbl Augenheilkd* 1995;207:130-2.

#### Angle closure glaucoma secondary to hemiretinal vein occlusion

EDITOR.—Central retinal vein occlusion (CRVO) has been reported to cause shallowing of the anterior chamber with acute angle closure glaucoma.<sup>1,2</sup> This is due to anterior displacement of the lens-iris diaphragm caused by either the transudation of fluid from retinal vessels into the vitreous cavity or swelling of the ciliary body due to spasm, oedema, or detachment which may cause relaxation of lens zonules with subsequent crowding and closure of the angle.<sup>2,3</sup> We describe a patient who developed angle closure glaucoma without neovascularisation of the angle secondary to hemiretinal vein occlusion which responded to miotics and iridotomy suggesting a "pupillary block" mechanism. This is the first report of angle closure glaucoma following a hemiretinal vein occlusion.

#### CASE REPORT

A 63 year old African American man with controlled systemic hypertension noted reduced vision in his right eye for 1 month. Best corrected visual acuity was 20/200 right eye with +1.75 -0.75 × 85, and 20/25 left eye with +2.25 -1.00 × 95. Slit lamp examination was unremarkable, pupils were equally reactive without an afferent pupillary defect. Intraocular pressure (IOP) was 26 mm Hg right eye and 25 mm Hg left eye. Gonioscopy revealed grade 3 angles in both eyes. The superior half of the retina right eye had dilated tortuous veins and multiple superficial haemorrhages. The right optic nerve was oedematous and hyperaemic. Retinal examination was unremarkable left eye with a cup to disc ratio of 0.4 horizontally by 0.5 vertically. The patient was diagnosed with a hemiretinal vein occlusion right eye, elevated IOP in both eyes, and treated with betaxolol 0.25% twice daily in both eyes.

Two weeks later visual acuity was counting fingers right eye and unchanged left eye. IOP

was 42 mm Hg right eye and 20 mm Hg left eye, on betaxolol. The patient was referred to our office.

On examination the anterior chambers were shallow right eye and deep left eye. IOP was 45 mm Hg right eye and 21 mm Hg left eye. The angle was closed without neovascularisation right eye and grade 3 left eye. B scan ultrasonography revealed an unremarkable posterior segment without choroidal detachments right eye. Brimonidine 0.2% and Cosopt were administered to the right eye. Thirty minutes later the IOP was 36 mm Hg right eye. Three hours later IOP right eye was 28 mm Hg. Mydracyl 1%, neosynephrine 2.5%, and Cyclogyl 2% were administered and the IOP increased to 37 mm Hg. The patient was discharged on acetazolamide 250 mg by mouth four times daily, brimonidine 0.2% three times daily right eye, Cosopt twice daily right eye, and pilocarpine 2% four times daily right eye.

The following day, the anterior chamber had deepened and the IOP was 24 mm Hg right eye. Gonioscopy revealed a closed angle (Fig 1). Pilocarpine 2% was instilled and a laser iridotomy performed right eye. The following day the IOP was 16 mm Hg right eye. Gonioscopy revealed a grade 2 angle. Acetazolamide was discontinued, pilocarpine 4% four times daily right eye, brimonidine 0.2% three times daily right eye, and Cosopt twice daily right eye were continued.

Two months later, the anterior chambers were deep and the angles were grade 3 in both eyes. IOP was 14 mm Hg right eye on pilocarpine 4% four times daily and Timoptic XE four times daily 0.5% IOP on subsequent visits remained below 20 mm Hg, and the angle remained open (Fig 2). Visual acuity did not improve.

#### COMMENT

Transient angle closure glaucoma, an infrequent sequela of CRVO, has not been reported following hemiretinal vein occlusion (HRVO). Angle closure may occur days to months following a CRVO. Neovascular glaucoma may develop weeks or months following a retinal vascular occlusion. Elevated IOP



Figure 1 Gonioscopy, no angle structures seen in the right eye.



Figure 2 Gonioscopy, angle open to scleral spur with lightly pigmented trabecular meshwork, left eye.

during an acute attack of primary pupillary block angle closure glaucoma can lead to a retinal vascular occlusion. Risk factors for CRVO and HRVO include systemic hypertension and diabetes mellitus. A history of glaucoma has been associated with CRVO, HRVO, and branch retinal vein occlusion (BRVO).<sup>1</sup>

The patient in this report developed angle closure glaucoma within a few weeks of the HRVO. He had a history of systemic hypertension. Elevated IOP was noted in both eyes on initial examination. Cycloplegic agents increased the IOP, suggesting the angle closure was not due to a ciliary block mechanism. Pilocarpine and a laser iridotomy reduced the IOP and opened the angle in this patient, suggesting a secondary pupillary block mechanism. At the time of diagnosis of angle closure glaucoma the contralateral eye had a deep anterior chamber and a wide open angle, making a diagnosis of primary pupillary block angle closure glaucoma unlikely.

Previous reports of angle closure glaucoma secondary to central retinal vein occlusion suggest treatment with cycloplegic/mydriatic agents is beneficial in some patients.<sup>2</sup> Miotic agents have been reported to be of benefit in cases of angle closure glaucoma following a CRVO.<sup>3</sup>

Determining the mechanism of angle closure in an individual patient following a retinal vascular occlusion will guide the ophthalmologist to the appropriate treatment options, mydriatic or miotic therapy. Ultrasound biomicroscopy may be of benefit in differentiating between a ciliary block mechanism<sup>4</sup> and a pupillary block mechanism.<sup>5</sup>

Supported in part by grant EY01867 from the National Eye Institute, National Institutes of Health, Bethesda, MD, an unrestricted grant from Research to Prevent Blindness Inc, New York, and the Louis and Rachel Rudin Foundation, Inc, New York, NY, USA.

DEMETRIOS HALIKIOPOULOS  
JANET B SERLE

Department of Ophthalmology, Mount Sinai School of  
Medicine of New York University, New York, USA

Correspondence to: Janet B Serle, MD, Box 1183, Mount Sinai School of Medicine, One Gustave L Levy Place, New York, NY 10029, USA  
janet.serle@mssm.edu

Accepted for publication 17 May 2001

- 1 Sperduto RD, Hiller R, Chew E, et al. Risk factors for hemiretinal vein occlusion: comparison with risk factors for central and branch retinal vein occlusion. *Ophthalmology* 1998;105:765-71.
- 2 Phelps CD. Angle-closure glaucoma secondary to ciliary body swelling. *Arch Ophthalmol* 1974;92:287-90.
- 3 Grant W. Shallowing of the anterior chamber following occlusion of the central retinal vein. *Am J Ophthalmol* 1973;75:384-9.
- 4 Trope GE, Pavlin CJ, Bau A, et al. Malignant glaucoma: clinical and ultrasound biomicroscopic features. *Ophthalmology* 1994;101:1030-5.
- 5 Aslanides IM, Libre PE, Silverman RH, et al. High frequency ultrasound imaging in pupillary block glaucoma. *Br J Ophthalmol* 1995;79:972-6.

#### Varicella zoster virus immune recovery stromal keratitis in a patient with AIDS

EDITOR.—The advent of potent antiretroviral therapy has resulted in the recognition of the syndrome of immune recovery uveitis in patients with AIDS and a history of cytomegalovirus (CMV) retinitis.<sup>1</sup> Although the pathogenesis of this disease is poorly understood, it is hypothesised to be a consequence of an improved immune response to viral antigen

already present in the eye, with or without active viral replication.<sup>2</sup> We describe a case of immune recovery varicella zoster virus (VZV) stromal keratitis in a patient with AIDS.

#### CASE REPORT

A 37 year old man with AIDS (CD4 = 180 cells  $\times$  10<sup>6</sup>/l) developed right sided ophthalmic zoster and was treated with aciclovir (800 mg by mouth five times a day). Twelve days after onset of the rash, topical prednisolone acetate (one drop every 2 hours) was prescribed to treat multiple anterior stromal corneal infiltrates. The keratitis promptly resolved, and the corticosteroid drops were discontinued within 3 weeks. Over the next 5 months his cornea remained clear, but his HIV disease progressed with the CD4 count dropping to a nadir of 88 cells  $\times$  10<sup>6</sup>/l. He was started on potent antiretroviral therapy and prophylactic aciclovir 400 mg by mouth twice daily. His cornea remained clear for the next 2 years, but as his CD4 reached 398 cells  $\times$  10<sup>6</sup>/l, he presented with a complaint of redness of his right eye. On examination he had multiple anterior stromal infiltrates of his right cornea, similar in appearance to the keratitis associated with the previous episode of ophthalmic zoster (Fig 1). The recurrence of stromal keratitis occurred 2½ years after discontinuation of topical steroids and while the patient was taking aciclovir prophylaxis.

#### COMMENT

VZV associated anterior stromal keratitis is thought to be due to immune recognition of residual viral antigen in the corneal stroma.<sup>3</sup> The incidence of recurrent VZV stromal keratitis has not been well characterised, nor have factors which might precipitate recurrences. Recurrent keratitis related to immune system activation has been recognised following adenoviral infection.<sup>4</sup> In that case, subepithelial opacities associated with a previous

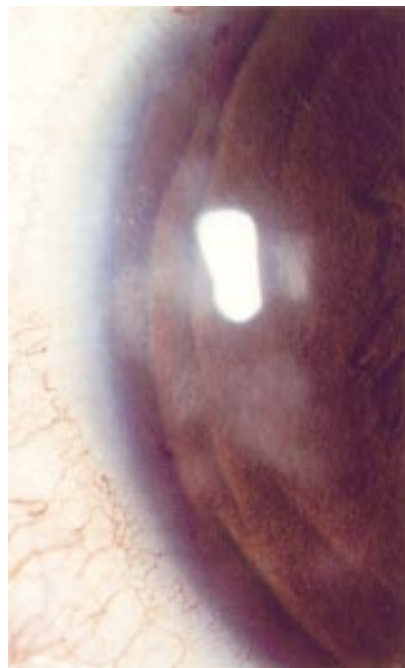


Figure 1 Slit lamp photograph of the temporal aspect of the patient's right eye shows stromal infiltrates with an intact corneal epithelium.

adenoviral follicular, keratoconjunctivitis recurred 9 months following the original infection in association with a severe upper respiratory infection. In this report, a patient with AIDS and a history of ophthalmic zoster had a recurrence of anterior corneal stromal infiltrates almost 3 years after the initial skin eruption. Recurrence of the keratitis was not associated with skin or corneal epithelial disease and occurred despite aciclovir prophylaxis. Although the recurrence of the keratitis with this patient's immune recovery may be coincidental, the significant delay between his initial zosteriform eruption and the recurrence of his stromal disease, as well as the close temporal relation between the recurrence and the patient's immune recovery, suggest that this is a case of immune recovery zoster keratitis in a patient with ophthalmic zoster.

Other examples of immune recovery disease in patients with AIDS receiving potent antiretroviral therapy are well recognised. Immune recovery uveitis has been described in patients with previous CMV retinitis.<sup>1,2</sup> In addition, immune recovery inflammation has been seen in association with previously clinically silent systemic *Mycobacterium avium* complex infection and in patients with cryptococcal meningitis.<sup>5,6</sup> In at least one of the cases of meningitis, immune recovery inflammation was thought to be directed against residual cryptococcal antigen, as opposed to a delayed immune response to viable organisms. As advances in AIDS therapy continue to improve the immune status of patients, immune recovery inflammation may become increasingly recognised.

TPM is the recipient of a Research to Prevent Blindness (NY, NY) Lew Wasserman Award.

AYMAN NASERI  
TODD P MARGOLIS

The Francis I Proctor Foundation and the Department of Ophthalmology, UCSF, Medical Center, San Francisco, USA

Correspondence to: Dr Todd P Margolis, The Francis I Proctor Foundation, UCSF, Medical Center, San Francisco, CA, 94143-0944, USA  
tpms@jitsa.ucsf.edu

Accepted for publication 15 June 2001

- Zegans ME, Walton RC, Holland GN, *et al.* Transient vitreous inflammatory reactions associated with combination antiretroviral therapy in patients with AIDS and cytomegalovirus retinitis. *Am J Ophthalmol* 1998;125:292-300.
- Holland GN. Immune recovery uveitis. *Ocular Immunology and Inflammation* 1999;7:215-21.
- Liesgang TJ. Corneal complications from herpes zoster ophthalmicus. *Ophthalmology* 1985;92:316-24.
- Hodge W, Wohl T, Whitcher JP, *et al.* Corneal subepithelial infiltrate recurrence sine adenovirus. *Cornea* 1995;14:324-5.
- Race EM, Adelson-Mitty J, Krieger GR, *et al.* Focal mycobacterial lymphadenitis following initiation of protease-inhibitor therapy in patients with advanced HIV-1 disease. *Lancet* 1998;351:252-5.
- Woods ML, MacGinley R, Eisen DP, *et al.* HIV combination therapy: partial immune restitution unmasking latent cryptococcal infection. *AIDS* 1998;12:1491-4.

#### *Dipetalonema reconditum* in the human eye

EDITOR.—Human ocular invasion by non-human filarial parasites has been reported for more than 200 years.<sup>1,2</sup> However, only just over a handful have actually been removed, described and identified in detail.<sup>3-6</sup> Furthermore, the *Dipetalonema* species that have been described in three cases were thought to be from the body cavity of the natural hosts—the porcupine and the beaver.<sup>4,5,7,8</sup>

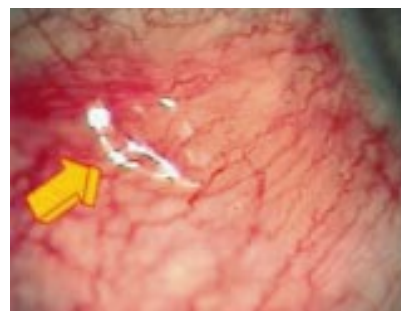

Figure 1 Subconjunctival infestation with *D reconditum* (arrow).

This report describes a case of *Dipetalonema reconditum* (usually associated with canine filariasis) in the human eye. It is noteworthy that this worm has morphological similarities to the canine heartworm *Dirofilaria immitis*, which in the past has been described in the human eye<sup>9</sup> but not satisfactorily identified.<sup>10</sup>

#### CASE REPORT

A 62 year old white resident of suburban Victoria, Australia, presented with a red and irritated right eye of 2 weeks' duration. This was exacerbated after a rural walking trip and did not improve with topical lubrication. He also noted mild diplopia on extreme right gaze. On examination, the visual acuity was 6/6 in the right eye and 6/4 in the left. There was mild limitation of right eye abduction. Localised bulbar conjunctival erythema and chemosis were noted inferotemporally in the right eye near the insertion of the lateral rectus. Slit lamp biomicroscopy revealed a slithering, clear, thread-like mobile mass in the subconjunctival space of the inflamed area (Fig 1 and video report (see *BjO* website)). Intraocular pressure and the rest of the ocular examination, including anterior and posterior segments, were unremarkable. Previous history included pyrexia of unknown origin (PUO) and lancinating headaches 5 months previously. Investigation results then of note included erythrocyte sedimentation rate (ESR) 96 mm in the first hour, C reactive protein (CRP) 411 mg/l, and trace proteinuria. He improved on intravenous ceftriaxone, metronidazole, and oral roxithromycin. He had also had another period of PUO and suffered with chronic *Giardia* infection.

The worm was removed following localised peritomy under topical local anaesthesia using lignocaine 2%, phenylephrine 10%, and phospholine iodide 12.5% (in an attempt to paralyse the worm). The specimen was removed alive and intact and sent in normal saline for identification. Laboratory examination revealed a worm measuring 32 mm in length with morphological features consistent with an unfertilised adult female *D reconditum*.

Patient investigations including thick and thin blood film, full blood count, ESR, CRP electrolytes, liver function tests, and chest x ray were all within normal limits. His pet dogs were found to be serologically negative for *Dipetalonema*.

He was treated with oral mebendazole, topical prednisolone acetate 1%, and chloramphenicol before the worm's identification. Two weeks following removal of the worm the diplopia had resolved and residual fibrosis of the conjunctiva at the site of removal was noted.

#### COMMENT

*Dipetalonema reconditum* is a nematode that is commonly found to be endemic in dogs' subcutaneous tissues. Worldwide distribution



includes the United States, Italy, and Africa. Its infestation in dogs, the only definitive host, is not clinically significant, although they may manifest an elevated eosinophil and leucocyte count. This manifestation may result in false positives in test for circulating *Dirofilaria immitis* microfilariae, also known as the dog heartworm. The differentiation of these two worms is important as *Dirofilaria* is pathogenic to canines. Knott's test<sup>11</sup> is used to detect these microfilaria serologically. Identification of these two adult worms is by their staining patterns with acid phosphatase: *Dipetalonema* stains evenly while *Dirofilaria* concentrates the acid phosphatase in two regions.

The *Dipetalonema reconditum* microfilarium averages about 250–270 µm in length and 4–4.5 µm in width with a round curved body, a distinguishing cephalic hook, and a blunt anterior end. Adult males average 13 mm in length and females 17–32 mm.<sup>12</sup>

*Dipetalonema* has an indirect life cycle with development of infective larvae that are carried by fleas (genus *Ctenocephalides*, *Pulex*), ticks (*Rhipicephalus sanguineus*), and lice (*Linognathus*). Dogs are infected when bitten by the fleas. The microfilarium circulates in the blood as a first stage larva. The larval life cycle lasts 61–68 days. The adult worm tends to infect the subcutaneous tissues.<sup>12</sup> Other less common sites of infestation include the body cavities and the kidneys.

Our case represents human subconjunctival infestation with an adult unfertilised *D reconditum*; this is, to our knowledge, the first report in the literature. The literature reveals three other documented cases of *Dipetalonema* species infestation in the human eye; however, none of them was *D reconditum*. The chronic nature and slow onset of the symptoms implies that this infestation excited a slow and limited inflammatory reaction within the ocular tissues.

There is no documented treatment for this infestation; ivermectin and milbemycin are recommended. Other control measures include flea, louse, and tick control. Hitherto, there has not been any documented public health significance. The incidence of *D reconditum* infestation in Australian dogs has significantly decreased since the introduction of the heartworm prevention programme as the treatment for *D immitis* also eliminates the *D reconditum*. As the serology in our patient's dogs was negative for *D reconditum*, one can postulate he was infected via a flea bite in his rural walking; however, we have no confirmative history. There is no documentation of the incidence of *D reconditum* in the Australian wildlife. As it is a self limiting condition, the definitive treatment is removal of the worm.

The authors thank Dr Harsha Sheorey, microbiologist at St Vincent's Hospital, Melbourne, for his help in identifying the organism.

T HUYNH  
J THEAN

Royal Victorian Eye and Ear Hospital, Melbourne,  
Australia

R MAINI

Centre for Eye Research Australia

Correspondence to: Dr T Huynh, Royal Victorian Eye and Ear Hospital, 32 Gisborne Street, East Melbourne, Victoria 3002, Australia

Accepted for publication 14 August 2001

- 1 Duke-Elder S, Perkins ES. Diseases of the uveal tract. *System of ophthalmology*. London: Henry Kimpton, 1966:Vol 9.
- 2 Barkan A. A case of filarial medinensis in the anterior chamber. *Arch Ophthalmol Otolaryngol* 1876;5:151.
- 3 Vodovozov AM, Jarulin GR, Djakonowa SW. *Dirofilaria im* Glaskörper des Menschen. *Ophthalmologica* 1973;166:88–93.

- 4 Burns RF, Helzerman R, Patrick M, et al. Intraocular filariasis (a motion picture). *Trans Am Acad Ophthalmol Otolaryngol* 1975;70:785–8.
- 5 Beaver PC, Meyer EA, Jarroll EL, et al. *Dipetalonema* from the eye of a man in Oregon, USA. A case report. *Am J Trop Med Hyg* 1980; 29:367–72.
- 6 Samples JR, Beaver PC, Fraunfelder FT, et al. A technique for removal of filariasis of the anterior chamber. *Ophthalmic Surg* 1988;19:124–7.
- 7 Cooke CT. Nematode worm in the anterior chamber of the eye. *Trans Pacific Coast Ophthalmol Soc* 1938;23:141–7.
- 8 Jones LT, Jordan LW, Sullivan NP. Intraocular nematode worms—report of a case and review of the literature. *Arch Ophthalmol* 1938;20: 1006–12.
- 9 Moorehouse DE. *Dirofilaria immitis*: a cause of human intra-ocular infection. *Infection* 1978;6: 192–3.
- 10 Dissanaik AS, Ramalingam S, Fong A, et al. Filariasis in the vitreous of the eye of man in peninsula Malaysia. *Am J Trop Med Hyg* 1977;26:1143–7.
- 11 Garcia LS, Bruckner DA. Procedures for detecting blood parasites. In: *Diagnostic medical parasitology*. American Society for Microbiology. 3rd ed. Santa Monica: Lynne Shore Garcia, ASM Press 1997:706.
- 12 *Internal parasites of dogs and cats: diagnostic manual*. Ciba-Geigy, p 3.

## Website extra

A video report is on the BJO website. It shows the undulating appearance of the right bulbar conjunctival surface in a 62 year old white male as the *Dipetalonema reconditum* remains mobile immediately before removal following localised peritomy

www.bjophthalmol.com

## Immunohistochemical detection of heat shock protein 27 and Ki-67 in human pterygium

EDITOR.—Pterygium, a disorder of the ocular surface, consists of atrophic conjunctival epithelium and a highly vascularised hypertrophic and elastotic degenerated connective tissue. Ultraviolet irradiation is considered to be the principal environmental factor through an effect on the basal stem cells on the nasal limbus and activation of the fibroblasts.<sup>1–3</sup> Previous studies have detected chromosomal allelic loss in slightly over 50% of pterygia and a low frequency of microsatellite instability.<sup>4</sup> However, no differences in cellular proliferation between pterygial and normal conjunctival tissue have been detected with flow cytometry.<sup>5</sup> On the other hand, a recent report suggests that pterygium may be the result of a failure of appropriate cellular apoptosis.<sup>6</sup> We studied 17 pterygia and 12 normal conjunctiva tissues from the nasal conjunctiva for the expression of heat shock protein 27 (Hsp27) and cell proliferation associated nuclear antigen Ki-67.

Hsp27, a member of the small heat shock proteins family, is overexpressed in response to many environmental and pathophysiological stresses including ultraviolet radiation, hormones, growth factors, infection and anoxia, and may be important in surveillance of cell integrity acting as a “molecular chaperone.”<sup>7</sup> Recently it has been found that Hsp27 constitutive overexpression in embryonic stem cells enhances the differentiation mediated decreased rate of cell proliferation and prevents these cells from undergoing apoptosis.<sup>8</sup>

Specimens from 17 patients (seven males and 10 females) (mean age 73.6) undergoing primary pterygium excision and 12 healthy people (three male and nine female) (mean age 77.7) undergoing cataract surgery were studied. None of these patients had an

ophthalmic or systemic disease or used topical or systemic medication. Informed consent was obtained from patients participating in this study. Formalin fixed, paraffin embedded serial sections were immunostained using monoclonal antibodies against Hsp27 (clone G3.1) and Ki-67 (clone MIB-1). Morphological assessment of immunostained tissue preparations and manual cell counting of immunolabelled cells were performed. Hsp27 and Ki-67 labelled cell fractions were expressed in percentages.

Hsp27 cytoplasmic immunoreactivity was observed only in basal and suprabasal layers of normal conjunctival epithelium (mean 36.7) (Fig 1A). On the other hand, strong Hsp27 immunopositivity in a high percentage of cells in all layers of epithelium was found in all pterygia examined in this study (mean 88.1) (Fig 1B, Table 1). Ki-67 immunoreactivity was confined in nuclei of scattered cells, located mostly in the basal layers of epithelium, in normal conjunctival epithelium (mean 5.2) as well as in pterygium (mean 9.4) (Table 1). No staining of Hsp27 and/or Ki-67 was observed in substantia propria in normal conjunctiva tissues and pterygia but in pterygia, Hsp27 strong immunoreactivity was observed in endothelial cells and smooth muscle cells of vessels. There was a statistically significant difference of Hsp27 immunoreactivity between normal conjunctival epithelium and pterygia ( $p < 0.001$ ) but no difference in Ki-67 immunoreactivity ( $p = 0.1$ ) although some pterygia contained large number of proliferative cells. There was no correlation between Hsp27 and Ki-67 labelling percentage in pterygia ( $p = 0.7$ ) and normal conjunctiva ( $p = 0.9$ ).

Our findings concerning Ki-67 expression are consistent with previous results suggesting that pterygium may not be a disorder of cell proliferation.<sup>5</sup> Overexpression of Hsp27 in all

Table 1 Immunohistochemical staining of epithelial cells for Hsp27 and Ki-67 in pterygia and normal conjunctiva

	Hsp27 immunoreactivity (% positive cells)	Ki-67 immunoreactivity (% positive cells)
Pterygia		
1	100	5
2	100	2
3	100	20
4	90	1
5	100	15
6	100	1
7	100	2
8	70	1
9	95	2
10	50	1
11	50	20
12	80	15
13	97	10
14	100	15
15	90	15
16	95	15
17	80	20
	Mean: 88.1 (SD 16.84)	Mean: 9.4 (SD 7.75)
Normal conjunctiva		
1	80	1
2	70	5
3	15	10
4	80	10
5	10	2
6	0	0
7	10	5
8	25	2
9	30	10
10	60	7
11	50	5
12	10	5
	Mean: 36.7 (SD 29.72)	Mean: 5.2 (SD 3.54)

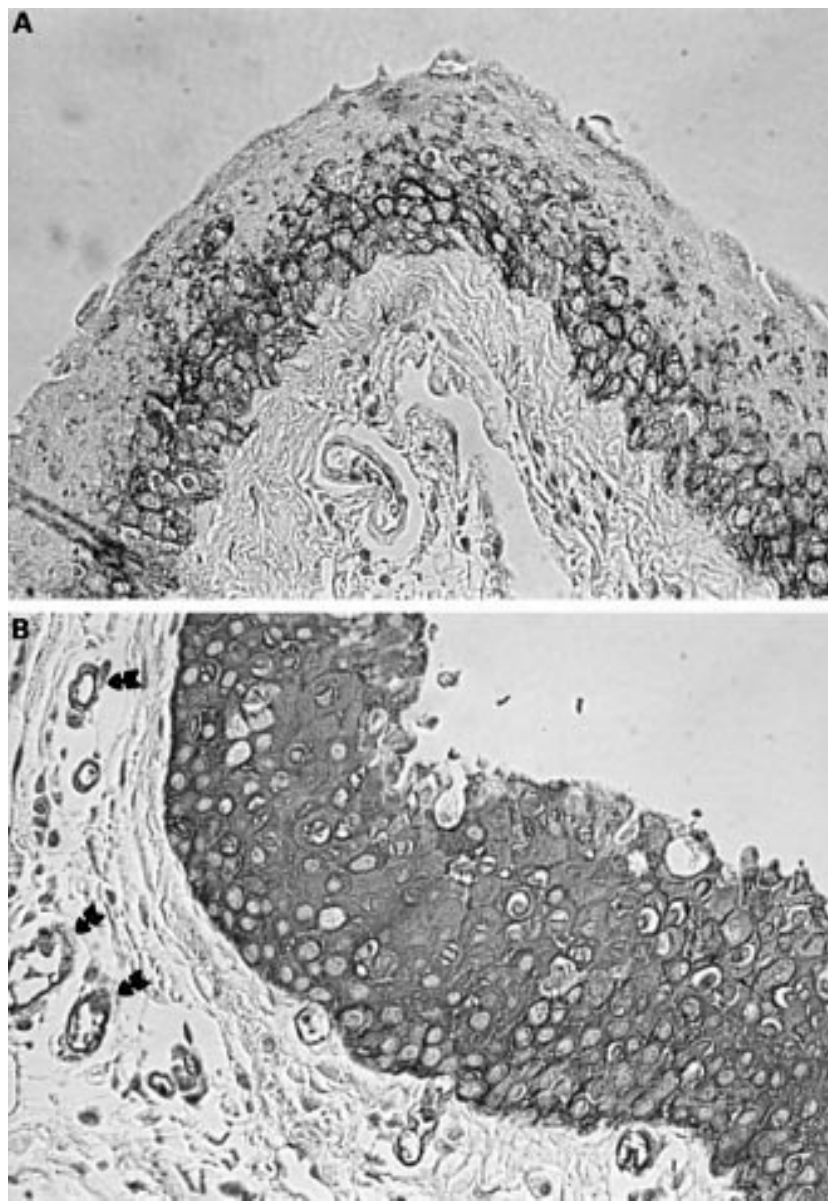


Figure 1 (A) Normal conjunctiva: Hsp27 cytoplasmic immunoreactivity in basal and subbasal layers of epithelium ( $\times 400$ ). (B) Pterygium: Hsp27 positive cells in all layers of epithelium. Cells of subepithelial connective tissue are Hsp27 negative while vessels are Hsp27 positive (arrows) ( $\times 400$ ).

pterygia is interesting because this protein is known to be related to differentiation when expressed in other epithelial tissues—for example, skin,<sup>9</sup> and in view of the recent report that Hsp27 transient expression seems essential for preventing embryonic stem cells from undergoing apoptosis.<sup>8</sup> Furthermore, Tan *et al*<sup>9</sup> recently proposed that pterygium may be related to faulty apoptosis. The role of Hsp27 in pterygium remains to be elucidated since Hsp27 is expressed in basal epithelial cells of normal conjunctiva, where the cells are mainly differentiating stem cells and in all layers of epithelium in pterygia. Further studies would provide valuable information regarding the possible role of Hsp27, and the involvement of heat shock proteins generally in the pathogenesis of pterygium.

NIKOLAOS PHARMAKAKIS

Department of Ophthalmology, School of Medicine,  
University of Patras, Patras 26500, Greece

MARTHA ASSIMAKOPOULOU

Department of Anatomy, School of Medicine,  
University of Patras

Correspondence to: Nikolaos Pharmakakis, MD,  
Department of Ophthalmology, School of Medicine,  
University of Patras, 26500 Greece  
npharmak@med.upatras.gr

Accepted for publication 14 March 2001

- 1 Moran DJ, Hollands FC. Pterygium and ultraviolet radiation: a positive correlation. *Br J Ophthalmol* 1984;**68**:343–6.
- 2 Kwok LS, Coroneo MT. A model for pterygium formation. *Cornea* 1994;**13**:219–24.
- 3 Dushku N, Reid TW. Immunohistochemical evidence that human pterygia originate from an invasion of vimentin-expressing altered limbal epithelial basal cells. *Curr Eye Res* 1994;**13**:473–81.
- 4 Spandidos DA, Sourvinos G, Kiaris H, *et al*. Microsatellite instability and loss of heterozygosity in human pterygia. *Br J Ophthalmol* 1997;**81**:493–6.
- 5 Karukonda SR, Thompson HW, Beuerman RW, *et al*. Cell cycle kinetics in pterygium at three latitudes. *Br J Ophthalmol* 1995;**79**:313–17.
- 6 Tan DTH, Tang WY, Liu YP, *et al*. Apoptosis and apoptosis related gene expression in normal conjunctiva and pterygium. *Br J Ophthalmol* 2000;**84**:212–16.
- 7 Ciocca DR, Oesterreich S, Chamness GC, *et al*. Biological and clinical implications of heat shock protein 27000 (HSP27): a review. *J Natl Cancer Inst* 1993;**85**:1558–70.
- 8 Mehlen P, Mehlen A, Godet J, *et al*. Hsp27 as a switch between differentiation and apoptosis in murine embryonic stem cells. *J Biol Chem* 1997;**272**:31657–65.
- 9 Jantschitsch C, Kindas-Mugge I, Metzke D, *et al*. Expression of the small heat shock protein HSP27 in developing human skin. *Br J Dermatol* 1998;**139**:247–53.