

# Outcome after silicone oil removal

Christiane I Falkner, Susanne Binder, Andreas Kruger

## Abstract

**Background**—Combined with vitreoretinal surgery, silicone oil injection has become a standard technique and improves the prognosis of complex retinal detachment. As silicone oil leads to long term complications, removal of silicone oil from the eye is recommended. To evaluate the outcome after silicone oil removal, retinal redetachment, visual acuity, and complications were analysed.

**Methods**—The authors analysed 115 consecutive cases of silicone oil removal (115 eyes), all operated by one surgeon. The series consisted of retinal detachments associated with proliferative vitreoretinopathy (103 eyes), proliferative diabetic retinopathy (six eyes), or ocular trauma (six eyes). The mean duration of intraocular silicone oil tamponade was 13.3 months, with a mean postoperative follow up of 1.8 years.

**Results**—Anatomic success after silicone oil removal, defined as a complete retinal attachment, was achieved in 95 of 115 eyes (82.6%). Redetachment occurred in 20 eyes (17.4%), mostly within the first 6 months after silicone oil removal. Including the successfully reoperated eyes, the authors present a final anatomic success rate of 108 eyes (93.9%). Visual acuity improved or remained unchanged in 93 eyes (80.9%).

**Conclusion**—While reattachment and complication rates were quite similar to other studies, a better visual outcome was achieved in these cases. The duration of the silicone oil tamponade had no significant effect on the reattachment rate. The authors recommend not to apply standard criteria for the timing of silicone oil removal, but to decide individually, considering the underlying disease, as well as the previous operations.

(Br J Ophthalmol 2001;85:1324-1327)

The use of silicone oil for the treatment of otherwise inoperable retinal detachments was first described by Cibis *et al* in 1962.<sup>1</sup> Scott<sup>2</sup> and Zivojnovic<sup>3</sup> modified this technique, and encouraging results were reported by many other surgeons.<sup>4-8</sup> Combined with vitreoretinal surgery, silicone oil injection has become a standard technique and improves the prognosis of complex retinal detachment associated with proliferative vitreoretinopathy, giant retinal tears, proliferative diabetic retinopathy, or ocular trauma. Compared with sulphur hexafluoride gas (SF<sub>6</sub>) as an intraocular tamponade for the management of retinal detachment, eyes treated with silicone oil were more likely

to be successfully reattached, to achieve a better visual acuity, and to have fewer postoperative complications.<sup>9-11</sup> However, silicone oil leads to long term complications particularly cataract, glaucoma, and keratopathy.<sup>5 7 12 13</sup> Therefore several authors have recommended the removal of silicone oil from the eye as soon as a stable retinal situation is achieved.<sup>14-17</sup> Silicone oil removal is a procedure that carries a definite risk of retinal redetachment, due to reproliferation of epiretinal membranes and increasing traction on the retina. In this report we present the results of 115 eyes that underwent modern pars plana vitrectomy and silicone oil removal. Visual acuity, the incidence and development of complications like cataract, hypertony or hypotony, keratopathy, and retinal detachment were analysed to evaluate the outcome after silicone oil removal.

## Patients and methods

We reviewed the records of 115 eyes of 115 consecutive patients who underwent silicone oil removal between 1989 and 1999. All surgery was performed by one surgeon (SB). This series included 54 male patients (47%) and 61 female patients (53%). The average age of the patients at the time of surgery was 54.9 years, with the range between 13 and 83 years.

The indications for the use of silicone oil were complex retinal detachments associated with proliferative vitreoretinopathy (103 eyes, 89.2%), proliferative diabetic retinopathy (six eyes, 5.4%) or ocular trauma (six eyes, 5.4%). Cases with proliferative vitreoretinopathy (PVR) showed various secondary diagnoses (Fig 1). The PVR grading of our early cases was done according to the Retina Society classification of 1983.<sup>18</sup> This group consisted of 66 eyes, with three eyes graded C3 and 63 eyes graded D. The other 37 eyes were graded according to the updated classification by Machemer *et al*.<sup>19</sup> In this group we found nine cases graded C1, nine cases C2, and 19 cases C3. All patients had previously undergone pars plana vitrectomy combined with dissection of epiretinal membranes, intraocular silicone oil injection, and argon laser endophotocoagulation. In some cases additional perfluorocarbon installation was performed. As a standard procedure in our clinic, aphakic eyes received inferior peripheral iridectomies to prevent pupillary block glaucoma. All eyes had been filled with highly purified silicone oil with a viscosity of 5000 centistokes. Many patients, particularly those with proliferative vitreoretinopathy, had had other surgical procedures before the silicone oil injection. Some of these procedures were not administered in our clinic and therefore could not be reviewed. The duration of intraocular silicone oil tamponade ranged from 1 month to 96 months, with a mean of 13.3

The Ludwig Boltzmann Institute of Retinology and Biomicroscopic Lasersurgery, Department of Ophthalmology, Rudolf Foundation Clinic, Juchgasse 25, A 1030 Vienna, Austria  
C I Falkner

Department of Ophthalmology, Rudolf Foundation Clinic, Juchgasse 25, A 1030 Vienna, Austria  
S Binder

Department of Ophthalmology, Vienna General Hospital, Währingergürtel 18-20, A 1090, Vienna, Austria  
A Kruger

Correspondence to:  
Christiane I Falkner, MD  
a9101872@unet.univie.ac.at

Accepted for publication  
16 April 2001

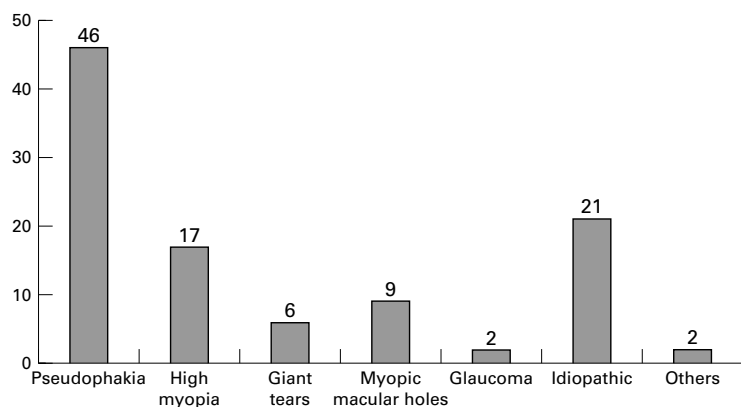


Figure 1 Secondary diagnoses of the proliferative vitreoretinopathy cases.

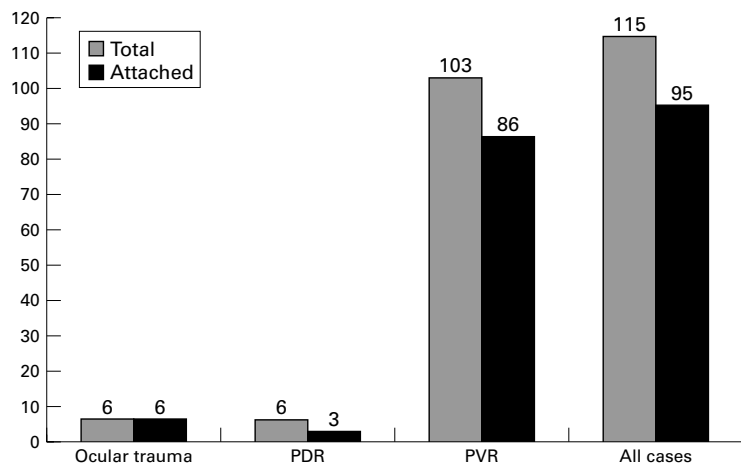


Figure 2 Attachment rate after silicone oil removal (PDR = proliferative diabetic retinopathy; PVR = proliferative vitreoretinopathy).

months. The criteria for silicone oil removal were a complete and stable attached retina within the encircling buckle and no active proliferative process or traction on the retina.

The oil was removed in vitrectomy technique via two sclerotomies under the binocular ophthalmoscope and under fundus control. A vacuum pump was used in all cases. In 11 cases silicone oil removal was combined with cataract extraction and intraocular lens implantation. All patients had ocular examinations before silicone oil removal, postoperatively and at each follow up visit. These examinations included best corrected visual acuity testing using a Snellen eye chart, measurement of intraocular pressure, slit lamp biomicroscopy, and fundus control with direct (three mirror contact lens) and indirect ophthalmoscopy. There was a mean postoperative follow up period of 1.8 years, ranging from 6 months to 3.5 years.

## Results

Anatomic success after silicone oil removal, defined as a flat retina with complete retinal attachment anterior and posterior to the buckle for a minimum of 6 months, was achieved in 95 of 115 eyes (82.6%). Retinal detachments anterior to the buckle stabilised by laser coagulation were considered anatomic failures. Retinal redetachment occurred in 20 eyes (17.4%). While no redetachment was seen

in the six eyes with primary ocular trauma, 17 of 103 eyes (16.5%) suffering from proliferative vitreoretinopathy (PVR), and three of six eyes (50%) with proliferative diabetic retinopathy (PDR) presented retinal redetachment (Fig 2). The mean duration of silicone oil tamponade in the attached group was 14.2 months and in the redetached group 12.3 months. Using the unpaired two tailed *t* test we found no significant difference between the attached group and the redetached group regarding the duration of silicone oil tamponade ( $p = 0.82202$ ).

We additionally compared two groups defined by the duration of silicone oil tamponade (group 1: silicone oil tamponade for less than 6 months; group 2: silicone oil tamponade for more than 6 months). Using the two tailed Fisher's exact test we found no significant difference ( $p = 0.70214$ ) in the numbers of stable and redetached cases in these two groups.

However, we discovered a difference between the attached and the redetached group regarding the number of total operations. Including the available data of previous operations we found a mean of 3.4 operations (range 2–6) in the redetached group and a mean of 1.8 operations (range 1–4) in the attached group.

Redetachments occurred mainly within the first 3 months. We found six redetachments (30%) within the first postoperative month and another eight (40%) within 3 months after silicone oil removal. Five patients (25%) developed a redetachment after 6 months and only one patient (5%) after 16 months. All 20 eyes were reoperated. In 15 eyes revision surgery consisted of vitrectomy with replacement of silicone oil. Vitrectomy with temporary perfluorocarbon installation and intraocular gas injection was successfully performed in three eyes, cryotherapy and additional scleral buckling in two cases. A stable reattached retina was achieved in 13 of these 20 eyes (65%), while seven eyes (35%) remained uncured. Including the successfully reoperated eyes, we present a final anatomic success rate of 93.9% (108 of 115 eyes).

Cataract formation was observed in 44 of 68 phakic eyes (64.7%), mostly within the first postoperative year. In 34 eyes cataract extraction and implantation of a posterior chamber lens was performed. In 11 of these patients cataract surgery was combined with silicone oil removal to improve the functional rehabilitation.

During silicone oil tamponade, elevated intraocular pressure (IOP), higher than 21 mm Hg, occurred in 54 eyes (46.9%). After silicone oil removal, these temporary changes normalised in all but 14 patients (12.2%), who developed secondary glaucoma. Eight eyes were treated successfully with antiglaucomatous medication and six eyes needed a surgical procedure. A temporary hypotony with an IOP of less than 8 mm Hg was seen in four patients (3.5%).

Nine eyes (7.8%) demonstrated a postoperative keratopathy. In seven of these eyes, the keratopathy disappeared within a few weeks,

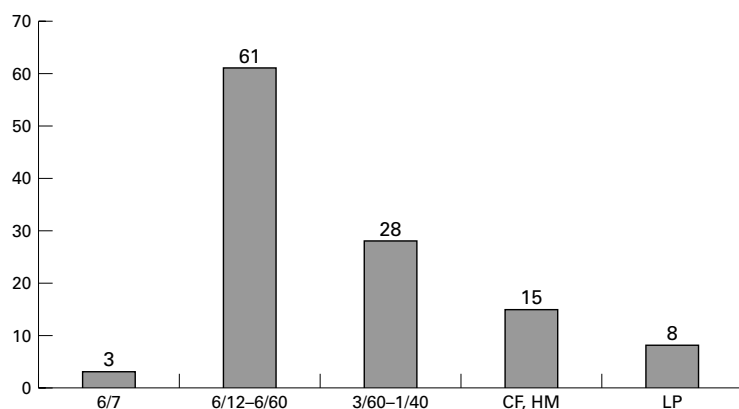


Figure 3 Visual acuity at the last follow up examination (Snellen eye chart).

whereas the remaining two eyes required a penetrating keratoplasty. Other complications were intravitreal haemorrhage in five eyes (4.3%), optic atrophy in four eyes (3.5%), and phthisis in one eye (0.9%). No enucleation for intractable chronic ocular pain was necessary.

To analyse the course of visual acuity (VA) we compared the mean best corrected VA during silicone oil tamponade (6/60) with the mean best corrected VA at the last follow up visit (6/30). An increase of VA was combined with continued improvement in retinal function after successful retinal reattachment, cataract extraction, and reduced optical effects of the silicone oil bubble after oil removal. Eyes were only graded as improved or deteriorated when VA changed two or more lines using the Snellen eye chart. VA following silicone oil removal, including eyes with retinal redetachment, improved in 62 cases (53.9%), remained unchanged in 31 eyes (27%), and worsened in 22 eyes (19.1%). The visual loss was related to the development of retinal redetachment, cataract, glaucoma, optic atrophy, keratopathy, vitreous haemorrhage, or a combination of two or more of these complications. The final functional success rate with a minimum visual acuity of 1/40 was achieved in 92 patients (80%). At the last follow up visit three patients (2.6%) had a visual acuity of 6/7, 61 patients (53%) a VA between 6/12 and 6/60, and 28 patients (24.4%) showed a VA between 3/60 and 1/40. In 15 patients (13%) the VA was counting fingers and hand movements and in eight patients (7%) light perception (Fig 3).

### Discussion

The reported incidence of redetachment varies between 0% and 32%.<sup>4-8 12 14-17 20-25</sup> This variation is most probably due to marked differences in the number of eyes studied, the duration of follow up after silicone oil removal, and the underlying diseases. In our series retinal redetachment after silicone oil removal occurred in 20 of 115 eyes (17.4%), while the final anatomic failure rate was 6.1%. Other authors report similar results<sup>6 21 25</sup> or higher failure rates.<sup>26</sup> No conclusions can be drawn from the high rate of redetachments in our PDR group because of the small number of cases.

Rates of anterior segment complications described in literature range from 34.5% to 100% regarding cataract formation,<sup>5-7 12 14 15 17 22 26 27</sup> and from 1.5% to 27.7% regarding elevated IOP.<sup>4-7 11-17 20 21 27 28</sup> These results are comparable with our findings (cataract 64.7%, elevated IOP 12.2%).

Rates of keratopathy were reported to range from 4.5% to 63%<sup>4-8 12 14-17 22 27 28</sup> while rates of hypotony vary between 5% and 51.4%.<sup>4 6 8 14-16 21 22 27</sup> Regarding these numbers, our rates definitely lie within the lower segment (keratopathy 7.8%, hypotony 3.5%).

A better visual outcome was achieved in our study. We had more patients with 6/60 or better postoperative VA than reported by others<sup>4 5 16</sup> and more patients had an increased or unchanged VA at the last follow up visit.<sup>8 17 21 22 27 28</sup> Stolba *et al* stated that a VA between 6/60 and 6/20 is essential for total or partial binocularity.<sup>29</sup> This range of VA was achieved in 63 of our 115 cases (54.8%). Cataract extraction and atraumatic surgery, paying special attention to the foveal area, may be reasons for the good functional outcome.

The optimal timing for the silicone oil removal still remains unknown and recommendations range from 3 to 6 months of sustained retinal attachment.<sup>15 16</sup> In our series the duration of the silicone oil tamponade had no significant effect on the reattachment rate. We have no fixed time limit for silicone oil removal. We prefer to have the oil removed in all patients, but we do not enforce removal if the retina cannot be stabilised. We usually do not remove the oil in unsuccessful cases with detached retinas unless uncontrollable IOP as a result of the silicone oil or other complications arises. A second silicone oil removal in these eyes would be associated with an increased risk of further redetachment, endless surgical interventions, and a loss of quality of life. We do not expect an improvement of VA but a further loss of function.

Three to 6 months after silicone oil removal, retinal redetachment generally becomes unlikely.<sup>8 14 15 21-24</sup> This is important for scheduling re-examinations of the patients and we therefore recommend close meshed controls after silicone oil removal—postoperatively, within the first week, every 2 weeks within the first 3 months, every 3–6 weeks within the following 3 months, and afterwards every 6 months. This way, redetachments after silicone oil removal can be discovered early and brought under control in time. Incompletely attached retinas can be stabilised without silicone oil reinstallation by using extensive laser photocoagulation, encircling bands, or intraocular gas tamponade.

PVR, the major complication of retinal detachment surgery, remains an unsolved problem. The Daunomycin Study Group examined the efficacy of intraoperative application of daunorubicin in eyes with idiopathic PVR. Daunorubicin is supposed to have a positive effect on the treatment of PVR by reducing the number of reoperations and increasing the reattachment rate.<sup>30</sup> To improve

the outcome of complicated retinal redetachment in eyes with PVR, more studies and research for drug combinations are necessary.

The success of silicone oil instillation seems to depend on the number and quality of previous vitreoretinal surgical procedures, as seen in our cases. Therefore, it is important to carefully evaluate indications for all vitreoretinal procedures and to opt for definite treatment.

In conclusion, we recommend not to search for standard criteria for the timing of silicone oil removal but to evaluate each single case individually. The underlying disease, as well as the previous procedures determine the stability of the retina. Close meshed and thorough follow up examinations, especially in the first 3 months, are crucial to identify early signs of reattachment. Although silicone oil tamponade is the best yet available procedure for the treatment of complicated retinal detachment, we hope that the pharmaceutical influence on proliferative vitreoretinopathy will be further evaluated.

- 1 Cibis PA, Becker B, Okun E, et al. The use of liquid silicone in retinal detachment surgery. *Arch Ophthalmol* 1962;68:590-9.
- 2 Scott JD. A rationale for the use of liquid silicone. *Trans Ophthalmol Soc UK* 1977;97:235-7.
- 3 Zivojinovic R, Mertens DA, Peperkamp E. Das flüssige Silikon in der Amotiochirurgie (II). Bericht über 280 Fälle-weitere Entwicklung der Technik. *Klin Monatsbl Augenheilkd* 1982;181:444-52.
- 4 McCuen BW, Landers MB, Machermer R. The use of silicone oil following failed vitrectomy for retinal detachment with advanced proliferative vitreoretinopathy. *Ophthalmology* 1985;92:1029-34.
- 5 Dimopoulos ST, Heimann K. Spätkomplikationen nach Silikonölinjektion. Langzeitbeobachtungen an 100 Fällen. *Klin Monatsbl Augenheilkd* 1986;189:223-7.
- 6 Luke K, Förster M, Laqua H. Langzeiterfahrungen mit intraokularer Silikonöl-Füllung. *Fortschr Ophthalmol* 1987;84:96-8.
- 7 Federman JL, Schubert HD. Complications associated with the use of silicone oil in 150 eyes after retina-vitreous surgery. *Ophthalmology* 1988;95:870-6.
- 8 Azen SP, Scott IU, Flynn HW, et al. Silicone oil in the repair of complex retinal detachments. A prospective observational multicenter study. *Ophthalmology* 1998;105:1587-97.
- 9 The Silicone Study Group. Vitrectomy with silicone oil or sulfur hexafluoride gas in eyes with severe proliferative vitreoretinopathy: results of randomized clinical trial: Silicone Study Report 1. *Arch Ophthalmol* 1992;110:770-9.
- 10 Abrams GW, Azen SP, McCuen BW, et al. Vitrectomy with silicone oil or long acting gas in eyes with severe proliferative vitreoretinopathy: results of additional and long-term follow-up. Silicone Study report 11. *Arch Ophthalmol* 1997;115:335-44.
- 11 Hammer M, Margo CE, Grizzard WS. Complex retinal detachment treated with silicone oil or sulfur hexafluoride gas: a randomized clinical trial. *Ophthalmic Surg Lasers* 1997;28:926-31.
- 12 Binder S, Velikay M, Zügner M, et al. Zum Sekundärglaukom nach Silikonölimplantation: Indikation, Technik und Ergebnisse. *Spektrum Augenheilkd* 1988;2:224-7.
- 13 Lucke K, Strobel B, Förster M, et al. Sekundärglaukome nach Silikonölnchirurgie. *Klin Monatsbl Augenheilkd* 1990;196:205-9.
- 14 Casswell AG, Gregor ZJ. Silicone oil removal. I. The effect on complications of silicone oil. *Br J Ophthalmol* 1987;71:893-7.
- 15 Casswell AG, Gregor ZJ. Silicone oil removal. II. Operative and postoperative complications. *Br J Ophthalmol* 1987;71:898-902.
- 16 Zilis JD, McCuen BW, de Juan E, et al. Results of silicone oil removal in advanced proliferative vitreoretinopathy. *Am J Ophthalmol* 1989;108:15-21.
- 17 Franks WA, Leaver PK. Removal of silicone oil-rewards and penalties. *Eye* 1991;5:333-7.
- 18 The Retina Society Terminology Committee. The classification of retinal detachment with proliferative vitreoretinopathy. *Ophthalmology* 1983;90:121-5.
- 19 Machermer R, Aaberg TM, Freeman HM, et al. An updated classification of retinal detachment with proliferative vitreoretinopathy. *Am J Ophthalmol* 1991;112:159-65.
- 20 Pavlovic S, Dick B, Schmidt KG, et al. Langzeitergebnisse nach Silikonölnentfernung. *Ophthalmologie* 1995;92:672-6.
- 21 Bodanowitz S, Hesse L, Poller S, et al. Management of retinal redetachment following silicone-oil removal. *Ger J Ophthalmol* 1996;5:67-72.
- 22 Scholda C, Egger S, Lakits A, et al. Silicone oil removal: results, risks and complications. *Acta Ophthalmol Scand* 1997;75:695-9.
- 23 Larkin GB, Flaxel CJ, Leaver PK. Phacoemulsification and silicone oil removal through a single corneal incision. *Ophthalmology* 1998;105:2023-7.
- 24 Jonas JB, Budde WM, Knorr HL. Timing of retinal redetachment after removal of intraocular silicone oil tamponade. *Am J Ophthalmol* 1999;128:628-31.
- 25 Scholda C, Egger S, Lakits A, et al. Retinal redetachment after silicone oil removal. *Acta Ophthalmol Scand* 2000;78:182-6.
- 26 Gonvers M. Temporary silicone oil tamponade in the treatment of complicated diabetic retinal detachments. *Graefes Arch Clin Exp Ophthalmol* 1990;28:415-22.
- 27 Hörle S, Schmidt J, Kroll P. Vitreoretinale Chirurgie bei komplizierten Netzhautablösungen im Kindes- und Jugendalter. *Ophthalmologie* 2000;97:482-6.
- 28 Wedrich A, Binder S, Velikay M, et al. Funktionelle und anatomische Ergebnisse der Silikonölnchirurgie bei proliferativer diabetischer Retinopathie. *Spektrum Augenheilkd* 1992;6:8-12.
- 29 Stolba U, Binder S, Krebs I, et al. Visual rehabilitation after silicone oil removal. Poster presented at the "Club Jules Gonin" 1998.
- 30 Wiedemann P, Hilgers RD, Bauer P, et al. Adjunctive daunorubicin in the treatment of proliferative vitreoretinopathy: results of a multicenter clinical trial. Daunomycin Study Group. *Am J Ophthalmol* 1998;126:550-9.