

LETTERS TO THE EDITOR

Lid retraction in primary hepatocellular carcinoma

EDITOR.—We report an unusual case of severely symptomatic lid retraction with secondary corneal exposure in a patient with terminal hepatocellular carcinoma and no evidence of thyroid orbitopathy.

CASE REPORT

A 69 year old woman attending the eye clinic with primary open angle glaucoma complained of a 2 month history of sore eyes. She was already using gel tears for dry eyes, in addition to betaxolol and latanoprost for her glaucoma. Visual acuities were 6/9 in each eye unaided, improving to 6/6 with a pinhole. On examination she had marked bilateral, symmetrical lid retraction, lid lag, and some mild punctate corneal epithelial staining. She had no other features suggestive of thyroid orbitopathy, or of generalised thyroid dysfunction and no goitre. Her free thyroxine and thyroid stimulating hormone were normal.

Eight months earlier she had presented with a large epigastric mass and was found to have advanced primary hepatocellular carcinoma. She had a raised alkaline phosphatase (930 IU/l) and alanine aminotransferase (169 IU/l) and an iron deficient anaemia (haemoglobin

91g/l). Hypercalcaemia (corrected serum calcium 3.4 mmol/l) had been treated with rehydration and a pamidronate infusion 4 months previously. She was also taking prednisolone 5 mg twice daily, morphine sulphate, lansoprazole, metoclopramide, and codanthrusate.

Despite increasing the frequency of the gel tears her symptoms did not improve and 2 months later her vision had deteriorated to counting fingers (CF) in each eye (6/24 and 6/60 right and left with a pinhole). She had 2-3 mm of upper lid retraction, markedly reduced blink, lid lag on downgaze, 3 mm of lagophthalmos, and marked interpalpebral corneal staining (Figs 1 and 2). Vertical upgaze was slightly reduced bilaterally, but felt to be typical of that commonly seen in older patients rather than indicative of a gaze palsy. Saccades were slightly jerky, particularly on upgaze. Convergence retraction nystagmus was not demonstrated. Convergence was poor, as may be expected with markedly reduced vision. Smooth pursuit on downgaze and horizontal gaze was normal. Corneal sensation was reduced bilaterally.

The latanoprost was discontinued, simple eye ointment prescribed at night, in addition to the gel tears, and her relatives taught her how to tape the lids closed. Thermal occlusion of both lower puncta was also performed.

A month later her eyes were more comfortable but vision no better. The lubricants were changed to frequent simple eye ointment only and urgent lateral tarsorrhaphies and medial canthoplasties were performed as a palliative procedure. This led to a significant subjective improvement in vision, reduction in inflammation, and an improvement in the corneal appearance. Her overall condition had deteriorated, however, and she died 2 weeks later.

COMMENT

Bartley¹ has classified the causes of lid retraction as neurogenic, myogenic (including disorders affecting the neuromuscular junction), mechanical, and miscellaneous. It is generally accepted that thyroid orbitopathy is the commonest cause of acquired unilateral or bilateral lid retraction.² A minority of such patients may be both clinically and biochemically euthyroid.

The most likely cause of lid retraction in this case is either neurological or "miscellaneous". Thyroid orbitopathy was an unlikely diagnosis on clinical grounds and further investigations, such as orbital computed tomograph scanning and thyroid antibody testing, were deemed unnecessary.

Poor upgaze is common in older patients and the patient had no other features suggestive of Parinaud's dorsal midbrain syndrome (her poor convergence was felt not to be significant). Decreased blink rate and lid lag are seen in both progressive supranuclear palsy and in Parkinson's disease, together with "cogwheel" pursuit and slow, hypometric saccades. While the patient had rather jerky saccades, she had no other features suggestive of either condition and, in particular, had no parkinsonian features and normal downgaze.^{2,3}

Bilateral lid retraction and lid lag with minimal impairment of vertical gaze have been described with a circumscribed lesion involving the periaqueductal grey matter in the region of the nucleus of the posterior commissure (nPC).^{2,4} It is possible that the patient had a brain metastasis involving the nPC, although it should be noted that she had no other overt clinical evidence of this. The patient had not had neuroimaging of her

brain, and it was not appropriate to perform this in the terminal stages of her disease.

Eyelid retraction has also been reported in association with a number of conditions with an undetermined aetiological relation. An example is the association with hepatic cirrhosis (Summerskill's sign),^{1,2} which Walsh and Hoyt suggest may cause a myopathy of the levator.⁵ An association with hepatocellular carcinoma has not been described previously, although we postulate that a similar mechanism may be involved. While prolonged high dose steroids may also cause lid retraction,⁶ this patient was on only a low palliative dose.

The severe keratopathy was probably multifactorial. Her eyes were exposed due to lid retraction, markedly reduced blink, and lagophthalmos, and a neurotrophic element was likely because of reduced corneal sensation. A toxic element could not be ruled out and therefore all topical medication was eventually stopped, apart from simple eye ointment that contains no preservatives. This, together with surgery to reduce the palpebral apertures, finally led to palliation of the patient's ocular symptoms.

ALISON MEADOWS
MATHEW RAYNOR
ANDREW LUFF
Southampton Eye Unit

Correspondence to: Mr Andrew Luff, Southampton Eye Unit, Southampton SO16 6YD

Accepted for publication 14 January 2000

- 1 Bartley GB. The differential diagnosis and classification of eyelid retraction. *Ophthalmology* 1996;103:168-76.
- 2 Lee AG, Brazis PW. Lid retraction and lid lag. In: *Clinical pathways in neuro-ophthalmology*. New York: Thieme, 1998:345-55.
- 3 Friedman DI, Jankovic J, McCrary JA. Neuro-ophthalmic findings in progressive supranuclear palsy. *J Clin Neuro-ophthalmol* 1992;12:104-9.
- 4 Averbuch-Heller L. Neurology of the eyelids. *Curr Opin Ophthalmol* 1997;8:27-34.
- 5 Walsh FB, Hoyt WF. The ocular motor system. In: *Clinical neuro-ophthalmology*. 3rd ed. Baltimore: Williams and Wilkins, 1969:304-30.
- 6 Glaser JS. Neuro-ophthalmic examination: general consideration and special techniques. In: *Neuro-ophthalmology*. 2nd ed. Philadelphia: Lippincott, 1990:37-60.

Bilateral birdshot retinochoroidopathy in absence of overt clinical lesions

EDITOR.—A case of bilateral birdshot chorioretinopathy diagnosed on the basis of indocyanine angiography in the absence of any overt clinical lesions is presented.

CASE REPORT

A 47 year old woman presented to the eye clinic with a history of photopsia in both eyes left more than right for the past 2 months. She also complained of a scotoma in the temporal field of her left eye. There was no significant ocular history. She had always been a migraine sufferer. She also gave a history of left hemiparesis with complete resolution. She had been investigated for multiple sclerosis and carotid artery disease at that time but all the results were reported to be normal.

On examination her best corrected visual acuity was 6/4 in the right and 6/5 in the left eye. Anterior chamber showed occasional cells in both eyes. The pupillary reactions were normal. Fundus evaluation did not show any signs of any retinal or choroidal disease. Vitreous showed plus cells. Optic discs were hyperaemic on both sides (Fig 1). Goldmann visual fields showed enlargement of the blind spots. Fundus fluorescein angiography revealed leakage from the disc in both eyes more

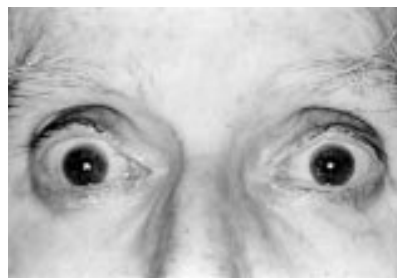

Figure 1 Bilateral lid retraction.

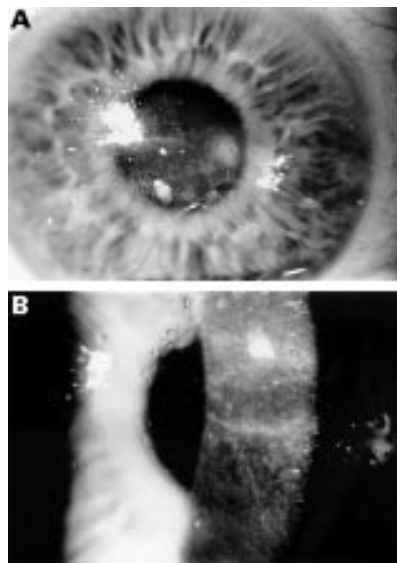


Figure 2 Corneal epitheliopathy

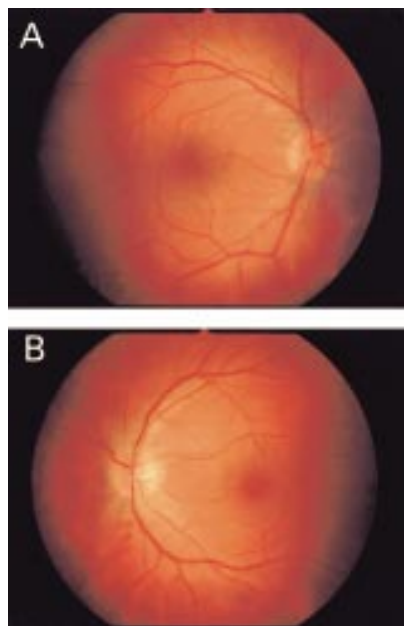


Figure 1 (A, B) Coloured fundus photographs of the right and left eye showing absence of fundus lesions.

pronounced in the left eye (Fig 2). ICG showed hypofluorescent dots in the choroid which developed early in transit and stayed through the mid phase. These were vasotropic in distribution and spared the peripapillary and macular areas. Retinal and choroidal vasculature was normal (Fig 3).

Based on the ICG findings a presumptive diagnosis of birdshot choroidopathy was made. Full blood counts were requested along with a chest x ray, angiotensin converting enzyme, and HLA typing. HLA typing revealed that she was HLA-A 29 positive. The diagnosis of birdshot choroidopathy was thus confirmed and the patient started on systemic steroids for a period of 6 weeks followed by cyclosporin.

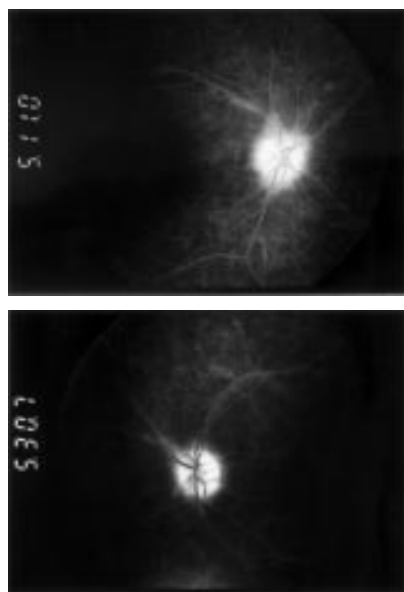


Figure 2 (A, B) Fundus fluorescein angiogram of the right and left eye showing leakage at the optic disc in both eyes.

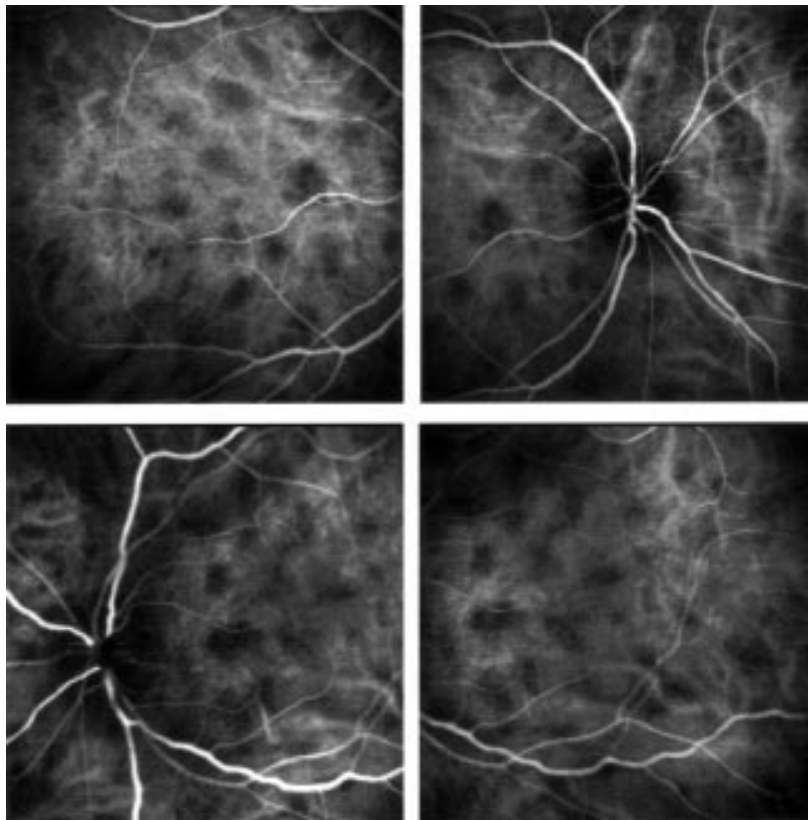


Figure 3 ICG angiography of the right and left eye showing the characteristic hypofluorescent lesions.

Follow up over a period of 6 months showed a marked improvement in her symptoms. Fundus examination still does not show any lesions. The optic discs were still hyperaemic.

COMMENT

Birdshot chorioretinopathy,¹ also described as vitiliginous chorioretinitis,² is seen more commonly in females in the third to sixth decade.³

It classically presents with painless reduced vision with floaters and occasional photopsia.^{2,3} Often unilateral and asymmetric at presentation, it invariably involves both eyes over time. The anterior segment is usually quiet with vitreous showing variable vitritis. Vitreous base/pars plana exudation is absent. Variable degrees of retinal vascular inflammation along with disc or macular oedema are seen. Presence of scattered oval, non-pigmented, and creamy yellow subretinal spots, with indistinct borders initially seen in nasal to the disc or in the inferior retina is the hallmark of the disease.³ New spots appear and existing spots may coalesce and enlarge with time.⁴ Long term complications include posterior subcapsular cataracts, retinal and disc oedema, retinal breaks and detachments, preretinal and choroidal neovascularisation with vitreous and subretinal haemorrhage, optic atrophy, and progressive chorioretinal atrophy.⁴

Fundus fluorescein angiography shows spots to be hypofluorescent in the transit phase which become mildly hyperfluorescent in the later stages.¹⁻³ Optic disc shows dye leakage which is compatible with the clinical picture. Diffuse and extensive dye leakage, a very characteristic sign, is also seen from retinal vasculature. Long term retinal or choroidal complications can also be seen.¹⁻³

Indocyanine angiography shows a number of well delineated hypofluorescent areas exceeding the number seen clinically appearing

early in the study and persisting throughout the course of the study. Early appearance, location, and size of these spots help differentiate between other multifocal choroiditis.^{5,6}

A strong association up to 96%^{7,8} has been reported between HLA-A29 and birdshot choroidopathy, with HLA-A29 positive patients having a 50-fold greater risk of developing this disease than those without it.⁴

The case in discussion fitted well into the clinical scenario of birdshot chorioretinopathy and had classic lesion on both ICG and fluorescein angiography but with no obvious clinical lesions. A high index of suspicion along with the use of ICG which demonstrated the classic lesion followed by the fact that the patient was HLA A29 positive helped to make the diagnosis. This case therefore re-emphasises the role of ICG angiography in establishing a diagnosis of chorioretinopathies in absence of clinical lesions.

M GUPTA
P PURI
I G RENNIE

Department of Ophthalmology, Royal Hallamshire Hospital, Glossop Road, Sheffield S10 2JF, UK

Correspondence to: Mr Mohit Gupta

Accepted for publication 22 November 2000

- 1 Kanski JJ, ed. Birdshot retinochoroidopathy. In: *Clinical ophthalmology: a systematic approach*. Oxford: Butterworth-Heinemann, 1994:194-5.
- 2 Gass JDM. Vitiliginous chorioretinitis. *Arch Ophthalmol* 1981;99:1778-87.
- 3 Ryan SJ, Maumenee AE. Birdshot retinochoroidopathy. *Am J Ophthalmol* 1980;89:31-45.
- 4 Soubrán G, Bokobza, Coscas G. Late developing lesions in birdshot retinochoroidopathy. *Am J Ophthalmol* 1990;109:204-10.
- 5 Howe LJ, Stanford MR, Graham EM, et al. Choroidal abnormalities in birdshot chorioretinopathy: an indocyanine green angiography study. *Eye* 1997;11:554-9.

- 6 Fardeau C, Herborn CP, Kullmann N, *et al*. Indocyanine green angiography in birdshot chorioretinopathy. *Ophthalmology* 1999;106:1928-34.
- 7 Nussenblatt RB, Mittal KK, Ryan SJ, *et al*. Birdshot retinochorioidopathy associated with HLA-B27 antigen and immune responsiveness to retinal S-antigen. *Am J Ophthalmol* 1982;94:147-58.
- 8 Priem HA, Kijlstra A, Neons L, *et al*. HLA typing in birdshot chorioretinopathy. *Am J Ophthalmol* 1988;105:182-5.

Anterior ischaemic optic neuropathy in a patient with HLA-B27 associated anterior uveitis and ankylosing spondylitis

EDITOR.—HLA-B27 positivity occurs in 40%–50% of patients with anterior uveitis.^{1,2} HLA-B27 associated anterior uveitis is typically non-granulomatous, recurrent, and unilateral or alternatingly bilateral. The most frequent systemic disease associations in HLA-B27 positive patients with anterior uveitis include ankylosing spondylitis, Reiter's syndrome, inflammatory bowel disease, and psoriatic arthritis.^{1,2} Ocular complications are more common in HLA-B27 positive patients with anterior uveitis compared with HLA-B27 negative patients,² and include cataract formation, pupillary synechiae, secondary glaucoma, and cystoid macular oedema.^{1,2} Although severe vitreous inflammation and optic disc oedema can be seen in 15%–20% of patients with HLA-B27 associated anterior uveitis, ischaemic optic neuropathy is rare.³⁻⁶ We describe a patient who developed anterior ischaemic optic neuropathy in the setting of known HLA-B27 associated recurrent, anterior uveitis and ankylosing spondylitis.

CASE REPORT

A 29 year old white man with a 10 year history of recurrent, alternating, anterior uveitis, HLA-B27 positivity, and radiographically documented sacroiliitis presented with a 2 week history of decreased vision in his right eye. His first episode of anterior uveitis occurred in his right eye 10 years before presentation. Two subsequent episodes involved the right eye 6 years and again 6 months before presentation. Each episode was controlled with topical prednisolone acetate 1%. His most recent episode was associated with mildly decreased vision, mild photophobia, and partial loss of his lower visual field on the right but no significant ocular pain or pain with eye movement. Examination revealed a best corrected visual acuity of 20/40 on the right and 20/20 on the left. Colour vision was slightly decreased on the right, measured as a slow 19/20 using pseudo-isochromatic plates. Anterior segment examination disclosed an afferent pupillary defect and a mild anterior uveitis. Posterior segment examination on the right revealed no vitreous inflammation but did show moderately severe optic disc oedema with a surrounding Paton's ring, as well as inferior capillary telangiectasis and superior capillary closure on the optic disc (Fig 1A). Fluorescein angiography confirmed superior capillary closure on the optic disc (Fig 1B), and revealed late leakage from the telangiectatic disc vessels (Fig 1C). Humphrey visual field testing disclosed an inferior altitudinal defect corresponding with the area of superior optic disc pallor. The patient was treated with topical prednisolone acetate, 1%, and was given a sub-Tenon's injection of triamcinolone acetonide 40 mg. A magnetic resonance scan of the brain and orbits failed to show enhancement of the optic nerve or evidence of central

demyelination. Serological tests including a normal complete blood cell count, a negative serum anti-*Bartonella henselae* IgG, a negative serum anti-*Toxoplasma gondii* IgG, and a negative enzyme linked immune assay for *Borrelia burgdorferi*. A chest x ray was unremarkable. On follow up examination, vision improved to 20/30 on the right and the optic disc oedema resolved but the afferent pupillary defect, superior optic disc pallor, and inferior altitudinal defect (Fig 1D) remained.

COMMENT

Although optic disc oedema may be observed in 15%–20% of HLA-B27 associated uveitis,² it usually occurs in the setting of moderate to severe vitreous inflammation, and rarely results from an ischaemic optic neuropathy. The absence of vitreous inflammation and the presence of an afferent pupillary defect, decreased colour vision, and the subsequent development of disc pallor accompanied by a persistent altitudinal field defect in our patient suggest, however, that an ischaemic optic neuropathy can occur in the setting of HLA-B27 associated uveitis. This notion is supported by previous descriptions of optic neuropathy in patients with HLA-B27 associated uveitis, both in the absence of systemic involvement,² and in patients with anterior uveitis in the setting of systemic disease.³⁻⁶

This work was supported in part by a career development award to Dr E T Cunningham Jr from Research to Prevent Blindness, Inc, New York, USA.

VIVIEN M-B THAM
EMMETT T CUNNINGHAM, JR
The Francis I Proctor Foundation and the Department of Ophthalmology, UCSF Medical Center, San Francisco, CA 94143-0944, USA

Correspondence to: Dr Emmett T Cunningham, Jr, The Pearl and Samuel J Kimura Ocular Immunology Laboratory, The Francis I Proctor Foundation, UCSF, Medical Center, San Francisco, CA, 94143-0944, USA

emmett@itsa.ucsf.edu

Accepted for publication 24 January 2001

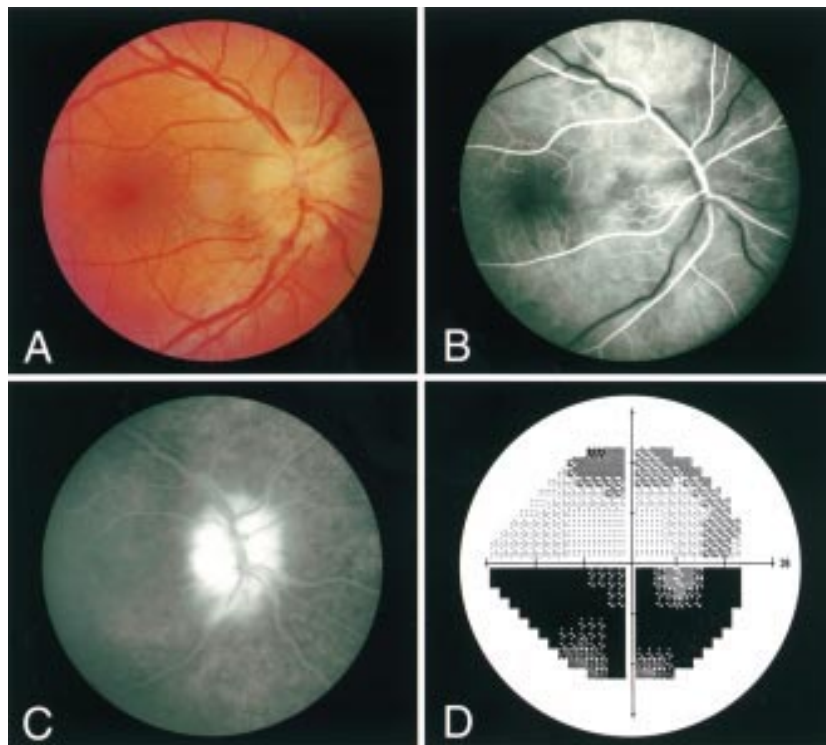


Figure 1 Colour photograph of the right fundus (A) taken at presentation shows moderate optic disc oedema with inferior capillary telangiectasis and superior capillary closure. Serial fluorescein angiograms performed at this same time shows decreased capillary perfusion of the superior segment of the optic disc (B), and diffuse, late leakage from the optic disc (C). A Humphrey 24-2 visual field taken 2 weeks after presentation reveals a dense, inferior, altitudinal defect corresponding to the segmental disc pallor (D).

- 1 Tay-Kearney ML, Schwam BL, Lowder C, *et al*. Clinical features and associated systemic diseases of HLA-B27 uveitis. *Am J Ophthalmol* 1996;121:47-56.
- 2 Power WJ, Rodriguez Alejandro, Pedroza-Seres M, *et al*. Outcomes in anterior uveitis associated with the HLA-B27 haplotype. *Ophthalmology* 1998;105:1646-51.
- 3 Heuer DK, Gager WE, Reeser FH. Ischemic optic neuropathy associated with Crohn's disease. *J Clin Neuro-ophthalmol* 1982;2:175-81.
- 4 Knox DL, Schachat AP, Mustonen E. Primary, secondary and coincidental ocular complications of Crohn's disease. *Ophthalmology* 1984;91:163-73.
- 5 Sedwick LA, Klingele TG, Burde RM, *et al*. Optic neuritis in inflammatory bowel disease. *J Clin Neuro-ophthalmol* 1984;4:3-6.
- 6 Kang SW, Lee EB, Baek HJ, *et al*. Bilateral optic neuritis in ankylosing spondylitis. *Clin Exp Rheumatol* 1999;17:635-6.

Cyclical central serous chorioretinopathy associated with cystoid macular oedema

EDITOR.—Central serous chorioretinopathy (CSC) is a common idiopathic condition which predominantly affects middle aged men. We report an atypical case in a woman which was unusual on two counts—frequent cyclical episodes governed by the menstrual cycle and the presence of significant cystoid macular oedema. To our knowledge, neither phenomenon has been previously described.

CASE REPORT

A 45 year old premenopausal white female presented with a 1 year history of intermittent blurring of central vision in her right eye. The left eye was blind following a penetrating eye injury as a child. Apart from low grade bronchiectasis with infrequent exacerbations she was otherwise well and took no regular medication. Initial clinical examination revealed a small area of neurosensory retinal detachment inferonasal to the fovea and cystoid macular oedema. There was no evidence of intraocular inflammation and the vitreous was clear. Fundus fluorescein angiography (FFA) taken during a symptomatic period showed three parafoveal areas of intraretinal oedema with small cystic spaces surrounding larger "petaloid" spaces typical of cystoid macular oedema (Fig 1A).

The patient had kept a menstrual diary over a year confirming a completely regular menstrual cycle and there was a clear association between poor subjective vision and the first half of each cycle. Vision deteriorated each month with the onset of menstruation and began to improve again around the time of ovulation.

Over the subsequent 12 months visual blurring fluctuated with Snellen visual acuity varying between 6/6 and 6/12 when measured at clinic visits.

Retinal examination at times of poor vision revealed a small foveal yellow spot and a small area of parafoveal neurosensory retinal elevation inferior to this. On examination during a period of normal vision during the latter half of the menstrual cycle, these changes had usually resolved leaving only slight perifoveal retinal pigment epithelium pigment disturbance and FFA showed persistence of the three more peripheral areas of retinal oedema but absence

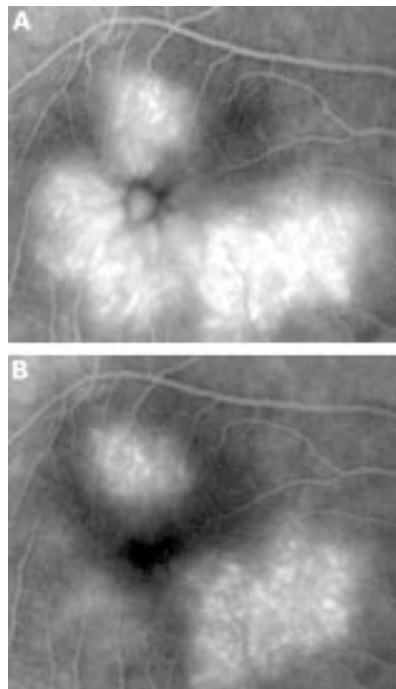


Figure 1 Late fluorescein angiograms of the right macula taken at 13 minutes. During a period of poor subjective vision and before hormone therapy there is significant cystoid macular oedema (CMO) with a typical petaloid pattern surrounded by three areas of outer retinal oedema (A). After 4 months of continuous hormone therapy with Mercilon there is no evidence of CMO and one area of retinal oedema has resolved (B).

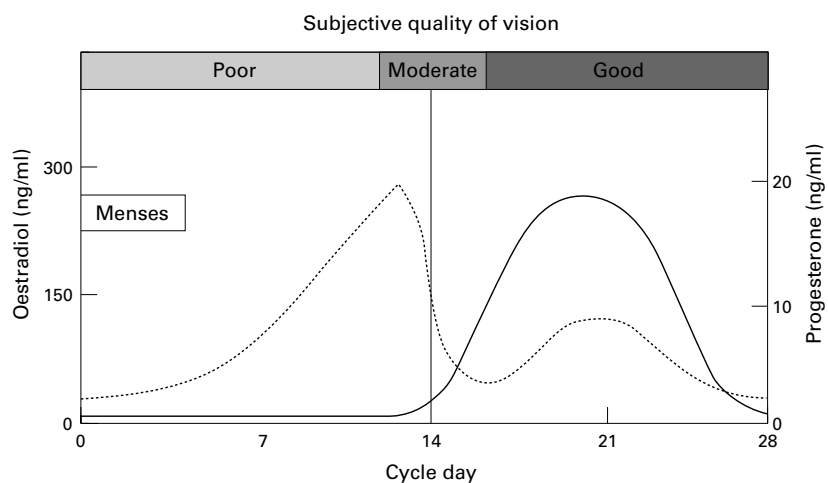


Figure 2 Subjective quality of vision recorded by the patient during a typical menstrual cycle superimposed on a graph of levels of the principal female hormones oestradiol (broken line) and progesterone (solid line). Poor vision is associated with very low progesterone levels during the first half of the cycle.

of the central petaloid changes. Indocyanine green angiography was normal with no evidence of choroidal vascular anomaly or leakage.

A typical month is illustrated in Figure 2. The subjective quality of vision is superimposed on a graph of levels of the principal female sex hormones oestradiol and progesterone, showing poor vision to be associated with very low progesterone levels during the early follicular half of the cycle. Her vision deteriorated from "good" to "bad" quite rapidly over a 1–2 day period associated with rapidly declining progesterone levels.

She was treated with the oral contraceptive pill Microgynon (levonorgestrel 150 µg, ethinylloestradiol 30 µg) on a continuous basis. Within 3 days of commencing treatment she experienced an improvement in vision to its best level which was maintained for 49 days followed by return of symptoms associated with a recurrence of clinical and angiographic cystoid macular oedema. Treatment was changed to continuous Mercilon (desogestrel 150 µg, ethinylloestradiol 20 µg), a pill containing an alternative less androgenic progestogen and lower dosage of oestrogen, with further recovery which has been maintained for 4 months. At review the macula was clinically dry and repeat FFA confirmed the absence of central oedema and resolution of one of the peripheral areas of oedema (Fig 1B).

COMMENT

The unusual clinical picture in this patient with cyclical visual blurring in her only good eye is suggestive of central serous chorioretinopathy (CSC) with episodes of localised serous retinal detachment. Clinical and angiographic cystoid macular oedema was a prominent feature not usually described in textbook accounts of the condition. An optical coherence tomography study of CSC suggests, however, that subclinical intraretinal oedema is usually present in detached retina, with retinal thickness returning to normal when serous fluid is resorbed.¹ Intraretinal cystic spaces were identified in one patient.

Pathological studies of the condition are limited but microcystic retinal degeneration in the Henlé fibre layer has been observed in eyes with a history of CSC.² One could therefore postulate that while usually subclinical, retinal oedema with cyst formation became clinically manifest in our patient owing to frequent

monthly recurrent episodes of CSC. The angiographic appearance suggested intraretinal fluid to be in the outer retinal layers and probably derived from the choroidal rather than the retinal vasculature—hyperfluorescence appeared in early frames of the angiogram.

Central serous chorioretinopathy appears to have a multifactorial aetiology and personality and hormonal influences may be important.³ CSC has been documented following systemic corticosteroid therapy⁴ and during pregnancy.⁵ Gass also described a single case of postpartum "idiopathic" cystoid macular oedema developing 3 days after a full term normal delivery with recovery after 2 months.⁶ This is relevant to our case, suggesting that rapidly declining hormone levels may rarely have adverse effects on retinal capillary, choriocapillaris, or RPE function. That hormonal fluctuations may influence inflammatory processes in the eye is supported by a report of cyclical premenstrual attacks of severe anterior uveitis responding to suppression of the pituitary-ovarian axis with danazol.⁷

Little is known about the precise influence of female sex hormones on ocular function and cyclical changes in various ocular and visual variables probably have little clinical significance, perhaps with the exception of fluctuation in contact lens tolerance.⁸ They appear to have some influence on choroidal circulation in women with significantly lower pulse amplitude and pulsatile ocular blood flow in post-menopausal women relative to age matched men and pre-menopausal women.⁹ At a molecular level, recent experimental work has identified sex steroid hormone receptor mRNAs in various ocular tissues, including retina, choroid, and retinal pigment epithelium in rats, rabbits, and humans suggesting these represent target tissues for androgens, oestrogens, and progestins.¹⁰ From a therapeutic perspective in this case the relative dosage of oestrogen and progestogen may be important as the pill with lower oestrogen but equivalent progestogen dose had a more prolonged and maintained therapeutic effect.

In conclusion, we feel the clinical picture in this patient represents atypical cyclical CSC associated with cystoid macular oedema with monthly attacks precipitated by progesterone deficiency during the early follicular phase of the menstrual cycle. Continuous oral contraceptive treatment has produced significant

symptomatic relief. Further study of any relation between attacks of CSC in female patients and the menstrual cycle would be of interest.

W BIRCHALL
S J CHARLES
Royal Eye Hospital, Oxford Road, Manchester
M13 9WH, UK

H M BUCKLER
Department of Diabetes and Endocrinology, Hope
Hospital, Stott Lane, Salford M6 8HD, UK

Correspondence to: Dr Birchall

Accepted for publication 15 January 2001

- Hee RM, Puliafito CA, Wong C, *et al.* Optical coherence tomography of central serous chorioretinopathy. *Am J Ophthalmol* 1995;120:65-74.
- Ueoka T. A pathologic study of central serous chorioretinopathy. *Acta Soc Ophthalmol Jpn* 1949;53:222-6.
- Yannuzzi LA. Type A behaviour and central serous chorioretinopathy. *Retina* 1987;7:111-30.
- Gass JDM, Little HL. Bilateral bullous exudative detachment complicating idiopathic central serous chorioretinopathy during systemic corticosteroid therapy. *Ophthalmology* 1995;102:737-747.
- Gass JDM. Central serous chorioretinopathy and white subretinal exudation during pregnancy. *Arch Ophthalmol* 1991;109:677-81.
- Gass JDM. *Stereoscopic atlas of macular diseases; diagnosis and treatment.* 4th ed. St Louis: CV Mosby, 1997:490.
- Guttridge NM. Changes in ocular and visual variables during the menstrual cycle. *Ophthalmic Physiol Opt* 1994;14:38-48.
- Bell JA. Danazol, premenstrual tension and uveitis. *Arch Ophthalmol* 1989;107:796.
- Centofanti M, Boniti S, Manni G, *et al.* Do sex and hormonal status influence choroidal circulation? *Br J Ophthalmol* 2000;84:786-7.
- Wickham LA, Gao J, Toda I, *et al.* Identification of androgen, estrogen and progesterone receptor mRNAs in the eye. *Acta Ophthalmol Scand* 2000;78:146-53.

A new pedigree with recessive CHED mapping to the CHED2 locus on 20p13

EDITOR.—Congenital hereditary endothelial dystrophy (CHED) and posterior polymorphous corneal dystrophy (PPCD) are phenotypically distinct diseases of the corneal endothelium. Linkage analysis has mapped a locus for autosomal dominant PPCD to chromosome 20p11.¹ Subsequently, other researchers placed a locus for autosomal dominant CHED (designated CHED1 by the human genome mapping workshop) in an overlapping genetic interval,² suggesting that these two disorders may be allelic variants of the same defective gene.

However, CHED is more commonly inherited as an autosomal recessive (AR) disease,³ and linkage analysis in a large consanguineous recessive Saudi Arabian pedigree excluded CHED1 as the causative locus.⁴ Genetic heterogeneity in this condition was further confirmed by linkage analysis in a large consanguineous Irish pedigree⁵ in which a second CHED genetic locus (CHED2) was subsequently localised more distally at 20p13.⁶

We now present a Pakistani pedigree with AR CHED in whom genetic analysis also confirms linkage to this second region, suggesting that AR CHED is clinically and genetically homogeneous.

CASE REPORT

Two generations of a large inbred family were examined, in whom the segregation pattern was consistent with an autosomal recessive mode of inheritance (Fig 1). The three affected daughters all gave a typical history of severe non-progressive corneal clouding present from birth, consistent with recessively inherited CHED. Best corrected visual acuity

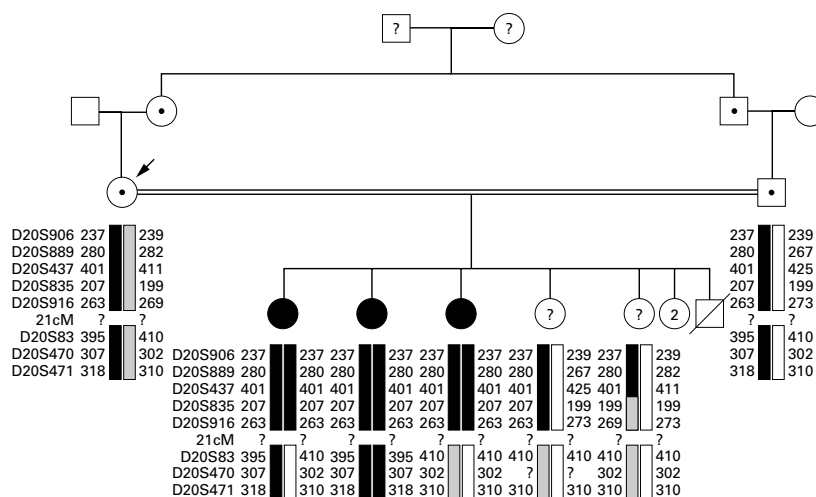


Figure 1 Autosomal recessive CHED pedigree. Solid symbols show affected individuals and open symbols denote unaffected individuals, the spot indicates carrier status. Double marriage lines indicate a consanguineous pairing. The autosomal recessive and autosomal dominant CHED disease gene haplotypes are indicated, with allele fragment sizes shown for each genetic marker.

was hand movements in all affected eyes, and examination revealed an avascularly opacified "ground glass" corneal appearance (Fig 2), and the presence of nystagmus.⁷ The eldest daughter had a unilateral penetrating keratoplasty performed at age 8 years, in the United States. Histological examination on the host button confirmed the diagnosis of CHED.⁸ The grafted eye had a large postoperative myopic and astigmatic error, but with refractive correction, the surgery had conferred an unquantifiable but useful improvement in visual function. The unaffected members were all asymptomatic with normal vision and a normal anterior segment examination.

COMMENT

This is only the second AR CHED family reported in the literature for which genetic analysis has been carried out. This analysis locates the abnormal gene to the CHED2 locus at chromosome 20p13 (Fig 1) and excludes the CHED1 locus at chromosome 20p11.

Genetic analysis was performed following DNA extraction by standard techniques. Fluorescently tagged polymorphic microsatellite markers were spaced across the CHED1 and the CHED2 loci. Amplified polymerase chain reaction products were detected using an "ABI 377" automated sequencer with GeneScan software.

Five genetic markers spanning the CHED2 locus were analysed (D20S906—3.6 cM—D20S889—2.8 cM—D20S437—1.1 cM—

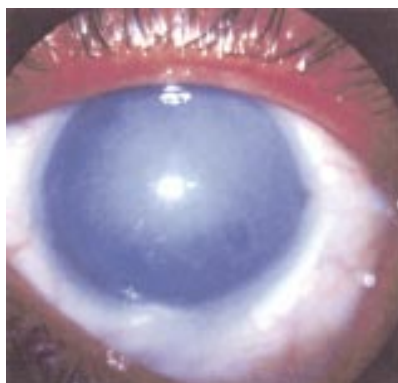


Figure 2 Opacified "ground glass" corneal appearance.

D20S835—2.1 cM—D20S916, with genetic distance as given on the Marshfield integrated genetic map).⁹ Examination of the haplotypes shown in Figure 1 reveals an area of identity by descent common to all three affected sisters, while the two unaffected sisters are heterozygous for this region. Multipoint linkage analysis with the LINKMAP program from the LINKAGE package gave a lod score of 2.64. The previous probability established by previous linkage to these markers of another AR CHED family makes this result statistically significant. In addition three markers spanning the CHED1 locus, approximately 21 cM centromeric from the CHED2 locus, were analysed. Haplotype analysis in this region clearly excludes the CHED1 region from involvement in the disorder in this family.

This is a significant result, particularly since the affected family is from a different racial group. Linkage analysis and clinical examination suggest genetic and clinical homogeneity for this disorder, but the disparate racial origins of the two CHED2 linked families make it likely that they have different mutations. This in turn should aid the identification of the mutant gene, which lies in a gene rich region of the genome.¹⁰ This will help affected individuals by allowing diagnosis by genetic testing and consequently permitting accurate genetic counselling. Also, it may provide valuable insights into the cellular biology of the corneal endothelium, which may improve our understanding of this cell layer and its dysfunction in old age and graft failure, both conditions for which there is currently little effective treatment.

The authors gratefully acknowledge the Wellcome Trust, who funded this research (award reference 061682/dcp).

MOIN D MOHAMED
Molecular Medicine Unit, University of Leeds
and Department of Ophthalmology,
St James's University Hospital, Leeds

MARTIN McKIBBIN
Department of Ophthalmology,
St James's University Hospital, Leeds

HUSSEIN JAFRI
YASMIN RAASHED
Department of Obstetrics and Gynaecology, Fatima
Jinnah Medical College, Lahore, Pakistan

C GEOFFREY WOODS
CHRIS F INGLEHEARN
Molecular Medicine Unit, University of Leeds,
St James's University Hospital, Leeds

Correspondence to: Dr Inglehearn, Molecular Medicine Unit, Clinical Sciences Building, University of Leeds, St James's University Hospital, Beckett Street, Leeds LS9 7TF

inglehe@hgmp.mrc.ac.uk

Accepted for publication 13 December 2000

- 1 Heon E, Mathers WD, Alward WLM, *et al.* Linkage of posterior polymorphous corneal dystrophy to 20q11. *Hum Mol Genet* 1995;4:485-8.
- 2 Toma NMG, Ebenezzer ND, Inglehearn CF, *et al.* Linkage of congenital hereditary endothelial dystrophy to chromosome 20. *Hum Mol Genet* 1995;4:2395-8.
- 3 Maumenee AE. Congenital hereditary corneal dystrophy. *Am J Ophthalmol* 1960;50:1114-24
- 4 Kanis AB, Al-Rajhi AA, Taylor CM, *et al.* Exclusion of AR-CHED from the chromosome 20 region containing the PPMD and AD-CHED loci. *Ophthalmic Genet* 1999;20:243-9.
- 5 Callaghan M, Hand CK, Kennedy SM, *et al.* Homozygosity mapping and linkage analysis demonstrate that autosomal recessive congenital hereditary endothelial dystrophy (CHED) and autosomal dominant CHED are genetically distinct. *Br J Ophthalmol* 1999;83:115-19.
- 6 Hand CK, Harmon DL, Kennedy SM, *et al.* Localisation of the gene for autosomal recessive congenital hereditary endothelial dystrophy (CHED2) to chromosome 20 by homozygosity mapping. *Genomics* 1999;61:1-4.
- 7 Judisch GF, Maumenee IH. Clinical differentiation of recessive congenital hereditary endothelial dystrophy and dominantly inherited endothelial dystrophy. *Am J Ophthalmol* 1978;85:606-12.
- 8 Kirkness CM, McCartney A, Rice NSC, *et al.* Congenital hereditary corneal oedema of Maumenee: its clinical features, management, and pathology. *Br J Ophthalmol* 1987;71:130-44.
- 9 http://research.marshfieldclinic.org/genetics/Map_Markers/maps/indexmap.html
- 10 <http://www.ncbi.nlm.nih.gov/genemap/map.cgi?CHR=20>

Endogenous *Rhodotorula minuta* and *Candida albicans* endophthalmitis in an injecting drug user

EDITOR.—Although still uncommon, endogenous fungal endophthalmitis has increased notably owing to widespread use of immunosuppressive therapy, hyperalimentation, and injecting drug use. *Candida* is the most common causative organism with isolated cases of *Aspergillus* reported.¹ *Rhodotorula* species are ubiquitous, airborne, asporogenous yeasts recovered from food, air, soil, water, gastrointestinal tracts, and skin. *Rhodotorula* spp are usually environmental saprophytes; however, they may seldom cause both systemic and ocular infections, especially in immunocompromised patients.² Reported ocular infections include chronic dacryocystitis,³ keratitis,⁴ chronic postoperative endophthalmitis,⁵ and corneal lamellar graft infection.⁶ We report a case of endogenous *Rhodotorula minuta* and *Candida albicans* endophthalmitis in an injecting drug user.

CASE REPORT

A 27 year old man was admitted with a 3 month history of progressive visual loss and intraocular inflammation in his right eye. He had initially been examined by other ophthalmologists who observed two large yellow-white lesions with fluffy borders in the posterior pole, diagnosed toxoplasmic retinochoroiditis, and started treatment with trimethoprim-sulfamethoxazole. After initial improvement, he eventually developed endophthalmitis and was referred to us for further treatment.

His medical history included injecting drug use and chronic hepatitis C virus. On admission, visual acuity was right eye light perception and left eye 20/20. Slit lamp examination of the right eye disclosed conjunctival injection and a

10% hypopyon. Ophthalmoscopic examination showed 4+ vitreous reaction that obscured retinal details. No retinal detachment was visible on B-scan ultrasonography. Left eye examination was unremarkable.

TPHA test and tests for the detection of serum IgM and IgG to cytomegalovirus, hepatitis B virus, HIV, and *Toxoplasma gondii* were negative.

The patient underwent pars plana vitrectomy of the right eye. Hazy visualisation of the fundus disclosed a grey-white necrotic appearing retina. Bacterial and fungal cultures of the vitreous specimen were taken. Amikacin (400 µg) and vancomycin (1 mg) were injected intravitreally. In addition, injecting cefotaxime (500 mg twice daily) and topical tobramycin (0.3%), dexamethasone (0.1%), and atropine (1%) were given. Gram staining of the vitreous specimen revealed the presence of inflammatory cells and Gram positive yeasts, but no bacteria; as a result, oral ketoconazole (400 mg daily) was added to the treatment regimen.

Bacterial cultures were negative. On day 6, fungal cultures showed both red and white colonies, identified as *R minuta* and *C albicans*, respectively. Accordingly, injecting cefotaxime was discontinued, intravitreal amphotericin B (5 µg) given, and oral ketoconazole continued for a total of 4 weeks. Once the infection resolved, the retina appeared to be grey-white, ischaemic, and necrotic. Final visual acuity in the right eye was uncertain light perception.

COMMENT

Fungal organisms account for more than one half of cases of endogenous endophthalmitis.¹ Endogenous fungal endophthalmitis may be caused by many different species, including *Candida*, *Aspergillus*, *Coccidioides*, *Cryptococcus*, *Blastomyces*, and *Sporothrix*.^{1,7} Patients with endogenous fungal endophthalmitis typically have systemic risk factors, including injecting drug abuse, long term injecting treatment, hyperalimentation, recent systemic surgery or trauma, indwelling bladder catheters, malignancy, immunosuppression, or debilitation. In a recent retrospective study, a history of injecting drug use was obtained in 22% of cases.⁸ Endogenous fungal endophthalmitis results from the bloodborne spread of organisms to the eye from a site of infection elsewhere in the body or from contaminated catheters or needles. Most cases occur without evidence of an ongoing fungaemia.¹

Endogenous fungal endophthalmitis develops slowly as focal or multifocal areas of retinochoroiditis. Granulomatous or non-granulomatous inflammation is observed with keratic precipitates, a hypopyon, and vitritis. Mimicking toxoplasmic retinochoroiditis, posterior pole lesions appear yellow-white with fluffy borders, ranging in size from small cotton wool spots to several disc diameters. The lesions originate in the retina and result in exudation into the vitreous.

To our knowledge, there have been no reports of isolation of *R minuta* from eyes with endogenous endophthalmitis. Other authors described a case of chronic *Rhodotorula* endophthalmitis following cataract surgery.⁵ These types of organisms may be difficult to recover in the vitreous aspirate. We routinely request that the microbiology laboratory keep the cultures for longer than usual to allow uncommon, indolently replicating organisms to grow. As an injecting drug user, our patient most likely developed endogenous endophthalmitis following the bloodborne spread of fungi to the eye from a contaminated needle. Despite treatment with oral and intraocular antifungal

agents and vitrectomy, he had poor visual outcome. Although endogenous fungal endophthalmitis generally has a very poor prognosis and early treatment of central lesions seldom salvages useful vision because of damage to central photoreceptors,¹ delay in the diagnosis probably contributed to the poor visual outcome in our patient. Our report suggests that *R minuta* should be considered a possible aetiological agent of endogenous endophthalmitis, especially in patients with history of injecting drug use.

ANTONIO PINNA
FRANCESCO CARTA

*Institute of Ophthalmology, University of Sassari,
Sassari, Italy*

STEFANIA ZANETTI
SILVANA SANNA
LEONARDO A SECHI

*Department of Biomedical Sciences,
Section of Experimental and Clinical Microbiology,
University of Sassari, Sassari, Italy*

Correspondence to: Antonio Pinna, MD, Via Casula 6, 07100 Sassari, Italy
apinna@uniss.it

Accepted for publication 14 February 2001

- 1 Kresloff MS, Stellarin AA, Zarbin MA. Endophthalmitis. *Surv Ophthalmol* 1998;43:193-224.
- 2 Gyaurgieva OH, Bogomolova TS, Gorshkova GI. Meningitis caused by *Rhodotorula rubra* in an HIV-infected patient. *J Med Vet Mycol* 1996;34:357-9.
- 3 Muralidhar S, Sulthana CM. *Rhodotorula* causing chronic dacryocystitis: a case report. *Ind J Ophthalmol* 1995;43:196-8.
- 4 Guerra R, Cavallini GM, Longanesi L, *et al.* *Rhodotorula glutinis* keratitis. *Int Ophthalmol Clin* 1992;16:187-90.
- 5 Gregory JK, Haller JA. Chronic postoperative *Rhodotorula* endophthalmitis. *Arch Ophthalmol* 1992;110:1686-7.
- 6 Panda A, Pushker N, Nainiwal S, *et al.* *Rhodotorula* sp infection in corneal interface following lamellar keratoplasty—a case report. *Acta Ophthalmol Scand* 1999;77:227-8.
- 7 Brod RD, Clarkson JG, Flynn HW Jr, *et al.* Endogenous fungal endophthalmitis. In: Tasman W, Jaeger EA, eds. *Duane's clinical ophthalmology*. Vol 3. Philadelphia: JB Lippincott, 1990:1-30.
- 8 Essman TF, Flynn HW Jr, Smiddy WE, *et al.* Treatment outcomes in a 10-year study of endogenous fungal endophthalmitis. *Ophthalmic Surg Lasers* 1997;28:185-94.

The disappearing "melanoma"

EDITOR.—Uveal melanoma is the most common primary intraocular malignancy in adults. Accurate diagnosis relies upon evaluation by indirect ophthalmoscopy as well as on characteristic features present on ancillary tests such as ultrasonography and angiography. Masquerading lesions can occasionally provide diagnostic challenges. Common simulating lesions include choroidal naevi, metastases, haemangioma, osteoma, CHRPE, and disciform scar.¹ We report the case of a patient with a lesion simulating an intraocular melanoma which resulted from the development of an orbital cyst that indented the globe.

CASE REPORT

A 49 year old white male was referred with a diagnosis of an intraocular melanoma. He complained of progressively decreasing vision in his right eye over the previous 1.5 years. His medical history was notable for HIV positive status with a CD4 count of 295 cells × 10⁹/l. There was no history of any opportunistic infections. At the time of evaluation, he was receiving external beam radiation for squamous cell carcinoma of the nasal mucosa. Ocular history was significant for a right

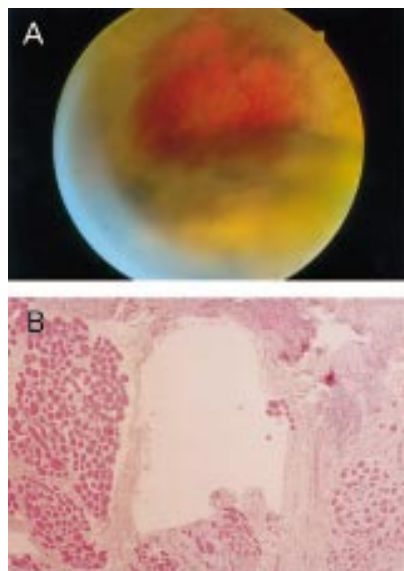


Figure 1 (A) Fundus photograph showing a dome-shaped pigmented mass in the periphery of the right eye. (B) Histopathology confirming an epithelial inclusion cyst.

orbital fracture, resulting from an assault, surgically repaired 4 years before this evaluation.

On physical examination, visual acuity was 20/200 right eye and 20/40 left eye. The right eye was proptosed 6 mm anteriorly and there was associated vertical dystopia with 3 mm of scleral show. Motility was decreased in upward gaze in the right eye and was full contralaterally. The anterior segment was quiet in both eyes. On indirect ophthalmoscopy there was an elevated dome-shaped pigmented lesion in the inferior periphery of the right eye, measuring 16 mm in basal diameter and 5 mm in height (Fig 1A). The elevated portion extended to the ora serrata but did not appear to involve the ciliary body. Ultrasonography suggested a solid heterogeneous mass 5 mm in height. The globe was indented in the area of the mass.

Given the patient's history of trauma and findings of decreased ocular motility with

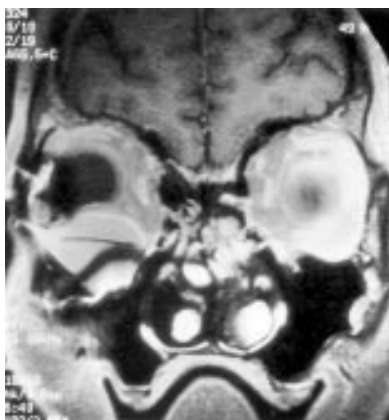


Figure 2 MRI, coronal view, showing a cystic orbital mass indenting the right globe. Note the silastic plate within this cystic structure.

proptosis, a magnetic resonance image was obtained. Neuroimaging revealed a cystic mass in the orbit indenting the globe inferiorly (Fig 2). Within the cyst, a prosthetic device was appreciated. No intraocular mass was present and the choroid was of uniform thickness. Surgical exploration of the orbit revealed a mucocele 2.5 cm in diameter. Within the cyst, a silastic plate was identified.

Histopathology confirmed an epithelial inclusion cyst (Fig 1B). Over a 13 month period, the initial funduscopic findings gradually resolved. Pigmentary changes remained in the inferior periphery but were not associated with choroidal elevation. Repeat ultrasonography demonstrated diminution in the thickness of the mass. The patient was orthophoric in primary gaze and visual acuity returned to 20/40 in both eyes.

COMMENT

Masquerading lesions may appear nearly identical to uveal melanoma on indirect ophthalmoscopy. In this case, associated orbital abnormalities and careful review of patient history suggested the need for further diagnostic evaluation. Neuroimaging, including MRI, can provide useful information in

the management of complex intraocular lesions.²⁻⁴ In this case, MRI identified a cystic mass that arose following the placement of a silastic plate following traumatic injury; once the cyst was removed, the associated ophthalmoscopic findings resolved and the "melanoma" disappeared.

This work was supported in part by Research to Prevent Blindness, Heed Ophthalmic Foundation (Dr Gombos), That Man May See Foundation, Inc, and UCSF Core Grant EY02162.

DAN S GOMBOS

Ocular Oncology Unit, Department of Ophthalmology,
University of California, San Francisco,
California, USA

MELISSA L MELDRUM

Department of Ophthalmology, The Emory Clinic,
Atlanta, Georgia, USA

JENNIFER HASENYAGER SMITH

Ocular Oncology Unit, Department of Ophthalmology,
University of California, San Francisco,
California, USA

CHEN LEE

Division of Plastic and Reconstructive Surgery,
Department of Surgery, University of California,
San Francisco, California, USA

JOAN M O'BRIEN

Ocular Oncology Unit, Department of Ophthalmology,
University of California, San Francisco,
California, USA

Correspondence to: Joan O'Brien, MD, Director,
Ocular Oncology Unit, University of California, San
Francisco, 10 Kirkham Street, Box 0730, San Fran-
cisco, CA 94143, USA

Accepted for publication 20 February 2001

- 1 Shields JA, Shields CL. Differential diagnosis of posterior uveal melanoma. In: Shields JA, Shields CL, eds. *Intraocular tumors: a text and atlas*. Philadelphia: Saunders, 1992:137-53.
- 2 Haik BG, Saint Louis L, Smith ME, et al. Magnetic resonance imaging in choroidal tumors. *Ann Ophthalmol* 1987;19:218-38.
- 3 Peyman GA, Mafee MF. Uveal melanoma and similar lesions: the role of magnetic resonance imaging and computed tomography. *Radiol Clin N Am* 1987;25:471-86.
- 4 Smith EV, Gragoudas ES, Kolodny NH, et al. Magnetic resonance imaging: an emerging technique for the diagnosis of ocular disorders. *Int Ophthalmol* 1990;14:119-24.