

## A randomised trial of the effect of intraoperative 5-FU on the outcome of trabeculectomy in east Africa

D Yorston, P T Khaw

### Abstract

**Aims**—To determine if intraoperative application of 5-fluorouracil (5-FU) improves the prognosis for trabeculectomy in east Africa.

**Methods**—68 eyes with chronic open angle glaucoma were included in a randomised trial of intraoperative 5-FU versus placebo. Main outcome measures were intraocular pressures at 6 months and probability of failure at 2 years.

**Results**—180 days after surgery the mean intraocular pressure (IOP) was 17.4 (SD 6.1) mm Hg in the placebo group and 16.9 (5.8) mm Hg in the 5-FU group. By 2 years after trabeculectomy, the probability of successful IOP control was 70.6% in the placebo group, and 88.8% in the 5-FU group. The placebo group was 2.18 times (95% CI 0.67 to 7.15) more likely to require additional IOP lowering procedures than the 5-FU group. Among patients followed for 2 years, 30% lost 0.3 logMAR units of visual acuity.

**Conclusions**—Trabeculectomy in Africa has an acceptable success rate which may be enhanced by the use of intraoperative 5-FU. It is estimated that this would cost approximately £1.25 per trabeculectomy failure prevented.

(Br J Ophthalmol 2001;85:1028–1030)

This study was designed to determine whether a single intraoperative dose of 5-FU would improve the outcome of trabeculectomy in east Africa.

### Methods

Only patients with chronic open angle glaucoma were included in the study. Patients were excluded if they could not return for follow up examinations, or if they were at high risk of failure.

Patients were randomised to 5-FU or placebo at surgery, when a nurse opened a sealed envelope, and prepared the appropriate solution. The surgeon did not know which treatment was given.

Cellulose swabs were soaked in either 5-FU (25 mg/ml) or normal saline, and placed between the conjunctiva and sclera for 5 minutes.

Major outcome measures were IOP at 6 months, and risk of failure at 2 years after surgery. Failure was defined as a pressure of more than 26 mm Hg on one occasion, or a pressure of between 22 and 26 mm Hg on two occasions at least 2 months apart.

### Results

Sixty eight eyes of 68 patients were included in the study. All eyes had an IOP greater than 21 mm Hg. The mean preoperative IOP was 32.4 (SD 9.2) mm Hg in the placebo group, and 33.8 (SD 8.8) mm Hg in the 5-FU group.

There were no major intraoperative complications. Postoperatively 10 out of 32 5-FU treated patients, and four out of 36 control patients had a shallow anterior chamber (AC) ( $\chi^2 = 4.2$ ,  $p = 0.04$ ). No patient showed signs of epithelial toxicity. Ninety days after surgery, 16 out of 26 patients in the 5-FU group had cystic blebs, compared with 10 out of 32 placebo treated patients ( $\chi^2 = 5.3$ ,  $p = 0.02$ ). This difference decreased with time, and was not significant at 180 days post-trabeculectomy.

Although 58 patients were followed for at least 180 days, only 56 were assessed at 180 days. Thirty patients (44.1%) were followed for more than 2 years.

The mean IOP at 14 days after surgery was 16.2 mm Hg in the placebo group, and 10.7 mm Hg in the 5-FU group (difference = 5.5

Kikuyu Eye Unit,  
Kikuyu, Kenya  
D Yorston

Wound Healing  
Research Unit and  
Glaucoma Unit,  
Moorfields Eye  
Hospital and Institute  
of Ophthalmology,  
11–43 Bath Street,  
London EC1V 9EL, UK  
P T Khaw

Correspondence to:  
Mr David Yorston,  
Department of Epidemiology  
and International Eye  
Health, Institute of  
Ophthalmology, 11–43 Bath  
Street, London EC1V 9EL,  
UK

e.cartwright@ucl.ac.uk

Accepted for publication  
20 April 2001

Chronic open angle glaucoma is a common cause of blindness in Africa.<sup>1</sup> In Tanzania 3.1% of the population aged 40 or over have chronic open angle glaucoma.<sup>2</sup> Glaucoma is usually treated by trabeculectomy<sup>3</sup> soon after diagnosis.

Trabeculectomy outcomes can be improved by using antimetabolites.<sup>4–6</sup> However, daily injections of 5-fluorouracil (5-FU) are inconvenient, and mitomycin has serious adverse effects.<sup>7</sup> A single intraoperative application of 5-FU may be safer,<sup>8</sup> and may improve IOP control.<sup>9–12</sup>

In Ghana, intraoperative 5-FU produced lower postoperative IOPs than placebo, and mitomycin C was even more effective than 5-FU.<sup>13 14</sup>

Table 1 Intraocular pressures (mm Hg) 180 days after surgery

	<14	<17	<22	>21
Placebo	8 25.0%	17 53.1%	24 75.0%	8 25.0%
5-FU	8 33.3%	13 54.2%	20 83.3%	4 16.7%

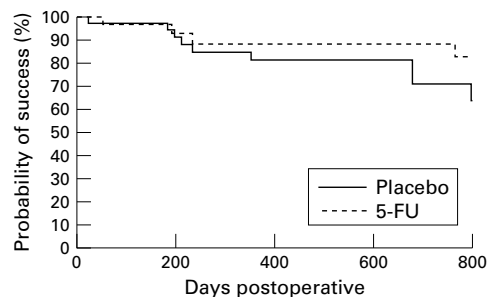


Figure 1 Kaplan-Meier survival curve for risk of trabeculectomy failure during first 2 years after surgery.

mm Hg,  $SE_{diff} = 1.51$ , 95% CI = 2.49–8.51). IOPs 180 days after surgery are shown in Table 1. The mean IOP at day 180 was 17.5 (SD 6.0) mm Hg in the placebo group, and 16.8 (SD 5.8) mm Hg in the 5-FU treated group. No patient had an IOP less than 8 mm Hg.

Survival analysis, using the Kaplan-Meier technique (see Fig 1), showed that the probability of IOP control without further intervention 2 years after trabeculectomy was 0.89 in the 5-FU group, and 0.71 in the placebo group (difference = 0.18,  $SE_{diff} = 0.112$ , 95% CI = 0.402 to -0.037). The placebo group was 2.18 times (95% CI = 0.67 to 7.15) more likely to have had further IOP lowering treatment.

Of 30 eyes followed for at least 2 years after surgery, four placebo eyes (30.8%), and five 5-FU treated eyes (29.4%) lost at least 0.3 log-MAR units of acuity. The mean preoperative IOP was 39.22 mm Hg in these eyes, compared to 30.05 mm Hg in those that did not lose vision (difference = 9.17,  $SE_{diff} = 2.73$ , 95% CI = 3.59–14.7). There was no difference in the latest mean IOP.

## Discussion

Intraoperative application of 5-FU may reduce the risk of trabeculectomy failure in east African patients. Our definition of failure was stricter than some UK based studies that allowed medically controlled IOP as a qualified success.<sup>12</sup> The risk of requiring further treatment to lower IOP within 2 years of surgery appears to be greater in the placebo group than in 5-FU treated patients. However, because of the small number of patients, the confidence limits for this increased risk are very wide. Although the effect of a single intraoperative dose of 5-FU diminishes with time, it may last long enough to have an effect on outcomes at 2 years.

At 2 years, the probability of an IOP of less than 22 mm Hg without further intervention was 88.8% in the 5-FU treated group and 70.6% in the placebo group. If a successful outcome at 2 years is 10% greater with 5-FU than without it, routine use of 5-FU would be very cost effective—approximately £1.25 per trabeculectomy failure prevented.

Most studies of peroperative 5-FU have shown few adverse effects.<sup>11–14</sup> In this study, 5-FU was associated with an increased risk of shallow anterior chamber at 2 weeks, and of a thin walled cystic bleb at 3 months. No eye became hypotonous.<sup>15</sup>

In Ghana, Egbert found a success rate (IOP  $\leq 20$  mm Hg) of 83% at 1 year<sup>13</sup> in the 5-FU treated group, as opposed 88% at 2 years in our study. However, only 39% of the controls in Ghana were successful at 1 year,<sup>13</sup> compared to 70.6% of controls in our study.

Trabeculectomy in east Africa carries a significant risk of visual loss. Patients with a higher preoperative IOP are at greater risk. As no eyes were hypotonous, the reduction in vision is unlikely to be due to overdrainage. The most probable cause is increasing lens opacity. In Tanzania,<sup>6</sup> a similar incidence of visual loss was found, mostly because of media opacity. The Collaborative Normal Tension Glaucoma Study found that IOP reduction was only beneficial after discounting the effects of cataract.<sup>16</sup>


One limitation of this trial is inadequate follow up. It is hard to achieve good follow up in Africa.<sup>17, 18</sup> It is particularly difficult following trabeculectomy, when vision rarely improves despite repeated clinic attendances.

Trabeculectomy is effective at controlling IOP in east Africa, and this effectiveness may be enhanced by the use of intraoperative 5-FU.

This study was supported in part by the International Glaucoma Association and in part by the Iris Fund/Royal College of Ophthalmologists' Prize. It was undertaken by authors who are funded in part by the NHS Executive; the views expressed in this publication are those of the authors and not necessarily of the NHS Executive. The work was also supported by the Glaucoma Unit, Moorfields Eye Hospital NHS Trust, London UK, and by Christian Blind Mission, Winship Road, Cambridge CB4 6BQ, UK.

- 1 Wormald R, Foster A. Clinical and pathological features of chronic glaucoma in north-east Ghana. *Eye* 1990;4:107.
- 2 Buhrmann RR, Quigley HA, Barron Y, et al. Prevalence of glaucoma in a rural East African population. *Invest Ophthalmol Vis Sci* 2000;41:40–8.
- 3 Verrey JD, Foster A, Wormald R, et al. Chronic glaucoma in northern Ghana—a retrospective study of 397 patients. *Eye* 1990;4:115–20.
- 4 The Fluorouracil Filtering Surgery Study Group. Fluorouracil filtering surgery study one year follow-up. *Am J Ophthalmol* 1983;108:625.
- 5 The Fluorouracil Filtering Surgery Study Group. Three year follow-up of the fluorouracil filtering surgery study. *Am J Ophthalmol* 1993;115:82.
- 6 Quigley HA, Buhrmann, RR, West SK, et al. Long term results of glaucoma surgery among participants in an east African population survey. *Br J Ophthalmol* 2000;84:860–4.
- 7 Al-Hazmi A, Zwaan J, Awad A, et al. Effectiveness and complications of mitomycin C use during paediatric glaucoma surgery. *Ophthalmology* 1998;105:1915–20.
- 8 Occlleston NL, Alexander RA, Mazure A, et al. Effects of single exposures to antiproliferative agents on ocular fibroblast-mediated collagen contraction. *Invest Ophthalmol Vis Sci* 1994;35:3681–90.
- 9 Khaw PT, Sherwood MB, Mackay SL et al. Five minute treatments with fluorouracil, floxuridine, and mitomycin have long term effects on human Tenon's capsule fibroblasts. *Arch Ophthalmol* 1992;110:1150–4.
- 10 Khaw PT, Doyle JW, Sherwood MB, et al. Effects of intra-operative 5-fluorouracil or mitomycin C on glaucoma filtration surgery in the rabbit. *Ophthalmology* 1993;100:367–72.
- 11 Lanigan L, Sturmer J, Baez KA, et al. Single intraoperative applications of 5-fluorouracil during filtration surgery: early results. *Br J Ophthalmol* 1994;78:33–7.
- 12 Bell R, Habib N, O'Brien C. Long term results and complications after trabeculectomy with a single per-operative application of 5-fluorouracil. *Eye* 1997;11:663–71.

- 13 Egbert PR, Williams AS, Singh K, *et al.* A prospective trial of intraoperative fluorouracil during trabeculectomy in a black population. *Am J Ophthalmol* 1993;116:612-16.
- 14 Singh K, Egbert PR, Byrd S, *et al.* Trabeculectomy with intraoperative 5-fluorouracil vs mitomycin C. *Am J Ophthalmol* 1997;123:48-53.
- 15 Singh K, Byrd S, Egbert PR, *et al.* Risk of hypotony after primary trabeculectomy with antifibrotic agents in a black west African population. *J Glaucoma* 1998;7:82-5.
- 16 Collaborative Normal Tension Glaucoma Study Group. Comparison of glaucomatous progression between untreated patients with normal tension glaucoma and patients with therapeutically reduced intraocular pressures. *Am J Ophthalmol* 1998;126:487-97.
- 17 Egbert PR, Buchanan M. Results of extracapsular cataract surgery and intraocular lens implantation in Ghana. *Arch Ophthalmol* 1991;109:1764-8.
- 18 Cook NJ. Evaluation of high volume extracapsular cataract extraction with posterior chamber lens implantation in Sierra Leone, west Africa. *Br J Ophthalmol* 1996;80:698-701.



Want full text but don't have  
a subscription?

**Pay per view**

For just \$8 you can purchase the full text of individual articles using our secure online ordering service. You will have access to the full text of the relevant article for 48 hours during which time you may download and print the pdf file for personal use.

**[www.bjophthalmol.com](http://www.bjophthalmol.com)**