

CASE REPORT

Osteomyelitis pubis versus osteitis pubis: a case presentation and review of the literature

S Pauli, P Willemsen, K Declerck, R Chappel, M Vanderveken

Br J Sports Med 2002;**36**:71–73

An athletic 23 year old man presented with suprapubic tenderness, fever, and raised inflammatory blood variables. A diagnostic laparoscopy was performed, with a presumed diagnosis of retrocaecal appendicitis, but no abnormalities were found, apart from free fluid in the pouch of Douglas. Imaging of the pubic area suggested bony infection and inflammation. Biopsy and culture confirmed the presence of *Staphylococcus aureus*, a very common pathogen. The final diagnosis was osteomyelitis pubis, an infectious disease, and osteitis pubis, an inflammatory disease.

A 23 year old man presented to our emergency room with the following complaints: lower abdominal tenderness and pain, and pyrexia of 38°C for 24 hours.

On clinical investigation the hypogastrium was found to be painful with guarding. There were no further abnormal findings. Rectal examination was normal. Laboratory examination showed raised inflammatory variables: erythrocyte sedimentation rate was 28 mm in first hour, fibrinogen was 60.9 g/l (normal range 18–40 g/l), and C reactive protein was 269 mg/l (normal value less than 10 mg/l). The white blood count was 11 200/mm³ (normal range 3500–9800) with 80.4% of neutrophils. A plain abdominal radiograph was normal.

An emergency laparoscopy was performed. Peroperatively, free fluid was found in the pouch of Douglas. There was no bacterial growth when this fluid was cultured. The appendix was macroscopically normal and was left in situ. Further diagnostic steps were necessary. Urine culture was negative. Ultrasound examination of the abdomen showed intraperitoneal air, which was due to the laparoscopy. Clinical re-evaluation showed a localised tenderness in the pubic area. A more detailed history was taken at this stage. The patient reported that for the past year he had only be able to exercise twice a week. After exercising he experienced pain in the

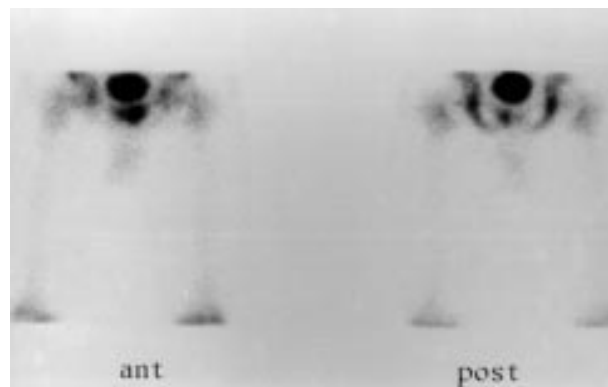


Figure 1 Technetium-99m methyl diphosphonate scan showing activity especially on the left side of the symphysis pubis.

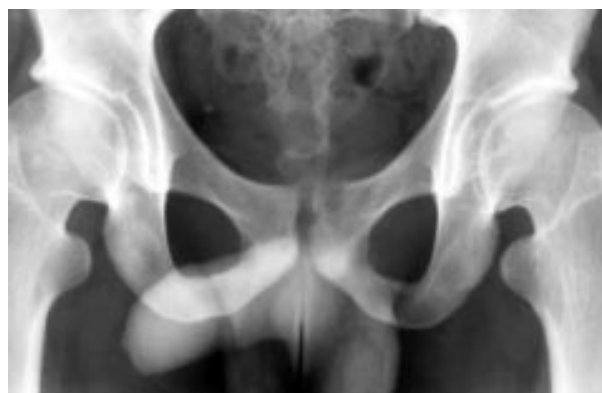

Figure 2 Radiograph of the os pubis showing an unclear lining of the symphysis pubis and bony destruction. Normal anatomy, no diastasis.

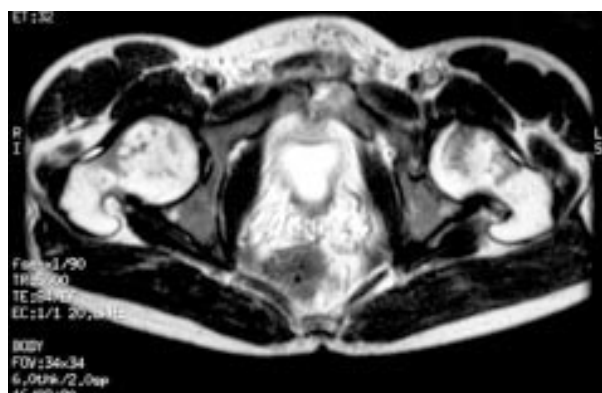


Figure 3 Magnetic resonance imaging scan (T2 images) with bilateral abnormal hyperintense signal, more on the left side of the symphysis pubis and normal anatomy and normal signals from the musculotendinous structures.

pubic region and stiffness for two days, which then resolved spontaneously. A radiograph of the os pubis showed sclerosis and bony destruction of the margins of the symphysis pubis, suggesting osteitis pubis (fig 1). A technetium-99m methyl diphosphonate bone scan showed a solitary area of hyperactivity in the left os pubis and symphysis pubis (fig 2). Magnetic resonance imaging (MRI) of the pubic region clarified the diagnosis, with enhanced activity in the symphysis pubis on the T2 images—on the left side of the symphysis more than on the right side (fig 3).

The next step was to obtain a biopsy specimen of the pubic bone for microscopic and microbiological examination. Under

Abbreviations: MRI, magnetic resonance imaging

general anaesthesia, an x ray guided biopsy of the left pubic bone was performed. Culture results showed a rich growth of *Staphylococcus aureus* with the following sensitivity: sensitive to oxacillin, clindamycin, netilmicin, amikacin, cotrimoxazole, minocycline, and ofloxacin; resistant to penicillin. Histological examination showed bony destruction, osteolysis, and fibrotic zones with clusters of histiocytes.

Intravenous flucloxacillin was started, in combination with non-steroidal anti-inflammatory drugs. Apart from striking eczema and diffuse scratch lesions, there was no clear entry site for the bacteria.

Fever, pain, and inflammatory blood variables normalised after one week of intravenous antibiotic treatment. The patient was discharged home after 10 days, and antibiotics were continued orally for four weeks (ofloxacin).

The patient was seen in the outpatient clinic four months later. He was asymptomatic and exercising (football, tennis) at a higher level than before. The inflammatory variables were normal and no further technical investigations were carried out as the patient was completely symptom free.

DISCUSSION

The symphysis pubis is a non-synovial amphiarthrodial joint situated at the confluence of the two pubic bones, consisting of an intrapubic fibrocartilagenous disc sandwiched between thin layers of hyaline cartilage.¹ Bony infection or inflammation of the pubic area is rare. In the literature, these two conditions are commonly confused with each other. There is actually a distinct difference between osteomyelitis and osteitis pubis (table 1).

Osteomyelitis of the pubic symphysis differs from osteitis pubis. The latter is an entity characterised by pelvic pain, a wide based gait, and bony destruction of the margins of the pubic symphysis. It is a self limiting inflammation secondary to trauma, pelvic surgery, childbirth, or overuse (usually in athletes). Osteomyelitis pubis on the other hand has the same clinical signs, but is infectious in nature. The pathogenesis of both is still unclear.

Delay in diagnosis is common, primarily because of the uncommon site and rarity, and also because of the difficulty in making a differential diagnosis with urological, gynaecological, and abdominal emergencies. Osteitis pubis and osteomyelitis pubis should be considered when a patient presents with the following signs: pain or pubic tenderness, painful hip abduction, and fever. Pain occurs while walking, radiating to the perineal, testicular, suprapubic, or inguinal region, and can also develop in the scrotum after ejaculation. Furthermore, there is mild leucocytosis, raised levels of acute phase proteins (fibrinogen, C reactive protein), and increased erythrocyte sedimentation rate. The following technical investigations may contribute to the diagnostic process: a whole body bone scintigraphy will show hyperactivity at the pubis; MRI and computed tomography scans can show inflammatory changes in the bone.

To distinguish between osteomyelitis and osteitis pubis, a biopsy and culture of the affected area are necessary.¹⁻³ The most common infecting agent is *S aureus*. Less common are

Take home message

Both osteitis pubis, an inflammatory disease, and osteomyelitis pubis, an infectious disease, can appear in one patient at the same time.

Pseudomonas aeruginosa, *Escherichia coli*, anaerobic bacteria, *Salmonella* species, *Streptococcus* species, and *Brucella* species.²⁻⁴⁻¹⁰ The most common cause of osteomyelitis pubis is postoperative inoculation, particularly after gynaecological and urological operations, often when a technical complication has occurred.¹¹⁻¹⁶ A few cases have been reported to occur after endoscopic inguinal hernia repair as the result of attachment of the prosthesis to the os pubis.¹⁷ However, there remain many cases of osteomyelitis without identifiable origin, for instance after spontaneous vaginal delivery¹² and the present case of a pyogenic osteomyelitis of the pubis in an otherwise healthy athlete. We do not know if eczematous lesions were the source of circulating bacteria; we found no such evidence in the literature.

Osteitis pubis is a painful inflammatory process mostly seen in athletes. It is typical in sports with a lot of sprinting and sudden changes of direction, such as running, basketball, soccer, ice hockey, and tennis.¹⁰⁻¹⁸⁻²⁰

Antibiotic treatment is essential in the management of osteomyelitis pubis, depending on the identification of the causative agent. Initial intravenous treatment must be followed by oral treatment for at least four weeks. After this, antibiotic treatment should be continued until the erythrocyte sedimentation rate is normalised (which often takes more than three months). Other treatment is the same as for osteitis pubis: rest and anti-inflammatory medication. Some athletes with osteitis pubis did well after local injections with corticoids.¹⁹ Surgical debridement and curettage of osteomyelitis pubis is indicated in patients with severe complications such as pelvic diastasis, because of bone necrosis, cystic perforation, pelvic instability, and severe pain not responding to antibiotic treatment.²⁰⁻²¹

Our patient clearly had osteomyelitis, as we found infection with a staphylococcal species. However, interestingly, this patient also had typical chronic signs of osteitis pubis, as seen on the technical investigations, but without clinical implications. The bilateral parasymphyseal changes observed on the isotope bone scan (fig 1) and plain radiograph (fig 2), such as the posterior symphyseal extrusion and buttressing osteophyte formation with the extrusion indenting into the bladder base on the MRI scan (fig 3), suggest chronic symphyseal stressing changes. We assume that the osteitis pubis with the inflammatory process, especially in the superior aspect of the left pubis, is the ideal spot for bacterial ingrowth causing pyogenic osteomyelitis.

Conclusion

The diagnosis of osteomyelitis pubis should be considered in every patient who experiences pubic pain that is exacerbated

Table 1 Comparison of the features of osteomyelitis pubis and osteitis pubis

	Osteomyelitis pubis	Osteitis pubis
Basic feature	Infectious	Inflammatory
Bacterial growth	Positive	Negative
Treatment	Antibiotics, NSAID, rest, surgery for complications	Self limiting, rest, NSAID, corticoids
Causes	Pelvic surgery, childbirth, abdominal pathology, unknown.	Trauma, pelvic surgery, childbirth, overuse (athletes)
Clinical features	Wide based gait, pelvic pain, painful hip abduction, fever	Wide based gait, pelvic pain, painful hip abduction, fever
Technical investigations	x Ray, MRI, CT scan, bone scintigraphy	x Ray, MRI, CT scan, bone scintigraphy

NSAID, Non-steroidal anti-inflammatory drugs; MRI, magnetic resonance imaging; CT, computed tomography.

while walking. Biopsy and culture are necessary to make a differential diagnosis with osteitis pubis, an inflammatory condition of the pubic symphysis and the surrounding muscular insertions. However, both osteitis and osteomyelitis pubis can appear together in one patient as shown in our case. The most common pathogen of pyogenic osteomyelitis is *S aureus*. Intravenous antibiotic treatment should be started immediately. Delay in diagnosis and treatment can cause severe complications, such as pelvic instability, pubic diastasis, and even urinary bladder perforation.

.....
Authors' affiliations

S Pauli, P Willemsen, M Vanderveken, Department of Abdominal Surgery, University of Antwerp, Middelheim General Hospital, Antwerp, Belgium

R Chappel, Department of Physiotherapy and Revalidation
K Declerck, University of Antwerp, Middelheim General Hospital, Antwerp, Belgium

Correspondence to: Dr Vanderveken, Middelheim General Hospital, Lindendreef 1, B-2020 Antwerp, Belgium; paulisteven@hotmail.com

Accepted 13 September 2001

REFERENCES

- Gamble JG**, Simmons SC, Freedman M. The symphysis pubis. Anatomic and pathologic considerations. *Clin Orthop* 1986;**203**:261-72.
- Bouza E**, Winston DJ, Hewitt WL. Infectious osteitis pubis. *Urology* 1978;**12**:663-9.
- Lupovitch A**, Elie JC, Wysocki R. Diagnosis of acute bacterial osteomyelitis of the pubis by means of fine needle aspiration. *Acta Cytol* 1989;**33**:649-51.
- Peluchon P**, Sommier J, Janoyer M, et al. Pubic osteitis caused by *Salmonella indiana*. Apropos of a case. *Rev Chir Orthop Reparatrice Appar Mot* 1997;**83**:743-6.
- Sucato DJ**, Gillespie R. *Salmonella* pelvic osteomyelitis in normal children: report of two cases and a review of the literature. *J Pediatr Orthop* 1997;**17**:463-6.
- Mansoori D**, Gangi EN, Touzet P. Brucellosis of the pubic symphysis. Apropos of a case. Review of the literature. *Rev Chir Orthop Reparatrice Appar Mot* 1996;**82**:753-6.
- Groeneweg CE**, Thurnheer U. Spontaneous pubic osteomyelitis caused by *Pseudomonas aeruginosa*. *Schweiz Med Wochenschr* 1993;**123**:1520-5.
- Ortiz-Neu C**, Marr JS, Cherubin CE, et al. Bone and joint infections due to *Salmonella*. *J Infect Dis* 1978;**138**:820-8.
- Jenkins FH**, Raff MJ, Florman LD, et al. Pubic osteomyelitis due to anaerobic bacteria. *Arch Intern Med* 1984;**144**:842-3.
- Karpos PA**, Spindler KP, Pierce MA, et al. Osteomyelitis of the pubic symphysis in athletes: a case report and literature review. *Med Sci Sports Exerc* 1995;**27**:473-9.
- Burns JR**, Gregory JG. Osteomyelitis of the pubic symphysis after urologic surgery. *J Urol* 1977;**118**:803-5.
- Esckridge C**, Longo S, Kwark J, et al. Osteomyelitis pubis occurring after spontaneous vaginal delivery: a case presentation. *J Perinatol* 1997;**17**:321-4.
- Sexton DJ**, Heskestad L, Lambeth WR, et al. Postoperative pubic osteomyelitis misdiagnosed as osteitis pubis: report of four cases and review. *Clin Infect Dis* 1993;**17**:695-700.
- Lentz SS**. Osteitis pubis: a review. *Obstet Gynecol Surv* 1995;**50**:310-15.
- Michiels E**, Knockaert DC, Vanneste SB. Infectious osteitis pubis. *Neth J Med* 1990;**36**:297-300.
- Rutherford A**. Osteomyelitis of the symphysis pubis. *N Z Med J* 1983;**96**:332-3.
- Mader R**, Yeromenko E. *Pseudomonas* osteomyelitis of the symphysis pubis after inguinal hernia repair. *Clin Rheumatol* 1999;**18**:167-9.
- Barry NN**, McGuire JL. Acute injuries and specific problems in adult athletes. *Rheum Dis Clin North Am* 1996;**22**:531-49.
- Holt MA**, Keene JS, Graf BK, et al. Treatment of osteitis pubis in athletes. Results of corticosteroid injections. *Am J Sports Med* 1996;**24**:248.
- Fricke PA**, Taunton JE, Ammann W. Osteitis pubis in athletes. Infection, inflammation or injury? *Sports Med* 1991;**12**:266-79.
- Grace JN**, Sim FH, Shives TC, et al. Wedge resection of the symphysis pubis for the treatment of osteitis pubis. *J Bone Joint Surg [Am]* 1989;**71**:358-64.

Note to readers

Since February 2001, we have included colour pictures of sporting activities on the cover of the *British Journal of Sports Medicine*. We hereby solicit your ideas and contributions for future covers of the *British Journal of Sports Medicine*. Original artwork, photographs, and posters may all be considered. We will credit the photographer and athlete(s)/team on the contents page of the issue.

Please send ideas and submissions (original artwork or high-quality, camera-ready photographs) to Rachel Fetches, BMJ Publishing Group, BMA House, Tavistock Square, London WC1H 9JR, UK. Electronic submissions (TIFF files, with a minimum resolution of 600 dpi or high quality JPEG files) can be sent via email to editorialservices@BMJgroup.com.