

CASE REPORT

Stress fracture of the hook of the hamate

A R Guha, H Marynissen

Br J Sports Med 2002;**36**:224–225

Fractures of the hook of the hamate have rarely been reported. They have usually resulted from blunt trauma or a sharp strike against the hamate hook while swinging a golf club, baseball bat, or tennis racquet. Patients present with acute onset of pain localised over the ulnar aspect of the wrist and reduction in grip strength. In the case reported here, the patient complained of gradual onset of pain on the ulnar aspect of the wrist after altering his grip for serving in tennis. Once the diagnosis was made, the fracture was treated conservatively and the patient made a complete recovery.

The purpose of this paper is to (a) report that the hook of the hamate may be fractured as a result of stress from repetitive microtrauma and (b) review the literature.

CASE REPORT

A 33 year old, right handed, recreational athlete presented with a two week history of pain on the ulnar side of his right wrist. The pain gradually began while he was playing tennis, starting four weeks after he had changed his style of serving and consequently his grip on the handle of his racquet. He did not remember any incident when the butt of the handle hit his wrist forcefully and he had no other history of injury. There was tenderness over the fourth carpometacarpal joint, mainly on the dorsal side, and his grasp was weakened. There was no localised swelling, and pinch strength was normal. Routine anteroposterior and lateral radiographs and an ultrasound scan were normal. He was initially treated with a steroid injection over the fourth and fifth extensor tendons and a wrist brace. He had no relief of symptoms and was referred to us five weeks later.

Clinical examination showed tenderness over the dorsal aspect of the fourth and fifth carpometacarpal joints and

severe tenderness over the canal of Guyon. Radiographs, including a carpal tunnel view for a suspected hook of the hamate fracture, were inconclusive. A bone scintigram showed a hot spot at the ulnar aspect of the distal carpus. A magnetic resonance imaging (MRI) scan excluded avascular necrosis of the hook of the hamate and showed marrow oedema suggestive of a fracture, but no fracture line was delineated (fig 1). A high density computed tomography scan confirmed the diagnosis of fracture of the hook of the hamate (fig 2).

The patient was treated with a brace for three weeks and a plaster cast including the fourth and fifth fingers, for a further three weeks, because of a mild recurrence on resuming work. Since then, the wrist has become completely pain free and has regained full function. The patient has returned to playing tennis at his former level and is symptom free one year after the onset of symptoms.

DISCUSSION

A review of the literature shows that fractures of the hook of the hamate have been rarely reported. A high index of suspicion is required to establish the diagnosis. It is easily overlooked and dismissed as a wrist sprain. The fracture is usually associated with trauma, usually the result of a fall on the dorsiflexed hand,^{1,2} direct impact on the palm causing sudden forcible dorsiflexion of the wrist,³ or by the butt of a tennis/squash racquet or golf club striking the hook of the hamate.^{4–6} Our patient did not report a sudden onset of pain, nor was there any history of injury. His symptoms started gradually, four weeks after a change in grip on the racquet while serving. These features suggest a stress fracture caused by repetitive overload rather than a single traumatic event. To our knowledge, a stress fracture of the hook of the hamate caused by repetitive microtrauma has not previously been reported.

Patients with acute fractures of the hook of the hamate often present late with persistent pain on the ulnar side of the

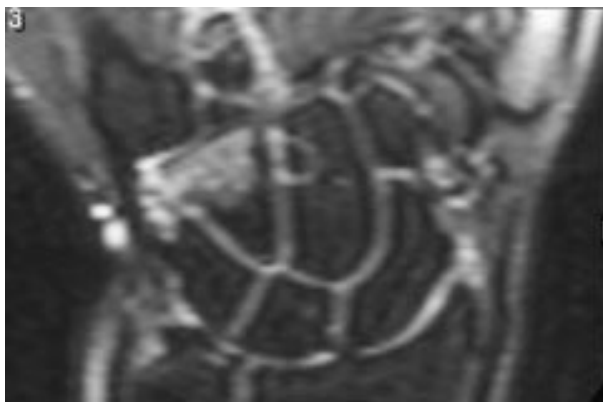


Figure 1 Single time inversion ratio (STIR) sequence magnetic resonance scan of the wrist showing altered signal over the hook of the hamate suggesting marrow oedema.

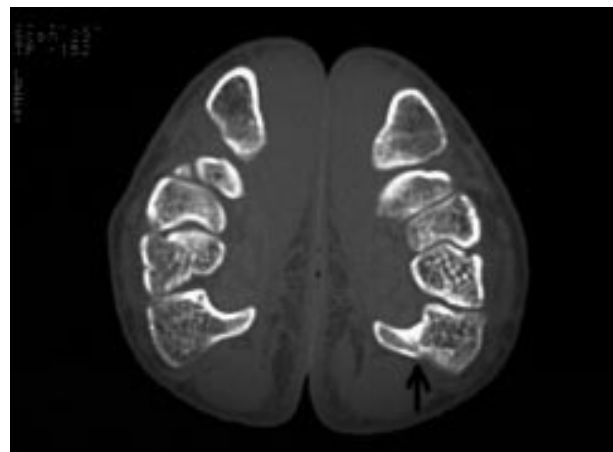


Figure 2 High density computed tomography scan of both wrists in the "praying position" showing a fracture through the base of the right hamate hook.

Take home message

- Fracture of the hook of the hamate can be caused by repetitive stress injury
- The fracture may present with pain on the dorso-ulnar aspect of the wrist
- CT scan of the wrists in the "praying position" is the imaging modality of choice
- The fracture may be successfully treated conservatively in a short arm cast including the fourth and fifth fingers

wrist, more on the dorsal aspect,^{2-5,8} with weakness of grasp and pain on resisted flexion/abduction of the little finger. The hamate is covered on the volar aspect with thick skin, subcutaneous fibrofatty tissue, and parts of the palmaris brevis muscle and transverse carpal ligament, which makes it difficult to palpate. In the presence of a fracture of the hamate hook, firm pressure is required to elicit pain through the thick soft tissue coverings on the volar aspect. However, direct pressure on the thinly covered dorsolateral aspect of the wrist is more painful, especially if the fracture is at the base of the hook. The site of maximal palpation tenderness may be misleading.

The common complications encountered include rupture of the flexor tendons of the little finger and sensory/motor deficit of the ulnar nerve.⁹ Median nerve and ulnar artery compression have also been reported.^{2,4-7,10} Rupture of the flexor tendons to the little finger is probably caused by constant chafing against the raw bony surface, perhaps aided by the injection of steroids into the region. Stark *et al*⁶ have suggested that the steroids rather than the fracture are responsible for the rupture. Rupture of the tendon renders a more unfavourable outcome, and most authors have recommended early excision of the hook.^{1,2,5,6,10}

Plain radiographs (anteroposterior/lateral/oblique) are not very helpful in making the diagnosis. Special radiographic views can be used to confirm the diagnosis, including:

- Carpal tunnel views as described by Hart and Gaynor¹¹ with the wrist in full dorsiflexion. However, extreme dorsiflexion can be painful in patients in the acute stage.
- Partially supinated lateral (reverse oblique) view with the wrist in maximum radial deviation. Accurate positioning of the wrist is crucial because rotation of the wrist by a few degrees can project the hamate behind the carpal arch. Repeated views are therefore recommended before the final films are taken to ensure a perfect position.^{5,6}

A bone scan allows distinction between bony and soft tissue disorders in the region.

MRI scans have high sensitivity in showing avascular necrosis of the hamate hook, and an altered signal caused by marrow oedema is seen in the presence of a fracture.

A high density CT scan with the wrists in the "praying position" using 2 mm cuts in the axial and sagittal plane allows comparison between the two wrists. It is reported to have a sensitivity of 100%, specificity of 98.4%, and accuracy of 97.2%⁴ and is the radiographic technique of choice in the diagnosis of hook of the hamate fractures.

Fractures diagnosed within three months can be treated conservatively with immobilisation involving the fourth and fifth fingers.^{7,8} Late or recurrent cases are probably better treated with excision of the hook of the hamate to avoid possible complications such as rupture of the flexor tendons.^{1,2,5,6,10}

Authors' affiliations

A R Guha, H Marynissen, Department of Orthopaedics, Burnley General Hospital, Casterton Avenue, Burnley, Lancashire BB10 2PQ, UK

Correspondence to: Mr Marynissen, Burnley General Hospital, Casterton Avenue, Burnley, Lancashire BB10 2PQ, UK; hans@marynissen.demon.co.uk

Accepted 4 January 2002

REFERENCES

- 1 **Cameron HU**, Hastings DE, Fournasier VL. Fracture of the hook of the hamate: a case report. *J Bone Joint Surg [Am]* 1975;**57**:276-7.
- 2 **Carter PR**, Eaton RG, Littler JW. Ununited fracture of the hook of the hamate. *J Bone Joint Surg [Am]* 1977;**59**:583-8.
- 3 **Plancher KD**, Minnich JM. Sports specific injuries. *Clin Sports Med* 1996;**15**:207-18.
- 4 **Egawa M**, Asai T. Fractures of the hook of the hamate: report of six cases and the suitability of computerised tomography. *J Hand Surg* 1983;**8**:393.
- 5 **Parker RD**, Berkowitz MS, Brahm MA, *et al*. Hook of the hamate fractures in athletes. *Am J Sports Med* 1986;**14**:517-23.
- 6 **Stark HH**, Jobe FW, Boyes JH, *et al*. Fracture of the hook of the hamate in athletes. *J Bone Joint Surg [Am]* 1977;**59**:575-82.
- 7 **Gupta A**, Risitano G, Crawford R, *et al*. Fractures of the hook of the hamate. *Injury* 1989;**20**:284-6.
- 8 **Milch H**. Fracture of the hamate bone. *J Bone Joint Surg* 1934;**16**:459-62.
- 9 **Nisenfield FG**, Neviasser RJ. Fracture of the hook of the hamate: a diagnosis easily missed. *J Trauma* 1974;**14**:612-17.
- 10 **Futami F**, Haruhiko A, Tsukamoto Y. Fractures of the hook of the hamate in athletes. *Acta Orthop Scand* 1993;**64**:469-71.
- 11 **Hart VL**, Gaynor V. Roentgenographic study of the carpal canal. *J Bone Joint Surg* 1941;**23**:382-3.



Additional figures for this case report can be viewed on www.bjsportmed.com