

CASE REPORT

Surgical repair of a chronic rupture of the rectus femoris muscle at the proximal musculotendinous junction in a soccer player

R Straw, K Colclough, G Geutjens

Br J Sports Med 2003;37:182–184

A rare case is presented of a longstanding rupture of the rectus femoris muscle at the proximal musculotendinous junction in a semiprofessional soccer player. Its different and unique presentation, the surgical repair, and the remarkable functional recovery are discussed.

Proximal ruptures of the rectus femoris have been well documented at the origin of the direct head as it arises from the anterior superior iliac spine. Although these proximal ruptures are well described, we have found no reports of a complete rupture of the direct head of the rectus femoris muscle at the musculotendinous junction.

CASE REPORT

A 22 year old semiprofessional soccer player presented one year after an injury. During a game he experienced a tearing sensation in his right thigh as he attempted to kick the ball. He was unable to complete the match and developed severe bruising and swelling. Despite physiotherapy and rehabilitation over the next 12 months, he remained unable to sprint or kick a ball. He also noticed a painful lump appearing in his thigh during quadriceps contraction.

Physical examination showed loss of the normal contour of the rectus femoris. During quadriceps contraction, the muscle belly of the rectus femoris could be seen to bunch up and move distally, suggesting a proximal rupture. This was tender to palpation. Clinically his quadriceps power was reduced.

Magnetic resonance imaging without gadolinium enhancement confirmed considerable retraction of the rectus femoris muscle belly down the thigh. The muscle belly appeared to be completely detached from its proximal tendon (direct head), but normal in its substance. The proximal tendon had a normal appearance and was clearly attached to the anterior inferior iliac spine (fig 1).

Muscle strength was evaluated before surgery using a KIN-COM III isokinetic dynamometer. Appreciable weakness of the extensor mechanism was found. The affected quadriceps had only 66% of concentric power compared with the normal side. Eccentric power was only slightly reduced. Hamstring muscle strength was also considerably reduced.

Surgical reattachment was performed. Through a 20 cm longitudinal incision, the muscle belly of the rectus femoris was fully mobilised. The muscle belly was embedded in a moderate amount of scar tissue. The proximal tendon, however, was surrounded by a dense mass of scar tissue. The tendon of the direct head was freed and traced back to its origin, the anterior inferior iliac spine, where the attachment was found to be normal. The muscle belly was brought proximally as far as possible (about 12 cm). The surrounding scar tissue

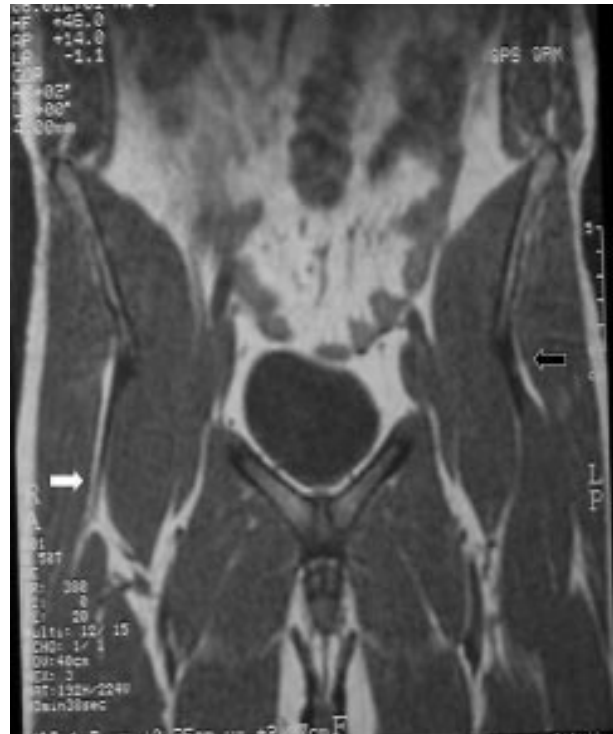

Figure 1 Magnetic resonance image of the thigh showing a normal rectus femoris tendon and muscle on the left (white arrow) and the proximal muscle avulsion on the right (black arrow) with a normal tendon still attached to the anterior inferior iliac spine and a very distally retracted muscle belly.

and some fibrosis of the muscle allowed muscle continuity to be restored by direct suture repair using No 2 Ethibond sutures.

After the operation, the knee was immobilised in an extension splint for six weeks. Supervised physiotherapy was then started in the form of a progressive range of movement and strengthening protocol.

At six months, the patient was pain free, his thigh had a normal appearance, and no lump was apparent during quadriceps contraction. He was able to sprint and had returned to problem-free semiprofessional football. KIN-COM tests showed that the concentric power had been restored to almost normal (fig 2).

DISCUSSION

Strain injuries of the rectus femoris muscle are common. These injuries can occur during both eccentric and explosive forceful contractions of the muscle.¹⁻³ Gait analysis has shown that the primary function of the quadriceps during running is

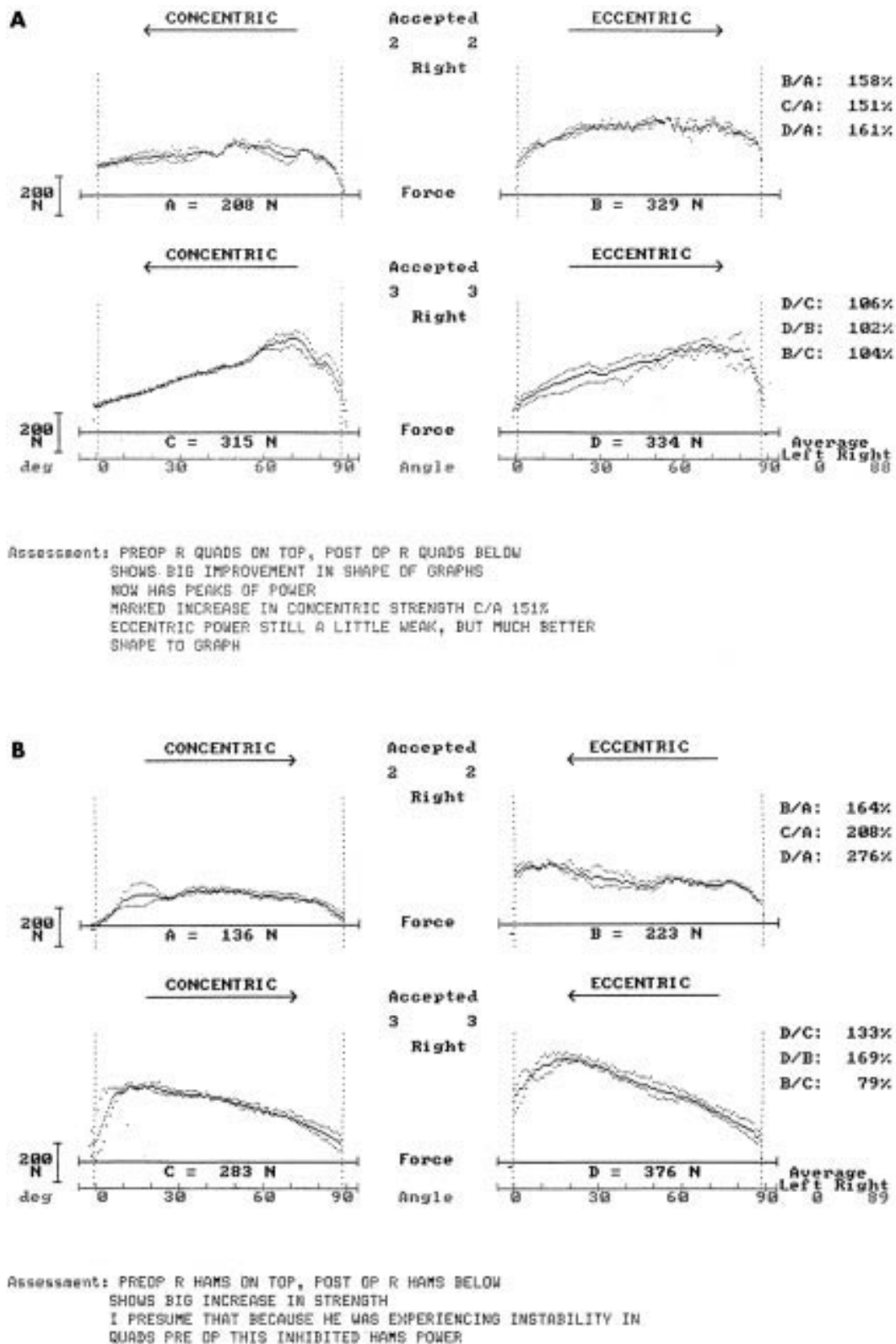


Figure 2 Readouts of KinCom test results before and after surgery. (A) Right quadriceps before (top) and after (bottom) surgery. (B) Right hamstring before (top) and after (bottom) surgery.

deceleration of knee flexion at heel strike, which is accompanied by simultaneous contraction with the hamstrings during the support phase.⁴ The rectus femoris muscle is therefore most often injured while regulating hip and knee motion. During soccer, the rectus femoris can be injured as the quad-

riceps contracts forcefully to extend the knee and flex the hip to strike the ball. The muscle has a high percentage of type II muscle fibres which enable it to produce rapid forceful activity.⁵ As the rectus femoris is the only biarticular muscle of the quadriceps, it is not surprising that it is the one most commonly injured.⁶

Avulsion type ruptures of the direct head of the rectus femoris muscle from its origin, the anterior inferior iliac spine, are well documented, as are ruptures occurring at the distal tendon junction where the rectus inserts into the quadriceps tendon.⁷ Less common are injuries at the musculotendinous junction. Injuries at this level have been identified by Temple *et al*,⁸ who described tears appearing as pseudotumours in seven cases. However, we have found no reports of complete ruptures at this level. In addition, we have found no reports describing the operative repair of a chronic rupture.

Clinical examination showed a unique feature in that the muscle belly retracted distally (towards the knee) during quadriceps contraction.

Ehman and Berquist⁹ have shown that contrast enhanced magnetic resonance imaging should be the investigation of choice.

Concentric and eccentric strength testing was performed before and after surgery using the KIN-COM III isokinetic dynamometer. Before the operation, the quadriceps showed considerable reduction in concentric power compared with the normal side with no peak of power (fig 2). Interestingly, the hamstrings also showed reduced power. This was despite intensive physiotherapy, and we speculate that this was due to the lack of a normally functioning quadriceps mechanism resulting in wasting of its antagonists. Concentric power was restored to both the quadriceps and hamstrings after surgery, with peak power similar to the normal side.

Because of the paucity of literature on this injury, there was no definitive treatment protocol. However, Cross *et al*¹⁰ report satisfactory results after surgical reattachment of chronic complete proximal hamstring tendon avulsions. We felt that this article was a reasonable guide for setting up our own treatment protocol for this case, as both injuries deal with proximal injuries rather than the more common distal tendon avulsions. Cross *et al* also immobilised the knee after surgical reattachment of thigh muscles (albeit posteriorly compared with our anterior injury) rather than immobilising the hip, and we felt that immobilising the hip would have been more impractical. Non-operative treatment can be considered in inactive people, but in this patient we believe that surgical repair was indicated. We felt that immobilisation of the hip after surgery would have been both impractical and perhaps detrimental to the eventual outcome. Immobilisation of the hip alone would have been insufficient to protect the repair and would therefore still have necessitated immobilisation of

Take home message

Late repair of a chronic musculotendinous avulsion injury to the direct head of the rectus femoris can still give an excellent result.

the knee where the arc of movement and hence excursion of the hamstrings is greater than in the hip. We felt that immobilisation of the knee alone would provide satisfactory protection of the repair.

This patient made a full recovery and was able to return to his previous level of sport, justifying the surgical repair, even at this late stage after the injury.

Authors' affiliations

R Straw, K Colclough, G Geutjens, Department of Orthopaedic Surgery, Derbyshire Royal Infirmary, Derby, UK

Correspondence to: Mr Geutjens, Derbyshire Royal Infirmary, London Road, Derby DE1 2QY, UK; Guido.Geutjens@sdah-tr.trent.nhs.uk

Accepted 13 June 2002

REFERENCES

- 1 Garrett WE Jr. Muscle strain injuries: clinical and basic aspects. *Med Sci Sports Exerc* 1990;**22**:436-43.
- 2 Rask MR, Lattig GJ. Traumatic fibrosis of the rectus femoris muscle. *JAMA* 1972;**221**:268-9.
- 3 Renstrom PA. Tendon and muscle injuries in the groin area. *Clin Sports Med* 1992;**11**:815-31.
- 4 Elliot BC, Blanksby BA. The synchronization of muscle activity and body segment movements during a running cycle. *Med Sci Sports Exerc* 1979;**11**:322-7.
- 5 Garrett WE Jr, Cardiff JC, Bassett FH III. Histochemical correlates of hamstring injuries. *Am J Sports Med* 1984;**12**:98-103.
- 6 Zarins B, Ciullo JV. Acute muscle and tendon injuries in athletes. *Clin Sports Med* 1983;**2**:167-82.
- 7 Hasselman CT, Best TM, Hughes C, *et al*. An explanation for various rectus femoris strain injuries using previously undescribed muscle architecture. *Am J Sports Med* 1995;**23**:493-9.
- 8 Temple HT, Kuklo TR, Sweet DE, *et al*. Rectus femoris muscle appearing as a pseudotumor. *Am J Sports Med* 1998;**26**:544-8.
- 9 Ehman RL, Berquist TH. Magnetic resonance imaging of musculoskeletal trauma. *Radiol Clin North Am* 1986;**24**:291-319.
- 10 Cross MJ, Vandersluis R, Wood D, *et al*. Surgical repair of chronic complete hamstring tendon rupture in the adult patient. *Am J Sports Med* 1998;**26**:785-9.