

## ORIGINAL ARTICLE

## Comparing spondylolysis in cricketers and soccer players

P L Gregory, M E Batt, R W Kerslake

*Br J Sports Med* 2004;**38**:737–742. doi: 10.1136/bjism.2003.008110

**Objective:** To determine whether the location of spondylolysis in the lumbar spine of athletes differs with biomechanical factors.

**Methods:** Single photon emission computerised tomography and reverse gantry computerised tomography were used to investigate 42 cricketers and 28 soccer players with activity related low back pain. Sites of increased scintigraphic uptake in the posterior elements of the lumbar spine and complete or incomplete fracture in the pars interarticularis were compared for these two sports.

**Results:** Thirty seven (90.4%) cricketers and 23 (82.1%) soccer players studied had sites of increased uptake. In cricketers, these sites were on the left of the neural arch of 49 lumbar vertebrae and on the right of 33 vertebrae. In soccer players there was a significantly different proportion, with 17 sites on the left and 28 on the right (difference of 22.0%; 95% confidence interval (CI) 0.04 to 0.38). Lower lumbar levels showed increased scintigraphic uptake more frequently than did higher levels, although the trend was reversed at L3 and L4 in soccer. Forty spondylolyses were identified in the lumbar vertebrae of the cricketers and 35 spondylolyses in the soccer players. These comprised 26 complete and 14 incomplete fractures in the cricketers, and 25 complete and 10 incomplete fractures in the soccer players. Similar numbers of incomplete fractures were found either side of the neural arch in soccer players, but there were more incomplete fractures in the left pars (14) than in the right (2) in cricketers. The proportion of incomplete fractures either side of the neural arch was significantly different between cricket players and soccer players (difference of 37.5%; 95% CI 0.02 to 0.65). Most complete fractures were at L5 (66.7%) and more were found at L3 (15.7%) than L4 (6.9%). However, incomplete fractures were more evenly spread though the lower three lumbar levels with 41.7% at L5, 37.5% at L4, and 20.8% at L3.

**Conclusions:** Fast bowling in cricket is associated with pars interarticularis bone stress response and with development of incomplete stress fractures that occur more frequently on the left than the right. Playing soccer is associated with a more symmetrical distribution of bone stress response, including stress fracturing. Within cricketers, unilateral spondylolyses tend to arise on the contralateral side to the bowling arm.

See end of article for authors' affiliations

Correspondence to:  
Dr P L Gregory, University  
of Nottingham, Centre for  
Sports Medicine,  
Nottingham NG7 2UH,  
UK; peter.gregory@  
nottingham.ac.uk

Accepted  
9 December 2003

Athletes with low back pain may have sustained a stress fracture of a pars interarticularis of the lumbar spine. The pars interarticularis are found between the inferior and superior articular processes of the neural arch at the junction between the laminae and pedicles. Thus there are two pars interarticularis at each vertebral level; one on the left and one on the right. Spondylolysis is a separation in the neural arch, usually seen in the pars interarticularis. A spondylolysis may be complete if it passes right through the pars or incomplete if the fracture appears on one side of the cortex and not the other.

Spondylolysis may occur because of cyclical loading with repetitive activities of sport and will result in a stress response in the bone. Rarely the pars interarticularis may fracture acutely with trauma.<sup>1</sup> Some spondylolyses may result from dysplasia with failure of normal ossification.<sup>1–5</sup> Bilateral spondylolysis may allow forward displacement of the upper vertebrae and separation of the anterior aspects of the vertebra from its neural arch. This is known as spondylolisthesis and is never present at birth. Spondylolisthesis can be identified on plain radiography, and studies suggest that prevalence increases with age between 6 and 40 years, with a prevalence in asymptomatic adults of 4–6%.<sup>6,7</sup>

Sporting activity is an important predisposing factor in the development of spondylolysis. Soler reviewed 3152 elite Spanish athletes initially screened with plain radiographs and found an 8.02% rate for spondylolysis,<sup>8</sup> and Rossi found 12.5% cases in 3132 competitive athletes.<sup>9</sup> In a study by Morita of 381 patients aged 6–18 years with spondylolysis, 376 were described as very active in sport, yet only two gave a

history of trauma.<sup>10</sup> Several sports are associated with the development of spondylolysis: cricket,<sup>11–13</sup> gymnastics,<sup>8,14–16</sup> American football,<sup>17–19</sup> soccer,<sup>10</sup> baseball,<sup>10</sup> and weightlifting.<sup>16</sup> Soler found a rate of 26.7% for spondylolysis in throwing sports,<sup>8</sup> and it is thought that fast bowling is the risk activity in cricket.<sup>11–13</sup> Repeated hyperextension and rotation of the lumbar spine are proposed as predisposing factors in the aetiology of spondylolyses and these are features of fast bowling and gymnastics.

Back pain may indicate the development of spondylolysis. Micheli found 47% of patients under 18 years of age presenting to a sports medicine clinic with back pain had spondylolysis compared with 5% of adults over 21 years presenting with back pain to a back clinic.<sup>20</sup> Morita found 32% of patients <19 years old who had been referred to a sports clinic with backache had spondylolysis.<sup>10</sup> Athletes presenting with activity related low back pain, which tends to be worse with lumbar extension, should be investigated for spondylolysis. Bone scintigraphy determines whether there is increased metabolic activity in sites of the lumbar spine. Planar bone scan cannot reliably distinguish between increased metabolic activity in the posterior neural arch and the underlying vertebral body, but single photon emission computerised tomography (SPECT) improves diagnostic localisation of bone by achieving separation of bony structures that overlap on standard planar images.<sup>21</sup> Our radiologist uses the results of SPECT to guide the use of

**Abbreviations:** rg-CT, reverse gantry computerised tomography; SPECT, single photon emission computerised tomography

reverse gantry computerised tomography (rg-CT), which is superior to conventional CT scanning because slices are perpendicular to the fracture plane in the pars interarticularis.<sup>22</sup> With rg-CT, morphological abnormalities in the pars may be identified and characterised as complete or incomplete fractures.

Many young people in the UK play soccer or cricket. Spondylolyses occur in those playing either sport. The biomechanics and demands involved in these sports are very different. Soccer involves multiple short sprints and kicking a ball with either foot, although usually one foot predominates, most often the right foot. It also involves heading the ball and occasionally throwing it with two hands above the head, and collision with opponents and contact with the ground. Cricket has three main facets; batting, bowling, and fielding. Batting involves multiple short sprints and striking a small ball with a wooden bat held in both hands. Bowling involves propelling the ball from a hand held above the head and with the elbow maintained straight. Fast bowling demands multiple short sprints. Fielding involves throwing the ball and using the hands or body to stop the ball. Cricketers use a preferred hand, usually the right, to bowl and throw in the field, and they tend to specialise in one type of bowling or batting. Cricket rarely involves collision, but contact with a hard ball and the ground is common.

Taking into consideration the different demands, and in particular the different biomechanical features, it was hypothesised that the typical location of bone stress reaction and spondylolysis in the lumbar spine of cricketers would differ from the typical location in soccer players. Therefore, the aim of this study was to determine whether the location of spondylolysis in the lumbar spine of athletes differs in soccer players and cricketers. Such a finding would indicate that the different biomechanical factors associated with these sports produce clinically significant different patterns of stress in the posterior element of the lumbar spine.

## METHODS

SPECT and rg-CT results of 42 cricketers and 28 soccer players presenting to the Centre for Sports Medicine or the Spinal Surgery Unit at Queens Medical Centre, Nottingham with low back pain related to their sporting activity were analysed.

The medical records of these 60 sportsmen were reviewed. Of the 42 cricketers, only one was female. Seven played international cricket. Nineteen were professional cricketers, and there were also eight amateurs representing their county or country at certain ages. Only two were not bowlers, and of the bowlers, only one was a spin bowler. Two fast bowlers bowled lefthanded. The median age at onset of low back pain was 19.7 years (range 13.0 to 29.9). Low back pain was predominantly left sided in 25, right sided in 7, and symmetrical in 10.

Of the 28 soccer players, all were male. Eight played professionally, while seven were aspiring to professional football and trained with academies or were on youth training schemes at professional soccer clubs. Only one was a goalkeeper; the rest were outfield players. The dominant leg of these soccer players had not been recorded. The median age at onset of low back pain was 17.5 years (range 11.5 to 44.0 years). Pain was predominantly left sided in 9, right sided in 4, and symmetrical in 15. This was a statistically different distribution of pain site to that of the cricketers ( $p = 0.033$ ;  $\chi^2$ ).

Planar bone scintigraphy and SPECT imaging was performed after the injection of 600 MBq 99m-technetium methylenediphosphonate intravenously. Using a dual headed gamma camera with a low energy ultrahigh resolution collimator over a 360° circular orbit, 64 images of the lumbar

region were acquired. The images were reconstructed by filtered back projection with pre-filtering, and were viewed interactively onscreen in axial, sagittal, and coronal planes by a senior musculoskeletal radiologist and selected images were hard copied. Increased scintigraphic activity was reported with respect to the activity in adjacent vertebral bodies and posterior elements. Where abnormal, the level, side, and specific location were determined.

CT scans were obtained with a reverse gantry angle (aligned from a lateral scout view to lie between the superior and inferior articular processes, with a maximum angulation of 25°). The sections were of 2 mm thickness, obtained at 2 mm intervals (3 mm sections were obtained in a small number of earlier cases) and multiplanar reformats were produced in most cases. An experienced musculoskeletal radiologist reviewed hard and soft copy images. Selective rg-CT imaging was performed with scanning through all posterior elements with increased scintigraphic activity found on SPECT and occasionally through L5 or L4 despite negative SPECT. The scintigraphic findings were available when the CT scans were reported. The integrity or otherwise of the pars interarticularis and other posterior element structures were reported as well as abnormalities of size, sclerosis, and the size and margins of any osseous defect.

Results were stored in a Microsoft Access (Redland, WA, USA) database, and Wilson's method was used to calculate confidence intervals on differences between proportions of lesions either side of the lumbar spine with statistical significance sought at the 5% level.

## RESULTS

The intervals between onset of pain, SPECT scan, and rg-CT are given in table 1. Only five cricketers (9.6%) and five soccer players (17.9%) had no increase in scintigraphic uptake on SPECT. There were 82 sites of increased uptake on SPECT in this study of 42 lumbar spines of cricketers and 45 sites of increased scintigraphic uptake in the 28 lumbar spines of soccer players. The side and lumbar level of these sites of increased uptake are detailed in table 2. Among the cricketers, these sites of increased scintigraphic activity occurred on the left side of the neural arch in 49 and on the right in 33, while in soccer players these occurred on the left side of the neural arch in 17 and on the right in 28. There was a significant difference between the percentage of sites of increased scintigraphic uptake on left and right sides between cricket players and soccer players (difference 22.0%; 95% CI 0.04 to 0.38).

**Table 1** Characteristics of cricketers and soccer players investigated for spondylolysis

	Cricketers	Soccer players
Number	42	28
Age (years)	19.7 (13.0 to 29.9)	17.5 (11.5 to 44.0)
Interval from onset of pain to SPECT (days)	284 (26 to 5967)	186 (45 to 2414)
Interval from SPECT to rg-CT (days)	7 (0 to 203)	2 (18 to 81)
Number (%) of players with one or more sites of increased scintigraphic uptake	37 (90.4%)	23 (82.1%)
Pars interarticularis studied by rg-CT	174	86
Number (%) players with one or more spondylolyses	28 (66.7%)	19 (67.8%)

Values shown as median (range), unless otherwise indicated.

**Table 2** SPECT findings in 42 cricketers and 28 soccer players: sites of increased scintigraphic uptake

Lumbar level	Side of posterior elements						Cricketers and soccer players (total)
	Cricketers			Soccer players			
	Right	Left	Sub-total	Right	Left	Sub-total	
L1	2	3	5	1	0	1	6
L2	5	4	9	1	1	2	11
L3	6	12	18	5	7	12	30
L4	6	12	18	4	1	5	23
L5	14	18	32	17	8	25	57
Total	33*	49*	82	28*	17*	45	127

\*Significant difference between percentage on left and right sides between cricket players and soccer players (p<0.05).

The most commonly affected lumbar level was the fifth; 32 times in cricketers and 25 times in soccer players (table 2). The trend for the lower lumbar vertebrae to be affected more than the higher was reversed at L3 in soccer players, in whom there were 12 sites of increased scintigraphic uptake at L3 and only five at L4. Table 2 shows that this difference came mostly from left sided sites of increased uptake, where seven pars were affected at L3 and only one at L4.

In the investigation of 42 cricketers, 174 pars interarticulares were imaged by rg-CT, and 40 spondylolyses were identified. The lumbar level and side of these spondylolyses are detailed in tables 3 and 4. Additionally, two articular process fractures were found. Fourteen cricketers had no fracture on CT. There were 24 complete and 16 incomplete fractures. Seven incomplete fractures were seen on the left fourth lumbar pars interarticularis, an example of which is shown in fig 1, while no complete or incomplete fractures

were seen on the right at L4. Over half of the spondylolyses were at L5, and those at L6 were complete fractures. No spondylolysis was identified in 14 cricketers. CT imaging for one soccer player was not available for review in this study, leaving rg-CT images of 86 pars interarticulares for analysis. In nine soccer players, no spondylolysis was identified, but 35 spondylolyses were identified in the total group. Complete fractures were described 25 times and incomplete fractures 10 times. There were equal numbers of incomplete fractures on either side of the neural arch and six of the incomplete fractures were at L5. There was a significant difference between the percentage of spondylolyses on left and right sides between cricket players and soccer players (difference 23.7%; 95% CI 0.01 to 0.43).

Incomplete fractures identified on rg-CT are detailed in table 3. There was also significant difference between the percentage of incomplete fractures on left and right sides

**Table 3** Reverse gantry findings in 42 cricketers and 27 soccer players: spondylolyses (incomplete fractures)

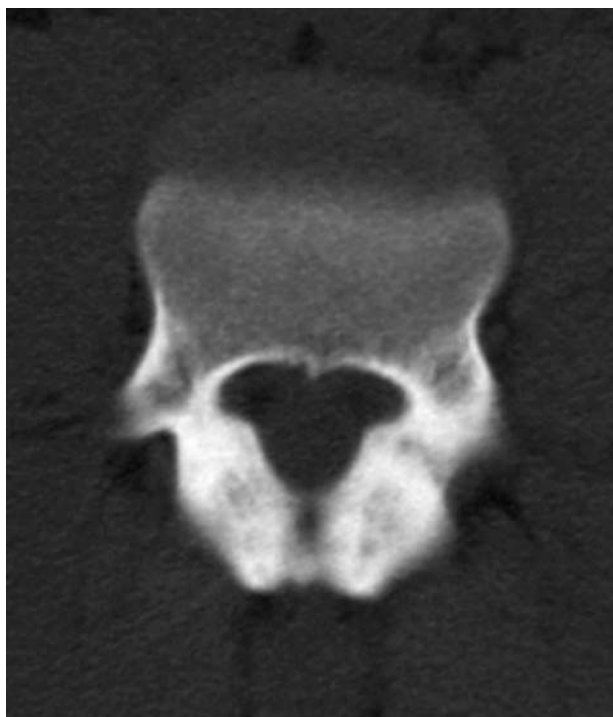Lumbar level	Pars interarticularis						Cricketers and soccer players (total)
	Cricketers			Soccer players			
	Right	Left	Sub-total	Right	Left	Sub-total	
L1	0	1	1	0	0	0	1
L2	0	0	0	1	0	1	1
L3	0	4	4	1	0	1	5
L4	0	7	7	1	1	2	9
L5	2	2	4	2	4	6	10
Total*	2*	14*	16	5*	5*	10	26

\*Significant difference between percentage on left and right sides between cricket players and soccer players (p<0.05).

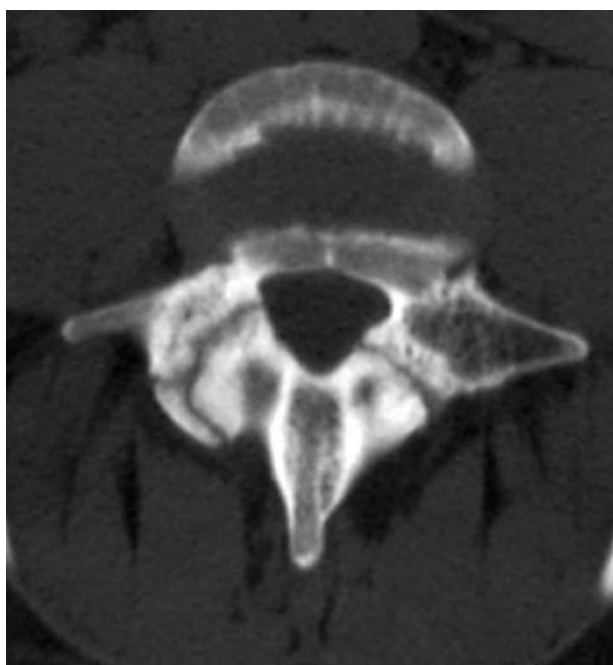
**Table 4** Reverse gantry findings in 42 cricketers and 27 soccer players: spondylolyses (complete fractures)

Lumbar level	Pars interarticularis						Cricketers and soccer players (total)
	Cricketers			Soccer players			
	Right	Left	Either left or right	Right	Left	Either left or right	
L1	0	0	0	0	0	0	0
L2	1	2	3	0	1	1	4
L3	1	3	4	1	3	4	8
L4	0	1	1	1	1	2	3
L5	6	10	16	10	8	18	34
Total	8	16	24	12	13	25	49

between cricket players and soccer players (difference 37.5%; 95% CI 0.02 to 0.65). Complete fractures identified on rg-CT are presented in table 4. The difference between the percentage of sites of complete fractures on left and right sides between cricket players and soccer players did not reach



**Figure 1** Reverse gantry computerised tomogram of L4 in an 18 year old cricketer, a fast bowler who uses his right arm to bowl, showing an incomplete fracture in the left pars interarticularis.



**Figure 2** Reverse gantry computerised tomogram of L5 in a 22 year old soccer player, showing bilateral complete spondylolyses with 2–3 mm separation.

statistical significance (difference 14.7%; 95% CI  $-0.12$  to  $0.39$ ).

More than one spondylolysis was identified in 10 cricketers. All six complete fractures at L5 on the right were paired with complete fractures on the left and all looked chronic with smooth sclerotic bone margins. One cricketer had a fracture line extending from the pedicle at L2 to the articular process on the contralateral side. Of two incomplete fractures on the right at L5, one fracture occurred in one of the only two cricketers known to bowl left handed in this cohort; the other occurred in a professional cricketer. The 14 incomplete fractures identified in the left pars interarticularis occurred in eight professional cricketers and four cricketers playing representative cricket for their counties and with aspirations to play professionally. All were fast, right handed bowlers. Two of these cricketers had two incomplete fractures in adjacent vertebrae on the left side. One international fast bowler had complete fractures at L2 to L4 with an incomplete fracture at L3, all in the left pars interarticularis.

Bilateral complete fractures at L5 were present in seven soccer players. An example is shown in fig 2. One of these players also had bilateral fractures at L2. The fracture on the right at L2 was incomplete. One professional soccer player had two bilateral spondylolyses. These were at L4 and L3 and the fracture on the right at L3 was incomplete. A further professional soccer player had four fractures identified: bilateral complete fractures at L3, an incomplete fracture at L4 on the right, and a complete fracture at L5 on the right. One keen amateur soccer player who also played county representative cricket and bowled left handed had two incomplete fractures identified; one at L4 on the left and the other at L5 on the right.

In cricketers, there were 23 unilateral spondylolyses, comprised of 16 incomplete and 7 complete fractures. In soccer players, 8/11 unilateral fractures were incomplete.

## DISCUSSION

This study provides data on patients involved predominantly in two popular sports in England. Large numbers of enthusiastic amateurs and relatively few professionals play both cricket and soccer, yet in the two cohorts there were large proportions of professional sportsmen and some internationals. Among the amateurs, many represented counties or had aspirations for a career in the sport professionally, suggesting a high level of involvement in the sport. It was surmised that the techniques of the sports have been repeated and employed with considerable skill and reproducibility in both groups. It is in these circumstances that stress fractures are most likely.

The results of this study are consistent with those describing a high incidence of bone stress response in cricketers;<sup>11–13</sup> however, this problem has only been reported in soccer players by Morita,<sup>10</sup> although soccer is one of the most popular sports worldwide. The percentage of cricketers (90.4%) and soccer players (82.1%) with a bone stress response in the posterior elements of the lumbar spine indicated by increased scintigraphic uptake on SPECT was high in those going on to have rg-CT. Typically those with negative SPECT would enter a different diagnostic and management algorithm at this point, though in some, the clinical suspicion of a spondylolysis remained strong enough for CT to be performed. Selective rg-CT scanning, usually based on the SPECT findings, identified spondylolyses in 66.9% of the cricketers and 66.7% of soccer players. In those 10 patients with no increased scintigraphic uptake on SPECT, only one had an abnormality identified on CT, a cricketer with an incomplete fracture at L4.

**WHAT IS ALREADY KNOWN ON THIS TOPIC**

- It has been suggested that spondylolyses are dysplastic in origin or are stress fractures.
- The biomechanical stresses involved in sports such as cricket produce these stress fractures in the pars interarticularis.

**WHAT THIS STUDY ADDS**

- Asymmetrical stresses of fast bowling in cricket produce corresponding patterns of bone stress response and spondylolyses in the spine, typically on the contralateral side to the bowling arm.
- Soccer is associated with a symmetrical pattern of spondylolyses.
- Incomplete spondylolyses are more common than previously described and are found to be more evenly spread in the lower three lumbar levels than complete spondylolyses, which are predominantly at L5.

Incomplete fractures are thought to be spondylolyses in evolution, and may heal before becoming complete. A high proportion (34.7%) of the fractures identified on CT were incomplete. This finding is noteworthy, as reference to incomplete lesions are rare in the literature.<sup>22–23</sup> Unilateral fractures tended to be incomplete, and bilateral fractures tended to be complete. We speculate that once a spondylolysis has become complete there is instability in the vertebral ring, leading to increased stress on the contralateral pars interarticularis, which then tends to fracture as well.

The asymmetrical distribution of increased scintigraphic uptake in cricketers was consistent with the higher number of incomplete fractures on the left side of the neural arch. More detailed analysis supports Hardcastle's suspicion that these lesions tend to be on the contralateral side to the bowling arm in fast bowlers.<sup>13</sup> It was speculated that the more symmetrical distribution of scintigraphic uptake and spondylolyses among the soccer player reflects their tendency to use either foot to kick the football with a variety of techniques involving various patterns of spinal movements. Soccer players do favour one foot, but do not use this exclusively at higher levels of the game, whereas it would be unusual for a fast bowler not to use one arm to bowl with exclusively. The techniques employed by fast bowlers vary, and a study by Elliot<sup>24</sup> suggested that certain techniques involving a forward facing back foot placement with a side facing shoulder placement were most at risk. These opinions were supported by Bartlett.<sup>25</sup>

The lesions in the pars have not been described relative to the dominant side of the bowlers in this study. The concept of dominance is not clear in cricket; cricketers may bowl left handed and yet bat right handed.

Lower lumbar levels showed increased scintigraphic uptake more often than did higher levels, although the trend was reversed at L3 and L4 in soccer. Complete fractures showed a similar trend towards higher frequency at L3 than L4 in soccer players and cricketers; however, most complete fractures were at L5 (66.7%). Blanda<sup>26</sup> reported 85% of spondylolyses at L5, Congeni<sup>22</sup> 71%, and Grogan<sup>23</sup> 97%. Standaert summarised in a review that 85–95% occurred at

L5 and 5–15% at L4, with more proximal levels affected rarely.<sup>27</sup> Among cricketers, incomplete fractures were spread more evenly throughout the lowest three lumbar levels, but the most common site was L4, where 43.8% of incomplete lesions were found.

**CONCLUSIONS**

Spondylolyses occur in cricketers and soccer players and should be considered as a cause of activity related low back pain, which is exacerbated by lumbar extension. Fast bowling in cricket is associated with pars interarticularis bone stress response and development of incomplete stress fractures more frequently on the left than the right. Playing soccer is associated with a more symmetrical distribution of bone stress response, including stress fracturing. In cricketers, unilateral spondylolyses tend to arise on the contralateral side to the bowling arm. These findings may be explained by the repetitive spinal movements of fast bowling, which contribute to propulsion of a ball from the same hand and in one direction relative to the trunk, while a variety of spinal movements contribute to kicking a football in various directions and with either foot in soccer, even though players often favour one foot. More research is required to understand how the techniques of each sport lead to these injuries.

**Authors' affiliations**

**P L Gregory**, University of Nottingham, Nottingham, UK

**M E Batt, R W Kerslake**, Queens Medical Centre, Nottingham, UK

Conflict of interest: none declared

**REFERENCES**

- 1 **Wiltse LL**, Newman PH, Macnab I. Classification of spondylolysis and spondylolisthesis. *Clin Orthop* 1976;**117**:23–9.
- 2 **Schwegel A**. *Knochenvarietäten* 1859;**5**:283.
- 3 **Rambaud A**, Renault C. *Origine et développement des os*. Paris: F Chamerot, 1864.
- 4 **Willis TA**. The separate neural arch. *J Bone Joint Surg* 1931;**13**:709–21.
- 5 **Wiltse LL**. The etiology of spondylolisthesis. *J Bone Joint Surg Am* 1962;**44-A**:539–59.
- 6 **Rowe GG**, Roche MB. The etiology of the separate neural arch. *J Bone Joint Surg Am* 1953, **35-A**:102.
- 7 **Fredrickson BE**, Baker D, McHolick WJ, et al. The natural history of spondylolysis and spondylolisthesis. *J Bone Joint Surg Am* 1984;**66**:699–707.
- 8 **Soler T**, Calderon C. The prevalence of spondylolysis in the Spanish elite athlete. *Am J Sports Med* 2000;**28**:57–62.
- 9 **Rossi F**, Dragoni S. Lumbar spondylolysis: occurrence in competitive athletes. Updated achievements in a series of 390 cases. *J Sports Med Phys Fitness* 1990;**30**:450–2.
- 10 **Morita T**, Ikata T, Katoh S, et al. Lumbar spondylolysis in children and adolescents. *J Bone Joint Surg Br* 1995;**77**:620–5.
- 11 **Foster D**, John D, Elliott B, et al. Back injuries to fast bowlers in cricket: a prospective study. *Br J Sports Med* 1989;**23**:150–4.
- 12 **Annear PT**, Chakera TM, Foster DH, et al. Pars interarticularis stress and disc degeneration in cricket's potent strike force: the fast bowler. *Aust N Z J Surg* 1992;**62**:768–73.
- 13 **Hardcastle P**, Annear P, Foster DH, et al. Spinal abnormalities in young fast bowlers. *J Bone Joint Surg Br* 1992;**74**:421–5.
- 14 **Dixon M**, Fricker P. Injuries to elite gymnasts over 10 yr. *Med Sci Sports Exerc* 1993;**25**:1322–9.
- 15 **Jackson DW**, Wiltse LL, Cirincione RJ. Spondylolysis in the female gymnast. *Clin Orthop* 1976;**117**:68–73.
- 16 **Rossi F**. Spondylolysis, spondylolisthesis and sports. *J Sports Med Phys Fitness* 1978;**18**:317–40.
- 17 **McCarroll JR**, Miller JM, Ritter MA. Lumbar spondylolysis and spondylolisthesis in college football players. A prospective study. *Am J Sports Med* 1986;**14**:404–6.
- 18 **Ferguson RJ**, McMaster JH, Stanitski CL. Low back pain in college football linemen. *J Sports Med* 1974;**2**:63–9.
- 19 **Semon RL**, Spengler D. Significance of lumbar spondylolysis in college football players. *Spine* 1981;**6**:172–4.
- 20 **Micheli LJ**, Wood R. Back pain in young athletes. Significant differences from adults in causes and patterns. *Arch Pediatr Adolesc Med* 1995;**149**:15–18.
- 21 **Collier BD**, Johnson RP, Carrera GF, et al. Painful spondylolysis or spondylolisthesis studied by radiography and single-photon emission computed tomography. *Radiology* 1985;**154**:207–11.

- 22 **Congeni J**, McCulloch J, Swanson K. Lumbar spondylolysis. A study of natural progression in athletes. *Am J Sports Med* 1997;**25**:248–53.
- 23 **Grogan JP**, Hemminghytt S, Williams AL, *et al*. Spondylolysis studied with computed tomography. *Radiology* 1982;**145**:737–42.
- 24 **Elliott BC**, Hardcastle P, Burnett A, *et al*. The influence of fast bowling and physical factors on radiological features in high performance fast bowlers. *Sports Med Training Rehabil* 1992;**3**:113–120.
- 25 **Bartlett R**, Stockill N, Elliott BC, *et al*. The biomechanics of fast bowling in men's cricket: A review. *J Sports Sci* 1996;**14**:403–424.
- 26 **Blanda J**, Bethem D, Moats W, *et al*. Defects of pars interarticularis in athletes: a protocol for nonoperative treatment. *J Spinal Dis* 1993;**6**:406–11.
- 27 **Standaert CJ**, Herring SA. Spondylolysis: a critical review. *Br J Sports Med* 2000;**34**:415–22.

## ELECTRONIC PAGES .....

### Online case reports

The following electronic only articles are published in conjunction with this issue of *BJSM* (see also pages 724, 753, and 757).

#### **Paraplegia secondary to fracture-sublucation of the thoracic spine sustained playing rugby union football**

A J Walsh, S Shine, F McManus

Fractures of the spinal column during rugby matches of all codes are rare but catastrophic, especially when associated with spinal cord injury. The cervical spine is vulnerable during trauma to the head and neck in contact sports. Spinal injuries reported during rugby matches have almost exclusively involved the cervical region, often with neurological sequelae. This is the first reported case of paraplegia caused by a fracture-dislocation of the thoracic spine resulting from a low velocity rugby union injury.

(*Br J Sports Med* 2004;**38**:e32) <http://bjsm.bmjournals.com/cgi/content/full/38/5/e32>

#### **Bridging osteophyte of the anterosuperior sacroiliac joint as a cause of lumbar back pain**

K A Parmar, M Solomon, A Loeffler, *et al*

A case report is presented of a patient with an anterosuperior osteophytic bone bridge of the sacroiliac joint causing lumbar back pain. After prolonged physiotherapy, the bone bridge was excised, with complete resolution of the symptoms. Excision should only be considered in cases of symptomatic sacroiliac joint pain that does not respond to rehabilitation programmes and conservative treatment.

(*Br J Sports Med* 2004;**38**:e33) <http://bjsm.bmjournals.com/cgi/content/full/38/5/e33>