

Magnetic resonance imaging as the primary imaging modality in children presenting with acute non-traumatic hip pain

P M White, J Boyd, T F Beattie, M Hurst, G M Hendry

Abstract

The role of magnetic resonance imaging (MRI) in children presenting with acute non-traumatic hip pain was evaluated prospectively. Hip MRI was performed in addition to standard investigations (arthrosonography ± hip radiographs) in 50 children presenting to the accident and emergency department of a paediatric hospital. MRI was performed on an open 0.23T system and comprised gradient echo T1 weighted coronal, fast spin echo T2 weighted coronal and inversion recovery spin echo (IRSE) axial sequences. Diagnostic quality MRI examinations were obtained in 94% of children. The IRSE sequence was the most reliable at determining underlying disorder ($p < 0.002$). Interobserver agreement on the MRI examinations was very good with unweighted κ value of 0.89, 95% confidence intervals 0.79, 0.99. Sensitivity of MRI was 0.79 (0.68, 0.90), specificity 1.00 (0.89, 1.00), accuracy 0.81 (0.70, 0.92), PPV 1.00 (0.89, 1), NPV 0.36 (0.25, 0.47). Sensitivity of standard imaging was 0.70 (0.54–0.86), specificity 0.57 (0.41, 0.73), accuracy 0.72 (0.56, 0.88), PPV 0.91 (0.75, 1.00), NPV 0.24 (0.08, 0.40). MRI correctly identified all seven children with serious underlying disorder whereas conventional imaging correctly diagnosed only two. Pelvic musculoskeletal infection was associated with the combination of marked alteration in signal in tissues adjacent to a symptomatic hip and an erythrocyte sedimentation rate of >20 mm 1st h ($p < 0.0001$). In conclusion, MRI is a practical, well accepted and accurate non-invasive imaging technique in children presenting with acute non-traumatic hip pain. Combined with inflammatory markers MRI can be used to determine those children who require aggressive management. Where it is available, MRI is the imaging modality of choice in this condition.

(Emerg Med J 2001;18:25–29)

Keywords: magnetic resonance imaging; arthrosonography; hip pain; children

Acute hip pain is a common cause for children presenting to the accident and emergency (A&E) department. Accurate diagnosis is vital as the underlying disorder may be serious.^{1,2} Clinical differentiation of transient synovitis (the cause of over 90% of non-traumatic

cases^{2,3}) from more serious disease can be difficult. Investigations are required to exclude serious underlying disorders such as Perthe's disease, slipped capital femoral epiphysis (SCFE) and pelvic musculoskeletal sepsis.^{1,2} Typically the first line of imaging investigation has been arthrosonography ± hip radiographs.⁴

Magnetic resonance imaging (MRI) is sensitive and specific in the diagnosis of a wide range of hip disorders in both children and adults^{1,5-8} but the availability of MRI in the acute situation has been limited in many centres. Therefore despite the advantages of multiplanar imaging, excellent soft tissue contrast, reproducibility and the lack of ionising radiation, the use of MRI in the early investigation of acute hip pain in children has been limited. We report the development of a rapid, practical MR examination protocol for use as the primary imaging modality in acute non-traumatic hip pain in children, and evaluate its performance compared with our current standard imaging protocol.

Methods

Fifty consecutive children presenting with acute non-traumatic hip pain to the Accident and Emergency Department at the Royal Hospital for Sick Children (RHSC), Edinburgh were studied prospectively. MRI of the hips was performed in addition to the standard investigations: blood tests (full blood count and erythrocyte sedimentation rate (ESR) and arthrosonography of the hips. Plain radiographs were obtained if osteomyelitis, septic arthritis, avascular necrosis or SCFE were suspected. Local Regional Ethical Committee approval for the study was obtained. Parents were invited to participate at the time of presentation to A&E. Written informed consent was obtained. The only exclusion criterion was an absolute contraindication to undergoing MRI (no children fell into this category). MRI examinations were usually performed within 24 hours of presentation to A&E and all were performed within 72 hours. Sample size was determined as the minimum necessary for a method comparison study.⁹

MR examinations were performed on an open low field strength MRI system 0.23T Picker Outlook (Picker, Stevenage, UK). The examination protocol comprised a coronal gradient echo T1 weighted sequence (TR 140, TE 13, NEX 3, FOV 360, matrix 216×256 , 4 mm thick slices, acquisition time 3:01), then a coronal fast spin echo T2 weighted sequence (TR 4800, TE 120, NEX 2, FOV 360, matrix 192×256 , 5 mm thick slices, TA 3:50) and

Department of Radiology, Royal Hospital for Sick Children, 9 Sciennes Road, Edinburgh EH9 1LF, UK
P M White
J Boyd
M Hurst
G M Hendry

Department of Accident and Emergency, Royal Hospital for Sick Children
T F Beattie

Correspondence to:
Dr Hendry
(geomica@hotmail.com)

Accepted 22 September 2000

Table 1 Proportion of MR studies of diagnostic quality (consensus opinion)

	T1 coronal	T2 coronal	IRSE axial
Good quality diagnostic images	44 (88%)	35 (70%)	45 (90%)
Images degraded by movement but still diagnostic	2 (4%)	8 (16%)	1 (2%)
Images non-diagnostic	4 (8%)	7 (14%)	3 (6%)
Not done due to patient becoming too restless	0	0	2 (4%)

Table 2 Diagnostic utility of the MR sequences used (consensus opinion)

Sequence	Most useful sequence (of the three)	Least useful sequence (of the three)
T1 coronal	2 (4.3%)	24 (51.1%)
T2 coronal	9 (19.1%)	10 (21.3%)
IRSE axial	24 (51.1%)	2 (4.3%)
No difference expressed	12 (25.5%)	11 (23.4%)

Table 3 Comparison of MRI with the standard imaging (47 of 50 cases)

	MRI examination	95% CI	Standard imaging	95% CI
Sensitivity	0.79	0.68, 0.90	0.70	0.54, 0.86
Specificity	1.00	0.89, 1.00	0.57	0.41, 0.73
Accuracy	0.81	0.70, 0.92	0.72	0.56, 0.88
Positive predictive value (PPV)	1.00	0.89, 1.00	0.91	0.75, 1.002
Negative predictive value (NPV)	0.36	0.25, 0.47	0.24	0.08, 0.40

Table 4 Performance of MRI and conventional imaging compared with the standard of reference

Underlying disease	Standard of reference	MRI (consensus opinion)	USS +/- radiography (32 of 50 had radiography)
Pelvic musculoskeletal infection	5	5	0
Transient synovitis	37	26	28
Perthe's disease	1	1	1
Perthe's + transient synovitis	1	1	1
True negative (no active disease)	6	5	4
False negative (for underlying disease)	—	9	12
False positive	—	0	4

Table 5 Relation between altered signal on IRSE sequence (in soft tissue/marrow adjacent to symptomatic hip) and underlying disease

Underlying disease	Degree of altered signal returned			
	Grade 0	Grade 1	Grade 2	Grade 3
Transient synovitis	25	7	5	1
Pelvic musculoskeletal infection	0	0	2	3

finally an axial inversion recovery spin echo sequence (TR 994, TE 16, TI 90, NEX 2, FOV 340, matrix 256 × 180, 6 mm slices, TA 5:58) using a small body coil. Including the localiser sequence the examination took 14 minutes to perform. Sedation with Triclofos sodium elixir (Evans Medical, Leatherhead, UK) was available but only used in two children. General anaesthesia was not available for the children in this study. Contrast enhancement was not used in order to minimise the invasiveness of the examination.

Two radiologists (PMW, GMH) independently reviewed each MR examination on a workstation (Picker Vistar) and completed a standard proforma sheet for each case. Each observer was blinded to the report of the other and the results of other investigations. The presence of an effusion was determined if fluid (on MRI signal characteristics) was seen causing bulging of the hip joint capsule such that a bone to capsular distance of more than 3 mm or R/L asymmetry between hips of more than 2 mm was present.^{10 11} The size of effusion was

measured at the point of maximum depth of fluid using electronic callipers. A small joint effusion was taken as 3–6 mm depth and moderate to large effusion as 6 mm or greater. Where abnormal high signal was returned from soft tissue adjacent to a symptomatic hip on IRSE images, this was classified arbitrarily as grade 1 (slight increase in signal compared with normal soft tissue), grade 2 (moderate increase in signal) or grade 3 (marked increase in signal). The observers assessed on a 3 point scale whether each of the sequences provided information of diagnostic quality and which (if any) of the three sequences was the most and least useful at confirming or excluding underlying disease in each case. At the end of the study the results from the observers were combined to give a consensus opinion on each MR examination. Where there was a difference in opinion, this was resolved by consensus review.

Arthrosonography was performed by experienced paediatric radiologists (who were not involved in reporting the MRI examinations) on a Siemens Sonoline Elegra (Siemens, Erlangen, Germany) machine using a 7.5 MHz linear probe. A standard examination technique as previously described was used.¹⁰ Where considered necessary, hip radiographs were obtained (with gonadal shielding) in the anteroposterior pelvis and frog leg lateral projections. Ultrasound, radiographic and blood test results plus the clinical findings and final diagnosis at discharge from follow up (determined from the clinical notes) were collated independently by one of the researchers (JB). Correlative pathological evidence from joint aspiration or biopsy specimens was not available in most cases (a change in our practice to routine joint aspiration for the purposes of a study was not felt to be ethically appropriate), so the “standard of reference” method was used to derive a standard against which to compare the performance of the different imaging modalities. This method has been described in detail in the imaging literature.^{12–14} It involves incorporating together all available clinical, laboratory and imaging information at the end of a predefined period to arrive at a firm diagnosis in each case—the “standard of reference”. As not all cases can be classified with absolute certainty, the standard of reference can never be completely accurate,¹⁴ but it does provide a practical means of comparing different imaging modalities when there is no gold standard available. Statistical analyses of data were performed using SPSS for Windows version 8.0.

Results

Thirty five boys and 15 girls were included in the study (range 1–13 years, mean age 6, standard deviation (SD) 2.6); the age and sex distribution is similar to that described in previous studies of acute hip pain in children.^{1 15} Forty four per cent had a history of recent viral illness (half were respiratory in origin). All the children were non-weight bearing or only partially weight bearing at presentation. Abnormalities on examination (reduced range of movement or tenderness on hip palpation, or

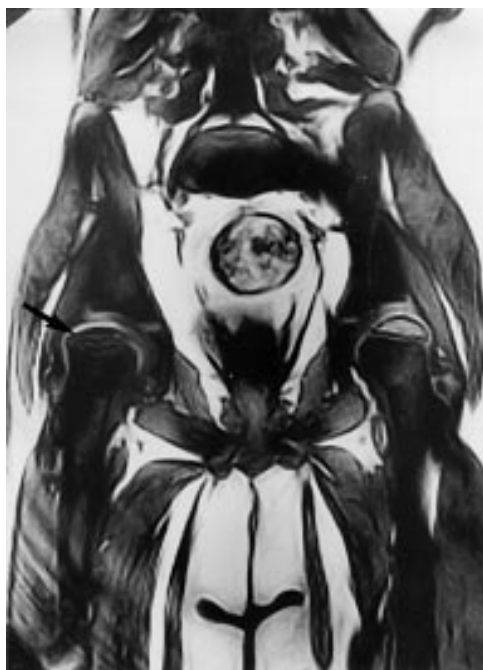

Figure 1 Gradient echo T1 weighted coronal image. Established avascular necrosis of the right femoral capital epiphysis (arrow head) with slight flattening of the left proximal femoral epiphysis.

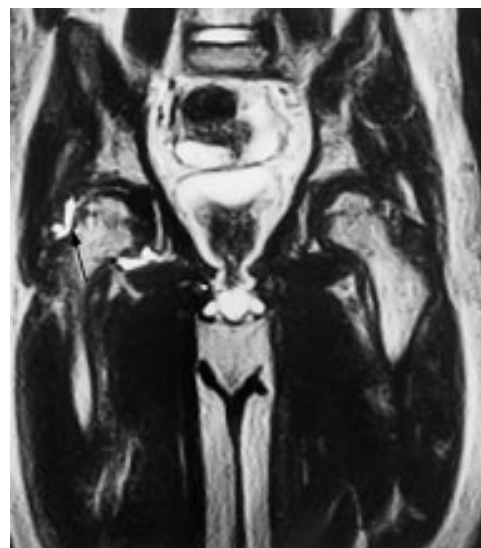


Figure 2 Fast spin echo T2 weighted coronal image. A moderately large right hip joint effusion is demonstrated (arrow head).

both) were present in 70%. Median duration of symptoms before presentation was 24 hours (range 4–1008).

Six children had no objective evidence of active disease and were therefore classed as “true negative” cases. No firm clinical diagnosis was reached in these children, two were queried as muscular sprains and the other four had been labelled as possible transient synovitis rather than as probable or definite cases. Only one of six had a history of recent illness, all were afebrile with normal haematological and imaging tests. The other 44 children had haematological (30), or imaging (34), or strong clinical evidence (29) of active hip pathology, or all three. This “true negative” rate is similar to that described in a previous study.¹

The ability of the MR sequences to provide diagnostic quality images was recorded prospectively by each radiologist (see table 1). An adequate diagnostic MR examination was obtained in 47 of 50 children (94%). The FSE T2 weighted coronal sequence was significantly less likely to produce an acceptable quality of image than the GE T1 weighted coronal ($p < 0.05$, χ^2 test with continuity correction) or IRSE axial sequences ($p < 0.011$, χ^2 test with continuity correction). There was no significant difference between the GE T1 weighted and IRSE sequences. The contribution of the MR sequences to confirming or excluding underlying disease was prospectively graded (see table 2). The IRSE was more useful than the T1 ($p < 0.0001$, χ^2 test with continuity correction) or T2 sequences ($p < 0.002$, χ^2 test with continuity correction) and the GE T1 weighted less useful than the T2 ($p < 0.007$, χ^2 test with continuity correction).

The observers disagreed on the interpretation of the MRI examination in 4 of 10 examinations. In one case the disagreement related to grading the size of effusion present. In two cases one observer interpreted the MRI examination as normal while the other interpreted it as demonstrating a small hip effusion. In the final case of disagreement one observer queried pelvic sepsis as well as joint effusion but this was not felt to be present on consensus review. The unweighted κ value for inter-rater agreement on the MRI examinations was 0.89, (95% CI 0.79, 0.99), indicating very good agreement.⁹

The results of the statistical analyses related to the MRI examinations are outlined in table 3.

In the subgroup of children with serious underlying disease—Perthe’s disease or pelvic musculoskeletal sepsis (septic arthritis, iliac osteomyelitis, iliopsoas or other pelvic muscle sepsis¹⁶)—MRI correctly identified all seven cases whereas conventional imaging alone correctly diagnosed only two of seven. Unweighted κ for the agreement between MRI and the standard of reference was 0.67 (95% CI 0.46, 0.88) indicating good agreement, between standard imaging and the standard of reference it was 0.36 (95% CI 0.09, 0.63) indicating only fair agreement. The performance of MRI and conventional imaging compared with the standard of reference is tabulated in table 4. For individual observers the level of agreement with the standard of reference was 0.59 (95% CI 0.37, 0.81) for observer A and 0.61 (95% CI 0.39, 0.83) for observer B—indicating moderate and good agreement respectively.

Eighteen children had altered signal on IRSE sequence in soft tissues or bone marrow adjacent to the symptomatic hip. The presence of pelvic musculoskeletal infection seems to be associated with a marked alteration in tissue signal on IRSE (grade 2 or 3) adjacent to the symptomatic hip in comparison to transient synovitis. This difference did not reach statistical significance, $p = 0.10$ (Fisher’s exact test,

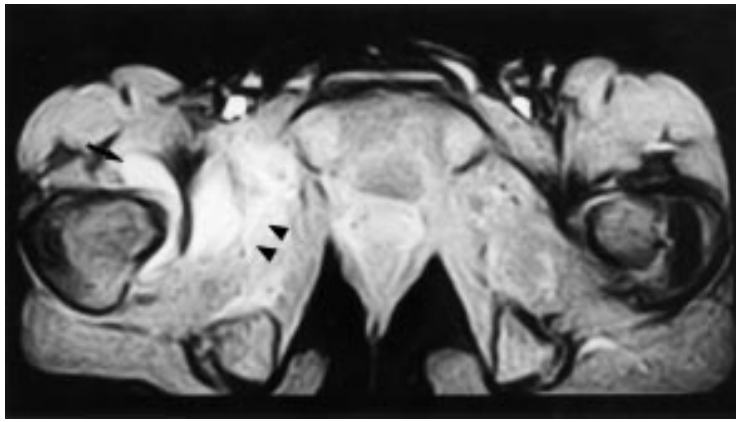


Figure 3 IRSE axial image. High signal intensity in the right obturator internus and externus muscles (arrow head). Normal marrow signal. Child was febrile with an ESR of 50 mm 1st h and a WCC of $12 \times 10^9/\text{dl}$. Diagnosis: pelvic musculoskeletal infection.

two tailed). On its own the presence of this altered signal is a poor discriminator of the nature of the underlying disease as there is clearly considerable overlap between diagnoses (see table 5). For children with transient synovitis and increased soft tissue MR signal, mean ESR value was 12.2 (SD 11.6) and for children with pelvic musculoskeletal sepsis mean ESR value was 45.5 (SD 10.8). For all 38 children with transient synovitis, mean ESR was 16.7 (SD 19.1). Only 7 of 38 had an ESR > 20 mm 1st h. No child with transient synovitis had grade 2/3 soft tissue signal changes and an ESR > 20 mm 1st h, whereas four of five children with pelvic musculoskeletal sepsis met these criteria. The fifth child had C reactive protein measured (instead of the ESR) and this was increased (126 mg/l), with abnormal bone marrow signal plus grade 2 signal increase in adjacent soft tissues and a joint effusion. The diagnosis in this case was osteomyelitis. The combination of markedly altered signal from adjacent tissues and an ESR >20 mm 1st h is significantly associated with underlying pelvic musculoskeletal infection, $p < 0.0001$ (Fisher's exact test). Taking this combination as a marker for pelvic musculoskeletal infection, its possession (in this small series) has a PPV and NPV of 1.00 (95% CI 0.96, 1) for underlying pelvic musculoskeletal infection.

Discussion

Appointment slots during the data acquisition stage of the study were specifically allocated on the MRI weekly schedule. The logistics of our MRI service allow the accommodation of emergencies and other urgent assessments of acute conditions including "irritable hip" during the working week.

The imaging protocol used in this study was a compromise chosen to combine speed of examination with the imaging sequences (T1W, T2W and fat suppression) and imaging planes (coronal and axial) reported in the literature as being the most useful.^{1 8 16-18} In general, sequence acquisition times are longer on low field MRI systems, restricting the number of sequences that can be performed during an examination. Because of relatively long acquisition times, combined with the aim

of developing a rapid and practical examination protocol, the MRI examination was restricted to three sequences and each sequence was performed in only one plane. The T1 weighted coronal sequence (fig 1) provided excellent delineation of anatomy, bone marrow and epiphyseal cartilage, while the T2 weighted sequence (fig 2) provided good delineation of joint effusion or other soft tissue disease. A fat suppression technique, IRSE (fig 3) was particularly effective in the demonstration of marrow and soft tissue diseases. MRI was well accepted by the children and diagnostic images were obtained in all patients without general anaesthesia, and only two required sedation.

Arthrosonography is widely used in the investigation of hip pain in children because of its sensitivity, particularly in detecting joint effusion.²⁰ It can produce false negative results in Perthe's disease and SCFE.^{10 20 21} The size of effusion can be used as a guide as to whether joint aspiration is necessary.²² The immediate aspiration of all joint effusions detected on ultrasound has been advocated² but is not used routinely in many centres. Joint aspiration is an invasive procedure and although the risk of complications is low,² they include inadvertent puncture of a major vessel, introduction of infection into the joint if there is a break in aseptic technique and reaction to the local anaesthetic or sedative used.²³ A general anaesthetic may even be required in some cases to obtain a diagnostic examination.²⁴ Arthrosonography plus aspiration may fail to diagnose some cases of pelvic musculoskeletal infection; particularly osteomyelitis where septic arthritis is not present,^{16 25 26} thereby giving false reassurance. For these reasons routine aspiration of all effusions is not performed in this centre.

The value of early radiographs in acute non-traumatic hip pain has been questioned by some authors,^{2 27 28} though supported by others.^{4 29} There is a radiation burden with plain radiographs of the hip even when gonadal shielding is used. In children where sepsis is suspected clinically or in older children (>8 years) where Perthe's and SCFE are more likely, radiographs are generally advised.²⁷ The rate of radiography in our series (32 of 50) was higher than expected as only 10 of the children were aged 8 years or over (nine of whom who had hip radiographs). By using MRI as the primary imaging modality in acute non-traumatic hip pain, hip radiographs in these children could be avoided. The results from this study indicate good sensitivity and specificity for MRI in the investigation of acute hip pain in children and suggest it is a more accurate method than arthrosonography and radiography (where routine aspiration of effusions is not performed). The results also indicate the poor sensitivity of hip arthrosonography and radiography in the diagnosis of pelvic musculoskeletal infection.

Both MRI and standard imaging strategies have a low NPV in children who present with a history of hip pain. A number of children were identified who had no abnormalities on

imaging yet had clinical and haematological evidence (raised ESR or white cell count, or both) of underlying hip disease. The low NPV reinforces the fact that imaging tests are not a substitute for a careful history and clinical examination. Inflammatory markers can be a useful adjunct in the management of acute hip pain, with an ESR of >20 mm 1st h suggested as a marker indicating the need for further investigation.³⁰ The data from this study indicate that the combination of markedly altered signal in tissues adjacent to a symptomatic hip in conjunction with an ESR of >20 mm 1st h (or significantly increased C reactive protein) could be used as a means of discriminating between those children who require aggressive management and those who can be treated expectantly. It is hoped that our data will stimulate further evaluation of this approach in other centres.

On follow up of the 37 children who were diagnosed with transient synovitis none went on to developed any complications that were not originally noted on MRI during the study.

In conclusion, hip MRI on an open low field strength system is a practical, well accepted and accurate non-invasive imaging technique in children presenting with acute non-traumatic hip pain. Combined with inflammatory markers MRI may discriminate between children who can be treated expectantly and those who require aggressive management. Where it is readily available, MRI is the primary imaging modality of choice in this group of children.

We would like to express our thanks to all our colleagues in the Departments of Accident and Emergency and Radiology, RHSC for their help in conducting this study. Particular thanks are due to Dr K Houlihan and Ms Wendy English, also to Dr D Signorini for his statistical advice.

Contributors

Dr P M White was the principal investigator who, discussed core ideas, produced the protocol design and obtained ethical approval. He analysed the data and concluded the detailed statistics. Dr G M Hendry was the second principal investigator who originated the idea and was actively involved in the protocol design, image analysis, editing and overseeing the study. Mr M Hurst was the lead radiographer who contributed to sequence optimisation and performed the imaging. He managed the subjects appointments and liaised with the referring clinicians. Miss J Boyd (student radiographer) worked with the principal investigator and was involved with the literature search process, patient consent and patient scanning. Her other roles included coordination of image analysis and assistance with data manipulation. Dr T Beattie was the referring A&E consultant who provided clinical information and initially discussed the study with the patient and parents. He also organised the follow up of patients.

Funding: none.

Conflicts of interest: none.

- 1 Ranner G, Ebner F, Fotter R, *et al.* Magnetic resonance imaging in children with acute hip pain. *Pediatr Radiol* 1990;20:67-71.
- 2 Fink AM, Berman L, Edwards D, *et al.* The irritable hip: immediate ultrasound guided aspiration and prevention of hospital admission. *Arch Dis Child* 1995;72:110-14.
- 3 Dahnert W. Bone and soft tissue disorders. In: Dahnert W, ed. *Radiology review manual*. 3rd ed. Baltimore: Williams and Wilkins, 1996:103.
- 4 Hollingworth P. Differential diagnosis and management of hip pain in childhood. *Br J Rheumatol* 1995;34:78-82.
- 5 Murray JG, Ridley NTF, Mitchell N, *et al.* Juvenile chronic arthritis of the hip: value of contrast-enhanced MR imaging. *Clin Radiol* 1996;51:99-102.
- 6 Takatori Y, Kokubo T, Ninomiya S, *et al.* Avascular necrosis of the femoral head. Natural history and magnetic resonance imaging. *J Bone Joint Surg* 1993;75B:217-21.
- 7 Lee MJ, Corrigan J, Stack JP, *et al.* A comparison of modern imaging modalities in osteonecrosis of the femoral head. *Clin Radiol* 1990;42:427-32.
- 8 Minio Paluello GB, De Pellegrin M, Tacchini S, *et al.* Persistent coxalgia in the child. The value of MR. *Radiol Med* 1995;89:402-8.
- 9 Altman DG. Some common problems in medical research. In: Altman DG, ed. *Practical statistics for medical research*. London: Chapman and Hall, 1991:403-9.
- 10 Adam R, Hendry GMA, Moss J, *et al.* Arthrosonography of the irritable hip in childhood; a review of one years experience. *Br J Radiol* 1986;59:205-8.
- 11 Marchal GJ, van Holsbeek, Raes M, *et al.* Transient synovitis of the hip in children: role of US. *Radiology* 1987;162:825-8.
- 12 Kosuda S, Kaji J, Yokoyama H. Does bone SPECT actually have lower sensitivity for detecting vertebral metastasis than MRI? *J Nucl Med* 1996;37:975-8.
- 13 White PM, Howard GCW, Best JJK, *et al.* The role of computed tomographic examination of the pelvis in the management of testicular germ cell tumours. *Clin Radiol* 1997;52:124-9.
- 14 Haubold Reuter RG, Duewell S, Schilcher BR, *et al.* The value of bone scintigraphy, bone marrow scintigraphy and fast spin-echo magnetic resonance imaging in the staging of patients with malignant solid tumours: a prospective study. *Eur J Nucl Med* 1993;20:1063-9.
- 15 Egund N, Wingstrand H, Forsberg L, *et al.* Computed tomography and ultrasonography for diagnosis of hip joint effusion in children. *Acta Orthop Scand* 1986;57:211-15.
- 16 Kearney SE, Carty H. Pelvic musculoskeletal infection in infants: diagnostic difficulties and radiological features. *Clin Radiol* 1997;52:782-6.
- 17 Tamburrini O, Sessa M, Della S, *et al.* MRI in transient osteoporosis of the hip. *Radiol Med* 1995;90:187-93.
- 18 Brower AC, Kransdorf MJ. Imaging of hip disorders. *Radiol Clin North Am* 1990;28:955-74.
- 19 Kleinman PK, Sperak MR. Advanced pediatric joint imaging. *Radiol Clin North Am* 1990;28:1073-1109.1]
- 20 Ehrendorfer S, LeQuesne G, Penta M, *et al.* Bilateral synovitis in symptomatic unilateral transient synovitis of the hip: an ultrasonographic study in 56 children. *Acta Orthop Scand* 1996;67:149-52.
- 21 Terjesen T. Ultrasound in the primary evaluation of patients with Perthe's disease. *J Pediatr Orthop* 1993;13:437-43.
- 22 Nimityongskul P, McBryde AM, Anderson LD, *et al.* Ultrasonography in the management of painful hips in children. *Am J Orthop* 1996;25:411-14.
- 23 Alexander JE, Seibert JJ, Glassie CM, *et al.* High resolution hip ultrasound in the limping child. *J Clin Ultrasound* 1989; 17:19-24.
- 24 Wilson DJ, Green DJ, MacLarnon JC. Arthrosonography of the painful hip. *Clin Radiol* 1984;35:17-19.
- 25 Zawin JK, Hoffer FA, Rand FF, *et al.* Joint effusion in children with an irritable hip: US diagnosis and aspiration. *Radiology* 1993;187:459-63.
- 26 Abbott GT, Carty H. Pyogenic sacroiliitis, the missed diagnosis? *Br J Radiol* 1993;66:120-2.
- 27 Steiner GM. Ultrasound of the skeletal system in children. In: Grainger RG, Allison DJ, eds. *Diagnostic radiology*. 2nd ed. Edinburgh: Churchill Livingstone, 1992:83-5.
- 28 Bickerstaff DR, Neal LM, Booth AJ, *et al.* Ultrasound examination of the irritable hip. *J Bone Joint Surg* 1990;72B:549-53.
- 29 Causey AL, Smith ER, Donaldson JJ, *et al.* Missed slipped capital femoral epiphysis: illustrative cases and review. *J Emerg Med* 1995;13:175-89.
- 30 Del Beccaro MA, Chapoux AN, Bochers T, *et al.* Septic arthritis versus transient synovitis of the hip: the value of screening laboratory tests. *Ann Emerg Med* 1992;21:1418-22.