

Traumatic asymmetrical bilateral hip dislocation in an adult

F Lam, J Walczak, A Franklin

Abstract

Bilateral hip dislocation occurring as a result of trauma is a rare condition. Simultaneous anterior and posterior traumatic dislocation of both hips is even more unusual. A case is reported of asymmetrical bilateral traumatic hip dislocation without an associated fracture of the pelvis or femur occurring in a young adult with no previous history of hip abnormality or ligamentous laxity. An unusual mechanism for this injury is also described.

(Emerg Med J 2001;18:506-507)

Keywords: hip dislocation; avascular necrosis; orthopaedic manipulation

Case report

An 18 year old man was involved in a road traffic accident, in which he was the driver of a motor vehicle in a head on collision. After the first impact, his car rotated 90 degrees and the off side was hit by a second vehicle travelling in the opposite direction. On admission, his left leg was externally rotated, abducted and slight flexed, while the right was held in fixed flexion, internal rotation and adduction. A pelvic radiograph (fig 1) performed in the resuscitation room revealed bilateral hip dislocation with the femoral head displaced antero-inferiorly on the left side and posteriorly on the right side. There was no associated fracture of the acetabulum or femur.

Both hips were reduced within one hour of presentation by closed manipulation under general anaesthesia. A radiograph after reduction confirmed concentric reduction and excluded any intra-articular fragments (fig 2). He was kept on bed rest for three weeks with skeletal traction followed by a further six weeks of non-weightbearing.

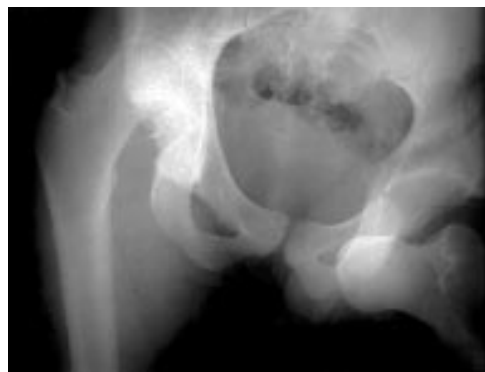

Figure 1 Radiograph of the pelvis and both hip joints showing an anterior dislocation of the left hip and a posterior dislocation of the right hip.

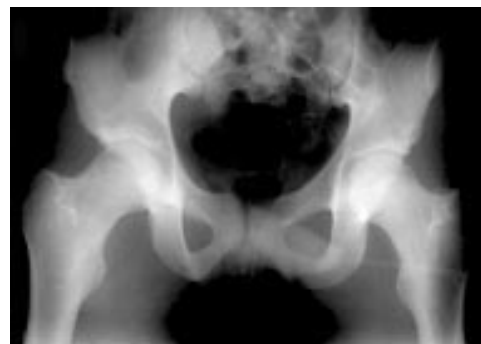


Figure 2 Radiograph of the pelvis after manipulation showing concentric reduction and excluded any intra-articular fragments.

Discussion

Traumatic dislocation of the normal hip joint is rare because of its deep acetabular cavity and strong surrounding ligamentous structures. Ninety per cent of dislocations are posterior, occurring as a result of high energy transfer mostly in car and motorcycle accidents (46% and 18% respectively¹). This results when a sufficient force is applied in the long axis of the femoral shaft while the hip is flexed and adducted. In contrast, anterior dislocations are caused by rotation and may be classified as superior and inferior. Superior ones occur attributable to abduction and external rotation in extension and inferior ones occur when the hip is adducted and external rotated in flexion.

Simultaneous anterior and posterior traumatic dislocation of both hips is even more unusual. We are aware of only five previously reported cases, which have all been associated with a fracture of either the pelvic ring²⁻⁵ or the femur.⁶

The mechanism of injury in our case probably involved adduction and internal rotation of the right hip and abduction and external rotation of the left hip, with both hips flexed. This "windswept" mechanism is consistent with an off centre passenger cell intrusion that directed longitudinal force along both femora, yet had a vector in the coronal plane. Upadhyay *et al*⁷ suggested that patients with reduced femoral anteversion, as measured by ultrasonography, represent an extreme of the population who were more likely to suffer from a simple posterior hip dislocation rather than a fracture dislocation, as the reduced anteversion acts like medial rotation to make the hip more susceptible to the dislocating force.

Several studies^{8,9} have shown that the risk of osteonecrosis occurring after a hip dislocation is related to the length of time the hip remains dislocated. The risk rises after a delay of six

Department of
Orthopaedic Surgery,
Bromley Hospital,
London, UK

Correspondence to:
Mr Lam, 4 Middlefield,
London NW8 6NE, UK
(mrflam@hotmail.com)

Accepted for publication
25 January 2001

hours, or after repeated attempts at closed reduction. Overall, the risk of developing osteonecrosis of the femoral head after an anterior or posterior hip dislocation ranges from between 8% and 15%, to as high as 40% after operative treatment.⁹ Our case illustrates that traumatic hip dislocation is an orthopaedic emergency and should be reduced under general anaesthesia with full muscle relaxation as soon as possible.

1 Upadhyay S, Moulton A. The long term results of traumatic posterior dislocation of the hip. *J Bone Joint Surg* 1981;**63B**:548–51.

- 2 Bansal VP, Mehta S. Bilateral hip dislocation: one anteriorly, one posteriorly. *J Orthop Trauma* 1991;**5**:86–8.
- 3 Nadkarni JB. Simultaneous anterior and posterior dislocation of hip. *J Postgrad Med* 1991;**37**:117–8, 118A.
- 4 Civil ID, Tapsell PW. Simultaneous anterior and posterior bilateral traumatic dislocation of the hips: a case report. *Aust N Z J Surg* 1981;**51**:542–4.
- 5 Sinha SN. Simultaneous anterior and posterior dislocation of the hip joints. *J Trauma* 1985;**25**:269–70.
- 6 Hill RJ, Chmell S. Contralateral anterior/posterior traumatic hip dislocations. *Orthopedics* 1990;**13**:87–8.
- 7 Upadhyay S, Moulton A, Burwell R. Biological factors predisposing to traumatic posterior dislocation of the hip. *J Bone Joint Surg* 1985;**67B**:232–6.
- 8 Epstein HC. Posterior fracture-dislocations of the hip: long term follow up. *J Bone Joint Surg* 1974;**56A**:1103–27.
- 9 Stewart M, Milford L. Fracture dislocations of the hip. *J Bone Joint Surg* 1954;**36A**:315.