

CASE REPORT

Failure to recognise ventricular standstill

P A Leonard, J E Burns

Emerg Med J 2002;**19**:86-87

Many accident and emergency (A&E) departments use the rhythm display of defibrillators to perform cardiac monitoring in critically ill patients, as do ambulance personnel and an increasing number of general practitioners. It has previously been recognised that ventricular fibrillation may exist with very low or even absent amplitude, with the patient appearing to be in asystole on the monitor.¹ To help overcome this problem modern defibrillators have an automatic gain feature that will increase the amplitude of low amplitude signals. We report a case where the failure to recognise that this increase in gain had occurred resulted in a delay in the recognition of periods of ventricular standstill in a child.

CASE REPORT

A 5 year old girl was referred to the A&E department by her general practitioner with a three day history of abdominal pain, intermittent fever, and profuse vomiting. That morning she had been observed to have a brief generalised seizure, which terminated spontaneously within a few seconds.

On arrival in the department she was alert and though normotensive was clinically dehydrated with a capillary refill time of five seconds and was noted to have a bradycardia of 60 bpm.

Her initial treatment with high flow oxygen and a 20 ml/kg bolus of intravenous normal saline improved her peripheral perfusion but had no effect on her bradycardia. She was observed to have a further brief episode where she lost consciousness and it was noted that her cardiac rhythm changed (fig 1).

This was interpreted as demonstrating a narrow complex tachycardia and treatment was continued with volume resuscitation and a search for electrolyte imbalance. It was only when she had a further episode of loss of consciousness and a second rhythm strip was recorded (fig 2) that it was realised that the "tachycardia" was in fact atrial activity at a rate of 150 per min that had been amplified by the automatic gain to look like small amplitude QRS complexes. The "seizures" were in fact Stokes-Adams attacks due to periods of ventricular standstill. A 12 lead ECG confirmed the presence of complete heart block with a ventricular escape rhythm (fig 3).

The child was given intravenous isoprenaline and a temporary femoral transvenous pacing wire was inserted. Echo-

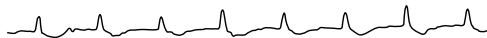

Figure 1 Rhythm strip recorded during seizures.

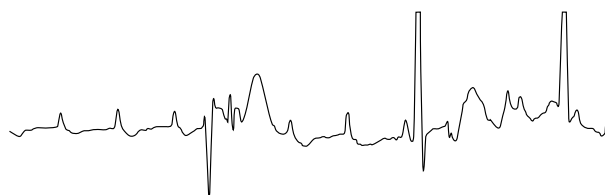


Figure 2 Ventricular standstill becomes apparent.

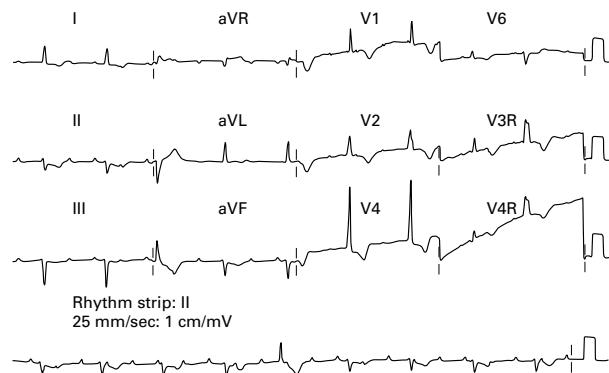


Figure 3 A 12 lead ECG showing complete heart block.

cardiography demonstrated poor left ventricular function with a speckled appearance to the ventricular septum and a diagnosis of myocarditis was made. The child went on to make an uncomplicated recovery, regaining her normal conduction and ventricular function.

DISCUSSION

Clearly the lack of ventricular activity would have been noted earlier if simultaneous assessment of the patient as recommended by Pediatric Advanced Life Support² courses had noted the absence of a pulse, however each episode lasted only a few seconds and the accompanying "seizure" made palpating a pulse almost impossible.

The confusion in this case was contributed to by the relatively fast atrial rate, which is entirely appropriate for a child of this age who is unwell, and is less likely to be present in an adult population. Automatic gain has been noted to cause failure of pacing in cardioverter defibrillators due to confusion of rapid atrial activity with ventricular response³ but we are not aware of other reports of human error attributable to this phenomenon.

Clinicians using any form of cardiac monitoring should make themselves familiar with all features of the equipment including the presence of automatic gain and be aware of this when interpreting displayed rhythms. Many defibrillators include the word Autogain on the printed rhythm strip to indicate this feature is being used, although they do not display this on screen. A 12 lead ECG should be performed if doubt as to the rhythm exists or if the patient is stable before starting treatment.

ACKNOWLEDGEMENTS

Conflict of interest: none.

PAL and JEB were both involved in the care of the patient and conceived the idea of the case report. PAL performed the literature search and prepared the article. JEB edited the article. PAL is guarantor for the report.

.....

Authors' affiliations

P A Leonard, Accident and Emergency Department, Royal Hospital for Sick Children, Edinburgh, UK

J E Burns, Department of Cardiology, Royal Hospital for Sick Children, Edinburgh

Correspondence to: Dr P A Leonard, Accident and Emergency Department, Royal Hospital for Sick Children, Sciennes Place, Edinburgh EH9 1LF, UK

Accepted for publication 11 May 2001

REFERENCES

- 1 **Ewy GA**, Dahl CF, Zimmerman M, *et al.* Ventricular fibrillation masquerading as ventricular standstill. *Crit Care Med* 1981;**9**:841–4.
- 2 **Chameides L.** *Textbook of pediatric advanced life support.* Dallas: American Heart Association and American Academy of Pediatrics, 1997.
- 3 **Curwin JH**, Roelke M, Ruskin JN. Inhibition of bradycardia pacing caused by far-field atrial sensing in a third-generation cardioverter defibrillator with an automatic gain feature. *Pacing Clin Electrophysiol* 1996;**19**:124–6.