

## SIMULATED INTERACTIVE MANAGEMENT SERIES

# Reduction of the posterior pelvic ring by non-invasive stabilisation: a report of two cases

A Qureshi, A McGee, J P Cooper, K M Porter

*Emerg Med J* 2005;22:885–886. doi: 10.1136/emj.2004.015891

We demonstrate radiological evidence that an external pelvic splint is effective at reducing open book pelvic fractures. Its use in the pre-hospital and emergency department settings should be encouraged in the initial management and resuscitation of patients with pelvic fractures.

Detection and treatment of life threatening haemorrhage is an integral part of the trauma primary survey. Pelvic ring disruption, particularly of the anteroposterior (AP) compression ("open book") type<sup>2</sup> can be associated with exsanguinating haemorrhage. Suggested strategies for control of such haemorrhage centre around stabilisation of the fracture and its primary clot, apposition of fracture surfaces, and reduction of pelvic volume in order to achieve a tamponade effect. Closed reduction of the pelvis and application of a pelvic external fixator can, in theory, achieve all three of these aims. Emergency application of an anterior external fixator is not a trivial procedure, and may compromise definitive pelvic surgery. The time required for location of equipment and fixator application may take up precious minutes in the resuscitation room.

A simple alternative to external fixation in the pre-hospital and emergency department environments is the use of non-invasive circumferential compression.<sup>5</sup> We present two cases where a pelvic ring disruption was successfully reduced and stabilised with a temporary, simple, external pelvic splint.

### CASE REPORTS

#### Patient 1

A 36 year old motorcyclist was admitted with multiple injuries following a head on collision with a car. On arrival he was tachycardic (104 beats/min), and hypotensive (71/34 mmHg). He remained tachycardic despite intensive intravenous fluid replacement with 8 units of blood and 2 units of fresh frozen plasma. A plain anteroposterior pelvis radiograph (fig 1A) revealed an open book fracture of the pelvis with a pubic symphysis disruption, fractures of the pubic rami, and opening of the right sacroiliac joint. His other injuries were fractures of the right distal radius, left radius and ulna, and soft tissue injuries to the right knee.

A pelvic splint (Stuart Pelvic Harness, Medistox Ltd., Blackburn, UK) was applied and once the patient was haemodynamically stable, a computed tomography (CT) scan performed. This demonstrated anatomical reduction of the right sacroiliac joint (fig 1B), and considerable haematoma around the base of the bladder and the pubic symphysis. Internal fixation of the anterior pelvic ring was not felt to be necessary and he was managed with an external fixator.

#### Patient 2

A 37 year old male pillion passenger was thrown from a motorcycle and sustained fractures of the right humerus,

radius, and ulna, ribs, and pelvis with associated urethral rupture. Plain anteroposterior radiograph of the pelvis, taken as part of the trauma series (fig 2A). His blood pressure remained labile and fluid dependent. There were no other evident sources of blood loss. A pelvic splint was applied in the department, which effectively closed the diastasis. Fluid requirements following application of the splint were reduced.

A CT scan of the abdomen and pelvis, taken with the splint in place, showed the pelvic injury was accurately reduced (fig 2B). Apart from an avulsion fracture of the L5 transverse process, there was little to suggest that there had been a major pelvic ring disruption. There was no intra-abdominal free fluid. A cystogram showed extravasation of contrast around the base of the bladder consistent with an extra-peritoneal bladder rupture that was managed non-operatively. The pubic symphysis was later internally fixed with a plate and screws.

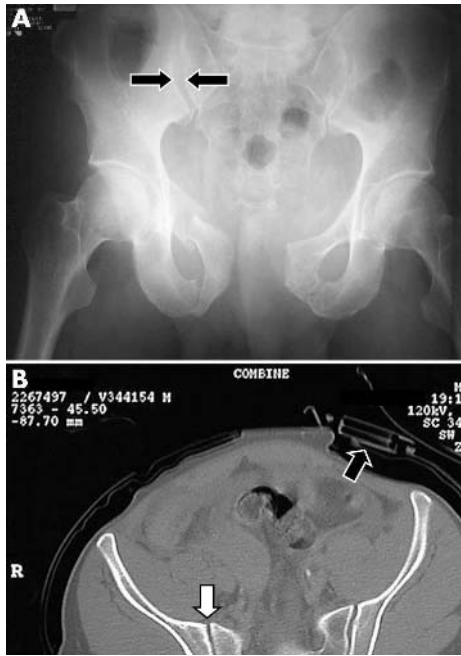
### DISCUSSION

A pelvic splint (fig 3A, B) or other binder is quick and easy to apply, needs minimal training in its use, and can be used by paramedical staff in the pre-hospital environment and junior medical staff and nurses in the emergency department. Although commercially available splints are convenient, an effective binder can be improvised from a sheet or other easily available material.<sup>3</sup> As demonstrated by the imaging in our cases, such devices can effectively reduce open book pelvic fractures.

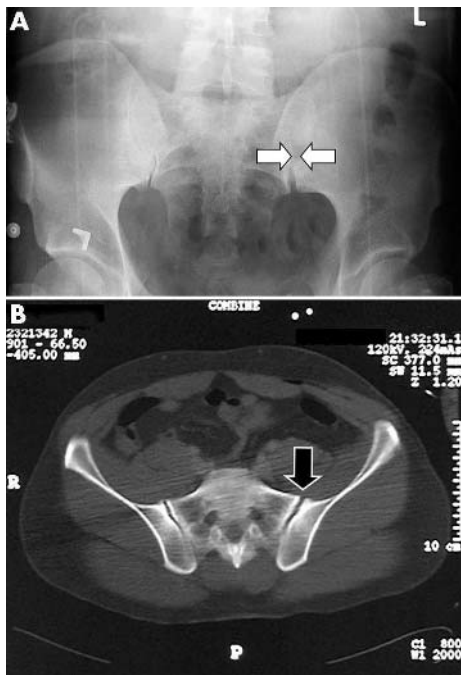
The pelvic splint is unobtrusive and does not hinder resuscitation. If necessary, an external fixator can later be applied by an experienced surgeon in a controlled sterile operating theatre environment. It has been recommended that the splint be placed at the level of the pubic symphysis and greater trochanters to generate the maximum benefit in reduction.<sup>1</sup> A relatively narrow splint as used here can keep the iliac crests clear for application of external fixation and permits access to the abdomen for clinical assessment, focused abdominal sonography for trauma (FAST) scanning, or, if necessary, laparotomy.

Our cases raise one concern with the use of this technique, namely, the potential situation of an unstable pelvic ring injury being masked by the reduction effected by the splint. The prime function of the trauma series AP pelvis radiograph is to screen for a potentially haemorrhagic pelvic ring injury, thus if the splint reduces the displacement, then a key step in assessment may be rendered valueless. In our first case, the presence of pubic rami fractures at least provided some indication of the degree of injury, while in the second case there was no fracture in the pelvic ring to indicate injury. If the latter case had the splint applied prior to the initial radiograph then the need to diagnose the degree of pelvic injury would have presented something of a dilemma –

**Abbreviations:** AP, anteroposterior; CT, computed tomography

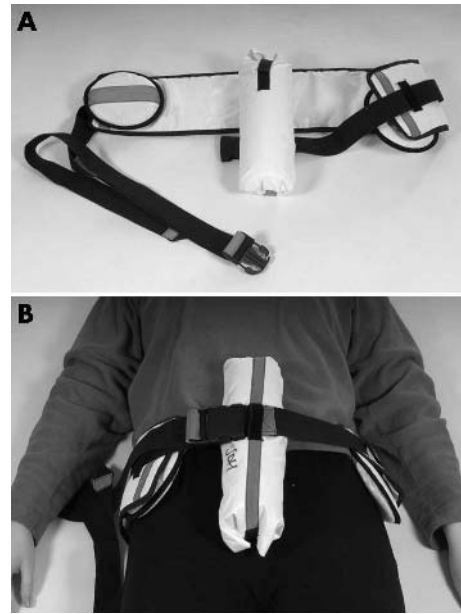


**Figure 1** Case 1. (A) Resuscitation room AP pelvic film illustrating the open book injury with opening of the right sacroiliac joint before the pelvic splint was applied. (B) Axial CT scan demonstrating the reduction of the right sacroiliac joint (white arrow). The buckle of the pelvic splint is clearly visible (black arrow).



**Figure 2** Case 2. (A) Resuscitation room AP Pelvic film taken before pelvic splint applied showing the opening of the left sacroiliac joint; (B) CT scan of pelvis with pelvic splint applied, showing reduction of the left sacroiliac joint.

remove the splint or remain ignorant of the severity of the injury. The beneficial effect of external pelvic stabilisation is most likely to be related to stabilisation of bone ends and the primary clot formed at sites of haemorrhage as the degree of



**Figure 3** (A) The Stuart pelvic harness; (B) a Stuart splint, illustrating its mode of application.

tamponade provided by reduction of pelvic volume is limited.<sup>4</sup> Release of the splint for the purpose of diagnosis may disturb the primary clot and lead to further haemorrhage, which may be compounded if coagulopathy has developed. Where a splint has been applied in the pre-hospital or resuscitation room prior to initial imaging, then other investigations may provide evidence of a potentially unstable pelvic ring injury. Abdominal ultrasound scanning or CT may reveal evidence of haematoma in the pelvis. Careful scrutiny of a good quality AP pelvis film or CT of the pelvis may reveal subtle ligamentous avulsion fractures of the ischial spine, sacrum, or L5 transverse process. Where such indicators of instability are negative but clinical suspicion is high, we would recommend that a repeat AP pelvis film should be taken with the splint slightly relaxed.

**Authors' affiliations**

A Qureshi, A McGee, J P Cooper, K M Porter, Selly Oak Hospital, Raddlebarn Road, Birmingham, UK

Competing interests: none declared

Correspondence to: Dr K M Porter, Trauma Department, University Hospital Birmingham NHS Trust, Selly Oak Hospital, Raddlebarn Road, Birmingham B29 6JD UK; keith.porter@uhb.nhs.uk

Received 18 March 2004

Revised 20 August 2004

Accepted 29 September 2004

**REFERENCES**

- 1 **Bottlang M**, Simpson T, Sigg J, et al. Noninvasive reduction of open-book pelvic fractures by circumferential compression. *J Orthop Trauma* 2002;**16**:367-73.
- 2 **Dalal SA**, Burgess AR, Siegel JH, et al. Pelvic fracture in multiple trauma: Classification by mechanism is key to pattern of organ injury, resuscitative requirements, and outcome. *J Trauma* 1989;**29**:981-1000.
- 3 **Duxbury MS**, Rossiter ND, Lambert AW. Cable ties for pelvic stabilisation. *Ann R Coll Surg Engl* 2003;**85**:130.
- 4 **Grimm MR**, Vrahas MS, Thomas KA. Pressure-volume characteristics of the intact and disrupted pelvic retroperitoneum. *J Trauma* 1998;**44**:454-9.
- 5 **Rouff ML Jr**, Falicov A, Woodhouse E, et al. Circumferential pelvic antishock sheeting: A temporary resuscitation aid. *J Orthop Trauma* 2002;**16**:45-8.