

ORIGINAL ARTICLE

The use of a template to improve the management of distal radial fractures

R Kotnis, M D Waites, O Fayomi, R Dega

Emerg Med J 2005;22:544–547. doi: 10.1136/emj.2004.016360

See end of article for authors' affiliations

Correspondence to: Mr R Kotnis, Department of Trauma, John Radcliffe Hospital, Oxford, UK; rkotnis@hotmail.com

Accepted for publication 8 February 2005

Objectives: The aim of this study was to reduce the number of inappropriately managed distal radial fractures with the use of a template.

Methods: A template has been developed to aid junior doctors and emergency nurse practitioners (ENPs) to decide which distal radial fractures require manipulation. Emergency Department (ED) junior doctors and ENPs were asked to review the radiographs of 12 distal radial fractures with and without the template and comment on whether the fracture required manipulation.

Results: There was an improvement in appropriate management with the template of 16.6% for the junior doctors and 22.3% for the ENPs. This was statistically significant for both groups when the results were analysed with a paired *t* test ($p < 0.01$).

Conclusions: We conclude that the availability of this template in the ED may be helpful to junior doctors and ENPs, and represents a low cost and efficient way of reducing the number of patients who attend a fracture clinic with a distal radial fracture in an unsatisfactory position. This may also reduce the numbers requiring admission and a manipulation under anaesthetic, which spares the patients the risks of general anaesthesia and may possibly be cost saving.

Adult distal radial fractures account for more than 8% of all bony injuries seen in the Emergency Department (ED).¹ These fractures are initially managed by junior doctors and, increasingly, emergency nurse practitioners (ENPs); both groups may have limited experience in fracture management. Most of the time, management in terms of whether the position is acceptable or requires reduction is relatively straightforward. However, there are occasions when fractures that require manipulation are not recognised and therefore not reduced. This necessitates the admission of these patients from fracture clinic usually for a manipulation under anaesthetic (MUA) because of the delay in fracture reduction. The implications for the patient are exposure to the risks associated with general anaesthesia and the inconvenience of a hospital admission. There are also cost implications.

Distal radial fractures can displace in a variety of directions and different fractures will demonstrate one or all of the displacements. The main patterns with reference to the distal fragment are dorsal tilt, dorsal displacement, radial displacement, and radial shortening. The literature and medical staff often refer to a dorsally angulated fracture. As McRae points out,² the accurate method of describing angulation is in terms of the apex of the fracture and therefore the commonly described dorsally angulated fracture is in fact apex anterior angulation. A less confusing and accurate term is to describe this displacement as dorsal tilt.

Much has been written about the management of displaced distal radial fractures and the criteria for manipulation remains controversial. It is widely accepted that the amount of displacement at the time of injury is the single most important determinant of final outcome.³ As clinicians we cannot influence the original deforming force but numerous authors maintain that the quality of reduction is the next most important factor in achieving good anatomical and functional results.^{3–7} Van der Linden and Ericsson⁷ reported that the method of immobilisation was of secondary importance compared with the quality of reduction. Stewart

*et al*⁸ and Lidström⁸ advocate that all fractures with more than 10° dorsal angulation should be reduced for optimal results.

A template has been developed for the benefit of junior doctors and ENPs working in the ED aimed at helping them identify those fractures that require reduction.

METHODS

A 12 month review of all adult distal radial fractures that underwent a MUA was performed at a District General Hospital. A total of 71 distal radial MUAs had been performed. Ten sets of notes could not be traced but the fracture management path could be followed for the other 61. The findings are illustrated in Table 1.

Table 1 illustrates that 33 fractures were recognised as needing surgical intervention and were referred direct to the orthopaedic team. However, eight displaced fractures had no attempted reduction in the ED and required admission from fracture clinic for a manipulation. A further 15 patients who had reductions in the ED were admitted at their first fracture clinic because the position was unacceptable. A review of the radiographs showed that 7 of the 15 fractures (47%) were not reduced to a satisfactory position on the ED post-reduction film. Five distal radial fractures were reduced in the ED to a satisfactory position but re-displaced at a later date.

Having established a need for a template, a study was undertaken to assess the practicality and impact that such a device may have on management of distal radial fractures.

A template was designed with four key measurements (fig 1). The first is concerned with dorsal tilt (angulation) with the acceptable limit set at 10° (fig 2). The second is radial shortening of which 3 mm is the acceptable limit (fig 3). Up to 2 mm of radial shift (fig 4) and dorsal displacement (fig 5) is acceptable.

A series of twelve radiographs with distal radial fractures was assembled. Three were of undisplaced fractures and nine

Abbreviations: ED, Emergency Department; ENP, emergency nurse practitioner; MAU, manipulation under anaesthetic

1. Dorsal angle
Lay the template precisely over the distal fragment.
Does the shaft fall on the manipulate or acceptable side of the line?

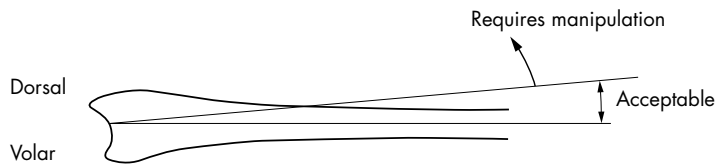
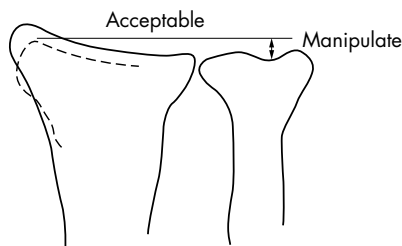
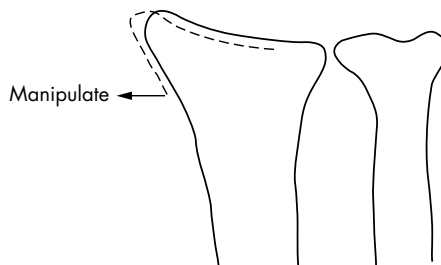


Figure 1 Wrist template showing all four key measurements

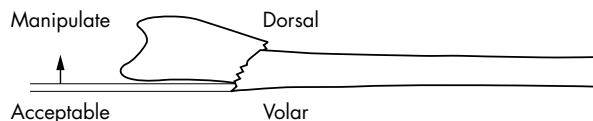
2. Radial shortening
Lay the ulna precisely on your film.



3. Radial shaft
Lay the radial shaft as accurately as possible on the radial shaft of your film.



4. Dorsal displacement
Place radial shaft as accurately as possible on the film.



were taken from the groups identified by the initial review whose management could be improved. Twelve ED junior doctors and six ENPs were asked to review the radiographs and decide, individually, whether the positions of the fractures were acceptable or required manipulation on appearance alone.

They were then shown the template (fig 1) and given a five minute tutorial on how to use it. Immediately afterwards, they were shown the same series of radiographs in a different order and asked to determine which fractures required manipulation and which were acceptable using the template.

There were also three feedback questions aimed at establishing how helpful subjects felt the template had been to them. Each answer was rated from one to four: one being not at all useful and four being very useful.

The results were collated and analysed using the paired *t* test with a *p* value of <0.05 being significant.

RESULTS

The results are tabulated in table 2.

| Fracture management | Number of cases (total 61) |
|--|----------------------------|
| Referred from ED to orthopaedics on call | 33 |
| No reduction in ED | 8 |
| Reduction in ED but position unacceptable at first fracture clinic | 15 |
| Reduction in ED, satisfactory position at first fracture clinic, slipped at later date | 5 |

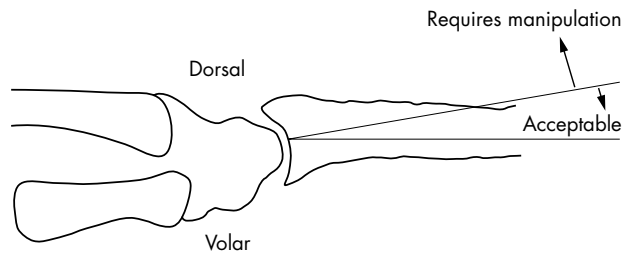
All but two junior doctors improved their scores when using the template (table 2). The average per cent correct increased by 16.6% on first use of the template. All the ENPs increased their score with the template by an average of 22.3% (table 3). The results for both groups are statistically significant (*p*<0.01) when a paired *t* test is used for analysis.

In answering the question “Did you find the template useful in making your decision?”, all but one found it useful as illustrated in table 4.

Similarly, all but one felt that such a template would prove useful to have in the ED and was user friendly.

DISCUSSION

There were eight people in our audit who underwent a general anaesthesia manipulation because the degree of



- Dorsal angulation
Lay the template over the distal fragment.
Does the shaft lie to the manipulate or acceptable side of the line on the template?

Figure 2 Enlarged view of dorsal angulation (dorsal tilt)

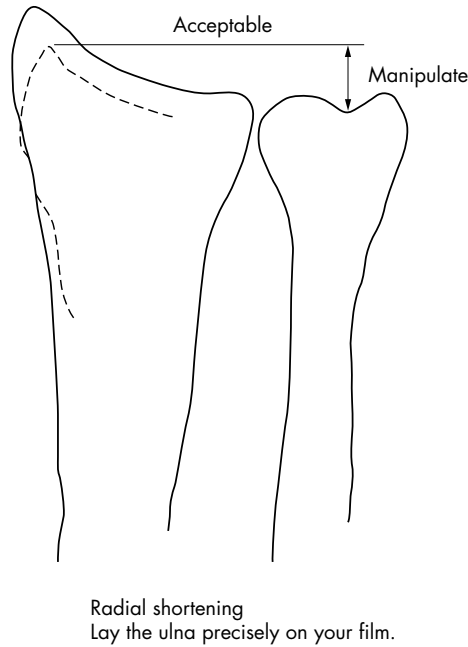


Figure 3 Enlarged view of radial shortening

displacement had not been recognised. A further seven patients had not had an adequate reduction necessitating an MUA. Together these two groups account for a quarter of all MUAs performed on distal radial fractures over a 12 month period. The introduction of a template, at minimal cost, may reduce the number of delayed general anaesthetic manipulations. The advantages to the individual are clear when one considers that this predominantly elderly population is most at risk from a general anaesthetic.

Certainly, the optimum time for reduction of a displaced radial fracture is at outset when pain relief for a manipulation can be performed with a fracture haematoma block as is common practice in most EDs. Delay in fracture reduction usually requires an MUA because of a less effective haematoma block and the increased difficulty in reduction.

An unnecessary MUA and therefore hospital admission avoided by the introduction of a template may also equate to a cost issue to a hospital trust. Clearly, the availability of a template is not going to remove the need of a general anaesthetic manipulation for all of these patients but it could improve their management.

Table 2 Junior doctor scores attained with and without the template

| Junior doctor | Score without template (out of 12) | Score with template (out of 12) |
|-------------------|------------------------------------|---------------------------------|
| 1 | 10 | 12 |
| 2 | 7 | 9 |
| 3 | 6 | 9 |
| 4 | 9 | 9 |
| 5 | 8 | 11 |
| 6 | 7 | 11 |
| 7 | 10 | 7 |
| 8 | 10 | 11 |
| 9 | 6 | 9 |
| 10 | 7 | 12 |
| 11 | 6 | 9 |
| 12 | 9 | 10 |
| Average % correct | 66% | 82.6% |

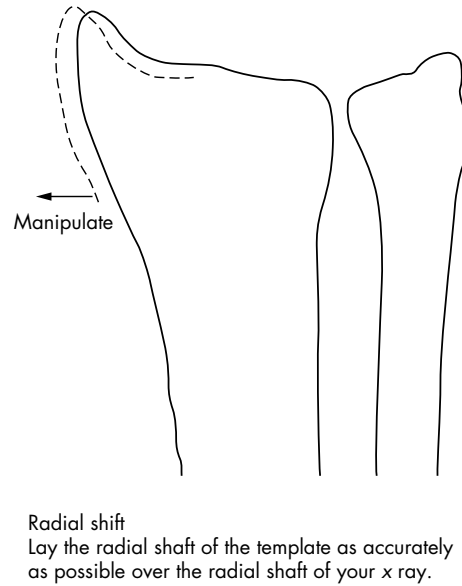


Figure 4 Enlarged view of radial shift

A significant improvement in recognition of substantial displacement was achieved by the junior doctors and ENPs in their first use of the template. With regular use this improvement is likely to increase. It could be argued that one would expect judgement to improve with experience. If this were entirely the case, we would have expected the three junior doctors with previous ED experience to have performed as well without the template as with it. In fact, all this group improved their scores when using the template.

Size difference between individual's bones proved not to be the problem we anticipated, with the template adequately fitting all radiographs tested so far. Any discrepancies can be further minimised by standardising the focal length used for radiographs.

Although most junior doctors and ENPs found the template easy to use, some did comment on making it more user friendly by labelling the template Left and Right as a reminder to flip the template over when encountering a Left wrist radiograph. Furthermore, a thumb could be included to distinguish volar from dorsal side. Van der Linden and Ericsson⁷ concluded that the displacement of a distal radial fracture may be adequately described by two measurements alone, dorsal tilt and radial shift, because other forms of displacement are directly related to them. The template could be simplified by using just two measurements of displacement.

In reality, most trauma and orthopaedic surgeons would accept more than 10° dorsal tilt in an elderly person. Indeed, Dias *et al*³ found that manipulation had no advantage over

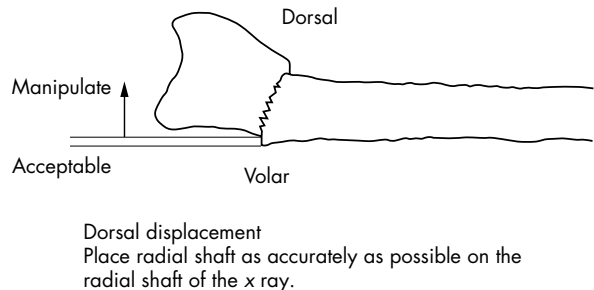


Figure 5 Enlarged view of dorsal displacement

Table 3 Emergency nurse practitioners' scores attained with and without the template

| Emergency nurse practitioner | Score without template (out of 12) | Score with template (out of 12) |
|------------------------------|------------------------------------|---------------------------------|
| 1 | 6 | 10 |
| 2 | 8 | 11 |
| 3 | 6 | 9 |
| 4 | 9 | 11 |
| 5 | 6 | 8 |
| 6 | 10 | 12 |
| Average % correct | 62.5% | 84.8% |

Table 4 Results of the feedback questions

| Question | Not at all useful/not at all easy | Not useful/not easy | Useful/easy | Very useful/very easy |
|------------------------------|-----------------------------------|---------------------|-------------|-----------------------|
| Template for decision making | 0 | 1 | 10 | 9 |
| Useful in A&E department | 0 | 1 | 6 | 13 |
| Ease of use | 1 | 4 | 7 | 8 |

conservative management in patients over 55 years of age, with up to 15° dorsal angulation acceptable. Kelly *et al*⁹ found that in some patients over 65 years old, up to 30° dorsal angulation could be accepted without significant deterioration in functional result. However, there are just as many studies that claim near anatomical reduction is key to achieving good functional and cosmetic results and that no more than 10° dorsal angulation should be accepted.^{4 7 8 10 11} This is why the acceptable limit was set at 10° in our study. Nevertheless, the design of the template is sufficiently simple that its limits could easily be tailored to the practices of an individual hospital.

This template has been shown to improve the decision making of junior doctors and ENPs with regard to distal radial fractures. At the cost of an overhead projector transparency the use of this device could reduce the number of inappropriately treated distal radial fractures and potentially reduce the numbers of patients requiring a MUA.

ACKNOWLEDGEMENTS

The authors would like to thank the Medical Illustration department at the Nuffield Orthopaedic Centre for their help with the figures used in this paper.

Authors' affiliations

R Kotnis, Oxford Trauma and Orthopaedic Rotation

M D Waites, South West Thames Trauma and Orthopaedic Rotation

O Fayomi, Oxford Emergency Medicine Rotation

R Dega, Consultant Trauma and Orthopaedic Surgeon, Wexham Park Hospital, Slough, Berkshire

Funding: none.

Competing interests: none declared

REFERENCES

- 1 **Golden GN**. Treatment and prognosis of Colles' fracture. *Lancet* 1963;511-15.
- 2 **McRae R**. *Practical fracture treatment*, Third Edition. London: Churchill Livingstone, 1999:11.
- 3 **Dias JJ**, Wray CC, Jones JM. The radiological deformity of Colles' fractures. *Injury* 1987;18:304-8.
- 4 **Stewart HD**, Innes AR, Burke FD. Factors affecting the outcome of Colles' fracture: an anatomical and functional study. *Injury* 1985;16:289-95.
- 5 **Pool C**. Colles's fracture. A prospective study of treatment. *J Bone Joint Surg [Br]* 1973;55B:540-4.
- 6 **Gartland JJ**, Werley CW. Evaluation of healed Colles' fractures. *J Bone Joint Surg [Am]* 1951;33A:895-907.
- 7 **Van der Linden W**, Ericsson R. Colles' fracture. How should its displacement be measured and how should it be immobilized? *J Bone Joint Surg [Am]* 1981;63A:1285-8.
- 8 **Lidström A**. Fractures of the distal end of the radius. A clinical and statistical study of end results. *Acta Orthop Scand* 1959;Suppl 41:1-118.
- 9 **Kelly AJ**, Warwick D, Crichtlow TPK, *et al*. Is manipulation of a moderately displaced Colles' fracture worthwhile? A prospective randomised trial. *Injury* 1997;28:283-7.
- 10 **McQueen M**, Caspers J. Colles fracture: does the anatomical result affect the final function? *J Bone Joint Surg [Br]* 1988;70B:649-51.
- 11 **McQueen M**, Maclaren A, Chalmers J. The value of remanipulating Colles' fractures. *J Bone Joint Surg [Br]* 1986;68B:232-3.