

white blood cell count was elevated at  $15.6 \times 10^3$  cells/mm<sup>3</sup>. Glucose, blood urea nitrogen, creatinine, sodium, potassium, and ionised calcium were within normal limits. Initial creatinine phosphokinase (CPK) level was greater than  $10 \times 10^3$  IU/L (normal range 24–204), and test for urine myoglobin was positive. Urine drug screen was negative for narcotics, cocaine, and amphetamines. ECG showed sinus tachycardia. Computed tomography of the head and cerebrospinal fluid studies were negative.

The patient was admitted to the intensive care unit with an initial diagnosis of meningoencephalitis and rhabdomyolysis. In addition to supportive management, he also received vigorous hydration, alkaline diuresis, and empirical antibiotics for coverage of probable meningitis. Renal function remained normal and CPK rapidly fell to within normal limits 2 days after admission. He was transferred to the medical ward on day 3 and was able to recall that he had ingested 30 pills of baclofen (Befon; 5 mg/tablet) in a suicide attempt about 36 hours before his arrival to the ED. He admitted that he irregularly took baclofen (5–10 mg a day) for treatment of spasticities due to amyotrophic lateral sclerosis. Co-ingestion of other drugs or alcohol was denied. The patient also had pains, swelling, and some pressure sores in his left buttock and thigh. An electroencephalogram performed 7 days after admission revealed diffuse cortical dysfunction compatible with encephalopathy. Other studies performed included somatosensory evoked potentials and magnetic resonance imaging of the brain, which were normal. He was discharged in excellent neurological function on day 12.

## DISCUSSION

Baclofen, a lipophilic analogue of the naturally occurring neurotransmitter gamma-aminobutyric acid (GABA), is the drug of choice for treatment of spasticity from spinal cord lesions and multiple sclerosis. It appears to act as an agonist at bicuculline insensitive GABA receptors in the spinal cord to decrease neurotransmitter release from presynaptic terminals.<sup>1</sup>

After a single therapeutic dose, baclofen is rapidly absorbed from the gastrointestinal tract. Blood levels peak within 2 hours. The serum half-life is 2–6 hours, which can be significantly prolonged after an overdose. The majority of this drug is excreted unchanged in the urine.<sup>2</sup> Signs of toxicity have been reported after ingestion of as little as 100 mg of

baclofen.<sup>3</sup> Adverse effects of baclofen overdose are well defined in the literature, and include somnolence, coma, seizures, encephalopathy, respiratory depression, flaccidity, hyporeflexia, and cardiac conduction abnormalities.<sup>4</sup> None of the patients described previously in the literature presented with rhabdomyolysis and acute delirium as in our case. Although uncommon, agitated confusion can be a pattern of baclofen encephalopathy. The mechanism for rhabdomyolysis in this case is uncertain. Drugs impairing the central nervous system, including baclofen, can cause rhabdomyolysis by pressure induced ischaemia due to prolonged immobilisation and muscle compression. This is supported in our case by the presence of pressure sores on the patient's left gluteus and thigh. Unwitnessed seizures may also have contributed to muscle breakdown in this case.

In conclusion, in the absence of detailed past medication history, an acutely confused patient complicated with rhabdomyolysis should have baclofen overdose included in the differential diagnosis, as routine toxicology screening does not include baclofen. Such atypical signs should be recognised early, as drug discontinuation and full supportive treatment result in good outcome, provided no hypoxic or ischaemic insult has occurred before medical attention.

## Authors' affiliations

**C-F Chong, T-L Wang**, Emergency Department, Shin-Kong Wu Ho-Su Memorial Hospital, Taipei, Taiwan, Republic of China

Competing interests: none declared

Correspondence to: Dr C-F Chong, Emergency Department, Shin-Kong Wu Ho-Su Memorial Hospital, No.95 Wen-Chang Rd, Shih-Lin District, Taipei City 111, Taiwan, Republic of China; jackchong@tmu.edu.tw

Accepted for publication 25 November 2004

## REFERENCES

- 1 **Ghose K**, Holmes KM, Matthewson K. Complications of baclofen overdosage. *Postgrad Med J* 1980;**56**:865–7.
- 2 **Gerkin R**, Curry SC, Vance MV, *et al*. First-order elimination kinetics following baclofen overdose. *Ann Emerg Med* 1986;**15**:843–6.
- 3 **Lee TH**, Chen SS, Su SL, *et al*. Baclofen intoxication: report of four cases and review of the literature. *Clin Neuropharmacol* 1992;**15**:56–62.
- 4 **Perry HE**, Wright RO, Shannon MW, *et al*. Baclofen overdose: drug experimentation in a group of adolescents. *Pediatrics* 1998;**101**:1045–8.

# An unusual swelling in the neck

**A A Abbasi, N S Harrop**

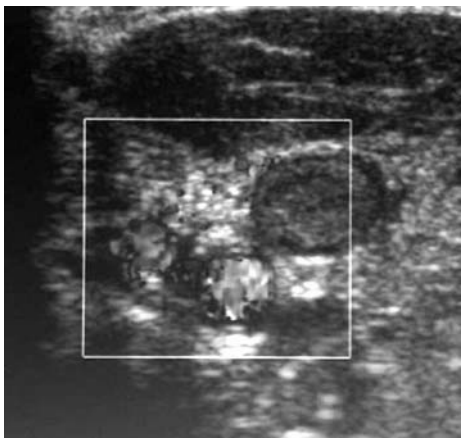
*Emerg Med J* 2005;**22**:674–675. doi: 10.1136/emj.2004.014613

Venous thrombosis is a fundamental pathological entity. Our patient provides an opportunity to consider etiology in terms of Virchow's classic triad. We also draw attention to the effort syndrome, in which recurrent, vigorous exertion of an upper extremity is thought to produce venous thrombosis by virtue of local endothelial trauma.

## CASE HISTORY

A 44 year old man was referred by his General Practitioner to the A&E department with a 4 to 5 day history of left-sided neck swelling, symptoms of pleuritic chest pain, and weight loss of one stone.

He had just returned from holiday in Africa and had suffered from altitude sickness whilst climbing Mount



**Figure 1** Showing an extensive thrombus within the left jugular vein, which extends to brachiocephalic and left axillary veins.

Kilimanjaro. He had then suffered a prolonged bout of diarrhoea.

At a first visit, the GP had advised fluids because of dehydration. After a few days, the patient developed swelling in the left supraclavicular region with intermittent chest pain. He was, therefore, referred to A&E.

On examination he looked well. There was a non-pulsatile, diffuse swelling, in the left supraclavicular region. It extended to the base of the neck. Its margins were not palpable. The swelling was red, hot, and tender. There was no lymphadenopathy.

The chest was clear and the heart sounds were pure. Abdominal examination was unremarkable.

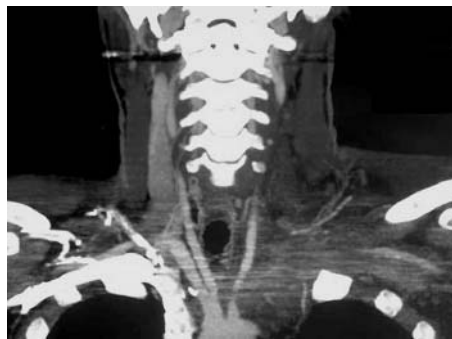He was thought to have an abscess. However, chest x rays showed broadening of the left superior mediastinum with a small left basal effusion. Ultrasound of the neck demonstrated extensive thrombus in the left jugular, subclavian, and axillary veins (figure 1). A thoracic CT scan demonstrated diffuse tissue swelling in the left side of the neck and superior mediastinum. CT did not disclose any lymphadenopathy. There were bilateral pleural effusions, more so on the left (figure 2).

The patient was admitted to a medical ward and he was treated for venous thrombosis with low molecular weight heparin initially, then Warfarin. The swelling improved. His CRP, initially significantly elevated (200), returned to normal. His full blood count, renal functions and liver functions were normal.

The patient was discharged after 5 days of hospital admission with advice to continue Warfarin for 6 months. He will have another CT scan after 6 weeks.

## COMMENT

Spontaneous thrombosis of the axillary or subclavian veins was first postulated as a cause of upper extremity pain and swelling by Sir James Padget in 1875.<sup>1</sup> Von Schroetter demonstrated thrombotic occlusion of upper limb veins, hence the Padget-Schroetter syndrome. More recently, the association between strenuous repetitive movement of the upper extremity and axillosubclavian thrombosis has been recognised and termed effort syndrome.<sup>2</sup> Apart from iatrogenic



**Figure 2** Showing an extensive thrombus within the left jugular vein, which extends to brachiocephalic and left axillary veins.

factors such as catheter placement, venous thrombosis of the axillary, or subclavian vein may be caused by external compression by an anatomical structure such as a congenital cervical rib or by the pathological development of a local tumour.<sup>3</sup>

Virchow's triad explains thrombosis in terms of venous stasis, vessel wall abnormality or disorders of the blood itself.<sup>4</sup>

In this patient, it is suspected that venous stasis may have been added to local tissue trauma. The patient had worn a rucksack, possibly obstructing venous flow as well as causing trauma to the vessel wall. He had suffered altitude sickness and it is of interest that hypoxia may also produce endothelial injury.<sup>5</sup> Finally, he had suffered a period of significant dehydration likely to have been attended by hemoconcentration and increased blood viscosity. In other patients, it is important to bear in mind that the occurrence of thrombosis at an unusual anatomic location may provide the first evidence of a hypercoagulable state, especially if there is a previous personal or a positive family history of thrombosis.<sup>6</sup> Suitable investigations would then include a haemophilia screen.

## Authors' affiliations

**A A Abbasi**, SpR in Accident and Emergency Medicine, Blackpool Victoria Hospital, Blackpool, Lancashire, UK

**N S Harrop**, Consultant in Accident and Emergency Medicine, Blackpool Victoria Hospital, Blackpool, Lancashire, UK

Correspondence to: A A Abbasi, Accident & Emergency Department, Blackpool Victoria Hospital, Blackpool, FY3 8NT; [aaabbasi38@hotmail.com](mailto:aaabbasi38@hotmail.com)

Accepted for publication 26 February 2004

## REFERENCES

- 1 **Coon WW**, Willis PW. Thrombosis of axillary and subclavian veins. *Arch Surg* 1967;**94**:657-63.
- 2 **Adams JT**, DeWeese JA. Effort thrombosis of axillary and subclavian veins. *Trauma* 1971;**11**:923-30.
- 3 **Horattas MC**, Wright DJ, Fenton AH. Changing concepts of deep vein thrombosis of the upper extremity-report of a series and review of the literature. *Surgery* 1988;**104**:561-7.
- 4 **Paget J**. *Clinical lectures and essays*. Green London, UK: Longman, 1875.
- 5 **Cromwell DL**. Effort thrombosis of the subclavian and axillary veins: review of the literature. *Ann Intern Medicine* 1960;**52**:1337-43.
- 6 **Thomas DP**, Roberts HR. Hypercoagulability in venous and arterial thrombosis. *Ann Intern Med* 1997;**126**:638-44.