

# A prospective evaluation of magnetic resonance cholangiopancreatography in patients with suspected bile duct obstruction

H E Adamek, J Albert, M Weitz, H Breer, D Schilling, J F Riemann

## Abstract

**Background**—The value of magnetic resonance cholangiopancreatography (MRCP) is under debate.

**Aims**—To assess the diagnostic accuracy of MRCP and endoscopic retrograde cholangiopancreatography (ERCP) and to determine whether MRCP may help to prevent unnecessary interventional procedures.

**Methods**—Eighty six patients with suspected common bile duct obstruction who presented between January and December 1996 were enrolled. Twenty six were excluded due to anatomical reasons or because MRCP or ERCP could not be performed successfully. Results of MRCP were interpreted by two radiologists and a gastroenterologist unaware of clinical diagnosis. Final diagnosis was determined by ERCP and histopathological findings or a follow up of at least 12 months.

**Results**—MRCP images of diagnostic quality were obtained in all 60 patients. Thirteen patients had a clear bile duct. Sensitivity and specificity for the detection of any abnormality (n=47) were 89% and 92%, and for the detection of malignancy (n=27) 81% and 100%, respectively. These results were equivalent to the respective figures of ERCP (91% and 92% for any abnormality, and 93% and 94% for malignant diseases).

**Conclusions**—MRCP is as sensitive as ERCP in the evaluation of biliary tract diseases. As the specificity of this non-invasive technique is close to 100%, MRCP

may prevent inappropriate invasive explorations of the common bile duct and pancreatic duct.

(Gut 1998;43:680-683)

Keywords: bile duct obstruction; magnetic resonance cholangiopancreatography;

Accurate methods of detecting common bile duct and pancreatic diseases in patients with obstructive jaundice are important to both surgeons and endoscopists. At present, endoscopic ultrasonography (EUS) and computed tomography (CT) although non-invasive diagnostic tools, are not always sufficiently sensitive.<sup>1-3</sup> Endoscopic retrograde cholangiopancreatography (ERCP) still is the gold standard for exploration of the biliopancreatic region. Nevertheless, ERCP is associated with significant complication rates.<sup>4</sup> Therefore, there is a clear need for a less invasive, safe, and highly sensitive diagnostic procedure for patients with suspected bile duct or pancreatic duct abnormalities.

The development of fast imaging sequences and the improvements in the quality of abdominal images have generated a new interest in magnetic resonance evaluation of biliopancreatic diseases.<sup>5</sup> Magnetic resonance cholangiopancreatography (MRCP) is a recently described, completely non-invasive technique that provides projectional images similar to those of ERCP without administration of contrast agents (fig 1). Recent technical developments have led to notable improvements in this field with a surprising clinical acceptance by gastroenterologists. The accuracy of MRCP in diagnosing common bile duct diseases has been evaluated by several authors.<sup>6,7</sup> Nevertheless, larger comparative studies evaluating MRCP and ERCP in patients with obstructive jaundice are not available. Thus, the respective roles of MRCP and ERCP in the diagnosis of common bile duct diseases are not well defined.

In order to determine the usefulness of MRCP in patients with suspected bile duct obstruction and to investigate whether MRCP may help to prevent unnecessary interventional procedures, we conducted a prospective controlled trial.

## Patients and methods

### PATIENTS

Patients were included into the study if they met one of the following criteria: biochemical abnormalities (raised alkaline phosphatase or  $\gamma$

### Department of Medicine

H E Adamek  
J Albert  
D Schilling  
J F Riemann

Department of Radiology, Klinikum Ludwigshafen, Academic Hospital of the University of Mainz, Germany  
M Weitz  
H Breer

Correspondence to:  
Dr H E Adamek,  
Department of Medicine C,  
Klinikum Ludwigshafen,  
Bremerstrasse 79, D-67063  
Ludwigshafen, Germany.

Accepted for publication  
29 April 1998

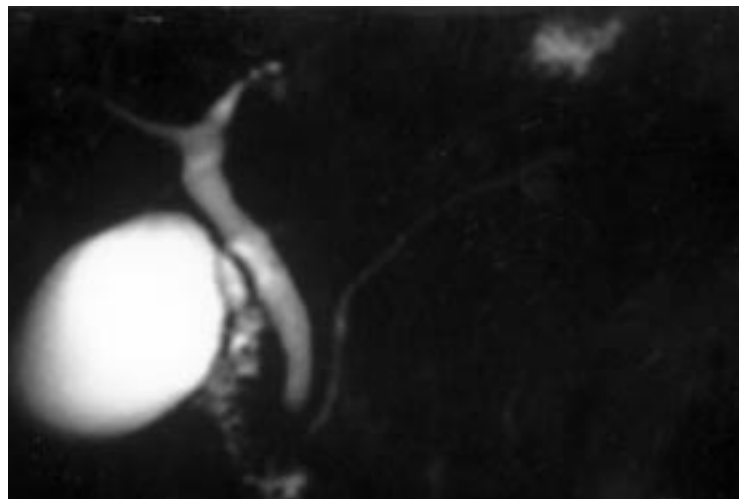


Figure 1 Normal sized biliary and pancreatic ducts and gall bladder.

Table 1 Diagnoses in the patient population (n = 60)

Final diagnosis	No of patients
Normal	13
Benign stricture	15
Cholelithiasis	3
Hepatolithiasis	1
Choledochal cyst	1
Malignant stricture	23
Cholangiocarcinoma	4

glutamyltranspeptidase more than twice the normal value and serum bilirubin above 2 µg/dl) or morphological features on abdominal ultrasonography (common bile duct dilated more than 7 mm in patients with a gall bladder in situ and 9 mm in patients with previous cholecystectomy). Patients were usually referred to us with a request for ERCP.

Between January and December 1996, 86 patients were eligible for the study (fig 2). All patients were scheduled to undergo ultrasonography as soon as possible. Informed consent was obtained for all patients. Eight patients had to be excluded because former operations with biliary enteric anastomosis (Roux-en-Y gastrojejunostomy or Whipple's procedure) made successful ERCP unlikely. These patients were included in a recent study of MRCP after failed ERCP.<sup>8</sup> In two patients, MRCP was not possible due to their claustrophobia, and complete ERCP was technically unsatisfactory in a further 16 patients, mainly because of distal common bile duct stenosis. Thus, the present study describes the findings in 60 patients (31 men and 29 women; mean age 64.4 years, range 11–78) with complete ERCP and MRCP information (table 1).

#### METHODS

The MR cholangiopancreatograms were acquired using commercially available software in a clinical MR scanner (Magnetom Expert 1-T-Scanner, Siemens Medical Systems, Erlangen, Germany) with a body coil. All sequences were performed during breath holding. After localised imaging, heavily T2 weighted pulse sequences were obtained in coronal and transverse planes. As a result, stationary fluids with a long T2 relaxation time, such as bile and pancreatic juice, will have a very high signal intensity. Two three-dimensional turbo spin echo techniques (3D TSE) were acquired

whenever possible: a single shot rapid acquisition with relaxation enhancement (RARE) technique with the acquisition of a single thick slice covering the entire imaging volume within a four second breath hold; and a further development of this technique by the addition of a half Fourier turbo spin echo sequence during a breath hold period of 18 seconds (HASTE). In this multislice technique, nine contiguous slices were obtained in an interleaved fashion with a thickness of 5 mm (acquisition time, 18 seconds). The field of view ranged from 16 to 40 cm, depending on the area of interest or the patient's condition.

Magnetic resonance cholangiopancreatograms were reviewed at the diagnostic workstation and on hard copy films. Individual source images were considered together with three-dimensional reconstructed views (MIP, maximum intensity projection).

The magnetic resonance tomography (MRT) and ERCP operators knew that the patient was participating in the study and they saw the patient's ultrasound examination. The operators were unaware of each other's findings until completion of data collection by a clinician who attended neither investigation. MRCP images were initially assessed for overall quality and visualisation of the intrahepatic and extrahepatic ductal systems as well as the pancreatic duct. If no bile ducts were visualised, the study was considered non-diagnostic. End points of the study were the size of the common bile duct and the pancreatic duct, the nature and the level of obstruction, the presence and the number of stones, and the ability to make an accurate diagnosis in patients with pathological findings. The interpretation of the ERCP images together with a histopathological finding or a follow up were used as the standard of reference for the determination of sensitivity and specificity of MRCP.

#### STATISTICS

Complete data collection was recorded on a database program (MS Paradox for Windows). Values are expressed as median (range) or mean (SD), unless otherwise stated. Data analysis was performed with a statistical software package (Unistat 3.0 for Windows, Unistat Co., UK). Results were compared between groups using a  $\chi^2$  statistic. Sensitivity, specificity, and positive predictive value were calculated. Probability values of less than 0.05 were considered statistically significant.

#### Results

MRCP studies of diagnostic quality were obtained in all subjects regardless of whether the common bile duct was dilated or not. MRCP correctly identified normal common bile duct calibre in 12 of the 13 patients (sensitivity 92%). MRCP presumed a biliary stricture in a patient with chronic pancreatitis. However, retrograde cholangiography showed a normal common bile duct.

All three cases of choledocholithiasis were correctly diagnosed on MRCP (fig 3). In one patient, stones were present in only the

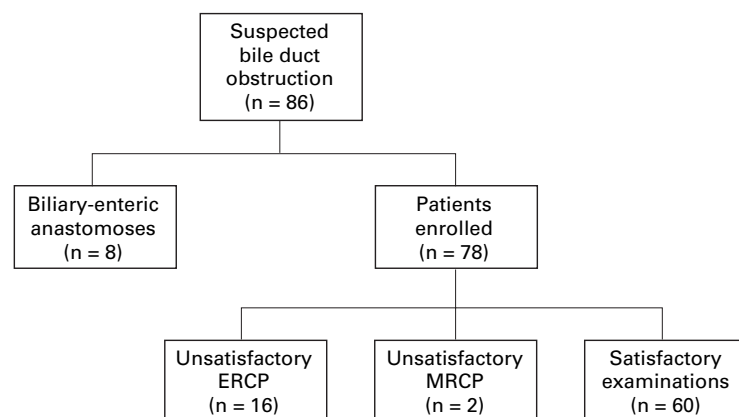


Figure 2 Flow chart of the study sample.

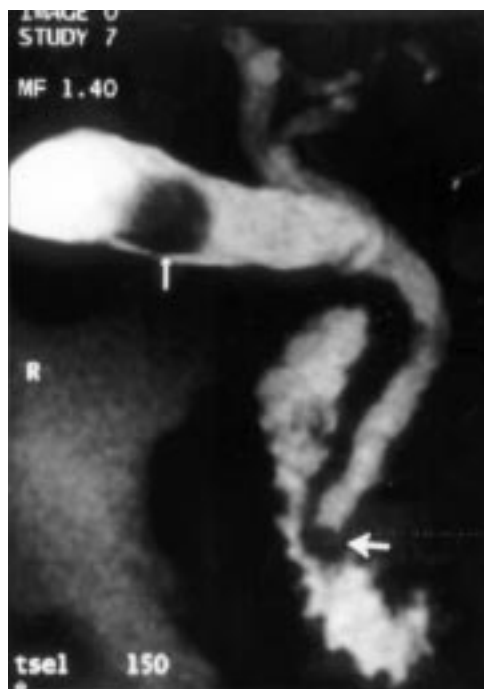

Figure 3 Choledocholithiasis. MRCP showing a distal intraductal filling defect representing a stone (thick arrow). Another stone can be easily seen in the gall bladder (thin arrow).

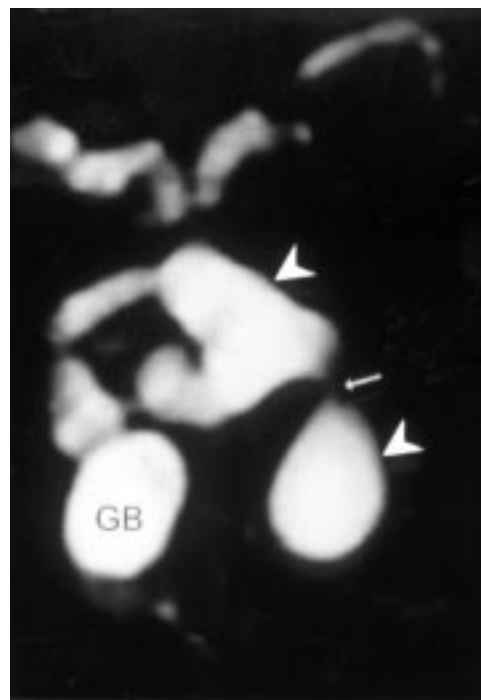


Figure 4 Cystic dilatation of the common bile duct. Multiple extrahepatic cysts (arrowheads) with a short stricture (thin arrow) representing a type 4B congenital dilatation of bile ducts according to Tōdani et al's modification of Alonso-Lej's classification.<sup>23</sup> GB, gall bladder.

intrahepatic bile ducts. MRCP not only showed the hepatolithiasis, but also presented data about the underlying dilatation of the bile ducts. Furthermore, MRCP showed large dilatation of the common bile duct in one child with a choledochal cyst (fig 4), that was not known previously. Overall, the sensitivity for detection of intraductal abnormalities was 100%.

Fifteen patients presented with a biliary stricture of benign origin (postoperative after laparoscopic cholecystectomy, due to chronic pancreatitis or cholangitis). MRCP correctly identified the presence, location, and cause of the strictures in all cases (sensitivity 100%).

Twenty seven patients had bile duct strictures due to malignant diseases (pancreatic carcinoma, ampullary carcinoma, or cholangiocarcinoma). Twenty two cases were correctly diagnosed on MRCP (sensitivity 81%). Malignant bile duct obstruction was misinterpreted on five occasions. In two patients, diffuse intrahepatic ductal changes due to cholangiocarcinoma (evident on ERCP) were not appreciated on MRCP. Two bile duct strictures were classified as benign (postoperative after former cholecystectomy); follow up, however, revealed malignant obstruction due to metastatic lesions. In one patient with a pancreatic head carcinoma, the common bile duct was normal on MRCP.

No complications were encountered after MRT. Three patients had minor complications (mild acute pancreatitis) after ERCP.

MRCP and ERCP showed similar sensitivities (table 2). However, MRCP yielded a high specificity for detecting malignant obstruction (100%)—no false positive results were recorded. In contrast, ERCP missed two cases of

Table 2 Sensitivity, specificity and positive predictive value (PPV) of MRCP for detecting biliary diseases

MRCP diagnosis	Any abnormality	Detection of malignancy
Sensitivity	89 (42/47)	81 (22/27)
Specificity	92 (12/13)	100 (33/33)
PPV	98 (42/43)	100 (22/22)

Results are expressed as % (no of examinations).

pancreatic carcinoma that were misinterpreted as chronic pancreatitis.

## Discussion

Over the past two decades, ERCP has emerged as the principal method for diagnostic examination of the biliary tree. Nevertheless, diagnostic ERCP is an uncomfortable procedure associated with a complication rate of up to 9%.<sup>9</sup> Today MRCP, a non-invasive technique with no morbidity, has gained a role in the evaluation of bile duct disease. Preliminary results show high sensitivity in detecting benign or malignant lesions affecting the biliary tree and related organs as well as intrahepatic and common bile duct lithiasis.<sup>10</sup> Recently, ERCP has been challenged not only by MRCP but also by endoscopic ultrasonography (EUS), which has proved to have an equal or superior sensitivity in diagnosing choledocholithiasis.<sup>11</sup>

Our prospective controlled study is the first to confirm that MRCP, compared with ERCP and with a follow up of at least one year, can distinguish clearly between benign and malignant diseases. In contrast to former investigations, we reviewed MR cholangiograms and pancreatograms. Introducing a technique

based on the RARE pulse sequence, we were able to visualise even the normal pancreatic duct as a high signal structure against a black low signal background.<sup>12</sup>

We found MRCP to be highly sensitive in the visualisation of normal common bile duct. This corresponds to other studies that were able to visualise the normal extrahepatic bile ducts in 90–100% of patients.<sup>10–13</sup> Bile duct dilatation is constantly visible during MRCP.<sup>14–15</sup> Although only three cases of choledocholithiasis were found, our results confirm former trials, finding a sensitivity approaching 100% for detection of biliary ductal dilatation and choledocholithiasis.<sup>16</sup> Smaller calculi are sometimes missed on single shot sequences and are better visualised on source images.<sup>17</sup> In choledocholithiasis, MRCP competes with EUS, which had a sensitivity of 97% in a recent investigation.<sup>1</sup>

Until now, there has been little information about the value of MRCP in diagnosing choledochal cysts.<sup>18–20</sup> In our trial, we were able to depict one case of choledochal cyst in a child presenting with jaundice, fever, and abdominal pain. MRCP was able to display the anomaly, as well as the common bile duct stricture associated with the cyst. Thus, MRCP is able to present a detailed visualisation of the anatomy of the choledochal cyst and surrounding bile ducts, which is required for planning surgery and postoperative control.

Although the diagnosis of malignant bile duct obstruction can be established by ultrasonography, the evaluation of tumour site and disease extent requires direct cholangiopancreatography. ERCP often only shows the ducts below the site of obstruction (double duct sign); visualisation of an obstructed part of the biliary tree is often not possible. In addition, opacification of undrained bile ducts places the patient at risk of cholangitis. Our results confirm the findings of former studies,<sup>21</sup> where MRCP sometimes failed to depict the cause of bile duct obstruction. Sensitivity of MRCP (81%) is less than that of ERCP (93%). Nevertheless, the differential diagnostic considerations can be improved with evaluation of the MR images always obtained before MRCP images.<sup>22</sup>

In the future, MRT will provide a sophisticated non-invasive technique for suspected biliary or pancreatic malignancies. In a single study, it has the potential of producing excellent cross sectional images of the liver and pancreas together with MRCP as well as MR angiography, thus extending the diagnostic information from simple biliopancreatic duct morphology to the surrounding structures, such as parenchymal and vascular tissues. It will therefore decrease the total cost of diagnostic work up in patients with suspected pancreatic carcinoma, providing similar or better results than ERCP, EUS, angiography, and CT in a single examination. This trend will probably improve the current lack of MR equipment in Europe, which is overloaded by neuroradiological and osteoarticular routines.

However, most pancreatic carcinomas are unresectable at the time of diagnosis; these

patients benefit from palliative endoscopic biliary drainage. Its inability to offer therapeutic interventions is a major weakness of MRCP. Another advantage of ERCP is the ability to visualise the ampulla at endoscopy and to carry out biopsies when indicated.

In conclusion, MRCP provides similar results to ERCP in patients with suspected bile duct obstruction. In patients in whom an interventional endoscopic procedure is unlikely, MRCP can replace ERCP as a diagnostic tool, as it is non-invasive and well tolerated by patients.

- 1 Amouyal P, Amouyal G, Lévy P, *et al.* Diagnosis of choledocholithiasis by endoscopic ultrasonography. *Gastroenterology* 1994;**106**:1062–7.
- 2 Fleischmann D, Ringl H, Schöfl R, *et al.* Three-dimensional spiral CT cholangiography in patients with suspected obstructive biliary disease: comparison with endoscopic retrograde cholangiography. *Radiology* 1996;**198**:861–8.
- 3 Stockberger SM, Wass JL, Sherman S, *et al.* Intravenous cholangiography with helical CT: comparison with endoscopic retrograde cholangiography. *Radiology* 1994;**192**:675–80.
- 4 Bilbao MK, Dotter CT, Lee TG, *et al.* Complications of retrograde cholangiopancreatography (ERCP): a study of 10 000 cases. *Gastroenterology* 1976;**70**:314–20.
- 5 Bearcroft PW, Lomas DL. Magnetic resonance cholangiopancreatography. *Gut* 1997;**41**:135–7.
- 6 Hall-Craggs MA, Allen CM, Owens CM, *et al.* MR cholangiography: clinical evaluation in 40 cases. *Radiology* 1993;**189**:423–7.
- 7 Guibaud L, Bret PM, Reinhold C, *et al.* Bile duct obstruction and choledocholithiasis: diagnosis with MR cholangiography. *Radiology* 1995;**197**:109–15.
- 8 Adamek HE, Weitz M, Breer H, *et al.* Value of magnetic-resonance cholangiopancreatography (MRCP) after unsuccessful endoscopic retrograde cholangiopancreatography (ERCP). *Endoscopy* 1997;**29**:741–4.
- 9 Baillie J. Complications of endoscopy. *Endoscopy* 1994;**26**:185–203.
- 10 Soto JA, Barish MA, Yucel EK, *et al.* Magnetic resonance cholangiography: comparison with endoscopic retrograde cholangiopancreatography. *Gastroenterology* 1996;**110**:589–97.
- 11 Prat F, Amouyal G, Amouyal P, *et al.* Prospective study of endoscopic ultrasonography and endoscopic retrograde cholangiography in patients with suspected common-bile duct lithiasis. *Lancet* 1996;**347**:75–9.
- 12 Soto JA, Barish MA, Yucel EK, *et al.* Pancreatic duct: MR cholangiopancreatography with a three-dimensional fast spin-echo technique. *Radiology* 1995;**196**:459–64.
- 13 Guibaud L, Bret PM, Reinhold C, *et al.* Diagnosis of choledocholithiasis: value of MR cholangiography. *AJR Am J Roentgenol* 1994;**163**:847–50.
- 14 Ishizaki Y, Wakayama T, Okada Y, *et al.* Magnetic resonance cholangiography for evaluation of obstructive jaundice. *Am J Gastroenterol* 1993;**88**:2072–7.
- 15 Kubo S, Hamba H, Hirohashi K, *et al.* Magnetic resonance cholangiography in hepatolithiasis. *Am J Gastroenterol* 1997;**92**:629–32.
- 16 Devière J, Matos C. Which test for common bile duct stones? Magnetic resonance cholangiopancreatography. *Endoscopy* 1997;**29**:666–8.
- 17 Becker CD, Grossholz M, Mentha G, *et al.* MR cholangiopancreatography: technique, potential indications, and diagnostic features of benign, postoperative, and malignant conditions. *Eur J Radiol* 1997;**7**:865–74.
- 18 Kubo S, Kinoshita H, Higaki I, *et al.* Choledochal cyst detected by MR cholangiopancreatography. *AJR Am J Roentgenol* 1996;**164**:513–14.
- 19 Pavone P, Laghi A, Catalano C, *et al.* Caroli's disease evaluation with MR-cholangiography (MRCP). *Abdom Imaging* 1996;**21**:111–19.
- 20 Ng KK, Wan YL, Lui KW, *et al.* Three-dimensional magnetic resonance cholangiopancreatography for evaluation of obstructive jaundice. *J Formos Med Assoc* 1997;**96**:586–92.
- 21 Hintze RE, Adler A, Veltzke W, *et al.* Clinical significance of magnetic resonance cholangiopancreatography (MRCP) compared with endoscopic retrograde cholangiography (ERCP). *Endoscopy* 1997;**29**:182–7.
- 22 Lomanto D, Pavone P, Laghi A, *et al.* Magnetic resonance cholangiopancreatography in the diagnosis of biliopancreatic diseases. *Am J Surg* 1997;**174**:33–8.
- 23 Todani T, Watanabe Y, Narusue M, *et al.* Congenital bile duct cysts. Classifications, operative procedures and review of thirty-seven cases including cancer arising from choledochal cyst. *Am J Surg* 1977;**143**:263–9.