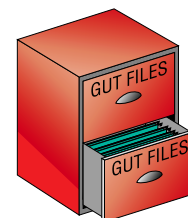


Idiopathic giant oesophageal ulcer in an immunocompetent patient. The efficacy of thalidomide treatment



Background—Idiopathic oesophageal ulcers have only been described in patients with acquired immunodeficiency syndrome (AIDS). We report the first case occurring in an immunocompetent patient.

Case history—A 52 year old man presented with a one year history of odynophagia, retrosternal chest pain, dysphagia, and a 10 kg weight loss. He had no history of gastrointestinal disease and had not taken drugs. An upper endoscopy, performed shortly after symptom onset, showed a 3 cm solitary oesophageal ulcer with smooth and irregular margins 3 cm above the gastro-oesophageal junction. Biopsy samples showed acute and chronic inflammation without any fungal or viral particles. Despite three months on a proton pump inhibitor, symptoms and endoscopic findings did not change. Oesophageal manometry and pH metry were normal, and endoscopic ultrasonography revealed thickening of all oesophageal wall layers without suspicious lymph nodes. Therapeutic trials, including lansoprazole (60 mg daily), acyclovir (1 g daily), and prednisolone (1 mg/kg daily), were ineffective.

A distal oesophagectomy was performed. Examination of the resected specimen showed a chronic ulcer (fig 1) covered with fibrous exudates; the oesophageal wall, down to the adventitia, had been replaced by collagenous fibrosis. Some lymphoid follicles with germinal centres were found, and there was no lymphoepithelial lesion or lymphoid cell infiltration. Two months later, the patient relapsed and endoscopy showed two ulcers above the gastro-oesophageal anastomosis (fig 1).

Thalidomide (150 mg daily for six weeks) improved symptoms quickly. After 28 days, the treatment was well tolerated and the symptoms had resolved. Six months after the end of the treatment, the patient remained asymptomatic and had gained 4 kg; endoscopy confirmed that the lesions had healed completely.

Immunological and infectious tests—Serology for HIV, cytomegalovirus, herpes simplex virus, HTLV1, and antinuclear antibodies was negative. CD4 count, immunoglobulin dosage, lymphoblastic proliferation test, and tetanus antibody dosage were normal and the tuberculin test was positive.

Histological examination of biopsy and surgical specimens did not find any fungal or viral infection. Histochemical studies (PAS, Grocott) and virological cultures for cytomegalovirus, herpes simplex virus, and adenovirus were negative. The immunohistochemical study confirmed the presence of B lymphocytes in the lymphoid follicles and showed some T lymphocytes in the fibrotic areas.

Conclusion—This is the first case of an idiopathic giant oesophageal ulcer in an immunocompetent patient. Other puzzling features were the recurrence of the ulcer after surgical resection, and the dramatic and sustained efficacy of thalidomide. Our patient did not take any medication before the onset of symptoms. Gastro-oesophageal reflux was excluded, and there was no evidence of infectious agents or neoplastic lesions in the biopsy or resection specimens. The clinical context, laboratory tests, and histological findings excluded other causes of oesophageal ulcers, such as ischaemic pathology, Crohn's disease, Behçet's disease, and bullous diseases.

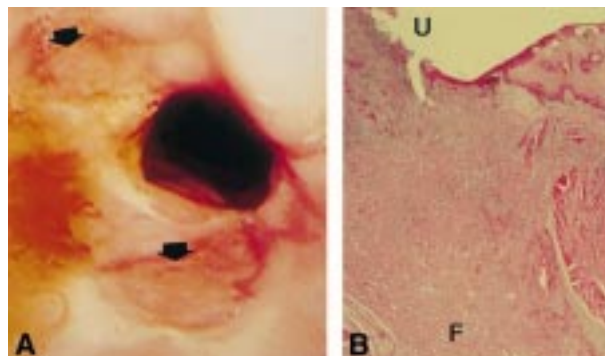


Figure 1 (A) Endoscopic image showing two large ulcerations of the distal oesophagus, above the oesophago-gastric anastomosis (arrows). (B) Microscopic view of surgical specimen (original magnification $\times 5$; haematoxylin and eosin); the ulcer (U) extends to the adventitia with noticeable fibrosis (F).

Extensive investigation of giant oesophageal ulcers in patients with HIV failed to identify any infection in 8–40% of cases.^{1–4} This virus was thought to cause the idiopathic ulcers in patients with HIV.^{5–7} However, our case provides the first evidence that idiopathic oesophageal ulcers can occur in the absence of HIV infection.

Thalidomide has been reported to be an effective treatment for oral and oesophageal ulcerations associated with AIDS.^{2 8–11} It may work by stimulating the proliferation of suppressor T lymphocytes and inhibiting the HIV virus by interfering with tumour necrosis factor α protein and mRNA.¹² In our case, it induced a complete and sustained healing of signs and lesions.

S OLLIVIER
J BONNET
M LEMANN
J-C COFFIN
R MODIGLIANI
R JIAN

Department of Gastroenterology

P BERTHEAU
Department of Pathology
Hôpital Saint-Louis,
75475 Paris CEDEX 10,
France

J-F FLEJOU
Department of Pathology,
Hôpital Beaujon,
Paris,
France

Correspondence to: Dr Jian.

- Baehr PH, McDonald GB. Oesophageal infections: risk factors, presentation, diagnosis, and treatment. *Gastroenterology* 1994;106:509–32.
- Connolly GM, Hawkins D, Harcourt-Webster JN, et al. Oesophageal symptoms, their causes, treatment, and prognosis in patients with acquired immunodeficiency syndrome. *Gut* 1989;30:1033–9.
- Bonacini M, Young T, Laine L. The causes of esophageal symptoms in human immunodeficiency virus infection. A prospective study of 110 patients. *Arch Intern Med* 1991;151:1567–72.
- Wilcox CM, Schwartz DA, Scott Clark W. Esophageal ulceration in human immunodeficiency virus infection. *Ann Intern Med* 1995;122:143–9.
- Chawla SK, Ramani K, Chawla K, et al. Giant esophageal ulcers of AIDS: ultrastructural study. *Am J Gastroenterol* 1994;89:412–15.
- Wilcox CM, Hewan-Lowe K. Etiology of human immunodeficiency virus-associated idiopathic esophageal ulcer. *Am J Gastroenterol* 1994;89:1913.

- 7 Rabeneck L, Popovic M, Gartner S, *et al.* Acute HIV infection presenting with painful swallowing and esophageal ulcers. *JAMA* 1990;263:2318–22.
- 8 Jacobson JM, Greenspan JS, Spritzler J, *et al.* Thalidomide for the treatment of oral aphthous ulcers in patients with human immunodeficiency virus infection. *N Engl J Med* 1997;336:1487–93.
- 9 Naum SM, Molloy PJ, Kania RJ, *et al.* Use of thalidomide in treatment and maintenance of idiopathic esophageal ulcers in HIV+ individual. *Dig Dis Sci* 1995;40:1147–8.
- 10 Paterson DL, Georghiou PR, Allworth AM, *et al.* Thalidomide as treatment of refractory aphthous ulceration related to human immunodeficiency virus infection. *Clin Infect Dis* 1995;20:250–4.
- 11 Sire S, Fraisse P, Rey D. Efficacité du thalidomide dans le traitement des ulcérations œsophagiennes au cours de l'infection par le virus de l'immunodéficience humaine. *Gastroenterol Clin Biol* 1995;19:128–9.
- 12 Makonkawkeyoon S, Limson-Pobre PNR, Moreira AL, *et al.* Thalidomide inhibits the replication of human immunodeficiency virus type 1. *Proc Natl Acad Sci USA* 1993;90:5974–8.